

CASE REPORT

Pancreaticoduodenectomy in a patient with a rare celiac trunk and hepatic artery anomaly, a case report from Syria

Basel Ahmad*, Ahmed Alshammat, Alin Haya Hamed, M. Fadi Alkurdi, and Hamoud Hamed

Faculty of Medicine, Damascus University, Syria

*Correspondence address. Salim Abdoon St. 194, Saroujah 06, Damascus, Syria. Tel: +00963967957367; E-mail: dr.baselahmad@gmail.com

Abstract

Pancreaticoduodenectomy is still one of the biggest and high complicated surgeries. It still has high morbidity and mortality rates. Liver receives its blood supply from one hepatic artery a branch of the celiac trunk. However variations of hepatic and celiac trunk are not rare. We present a case of a 60-year-old patient who underwent pancreaticoduodenectomy for ampulla tumor in which there were some rare anomalies. Angiographic CT after procedure confirmed the absence of celiac trunk, the absence of left gastric, the splenic artery arising from aorta directly and common hepatic artery arising from superior mesenteric artery. These anomalies are not considered contraindication and should not be. With good surgical experience the procedure may be done safely giving the patient his last choice to fight the disease.

INTRODUCTION

Pancreaticoduodenectomy (PD) is one of the biggest and high complicated surgery. It still has high morbidity and mortality rates [1].

Normally, liver receives its blood supply from one hepatic artery a branch of the celiac trunk and a pancreaticoduodenal arcade between superior mesenteric artery (SMA) and hepatic artery (HA) [2].

However, this normal supply applies only for 50-60% of cases [2] and variations of hepatic and celiac trunk are not rare [1].

These variations may complicate the procedure more and could lead to serious complications as biliary fistula, hepatic ischemia, hemorrhage and liver abscesses [1, 3].

Many surgeons have studied these anomalies in detailed and Michel's classification is probably the most used one [1].

We present a case of a 60-year-old patient who underwent pancreaticoduodenectomy for ampulla tumor and had a very rare anomaly in the celiac trunk and hepatic artery.

CASE REPORT

A 60-year-old patient with no medical history but diabetes mellitus II was referred to our tertiary university hospital (Al-Assad university hospital) for intermittent jaundice.

The complaint started one year before, in which the patient suffered fatigue and general weakness without weight loss or changes in bowel movement.

One month before admission, he developed pain in the right upper quadrant and intermittent jaundice as well as fatigue and general weakness.

Received: April 8, 2019. Accepted: April 24, 2019

Published by Oxford University Press and JSCR Publishing Ltd. All rights reserved. © The Author(s) 2019.

This is an Open Access article distributed under the terms of the Creative Commons Attribution Non-Commercial License (<http://creativecommons.org/licenses/by-nc/4.0/>), which permits non-commercial re-use, distribution, and reproduction in any medium, provided the original work is properly cited. For commercial re-use, please contact journals.permissions@oup.com

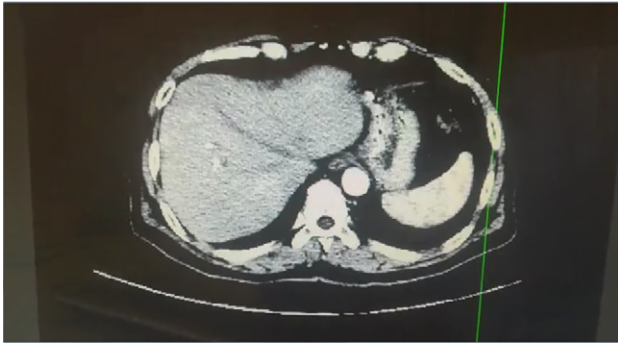On admission, the patient had no symptoms, no jaundice the lab values are shown on (Table 1).

Ultrasound showed common biliary duct dilation 2 cm, intrahepatic biliary system dilation. ERCP then was indicated in

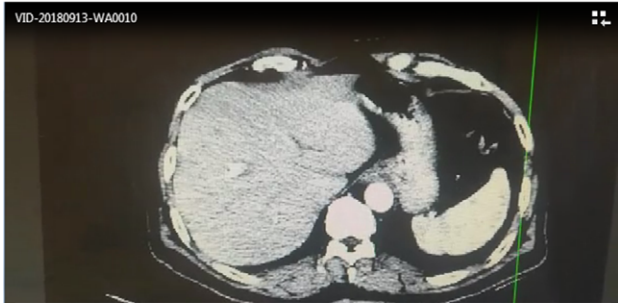
Table 1 Lab results on admission.

Test	Result	Reference range
White blood cells	6.29	4400–11 000/ μ l
Neutrophils percent	62%	40–70%
Hemoglobin	12	13–16 g/dl
Hematocrit	37.5	38–53%
Platelets	267	150–450 \times 103/ μ l
Urea	24	10–50 mg/dl
Creatinin	0.9	0.7–1.36 mg/dl
ALT	26	8–20 IU/l
AST	18	8–20 IU/l
PT	88%	
CEA	1.45	Up to 3, non smokers up to 6, smokers
CA19_9	2.28	0–37
AFP	1.33	0–10.9

(a)



(b)



(c)

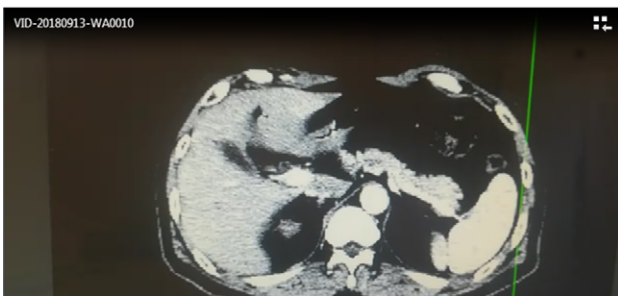


Figure 1: CT scan.

which swollen ampulla was detected, dilated common biliary duct 2 cm, dilation of intra hepatic ducts, signs of which increased the suspicion of ampulla tumor, so the ampulla was cut, biopsies were taken and 8.5 plastic stent was administrated.

CT scan showed no signs of metastasis (Fig. 1).

ERCP biopsy came out: villous adenomatous of ampulla vater with focal mild to moderate dysplasia. Thus the patient was being prepared for whipple procedure.

In operating room, Kocher incision, no ansarca, no peritoneal metastasis, the decision to perform whipple procedure was made. Gallbladder was resected, kocher maneuver, when isolating the CBD and common hepatic artery, anomalies were found, and the artery system was not that clear, no clear celiac trunk and no clear common hepatic artery. (Fig. 2)

Decision to continue whipple procedure was made, and slow and careful ligation of arteries was performed. Hopefully, the surgical team managed to make the procedure done.

Final pathology report: adenocarcinoma of the ampulla grade 1, duodenal gastric and pancreatic surgical margins were free, all isolated lymph nodes were free 0/18, the lymph nodes are free pT1a, Pn9, Mx.

Angiographic CT after procedure confirmed the absence of celiac trunk, the absence of left gastric, the splenic artery arising from aorta directly and common hepatic artery arising from superior mesenteric artery.(Fig. 3)

The patient was discharged one week later with 2 days in ICU,. 6 month follow-up revealed a healthy patient with no recurrence or ischemic complication.

DISCUSSION

It is a fact that it is hard even for experienced surgeons to perform major surgeries, such as liver resection, liver transplant or pancreaticoduodenectomy, these surgeries challenge the surgeons at their best [1].

only 52–80% of all cases has normal hepatic arterial anatomy in which the celiac trunk gives the splenic, the common hepatic and the left gastric branches [1].

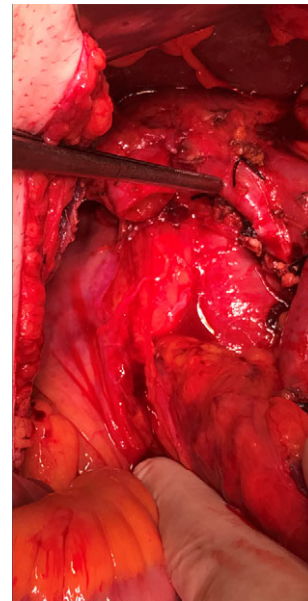


Figure 2: During procedure picture.

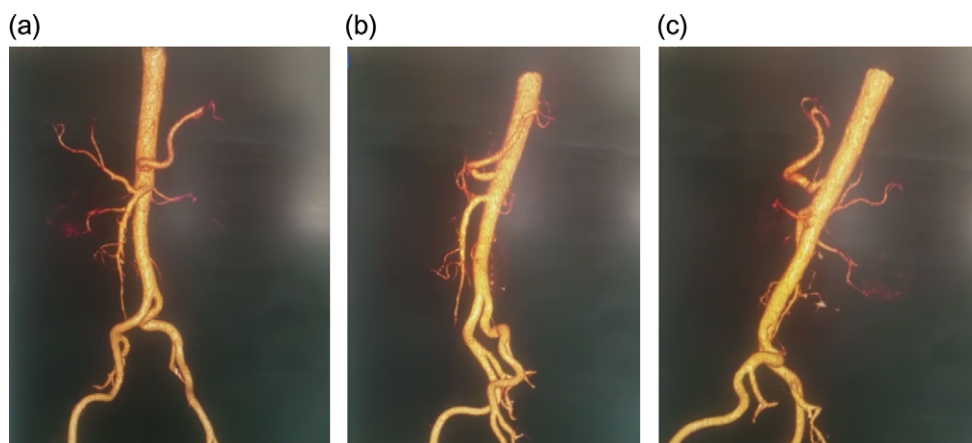


Figure 3: Angiographic CT after procedure.

As these anomalies are not rare, many has already studied and documented them and Michel's classification may be the most acceptable and used one in the surgery world these days [1].

'replaced' and 'accessory' hepatic artery anomaly were stressed up in Michel's classification due to its impact on liver transplant and pancreaticoduodenectomy surgeries [1].

Bifurcation of Celiac trunk, gastrosplenic trunk and hepatosplenic trunk are the most common anomalies whereas an absent celiac trunk is too rare and Bergman *et al.* have only reported it in his study as 0.4% [1].

In our case, there was no celiac trunk, no left gastric artery, the splenic artery emerged directly from the aorta and the common hepatic artery arising from Superior mesenteric artery. The surgical team completed the procedure despite this anomaly. The patient had a good recovery and a six-month follow up showed a person in acceptable health with no recurrence.

Zhou Ye *et al.* reported in 2017 a case of a patient who underwent pancreaticoduodenectomy and The CHA emerged from the superior mesenteric artery, the left gastric artery and splenic artery arising from the anterior wall of the abdominal 1 aorta [1].

CONCLUSION

Pancreaticoduodenectomy (PD) is one of the biggest and high complicated surgery. It still has high morbidity and mortality rates

variations of hepatic and celiac trunk are not rare and These variations may complicate the procedure more and could lead to serious complications. However, they are not considered contraindication and with good surgical experience the procedure may be done safely giving the patient his last choice to fight the disease.

CONFLICT OF INTEREST STATEMENT

None declared.

REFERENCES

1. Ye Z, Ye S, Zhou D, Zheng S, Wang W. A rare variation of celiac trunk and hepatic artery complicating pancreaticoduodenectomy: a case report and literature review. *Medicine (Baltimore)* 2017;**96**:e8969 <http://www.ncbi.nlm.nih.gov/pubmed/29310402> [cited 2018 Nov 29].
2. Tagkalos E, Jungmann F, Lang H, Heinrich S. One visceral artery may be enough; successful pancreatectomy in a patient with total occlusion of the celiac and superior mesenteric arteries. *BMC Surg* 2018;**18**:26 <http://www.ncbi.nlm.nih.gov/pubmed/29769055> [cited 2018 Nov 29].
3. Ahmad B, Turkmani K, Marwa ME, Ahmad T, Baghdadi R, Aboudamaah S, *et al.* Perioperative liver function after hepatectomy in a tertiary university hospital in damascus. *Asian Pacific Organ Cancer Prev* 2017;**18**:2109–13. http://journal.waocp.org/article_49489.html [cited 2017 Aug 26].