

Increased Rates of Descemet's Stripping Automated Endothelial Keratoplasty (DSAEK) Graft Failure and Dislocation in Glaucomatous Eyes with Aqueous Shunts

Francis Char DeCroos^{1,2}, MD; Derek W DelMonte², MD; Jessica H Chow², MD
Sandra S Stinnett², DrPH; Terry Kim², MD; Alan N Carlson², MD; Natalie A Afshari², MD, FACS

¹Wills Eye Institute/Mid Atlantic Retina, Philadelphia, PA, USA

²Duke University Eye Center, Durham, NC, USA

Purpose: To investigate the rates of Descemet's stripping automated endothelial keratoplasty (DSAEK) graft dislocation and failure in glaucomatous eyes, including eyes with history of trabeculectomy and/or aqueous shunts.

Methods: A retrospective, case-control study on a total of 424 consecutive eyes undergoing DSAEK at an academic setting compared 96 glaucomatous eyes to a control group of 328 eyes. Pre- and post DSAEK procedure data was aggregated for up to 2 years (mean follow-up, 6.5±6.9 months) including rates of graft dislocation and failure.

Results: Out of 96 glaucomatous eyes, 20 had undergone trabeculectomy, 27 had received one or more aqueous shunts, 12 had undergone both procedures and 37 were on medical therapy. Complete DSAEK graft dislocation and failure occurred in 2.7% and 3% of non-glaucomatous patients, respectively. Eyes with history of aqueous shunt surgery experienced graft dislocation and failure rates of 26.0% (OR=4.6, 95% CI 1.5-13.7, p=0.0067) and 26.0% (OR=10.3, 95% CI 3.8-27.1, p<0.0001), respectively. In contrast, glaucomatous eyes only on medical therapy (p=0.13) or with history of trabeculectomy (p>0.40) had no significant increase in graft dislocation or failure rates.

Conclusion: Eyes with medically controlled glaucoma or prior trabeculectomy demonstrated comparable rates of graft dislocation and failure as compared to controls. Aqueous shunt surgery was associated with increased rates of graft dislocation and failure after DSAEK.

Keywords: Glaucoma; Descemet's Stripping Endothelial Keratoplasty; Descemet's Stripping Automated Endothelial Keratoplasty; Aqueous Shunt; Graft Failure; Graft Dislocation

J Ophthalmic Vis Res 2012; 7 (3): 203-213.

Correspondence to: Natalie A Afshari, MD, FACS. Professor of Ophthalmology, Duke University Eye Center, Duke University Medical Center, Box 3802, Durham, NC 27710, USA; Tel: 001-919-684-3799; e-mail: afsha003@mc.duke.edu

Received: May 2, 2012

Accepted: June 5, 2012

INTRODUCTION

Descemet's stripping automated endothelial keratoplasty (DSAEK) is a welcome addition to the cornea surgeons' armamentarium for

a variety of corneal endothelial pathologies.¹ When compared to penetrating keratoplasty (PK), DSAEK offers many advantages. This procedure promotes faster visual recovery, more predictable refractive outcomes, and decreased

post-operative maintenance. This procedure offers preservation of corneal integrity, fewer suture related complications, and decreased risk of suprachoroidal hemorrhage.^{2,3}

As DSAEK gains widespread acceptance, it is being more frequently performed in eyes with a prior diagnosis of glaucoma. Glaucomatous eyes present a challenge for cornea surgeons for a variety of reasons aside from increased intraocular pressure (IOP). Compared to non-glaucomatous eyes, these eyes have increased rates of narrow angles, shallow anterior chambers (ACs), or peripheral anterior synechiae (PAS).^{4,5} These anterior chamber alterations may result in increased difficulty in graft placement leading to a higher rate of complications. Similarly, some glaucomatous eyes have undergone incisional surgery such as trabeculectomy or aqueous shunt procedures. This alternate outflow pathway from glaucoma surgery may cause difficulty in obtaining optimal anterior chamber air filling.⁶ Additionally, in the presence of one or more indwelling tube shunts, intracameral graft manipulation becomes more difficult (Fig. 1). Such complex anterior segments require more intraoperative manipulation, possibly leading to endothelial cell loss and subsequently decreased graft viability.

No consensus exists on whether glaucomatous eyes that have undergone filtration or aqueous shunt surgery are at higher risk of complications following DSAEK surgery. Several groups have reported that DSAEK can be efficacious in eyes with indwelling glaucoma tubes or prior trabeculectomy and that these conditions do not increase the rate of complications.⁷⁻¹¹ In contrast,

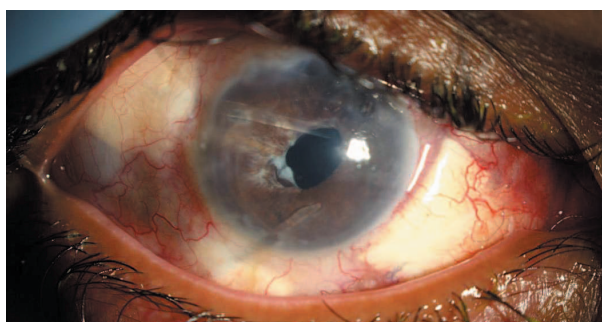


Figure 1. Descemet's stripping automated endothelial keratoplasty (DSAEK) performed in a glaucomatous eye with three prior indwelling aqueous shunts.

Price and coworkers noted that eyes with history of incisional glaucoma surgery demonstrate dramatically reduced 5-year graft survival rates after DSAEK as compared to eyes with no history of glaucoma surgery.¹²

Our series examines the correlation between a pre-existing diagnosis of glaucoma and graft complication rates after DSAEK by comparing a large number of glaucomatous eyes to non-glaucomatous controls. In particular, glaucomatous eyes with history of trabeculectomy and/or aqueous shunts were scrutinized for increased rates of graft dislocation and early failure.

METHODS

Patients

This retrospective, case-control study included 424 consecutive DSAEK cases in an academic setting. This study was approved by the Duke University Institutional Review Board (IRB), complied with the Health Insurance Portability and Accountability Act (HIPAA), and adhered to the Declaration of Helsinki. Overall, 96 glaucomatous eyes undergoing DSAEK were compared to a control group of 328 eyes with no prior history of glaucoma.

This study only included initial DSAEK procedure in any individual eye. Specifically, eyes with DSAEK graft failures or dislocations were included only once in calculating the rate of a particular complication. Prior studies have demonstrated that PK graft failure is a significant risk factor for secondary failure in DSAEK grafts¹³, therefore eyes with history of prior graft failure were excluded from the study. Eyes with retinal pathology or amblyopia were not excluded from the study.

Preoperative Evaluation

Prior to surgery, all patients received a detailed evaluation including determination of best corrected visual acuity (BCVA) with a Snellen chart, refraction, IOP measurement using a Goldmann applanation tonometer (AT 900, Haag-Streit, Manson, OH, USA) or the Tono-pen

XL or Avia (Richert, Depew, NY, USA), corneal pachymetry and slit lamp biomicroscopy.

Surgical Technique

The DSAEK surgical technique employed in the current series was similar to previously published descriptions.¹⁴⁻¹⁷ Briefly, donor grafts were obtained from Ocular Systems Incorporated (Winston-Salem, NC, USA) and mechanically pre-cut with a microkeratome. The pre-cut donor graft was trephined to the desired diameter and separated using forceps prior to placement in the host eye.

A 2.5 mm, beveled, clear corneal incision was created in the host eye. The host endothelium was scored, detached, and extracted from the eye. The wound was enlarged to the sides and the donor graft was folded with the endothelial side inward and gently inserted into the eye using single point insertion forceps. Air was then injected into the anterior chamber causing the graft to unfold and the donor endothelium to abut the host corneal stroma. 100% air fill was maintained for 8 to 60 minutes at the discretion of the surgeon followed by adjustment of IOP to a physiologic range.

Postoperative Care

Patients were re-evaluated postoperatively after one hour of supine positioning to ensure optimal graft placement. All eyes were treated for one week with topical fluoroquinolone (Vigamox, Alcon, Fort Worth, TX, USA) drops in addition to a one month course of 1% prednisolone acetate (Allergan, Irvine, CA, USA) four times daily. After one month, the prednisolone was tapered over the next few months to once daily. Steroid induced hypertension in some patients necessitated substitution of prednisolone acetate with fluorometholone (Allergan, Irvine, CA, USA) or loteprednol etabonate (Bausch & Lomb, Rochester, NY, USA). Eyes with inappropriate IOP levels from either pre-existing glaucoma or steroid induced IOP elevation were treated with topical glaucoma medications.

During the postoperative period, BCVA, IOP, slit lamp examination and posterior segment findings were recorded. Graft dislocation was

defined as 90% or more separation of the donor graft from the host corneal stromal bed requiring surgical reattachment. Graft failure was defined as a cornea opaque enough to obscure vision for at least 3 consecutive months or necessitating a repeat procedure (DSAEK or PK). Graft endothelial rejection was defined as the presence of keratic precipitates on the graft endothelium with or without graft edema.

Glaucoma Terminology

Patients with a prior diagnosis of glaucoma by a fellowship-trained glaucoma specialist were included in a subgroup to compare the outcomes of the study with a control group of non-glaucomatous eyes. No eyes in the control group had undergone filtration or glaucoma tube shunt surgery. Two eyes with untreated ocular hypertension (pre-operative IOP >24 mmHg) and no diagnosis of glaucoma were excluded from the study. Patients with a diagnosis of ocular hypertension (IOP ≤24 mmHg) receiving topical therapy were included in the control group. Formal evaluation of the optic nerve head, visual field testing, and quantification of the cup to disc ratio was not available for every eye in the control group. Glaucoma surgery was broken down into two subgroups; trabeculectomy and aqueous shunt procedures. Eyes that had only received laser procedures, such as selective laser trabeculoplasty (SLT) or peripheral iridotomy (PI) were not included in the glaucoma surgery subgroup.

Statistical Analysis

Analysis was performed using the SAS software version 9.1 (SAS Inc., Cary, NC, USA). Prior to analysis, BCVA based on Snellen acuity was converted to logarithm of minimum angle of resolution (logMAR) to facilitate statistical analysis. Univariate analysis of dichotomous data was performed using Fisher's exact test and analysis of continuous data was employed using Wilcoxon rank sum test of difference in medians. Two sided P-values less than 0.05 were considered as significant.

Any dichotomous associations reaching

significance ($P < 0.05$) in the univariate model underwent multiple logistic regression analysis. Employed covariates included aqueous shunts and abnormal ACs. Abnormal AC was defined as a dichotomous variable in the presence of any of the following: presence of an AC intraocular lens (ACIOL), shallow AC, narrow angle, or PAS. These were not analyzed as individual covariates to avoid overfitting the model.¹⁸ Glaucoma status was excluded as a covariate due to multicollinearity with both aqueous shunts and abnormal AC. Assumptions for logistic regression were met. The profile likelihood ratio method was used with a two-tailed P-value of 0.05. Interaction and goodness-of-fit diagnostics were also run. No cases with missing data were noted.

RESULTS

Non-glaucomatous Eyes

Of 328 DSAEK procedures conducted in

non-glaucomatous control eyes, 50.3% were performed on right eyes and 49.7% on left eyes. Mean age of this subgroup was 69.2 ± 11.3 years which included 114 men (34.8%) and 214 women (65.2%). Indications for surgery consisted of Fuchs dystrophy in 273 eyes (83.2%), pseudophakic bullous keratopathy in 34 eyes (10.3%), aphakic bullous keratopathy in 4 eyes (1.2%), failed PK in 15 eyes (4.6%), and other diagnoses in 6 eyes (1.8%); eyes were given more than one indication if appropriate.

Prior to surgery, 144 eyes (43.9%) were noted to be phakic, 166 (50.6%) had posterior chamber IOLs (PCIOLs), 5 (1.5%) had sulcus IOLs, 5 (1.5%) had ACIOLs, and 8 (2.4%) were aphakic. No eye in the control group had undergone prior trabeculectomy or aqueous shunt procedures, however, 4 eyes (1.2%) demonstrated shallow ACs/narrow angles, 7 (1.2%) exhibited PAS, and 1 (0.30%) eye had both PAS and shallow AC/narrow angles. The control population received an average of 0.02 glaucoma medications per

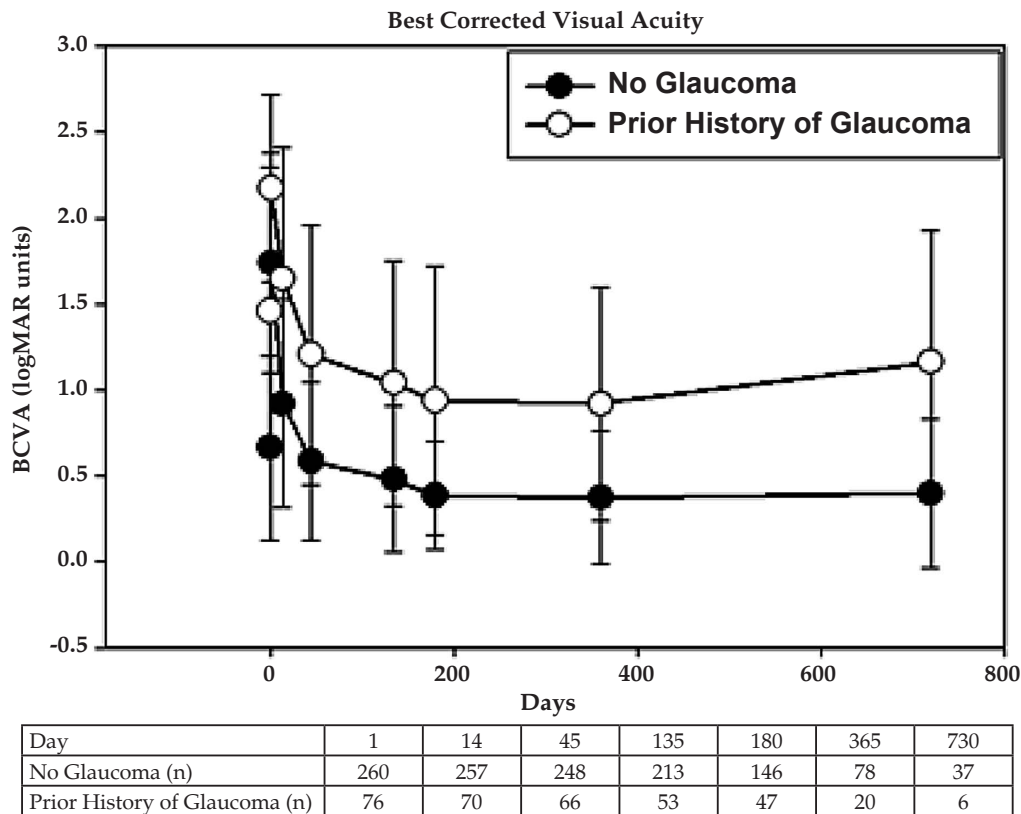


Figure 2. Best corrected visual acuity (BCVA) in eyes undergoing Descemet’s stripping automated endothelial keratoplasty (DSAEK). Significant differences ($P < 0.05$) were observed between the study groups at all time points. P-value based on Wilcoxon rank sum test of difference in medians.

eye preoperatively due to the presence of 5 eyes with ocular hypertension but no evidence of glaucoma.

Pre-operatively, corneal thickness in control eyes averaged 661 ± 68 micrometers. Mean donor age was 51.3 ± 16.5 years, and mean donor endothelial cell count was $3,058 \pm 337$ cells/square millimeters. Donor corneas were noted to have mean thickness of 492 ± 44 micrometers, and mean graft thickness harvested from these corneas was 126 ± 26 micrometers. Mean graft trephine diameter was 8.3 ± 0.4 millimeters. Prior to surgery, mean BCVA was 0.66 ± 0.54 logMAR (Snellen equivalent 20/91) and mean IOP was 14.9 ± 3.7 mmHg (Figures 2 and 3). A "DSAEK-triple" procedure (DSAEK, phacoemulsification and IOL implantation) was performed in 131 eyes (40%), while solitary DSAEK was performed in 197 eyes (60%). Post-DSAEK BCVA and IOP are detailed in Figures 2 and 3, respectively.

Graft dislocation occurred in 9 eyes (2.7%) and graft failure developed in 10 eyes (3.0%) postoperatively in control eyes. Of the 10 failed grafts, 2 failed to clear after surgery and 1 failed after endothelial rejection. No individual eye experienced both dislocation and failure after DSAEK. Graft dislocation and failure occurred in 12.5% and 0%, respectively of control eyes with PAS. Control eyes with narrow angles or shallow AC developed graft dislocation and failure in 0% and 0%, respectively (Tables 1 and 2).

Glaucomatous Eyes

Of 96 DSAEK procedures conducted in eyes with a prior history of glaucoma, 52.7% were performed in right eyes and 47.3% in left eyes. Mean age of this subgroup was 70.8 ± 17.7 years which included 44 men (45.8%) and 52 women (54.2%). Indications for surgery consisted of Fuchs dystrophy in 33 eyes (34.4%),

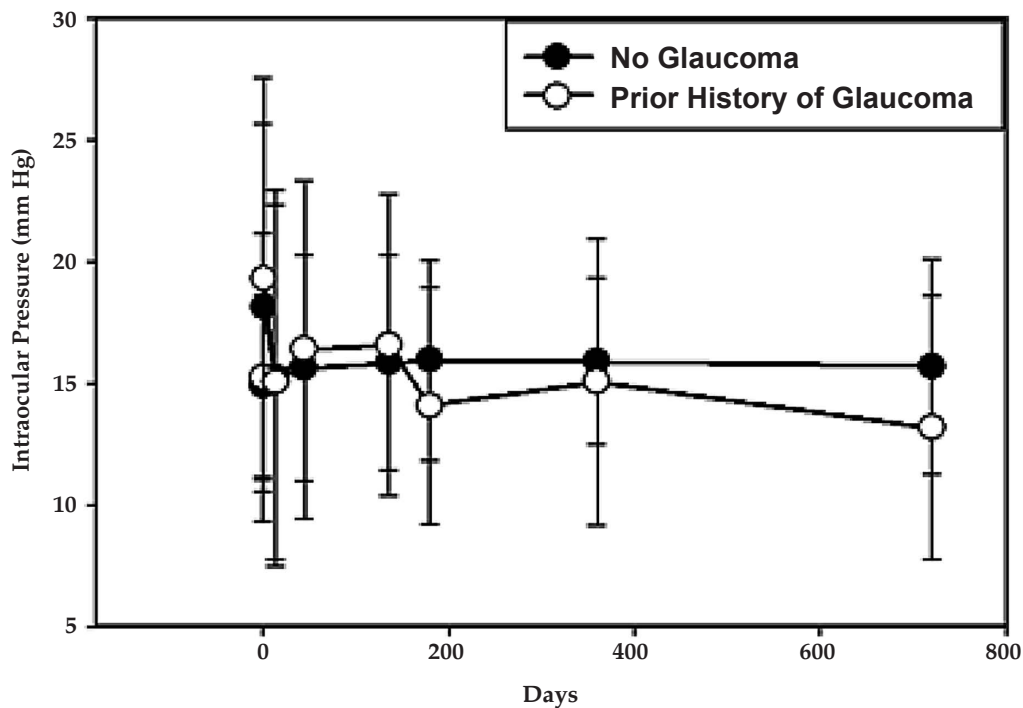


Figure 3. Intraocular pressure (IOP) in eyes undergoing Descemet’s stripping automated endothelial keratoplasty (DSAEK). Significant differences ($P < 0.05$) from baseline were observed only on day 1 in both groups and a significant difference was observed between the study groups only on day 180. P-value based on Wilcoxon rank sum test of difference in medians.

Table 1. Graft dislocation rates in eyes undergoing Descemet's stripping automated endothelial keratoplasty (DSAEK)

	Dislocation Rate	Odds Ratio	95% Confidence Interval	P-value
No prior history of glaucoma				
<i>All Eyes</i>	2.7%			
Anterior Segment Finding				
PAS	12.5%	5.1	0.56-45.6	0.22
Narrow angles/shallow AC	0%			
Lens Status				
ACIOL	40%	30.1	4.3-209.3	0.0064
Non-ACIOL	2.2%			
Prior history of glaucoma				
<i>All Glaucomatous Eyes</i>	10.4%	4.1	1.6-10.5	0.0034
Anterior Segment Finding				
PAS	26.3%	12.7	3.8-42.8	0.0004
Narrow angles/shallow AC	20%	8.9	2.5-31.9	0.0041
Lens Status				
ACIOL	33.3%	0.21	0.017-2.6	0.28
Non-ACIOL	9.7%			
Surgery				
None	2.7%	0.98	0.12-8.0	1
S/P any incisional glaucoma surgery	15.3%	6.4	2.5-16.4	0.00033
S/P trabeculectomy only	5.0%	1.9	0.22-15.5	0.45
S/P aqueous shunt only	26.0%	12.4	4.2-36.8	<0.0001
S/P aqueous shunt and trabeculectomy	8.3%	3.2	0.37-27.7	0.30
S/P multiple aqueous shunt (≥ 2 shunts)	30.0%	15.2	3.5-68.5	0.0035

PAS, peripheral anterior synechiae; AC, anterior chamber; S/P, status post; ACIOL, anterior chamber intraocular lens; Non-ACIOL, crystalline lens, posterior chamber IOL, sulcus IOL, or aphakic; P-value based on two-tailed Fisher Exact Test

Table 2. Graft failure rates in eyes undergoing Descemet's stripping automated endothelial keratoplasty (DSAEK)

	Failure Rate	Odds Ratio	95% Confidence Interval	P-value
No prior history of glaucoma				
<i>All Eyes</i>	3.0%			
Anterior Segment Finding				
PAS	0%			
Narrow angles/shallow AC	0%			
Lens Status				
ACIOL	20%	8.7	0.9-86.1	0.14
Non-ACIOL	2.8%			
Prior history of glaucoma				
<i>All Glaucomatous Eyes</i>	15.6%	5.9	2.6-13.6	<0.0001
Anterior Segment Finding				
PAS	15.8%	6.0	1.5-23.8	0.028
Narrow angles/shallow AC	20%	8.0	2.2-28.1	0.0055
Lens Status				
ACIOL	0%			
Non-ACIOL	16.1%			
Surgery				
No glaucoma surgery	8.1%	2.8	0.74-10.7	0.135
S/P any incisional glaucoma surgery	20.3%	6.9	3.0-16.0	<0.0001
S/P trabeculectomy only	5.0%	1.7	0.20-13.8	0.48
S/P aqueous shunt only	26.0%	11.1	3.8-32.3	<0.0001
S/P aqueous shunt and trabeculectomy	33.3%	15.9	4.1-61.7	0.00075
S/P multiple aqueous shunts (≥ 2 shunts)	20.0%	8.0	1.5-42.3	0.044

PAS, peripheral anterior synechiae; AC, Anterior Chamber; S/P, status post; ACIOL, anterior chamber intraocular lens; Non-ACIOL, crystalline lens, posterior chamber IOL, sulcus IOL, or aphakic; P-value based on two-tailed Fisher Exact Test

pseudophakic bullous keratopathy in 22 eyes (23.0%), aphakic bullous keratopathy in 3 eyes (3.1%), glaucomatous decompensation in 23 eyes (24.0%), failed PK in 12 eyes (12.5%), and other diagnoses in 8 eyes (8.3%). Eyes were given more than one indication if appropriate.

Prior to surgery, 13 eyes (13.5%) were noted to be phakic, 72 (75%) had PCIOLs, 1 (1.0%) had a sulcus IOLs, 3 (3.1%) had ACIOLs, and 7 (7.3%) were aphakic. Many eyes demonstrated complicated anterior segments, including 8 eyes (8.3%) with shallow AC or narrow angles, 7 (7.3%) with PAS, and 12 (12.5%) eyes exhibiting both PAS and shallow AC/narrow angles. The average number of glaucoma medications in glaucomatous eyes was 0.60 per eye preoperatively.

The majority of eyes (61.5%) in the glaucoma subgroup had undergone prior incisional surgery including 20 eyes (20.8%) with prior trabeculectomy, 27 eyes (28.1%) with one or more prior tube shunts, and 12 eyes (12.5%) with both types of procedures. Single tubes were noted in 27 eyes (28.1%), double tubes in 10 eyes (10.4%) and triple tubes in 2 eyes (2.1%) (Fig. 4).

Pre-operatively, corneal thickness in glaucomatous eyes averaged 702±124 micrometers. Mean donor age was 51.6±16.4 years, and mean donor endothelial cell density

was 3,034±390 cells/square millimeters. Donor corneas were noted to have mean thickness of 496±47 micrometers, and mean graft thickness harvested from these corneas was 127±24 micrometers. Mean graft trephine diameter was 8.0±0.6 millimeters. No statistically significant difference was noted between control and glaucomatous eyes in terms of donor endothelial cell count, donor corneal thickness, or graft thickness. Prior to surgery, mean BCVA was 1.46±0.84 logMAR (Snellen equivalent 20/577) and mean IOP was 15.2±5.9 mmHg (Figures 2 and 3). A “DSAEK-triple” procedure (DSAEK, phacoemulsification, and IOL implantation) was performed in 13 (13.5%) cases, while solitary DSAEK was performed in 83 eyes (86.5%). Post-DSAEK BCVA and IOP are detailed in Figures 2 and 3, respectively for eyes with a pre-existing diagnosis of glaucoma. Significant differences were noted in visual acuity between controls and glaucomatous eyes at all time points (P<0.05). Significant differences in IOP between the control and glaucoma subgroups were noted only at 6 months (P<0.05).

Graft dislocation was noted in 10 (10.4%) and graft failure was noted in 15 (15.6%) glaucomatous eyes. Of the 15 failed grafts, 4 failed to clear after surgery and 2 failed after endothelial rejection. No significant difference in endothelial rejection rates was noted between glaucomatous and non-glaucomatous eyes (P=0.13). No individual eye experienced both dislocation and failure after DSAEK. In glaucomatous eyes with no prior history of glaucoma surgery, the rate of dislocation was 2.7% and the rate of failure was 8.1%. In comparison, glaucomatous eyes with history of prior trabeculectomy experienced graft dislocation and failure rates of 5.0% and 5.0%, respectively. Glaucomatous eyes with prior aqueous shunt procedures experienced graft dislocation and failure rates of 26.0% and 26.0% respectively. Glaucomatous eyes with two or more prior aqueous shunts experienced graft dislocation and failure rates of 30.0% and 20.0%, respectively. Eyes with glaucoma and PAS experienced graft dislocation and failure rates of 26.3% and 15.8%, respectively. Eyes with glaucoma and narrow angles or shallow ACs experienced graft dislocation and failure rates

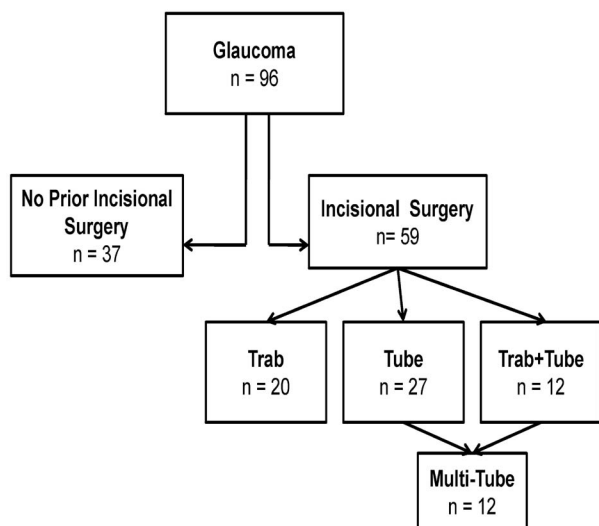


Figure 4. Schematic of glaucomatous subgroups undergoing Descemet’s stripping automated endothelial keratoplasty (DSAEK). Trab, trabeculectomy; Tube, aqueous tube shunt

20.0% and 20.0% respectively (Table 1 and 2).

Adjusted analysis controlling for abnormal AC (ACIOL, shallow AC, narrow angle, or PAS) also found the likelihood of graft dislocation (OR=4.6, 95% CI, 1.5-13.7, P=0.0067) and failure (OR=10.3, 95% CI, 3.8-27.1, P<0.0001) to be significantly associated with prior aqueous shunt surgery. For graft dislocation the overall model was statistically significant (P<0.0001), with evidence of borderline interaction between abnormal AC and aqueous shunts (P=0.037). The Hosmer-Lemeshow test of goodness-of-fit was satisfied and the c statistic was 0.776. For graft failure the overall model was statistically significant (P<0.0001), with no evidence of interaction between abnormal AC and aqueous shunts (P=1.00). The Hosmer-Lemeshow test of goodness-of-fit was satisfied and the c statistic was 0.684.

Adjusted analysis controlling for surgical indication (Fuchs dystrophy versus all other indications) similarly found the likelihood of graft dislocation (OR=5.0, 95% CI, 1.6-16.3, P=0.0063) and failure (OR=15.3, 95% CI, 4.7-56.5, P<0.0001) to be significantly associated with prior aqueous shunt surgery. For graft dislocation the overall model was statistically significant (P<0.0001), with no evidence of interaction between abnormal AC and aqueous shunt (P=0.41). The Hosmer-Lemeshow test of goodness-of-fit was satisfied and the c statistic was 0.737. For graft failure the overall model was statistically significant (P<0.0001), with no evidence of interaction between abnormal AC and aqueous shunt (P=0.24). The Hosmer-Lemeshow test of goodness-of-fit was satisfied and the c statistic was 0.724.

DISCUSSION

The most frequent complications of DSAEK are graft dislocation and failure, however reported rates of dislocation (mean, 14%; range, 0-82%) and failure (mean, 5%; range, 0-29%) vary widely across 34 articles reviewed in a recent meta-analysis.³ Our work examines graft dislocation and failure in a large population of glaucomatous eyes undergoing DSAEK. In particular, this study examined subpopulations

of glaucomatous eyes and identified that prior aqueous shunt surgery is strongly associated with increased graft dislocation and increased early failure rates.

Although the relationship between a prior diagnosis of glaucoma and complications after DSAEK has not been rigorously defined, it is well established that prior glaucoma surgery increases the risk of graft failure in eyes undergoing PK.^{13,19-21} In a retrospective study, a three-year graft failure rate of 59.1% was noted after PK in eyes with an indwelling Ahmed glaucoma valve.²² Similarly, the Cornea Donor Study analyzed subpopulations of eyes with a prior diagnosis of glaucoma undergoing PK. Eyes with history of prior glaucoma surgery demonstrated a 58% graft failure rate after five years, as compared to the 20% and 11% failure rates noted in glaucomatous eyes without prior surgery and non-glaucomatous eyes, respectively.²⁰ The shorter follow-up duration of the present study (mean=6.5 months) compared to the five year follow-up in the Cornea Donor Study prevents direct comparison, but suggests that higher rates of DSAEK graft failure would likely be observed with longer follow-up.

Supporting this assertion is the work by Price and coworkers who reported that 5 eyes with prior glaucoma surgery demonstrated a 40% five-year graft survival rate after DSAEK, compared to the 95% survival rate observed in non-glaucomatous eyes.¹² Our study demonstrated an elevated rate of DSAEK graft failure in glaucomatous eyes with history of aqueous shunt surgery, we did not note a significant increase in graft failure rates in eyes with history of trabeculectomy alone. Medically managed glaucomatous eyes in our series demonstrated comparable rates of failure to non-glaucomatous eyes, consistent with the results of Price and colleagues.¹²

Structural changes common to glaucomatous eyes advanced enough to require shunt surgery may contribute to this increased risk of graft failure. These eyes have an increased incidence of PAS, narrow angles, and shallow ACs.^{4,5} This altered anterior chamber anatomy that places the donor endothelium in closer proximity to blood vessels may subsequently increase rejection

risk. This mechanism has been implicated in the increased rates of PK failures in eyes with PAS.^{19,23,24} However, in the present study and another¹⁰, no significant increase in DSAEK graft rejection rates was noted in eyes with prior glaucoma surgery.

Eyes with shallow ACs may also experience direct trauma to the corneal endothelium from abnormal tissue proximity and subsequently increased graft complication rates. In a study on eyes undergoing trabeculectomy alone, the subgroup with postoperative shallow chambers demonstrated significant loss of endothelial cells, while no significant loss was noted in eyes that maintained normal chamber depth.²⁵ However, even after controlling for the effect of abnormal ACs with multivariate analysis, we observed significant increases in graft failure and dislocation rates in eyes with aqueous shunts.

This increased complication rate may be because indwelling glaucoma shunts can increase difficulty in obtaining optimal graft placement. Greater intraoperative graft manipulation may lead to excessive loss of endothelial cells. One prospective study has shown that DSAEK results in significantly increased endothelial cell loss compared to PK, and more graft manipulation likely worsens this tendency.¹² Finally, the glaucoma shunt may directly damage endothelial cells by constantly or intermittently chafing donor tissue, eventually inciting graft failure.

We observed an increased incidence of graft dislocation in glaucomatous eyes with a history of aqueous shunt surgery. In glaucomatous eyes with no history of incisional surgery or trabeculectomy only, dislocation rates were similar to control eyes. In contrast, eyes with aqueous shunt surgery demonstrated increased graft dislocation. Glaucoma shunt surgery often prevents complete anterior chamber air fill, as the air can egress into the subconjunctival space. This inability to obtain a complete air fill may prevent optimal adhesion of the graft until the endothelial pumps are fully active. Although the mechanism of DSAEK graft adhesion is not completely understood, it is thought that water causes stromal proteoglycans to uncoil and hook, acting as a sort of biochemical glue independent of any endothelial pump.²⁶

Increased graft manipulation and suboptimal intracameral air fill may weaken this attachment. Importantly, increased graft dislocation may also contribute to graft failure. One group investigating histopathologic findings in failed DSAEK grafts reports 88% of failed grafts had undergone detachment prior to failure.²⁷ In the present study, no eyes experienced both dislocation and failure; this disparity may be due to population differences between the two series. Eventually with longer follow-up we may also observe an increased graft failure rate in eyes that had experienced prior graft dislocation.

Our series is comparable to another study in which 52 glaucomatous eyes underwent DSAEK after trabeculectomy or tube shunt surgery and were followed for a mean of 12 months postoperatively.¹⁰ During this interval, Wiaux and coworkers observed no significant difference in rates of dislocation between eyes with surgically treated glaucoma (12.5%) and eyes without glaucoma surgery (15.2%). Similarly no difference in graft failure rate was observed between eyes with surgically treated glaucoma (12.5%) and eyes without glaucoma surgery (5.9%). It is important to note that the series by Wiaux and colleagues aggregated aqueous shunts and trabeculectomy cases into a single category for analysis. This is especially salient in light of our finding that trabeculectomy alone did not increase the rate of graft complications. The present study further differed in that it included eyes that had undergone multiple glaucoma surgeries, had multiple indwelling tubes, and DSAEK graft insertion was performed through a 2.5 mm incision. In particular, compared to the conventional 5 mm incision utilized by Wiaux *et al* and others, the utilization of a 2.5 mm incision may have resulted in greater endothelial cell loss and subsequently increased graft complications in our series.²⁸

Since the present study examined consecutive cases, indications for DSAEK were not similar between control and glaucomatous eyes. In control eyes for example, Fuchs dystrophy was the indication in 83% of cases as compared to 34% in glaucomatous eyes. Because of this disparity, multivariate logistic regression analysis was performed to control

for differences in preoperative diagnoses. This analysis clearly demonstrated increased rates of graft failure and dislocation associated with a prior aqueous shunt surgery.

To minimize graft complication rates in eyes with prior aqueous shunts it may be reasonable to perform DSAEK through a standard 5 mm incision to minimize endothelial cell loss, optimize anterior chamber air fill at surgery, avoid subsequent air removal, minimize graft manipulation, and trim shunts of excessive length prior to graft placement.^{7,10,11,28}

Our data must be interpreted in the context of several limitations. This work is a retrospective, case-control study. The retrospective nature of this study precludes detailed analysis of glaucoma history. Visual field testing, optic nerve analysis and glaucoma stratification would have allowed us to better understand correlations between specific glaucoma subtypes and increased rates of complications. Next, the population of glaucomatous eyes included in this series were derived from a tertiary eye care academic center and likely do not reflect the severity of glaucoma among the general population. This matter is supported by the fact that 20.3% of glaucomatous eyes had undergone multiple operations and 17.0% of cases had more than one indwelling aqueous shunts. Another indicator of the severity of glaucoma in this study sample is the disparity in both pre- and postoperative BCVA between glaucomatous and control eyes which may be in part due to advanced glaucomatous optic neuropathy. Finally, less than 30 instances of either graft failure or dislocation were noted in this review of over 400 cases. To avoid over fitting the regression model and generating unreliable odds ratios, additional clinical factors such as communication between the anterior and posterior segments that may contribute to graft dislocation or failure could not be included in the final model.^{18,29} Despite these limitations, the current series remains one of the largest to investigate the relationship between prior aqueous shunt surgery and DSAEK graft complications.

DSAEK is currently the procedure of choice for endothelial dysfunction and will be performed in more glaucomatous eyes in the future. Prior

aqueous shunt surgery seems to be associated with dramatically higher graft dislocation and failure rates. When performing DSAEK in eyes with an aqueous shunt, the increased rate of complications should prompt meticulous intraoperative and postoperative vigilance, as well as appropriate patient counselling.

Conflicts of Interest

None.

REFERENCES

1. Price MO, Price FW. Descemet's stripping endothelial keratoplasty. *Curr Opin Ophthalmol* 2007;18:290-294.
2. Suh LH, Yoo SH, Deobhakta A, Donaldson KE, Alfonso EC, Culbertson WW, et al. Complications of Descemet's stripping with automated endothelial keratoplasty: survey of 118 eyes at One Institute. *Ophthalmology* 2008;115:1517-1524.
3. Lee WB, Jacobs DS, Musch DC, Kaufman SC, Reinhart WJ, Shtein RM. Descemet's stripping endothelial keratoplasty: safety and outcomes: a report by the American Academy of Ophthalmology. *Ophthalmology* 2009;116:1818-1830.
4. Bonomi L, Marchini G, Marraffa M, Bernardi P, De Franco I, Perfetti S, et al. Epidemiology of angle-closure glaucoma: prevalence, clinical types, and association with peripheral anterior chamber depth in the Egna-Neumarkt Glaucoma Study. *Ophthalmology* 2000;107:998-1003.
5. Lee JY, Kim YY, Jung HR. Distribution and characteristics of peripheral anterior synechia in primary angle-closure glaucoma. *Korean J Ophthalmol* 2006;20:104-108.
6. Ide T, Yoo SH, Leng T, O'Brien TP. Subconjunctival air leakage after Descemet's stripping automated endothelial keratoplasty (DSAEK) in a post-trabeculectomy eye. *Open Ophthalmol J* 2009;3:1-2.
7. Riaz KM, Sugar J, Tu EY, Edward DP, Wilensky JT, Namavari A, et al. Early Results of Descemet-Stripping and automated endothelial keratoplasty (DSAEK) in patients with glaucoma drainage devices. *Cornea* 2009;28:959-962.
8. Duarte MC, Herndon LW, Gupta PK, Afshari NA. DSEK in eyes with double glaucoma tubes. *Ophthalmology* 2008;115:1435.
9. Esquenazi S, Rand W. Safety of DSAEK in patients with previous glaucoma filtering surgery. *J*

- Glaucoma* 2010;19:219-220.
10. Wiaux C, Baghdasaryan E, Lee OL, Bourges JL, Deng SX, Yu F, et al. Outcomes after Descemet stripping endothelial keratoplasty in glaucoma patients with previous trabeculectomy and tube shunt implantation. *Cornea* 2011;30:1304-1311.
 11. Phillips PM, Terry MA, Shamie N, Chen ES, Hoar K, Dhoot D, et al. Descemet stripping automated endothelial keratoplasty in eyes with previous trabeculectomy and tube shunt procedures: intraoperative and early postoperative complications. *Cornea* 2010;29:534-540.
 12. Price MO, Gorovoy M, Benetz BA, Price FW Jr, Menegay HJ, Debanne SM, et al. Descemet's stripping automated endothelial keratoplasty outcomes compared with penetrating keratoplasty from the Cornea Donor Study. *Ophthalmology* 2010;117:438-444.
 13. Price FW Jr, Whitson WE, Johns S, Gonzales JS. Risk factors for corneal graft failure. *J Refract Surg* 1996;12:134-143 discussion 143-147.
 14. Gorovoy MS. Descemet-stripping automated endothelial keratoplasty. *Cornea* 2006;25:886-889.
 15. Price FW Jr, Price MO. Descemet's stripping with endothelial keratoplasty in 50 eyes: a refractive neutral corneal transplant. *J Refract Surg* 2005;21:339-345.
 16. Price FW Jr, Price MO. Descemet's stripping with endothelial keratoplasty in 200 eyes: early challenges and techniques to enhance donor adherence. *J Cataract Refract Surg* 2006;32:411-418.
 17. Terry MA, Shamie N, Chen ES, Hoar KL, Friend DJ. Endothelial keratoplasty a simplified technique to minimize graft dislocation, iatrogenic graft failure, and pupillary block. *Ophthalmology* 2008;115:1179-1186.
 18. Moss M, Wellman DA, Cotsonis GA. An appraisal of multivariable logistic models in the pulmonary and critical care literature. *Chest* 2003;123:923-928.
 19. Price MO, Thompson RW Jr, Price FW Jr. Risk factors for various causes of failure in initial corneal grafts. *Arch Ophthalmol* 2003;121:1087-1092.
 20. Sugar A, Tanner JP, Dontchev M, Tennant B, Schultze RL, Dunn SP, et al. Recipient risk factors for graft failure in the cornea donor study. *Ophthalmology* 2009;116:1023-1028.
 21. Reinhard T, Kallmann C, Cepin A, Godehardt E, Sundmacher R. The influence of glaucoma history on graft survival after penetrating keratoplasty. *Graefes Arch Clin Exp Ophthalmol* 1997;235:553-557.
 22. Hollander DA, Giacconi JA, Holland GN, Yu F, Caprioli J, Aldave AJ, et al. Graft failure after penetrating keratoplasty in eyes with Ahmed valves. *Am J Ophthalmol* 2010;150:169-178.
 23. Sit M, Weisbrod DJ, Naor J, Slomovic AR. Corneal graft outcome study. *Cornea* 2001;20:129-133.
 24. Maguire MG, Stark WJ, Gottsch JD, Stulting RD, Sugar A, Fink NE, et al. Risk factors for corneal graft failure and rejection in the collaborative corneal transplantation studies. Collaborative Corneal Transplantation Studies Research Group. *Ophthalmology* 1994;101:1536-1547.
 25. Fiore PM, Richter CU, Arzeno G, Arrigg CA, Shingleton BJ, Bellows AR, et al. The effect of anterior chamber depth on endothelial cell count after filtration surgery. *Arch Ophthalmol* 1989;107:1609-1611.
 26. Slack JW, Kangas TA, Edelhauser HF, Geroski DH, McDermott ML. Comparison of corneal preservation media for corneal hydration and stromal proteoglycan loss. *Cornea* 1992;11:204-210.
 27. Oster SF, Ebrahimi KB, Eberhart CG, Schein OD, Stark WJ, Jun AS. A clinicopathologic series of primary graft failure after Descemet's stripping and automated endothelial keratoplasty. *Ophthalmology* 2009;116:609-614.
 28. Terry MA, Saad HA, Shamie N, Chen ES, Phillips PM, Friend DJ, et al. Endothelial keratoplasty: the influence of insertion techniques and incision size on donor endothelial survival. *Cornea* 2009;28:24-31.
 29. Afshari NA, Gorovoy MS, Yoo SH, Kim T, Carlson AN, Rosenwasser GO, et al. Dislocation of the donor graft to the posterior segment in Descemet stripping automated endothelial keratoplasty. *Am J Ophthalmol* 2012;153:638-642.