

Case Report

A Solitary Melanoma Metastasis Confined to the Submandibular Gland

Senne Gorris^a Celia Perdaens^b Veerle Delvaux^b
Vincent Vander Poorten^a Bart Neyns^c Ilan Baron^d

^aDepartment of Otorhinolaryngology Head and Neck Surgery, University Hospitals Leuven, KU Leuven, Leuven, Belgium; ^bDepartment of Anatomic pathology, AZ Jan Portaels, Vilvoorde, Belgium; ^cDepartment of Medical Oncology, University Hospital Brussel, Brussels, Belgium; ^dDepartment of Otorhinolaryngology Head and Neck Surgery, AZ Jan Portaels, Vilvoorde, Belgium

Keywords

Metastatic melanoma · Submandibular gland · Immunotherapy · Unknown primary · Case report

Abstract

Malignant melanoma is a type of cancer that most commonly originates from the skin, less frequently from mucosal surfaces, the eye, or meninges [*Annu Rev Pathol.* 2014;9(1):239–71]. In 2019, this type of malignancy was the third most frequent cancer to be diagnosed in males and the fifth most in females according to the American Cancer Society and the National Cancer Institute [*CA Cancer J Clin.* 2019;69(5):363–85]. The majority of the malignant melanomas in the head and neck region (85–90%) are cutaneous lesions, most often arising in the skin of the face [*Head Neck.* 2016;38:147–155]. In sharp contrast are the histological findings of metastatic melanoma with an unknown primary site: they are much more scarce and histologically difficult to diagnose. The literature is limited to case studies or small cohorts. In 2–6% of all patients suffering from metastatic melanoma, after clinical examination of the skin and mucosa, imaging, and other diagnostic examination, a primary tumor cannot be found [*Eur J Cancer.* 2004;40(9):1454–5]. A very small subgroup (0.5%) presents with a single focus of melanoma within the dermis or subcutaneous tissues [*Arch Dermatol.* 2000;136(11):1397–9]. We hereby report a case in this subgroup of a solitary melanoma metastasis found in the submandibular gland in a 59-year-old male. The tumor was discovered incidentally after surgical excision of this gland because of nodular enlargement.

© 2021 The Author(s).

Published by S. Karger AG, Basel

Introduction

Over the last decades, the incidence of melanoma has risen rapidly at an almost exponential pace. In 2019 melanoma was the third most common cancer in the USA for men and the fifth most common for women, only to be preceded by breast, prostate, colon, and uterine corpus cancer [1]. More than 95% are patients with cutaneous primaries where for the most part the treatment is curative after complete surgical resection. If resection is not possible or metastases have occurred, treatment is still possible, but the prognosis declines spectacularly even if it is treated. Melanoma is remarkably therapy resistant to various types of radio- and chemotherapy. Fortunately, during the past decade, efficient medical therapies have become available, including immune checkpoint inhibitors directed against PD-1 or CTLA-4 and combination of BRAF plus MEK-inhibitors (for BRAF V600mutant melanoma only).

The staging of melanoma is organized via the TNM system and divided into 5 stages [2]. It starts at stage 0 – melanoma in situ – which represents intraepithelial disease, up to stage III where regional nodal involvement is indicated, and ends in the last stage (stage IV) when distant metastatic spread is seen. The sites of initial metastases differ; 20% of metastasis involves the head and neck region [3]. Patients with a solitary melanoma are also classified as having stage IV disease by the current American Joint Committee on Cancer Classification [2] convention when there is histological confirmation of metastatic melanoma to skin, lymph node, or viscera.

The 5-year relative survival for patients diagnosed with melanoma is 92% [4]. This number is so high because the vast majority of melanomas are diagnosed in stage I, for which the 5-year relative survival approaches 100% [5]. According to the National Cancer Database [6], a total of 84,836 cases of cutaneous and noncutaneous melanoma were diagnosed between 1985 through 1994 in the USA. Of those cases, 91.2% were patients with stage I melanoma. On the other side, the 5-year survival for stage IV melanoma – metastasis beyond regional lymph nodes – was dismal before modern therapeutic options (9–19%) but has improved to over 40% [7, 8].

Moreover, these new medical therapies have also been demonstrated to improve the relapse-free survival rates following surgical removal of metastatic lymph nodes [9–11]. Although patients with a solitary melanoma metastasis would, according to the American Joint Committee on Cancer staging system, be classified as having stage IV melanoma with the corresponding dismal natural 5-year relative survival (9–19%), recent literature and clinical observation have shown much higher survival rates for patients with oligo-metastatic melanoma (Table 1).

Treatment of primary melanoma is done by surgery. Resection can result in high cure rates for patients with early- and intermediate-stage disease [18]. Macroscopic lymph node dissection remains the standard in patients with clinically detectable lymph node metastasis (stage III melanoma), although even extensive lymph node dissection does not increase survival. Careful follow-up has replaced elective CLND in patients found with microscopic melanoma metastases in the sentinel lymph node [19]. Patients with metastatic melanoma of unknown primary with a solitary distant skin, subcutaneous or nodal metastasis, and even isolated metastasis in adrenal glands, who were treated surgically, with or without an addition of systemic therapy, had a greater survival rate [20, 21].

Case Description

A 59-year-old male patient consulted an ENT – head and neck surgeon colleague for a snoring problem. After discovering an asymmetric swelling of the right submandibular region during the general clinical evaluation, he was referred to the radiology department for ultrasound of the region.

Table 1. Report on metastatic MUP or solitary metastasis

Article	Total patients	MUP	Solitary metastasis	Percentage solitary, %	Location H and N, %	5-year survival solitary, %
Bowen et al. [12]	1,800	–	11	0.61	27	83*
Schlagenhauff et al. [3]	3,258	75	30**	0.92	21	83
Schlagenhauff et al. [3]	3,258	75	37***	1.13	21	50
Giuliano et al. [13]	980	55	5	0.51	30.6	80
Anbari et al. [14]	40	40	3	7.5	17.5	100****
De Waal et al. [15]	33,181	857	106*****	0.32	–	35.3
Clerico et al. [16]	1,720	24	5	0.29	–	75
Savoia et al. [17]	4,881	93	27	0.55	9	–

The case we report concerns a solitary melanoma found inside the submandibular gland, and to our knowledge, such a case was not described earlier in the literature. Keeping this in mind the numbers for the solitary metastases in this table always come from categories where solitary parotid metastases or subcutaneous metastases are grouped, not solitary lymph nodes. MUP, melanoma of unknown primary.

*In this study, only an 8-year survival is known.

**Unknown primary with cutaneous or subcutaneous in-transit metastases.

***Unknown primary with lymph node metastasis.

****In this article, only a 4-year survival is known.

*****Subcutaneous melanoma metastases with unknown primary on one location.

Here, they concluded that there was a nodule within or against the submandibular gland that was radiologically distinct from the surrounding tissue. The nodule had a size of 1.7 cm, regular borders, and was homogeneously hyporefective. A fine-needle aspiration biopsy was performed. Histopathology showed a nonspecific lesion with signs of bleeding, possibly matching with a cyst.

MRI confirmed a nodular, mostly avascular, lesion within the right submandibular gland with low-density calcifications and diffusion restrictions. The lesion was T1 light hyperintense and T2 hypointense (in comparison with the muscles). The image was suggestive for a cystic nodule with a high protein content and calcifications. No extraglandular extension or locoregionally enlarged lymph nodes were noted.

After informing the patient, the therapeutic options were discussed, and he was sent to our department for removal of the submandibular gland. During the operation, there were no problems; the marginal branch of the facial nerve and both the lingual and hypoglossal nerve were preserved, the Wharton's duct was clipped as anteriorly as possible. The patient could leave the hospital 1 day later.

The gland was per direct fixed in a 4% formaldehyde solution (10% neutral buffered formalin). The anatomopathological report showed that on macroscopy, there was a black nodule of 2.5 cm within the submandibular gland. On microscopy, this intraglandular nodule was well circumscribed, partially surrounded by fibrous tissue and existed of epithelioid and spindle cells with prominent nucleoli and abundant brown pigment in the cytoplasm (shown in Fig. 1a).

The lesion extended focally into the parenchyma of the submandibular gland (shown in Fig. 1b). No lymphovascular invasion was seen. The resection margins showed no tumor. Part of the brown pigment was hemosiderin, shown by the Perls staining (shown in Fig. 1c). On the other hand, most of the cells showed a positive immunohistochemical staining with MelanA (shown in Fig. 1d), HMB-45 (shown in Fig. 1e), and S100, which is consistent with the diagnosis of a melanoma. An Idylla NRAS-BRAF mutation test (Biocartis) was performed and no NRAS or BRAF mutation were detected.

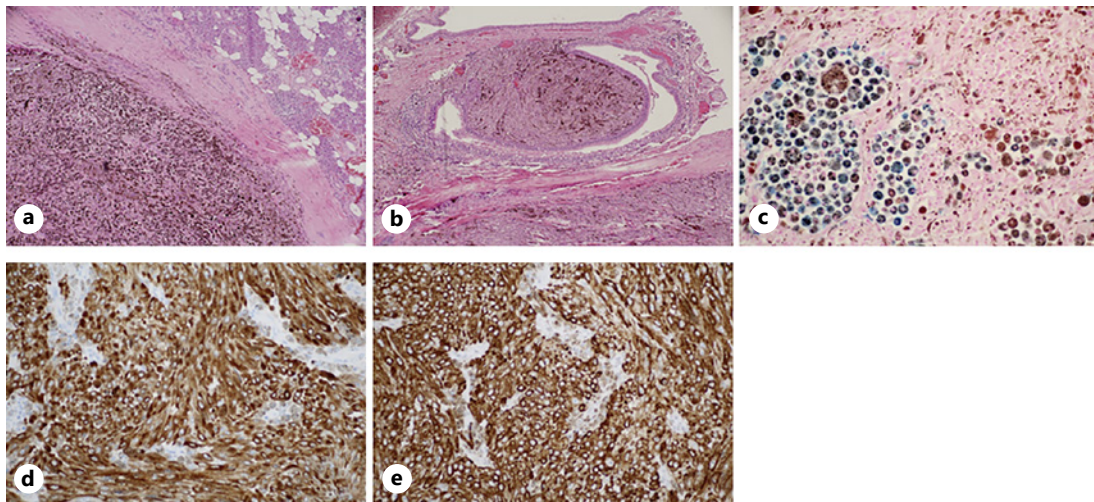


Fig. 1. **a** Intraglandular nodule well circumscribed, partially surrounded by fibrous tissue, and existed of epithelioid and spindle cells with prominent nucleoli and abundant brown pigment in the cytoplasm. **b** Lesion that extends focally into the parenchyma of the submandibular gland. **c** Hemosiderin on Perls staining. **d** Positive immunohistochemical staining with Melana. **e** Positive immunohistochemical staining with HMB-45.

Shortly after the discovery of this melanoma, a PET-CT showed no other lesions and a thorough examination by dermatology and ophthalmology was performed, with no evidence of a primary origin of the tumor. The case was discussed by the multidisciplinary tumor board, and the necessity of adjuvant therapy was discussed.

The final conclusion was that we were dealing with a solitary metastasis from an unknown primary melanoma, so the patient was considered stage IV-M1c. We therefore advised the patient to receive adjuvant immunotherapy. He was started on nivolumab 240 mg every 2 weeks [20]. If well tolerated, after 3 months the regime would have been changed to nivolumab 240 mg every 4 weeks. In the absence of serious side effects, this treatment would have been continued for 1 year. In March of 2020, the patient started with adjuvant nivolumab (anti-PD-1) for 5 cycles. The treatment had to be stopped at the end of May 2020 because of IR-colitis. At this moment, the patient is 12 months following the surgery with NED.

Discussion

Once the workup had resulted in the working hypothesis of “solitary metastasis from an unknown primary melanoma” a literature search for comparable case studies was performed. A very scarce subset of articles was found regarding a single focus of melanoma within the dermis or subcutaneous tissues. The salivary gland was certainly present in this subset, although it reported mainly about melanoma findings in the parotid gland. The case study presented here differs from this group: unlike the parotid, the normal submandibular gland does not show intraglandular lymph nodes [22, 23].

The fact that thorough clinical examination and imaging showed no evidence for a primary origin site has also been described as a possibility previously in the literature: in 2–6% of all patients suffering from metastatic melanoma, clinical examination of the skin and mucosa, imaging, and other diagnostic examination cannot reveal a primary tumor [24]. A very small subgroup (0.5%) presented with a single focus of melanoma within the dermis or subcutaneous tissues [12]. One case report describes a comparable patient to ours. In these

cases, the regression theory, that is, the primary tumor being eliminated by the immune system is often proposed. Regression is found in melanoma with a frequency that ranges from 10 to 35% [25].

The review of the references presented in this study and of similar cases studies suggests that melanoma metastasis should always be considered in the differential diagnosis for any patient presenting with a malignancy of unknown origin. It also indicates that the majority of melanoma metastasis with unknown primaries involving salivary glands has a better prognosis than stage IV melanoma of a known primary site with metastasis. Even though the American Joint Committee on Cancer still recommends that MUP's with salivary glands should be classified as stage IV. Last, this report and literature study concludes by underlining the need for increased reporting of every rare type of melanoma metastasis, so that in the future when diagnosed, patients can get a scientifically established adjuvant treatment based on a similar population.

Statement of Ethics

Written informed consent was obtained from the patient for publication of this case report and any accompanying images.

Conflict of Interest Statement

The authors have no conflicts of interest to declare.

Funding Sources

The authors received no specific funding for this work.

Author Contributions

Senne Gorris: conception, data collection, literature review, and writing. Celia Perdaens: materials and writing. Veerle Delvaux: materials. Bart Neyns: literature review and critical review. Vincent Vander Poorten: literature review and critical review. Ilan Baron: conception, data collection, literature review, and critical review supervision.

References

- 1 López F, Rodrigo JP, Cardesa A, Triantafyllou A, Devaney KO, Mendenhall WM, et al. Update on primary head and neck mucosal melanoma. *Head Neck*. 2016;38:147–55.
- 2 Amin MB, Edge SB. *American joint committee on cancer*. AJCC Cancer Staging Manual.
- 3 Schlagenhauff B, Stroebel W, Ellwanger U, Meier F, Zimmermann C, Breuninger H, et al. Metastatic melanoma of unknown primary origin shows prognostic similarities to regional metastatic melanoma: recommendations for initial staging examinations. *Cancer*. 1997;80(1):60.
- 4 Cancer Statistics Review, 1975-2015 - SEER Statistics. Accessed May 27, 2020. https://seer.cancer.gov/archive/csr/1975_2015/.
- 5 Miller KD, Nogueira L, Mariotto AB, Rowland JH, Yabroff KR, Alfano CM, et al. Cancer treatment and survivorship statistics, 2019. *CA Cancer J Clin*. 2019;69(5):363–85.
- 6 Chang AE, Karnell LH, Menck HR. The National cancer data base report on cutaneous and noncutaneous melanoma: a summary of 84,836 cases from the past decade the American college of surgeons commission on cancer and the American cancer society. *Cancer*. 1998;83:2.

- 7 Larkin J, Chiarion-Sileni V, Gonzalez R, Grob JJ, Rutkowski P, Lao CD, et al. Five-year survival with combined nivolumab and ipilimumab in advanced melanoma. *N Engl J Med*. 2019;381(16):1535–46.
- 8 Robert C, Ribas A, Schachter J, Arance A, Grob JJ, Mortier L, et al. Pembrolizumab versus ipilimumab in advanced melanoma (KEYNOTE-006): post-hoc 5-year results from an open-label, multicentre, randomised, controlled, phase 3 study. *Lancet Oncol*. 2019;20(9):1239–51.
- 9 Weber J, Mandala M, Del Vecchio M, Gogas HJ, Arance AM, Cowey CL, et al. Adjuvant nivolumab versus ipilimumab in resected Stage III or IV Melanoma. *N Engl J Med*. 2017;377(19):1824–35.
- 10 Eggermont AMM, Blank CU, Mandala M, Long GV, Atkinson V, Dalle S, et al. Adjuvant pembrolizumab versus placebo in resected stage III melanoma. *N Engl J Med*. 2018;378(19):1789–801.
- 11 Long GV, Hauschild A, Santinami M, Atkinson V, Mandalà M, Chiarion-Sileni V, et al. Adjuvant dabrafenib plus trametinib in stage III BRAF-mutated melanoma. *N Engl J Med*. 2017;377(19):1813–23.
- 12 Bowen GM, Chang AE, Lowe L, Hamilton T, Patel R, Johnson TM. Solitary melanoma confined to the dermal and/or subcutaneous tissue: evidence for revisiting the staging classification. *Arch Dermatol*. 2000;136(11):1397–9.
- 13 Giuliano AE, Moseley HS, Morton DL. Clinical aspects of unknown primary melanoma. *Ann Surg*. 1980;191(1):98–104.
- 14 Anbari KK, Schuchter LM, Bucky LP, Mick R, Synnestvedt M, Guerry D 4th, et al. Melanoma of unknown primary site: presentation, treatment, and prognosis—a single institution study University of Pennsylvania pigmented lesion study group. *Cancer*. 1997;73:1816–21.
- 15 De Waal AC, Aben KK, Van Rossum MM, Kiemeny LA. Melanoma of unknown primary origin: a population-based study in the Netherlands. *Eur J Cancer*. 2013;49(3):676–83.
- 16 Clerico R, Bottoni U, Paolino G, Ambrifi M, Corsetti P, Devirgiliis V, et al. Melanoma with unknown primary: report and analysis of 24 patients. *Med Oncol*. 2012;29(4):2978–84.
- 17 Savoia P, Fava P, Osella-Abate S, Nardò T, Comessatti A, Quaglino P, et al. Melanoma of unknown primary site: a 33-year experience at the Turin melanoma centre. *Melanoma Res*. 2010;20(3):227–32.
- 18 Koshenkov VP, Broucek J, Kaufman HL. Surgical management of melanoma. *Cancer Treat Res*. 2016;167:149–79.
- 19 Faries MB, Thompson JF, Cochran AJ, Andtbacka RH, Mozzillo N, Zager JS, et al. Completion dissection or observation for sentinel-node metastasis in melanoma. *N Engl J Med*. 2017;376(23):2211–22.
- 20 Howard JH, Thompson JF, Mozzillo N, Nieweg OE, Hoekstra HJ, Roses DF, et al. Metastasectomy for distant metastatic melanoma: Analysis of data from the first multicenter selective lymphadenectomy trial (MSLT-I). *Ann Surg Oncol*. 2012;19(8):2547–55.
- 21 Mittendorf EA, Lim SJ, Schacherer CW, Lucci A, Cormier JN, Mansfield PF, et al. Melanoma adrenal metastasis: natural history and surgical management. *Am J Surg*. 2008;195(3):363–9.
- 22 onkar PR, Ratnparkhi CR, Kajal M. High resolution ultrasound of the submandibular gland. *Int J Anat*. 2017;6(2):5–10.
- 23 Fives C, Feeley L, Sadadcharam M, O’Leary G, Sheahan P. Incidence of intraglandular lymph nodes within submandibular gland, and involvement by floor of mouth cancer. *Eur Arch Otorhinolaryngol*. 2017;274(1):461–6.
- 24 De Giorgi V, Stante M, Carli P. Unknown primary melanoma. *Eur J Cancer*. 2004;40(9):1454–5.
- 25 Blessing K, McLaren KM. Histological regression in primary cutaneous melanoma: recognition, prevalence and significance. *Histopathology*. 1992;20(4):315–22.