



Contents lists available at ScienceDirect

## International Journal of Surgery Case Reports

journal homepage: [www.casereports.com](http://www.casereports.com)

## Volvulus complicating jejunal diverticulosis: A case report



P.O. Igwe\*, E. Ray-Offor, A.B. Allison, E.F. Alufohai

Department of Surgery, University of Port Harcourt Teaching Hospital, Alakahia, Rivers State, Nigeria

## ARTICLE INFO

## Article history:

Received 2 December 2014  
 Received in revised form 8 February 2015  
 Accepted 9 February 2015  
 Available online 13 February 2015

## Keywords:

Jejunum  
 Diverticula  
 Volvulus

## ABSTRACT

**INTRODUCTION:** Diverticular disease is uncommon among Africans though increasing number of cases is now being reported, mainly of colonic diverticulosis. This condition afflicts all parts of the gastrointestinal tract but commonly the colon. Jejunal diverticula are rare, usually asymptomatic but may lead to an acute abdomen.

**CASE PRESENTATION:** A 68 year old female trader, who was referred from a peripheral center with insidious onset of severe colicky, generalized abdominal pain, repeated vomiting of recently ingested meal, no hematemesis. There was constipation and abdominal distension. The working diagnosis was dynamic intestinal obstruction of small bowel origin.

She had emergency exploratory laparotomy following resuscitation. The findings were: volvulus of the jejunum and multiple jejunal diverticula. A resection of 80 cm of the jejunum with most of the diverticula involved in the torsion was done with an end-to-end anastomosis of the jejunum. Her out-patient follow-up has been uneventful.

**DISCUSSION:** Jejunal diverticular disease is rare in Africa. Our patient presented with small bowel obstruction due to volvulus. Other complications are discussed.

**CONCLUSION:** Intestinal obstruction from diverticular disease is not always of colonic origin. It can occur in the jejunum.

© 2015 The Authors. Published by Elsevier Ltd. on behalf of Surgical Associates Ltd. This is an open access article under the CC BY-NC-ND license (<http://creativecommons.org/licenses/by-nc-nd/4.0/>).

## 1. Introduction

Jejunal diverticula are the outpouchings of the mucosa and the submucosa arising at the mesenteric border of the jejunum. It occurs in less than 0.5% of population [1]. The true etiology is unknown, but this condition is believed to develop from combination of abnormal peristalsis, intestinal dyskinesia and high segmental intra-luminal pressures. It could also be congenital arising from developmental anomalies.

A variety of complications can occur like stasis, bacteria overgrowth, diarrhoea, malabsorption syndrome, intestinal obstruction (as in index case), gastrointestinal bleeding, diverticulitis and rarely perforation with peritonitis [2–4].

## 2. Case report

A 68 year old female trader presented to the accident and emergency department with gradual onset of severe colicky generalized abdominal pain of six days duration prior to presentation associated with effortless vomiting of about five times a day. Vomitus consisted of recently ingested meal and no hematemesis. There

was complete constipation and progressive abdominal distension, anorexia and fever. No other significant symptoms were elicited.

She has had similar episodes intermittently, over the past three years prior to presentation but in a milder form. This was possibly the reason for which she was being treated for peptic ulcer disease in a peripheral center. She was a known hypertensive with poor drug compliance. She had no prior history of surgery, trauma to abdomen, exposure to radiotherapy. She was not a known diabetic patient. She was then referred to our hospital, when her symptoms persisted.

She was married in a monogamous family setting with three children. She took alcohol occasionally but did not use tobacco products. She was sixteen years post menopause and had no drug allergy.

On physical examination she was an elderly woman in painful distress. She was dehydrated, afebrile to touch, anicteric, no peripheral lymphadenopathy and no pedal edema.

Her vital signs were: respiratory rate 24 cycles  $\text{min}^{-1}$ , temperature was 37.00 C, pulse was 120 beats per minute full volume and regular. Blood pressure was 110/70 mm Hg. The respiratory, cardiovascular and central nervous system examinations were essentially normal.

Abdominal examination revealed distended abdomen which moved with respiration. Visible peristalsis was noted. Her hernia orifices were intact. There was generalized tenderness with guarding. No mass was palpable. The liver and spleen were not palpable

\* Corresponding author. Tel.: +234 8035510045.  
 E-mail address: [igwe\\_patrick@yahoo.com](mailto:igwe_patrick@yahoo.com) (P.O. Igwe).

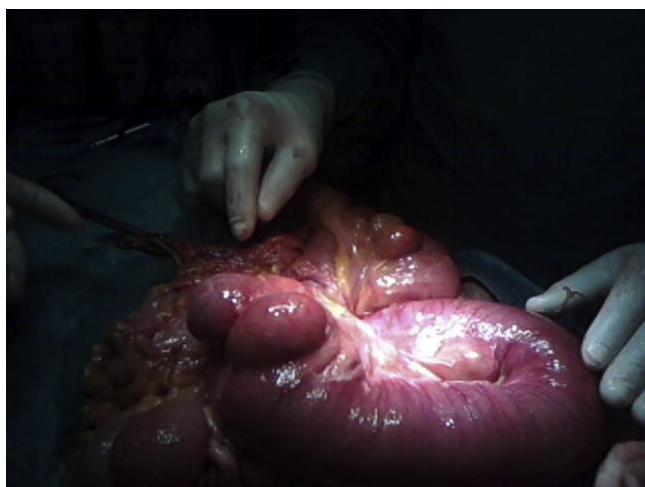


Fig. 1. Multiple diverticula disease of jejunum, with torsion of part of jejunum.

and the kidney was also not ballotable. The bowel sounds were present and hyperactive. Rectal examination was normal. A diagnosis of small bowel obstruction was made.

Investigations carried out included: Chest X-ray which showed features suggestive of cardiomegaly, aortic unfolding, but no evidence of pneumoperitoneum. Plain abdominal radiograph erect and supine showed multiple air-fluid level and dilated small bowel (jejunal) loops, respectively. Hemoglobin was 14g/dl, electrolyte urea and creatinine was Na=140mmol/l, K=4.6mmol/l, HCO<sub>3</sub> = 17mmol/l, Ur=4.7mmol/l, Cr=75umol/l. Urinalysis showed normal findings except for concentrated urine.

She was commenced on intravenous ceftriaxone 1 gm, metronidazole 500 mg, intravenous fluids. Analgesics, nasogastric tube and urethral catheter were passed. Fluid input and output monitoring and chatting were commenced. She had an emergency exploratory laparotomy and the findings were as follows:

Serous peritoneal fluid, volvulus of the jejunum with dilated proximal segment, multiple jejunal diverticula with the largest diverticulum upto 8 cm in widest diameter. The most proximal diverticular was 20 cm from the duodenojejunal (D-J) junction except for a minute diverticular observed close to the D-J junction. There was redundant caecum with the appendix in the midline (Figs. 1–3).

Resection of the jejunum including all portions with diverticula except for the smallest most proximal almost at the duodenojejunal

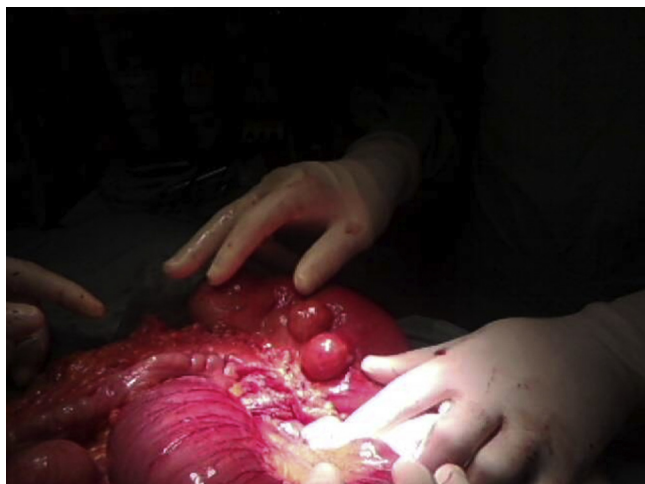
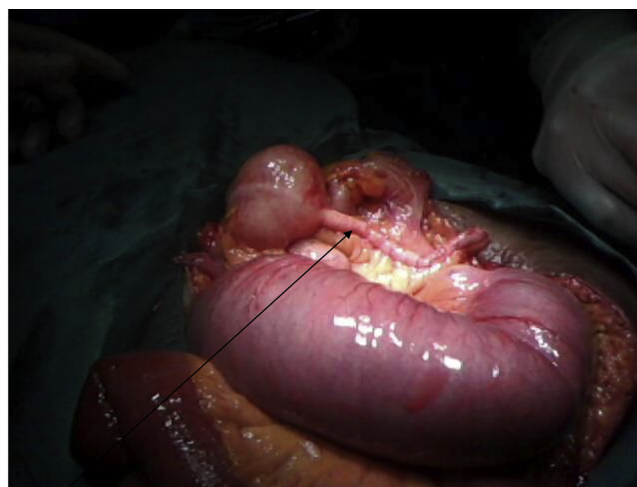

Fig. 2. Multiple diverticula of jejunum with part of dilated jejunum.



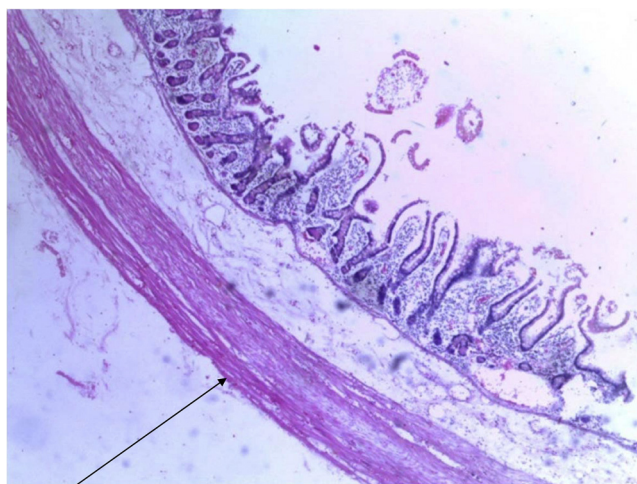
Appendix

Fig. 3. Vermiform appendix seen on left side of the midline with distended jejunum.

junction and jejunum-jejunal anastomosis was performed. Incidental appendicectomy and caecopexy were also carried out. Histology result showed inflamed diverticular, presence of muscular layer suggesting a congenital diverticular in origin and hypertrophied areas due to obstruction (Fig. 4–7). She did well post-operatively. Her fifth outpatient follow-up was uneventful.

### 3. Discussion

Jejunal diverticula are rare with an incidence of less than 0.5% [1]. Pathologically, they are commonly pseudo-diverticula of the pulsion type. They result from increased intraluminal pressure and weakening of the bowel wall. Increase in intraluminal pressure may be as a result of intermittent obstruction. Sommering was the first to describe this condition in 1794 and subsequently Astley Cooper in 1809. However the first operation for jejunal diverticula was performed in 1906 by Gordinier and Shil. Though most cases of jejunal diverticulosis remain asymptomatic complications are reported in 10–30% of patients [2–4] These include chronic abdominal pain, malabsorption syndrome, hemorrhage, diverticulitis, Intestinal Obstruction (as in index case), abscess formation, and rarely, perforation as reported by Butler et al. [5]. Complications of jejunal



Muscle layer

Fig. 4. Section from area of haustration (Out pouching).

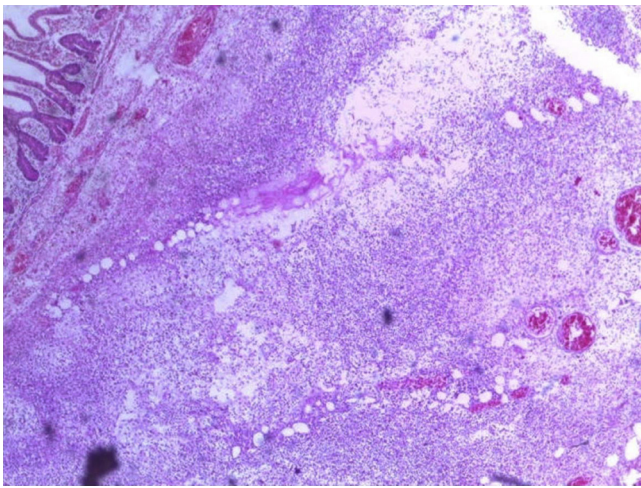


Fig. 5. Section of thick hyperemic areas (inflammatory cells).

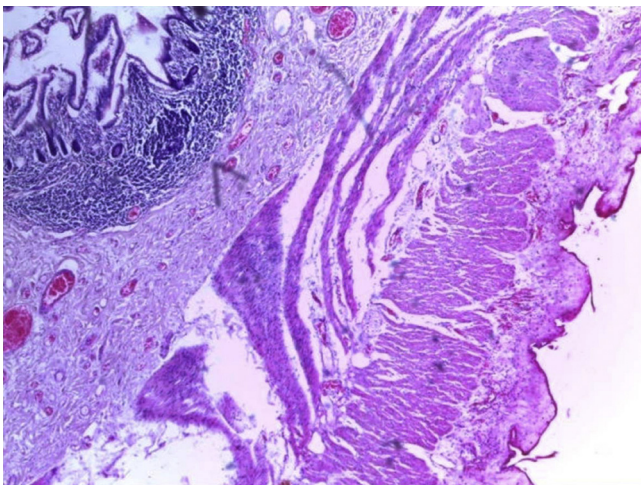
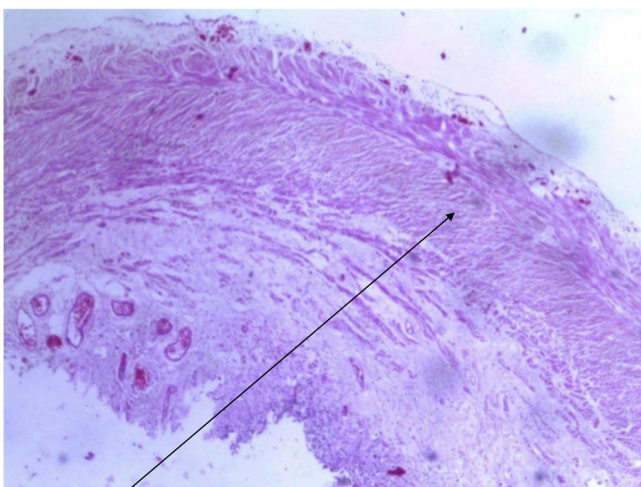


Fig. 6. Proximal resection margin.



Hypertrophied muscle layer

Fig. 7. Distal resection margin.

diverticulosis warranting surgical intervention occur in 8–30% of patients [6]. Common acute complications include; diverticulitis, bleeding, intestinal obstruction, and perforation [7].

Jejunal diverticulosis is a diagnostic dilemma. There is no investigative modality that is completely reliable. Plain radiograph of the abdomen and or chest may demonstrate evidence of intestinal obstruction or ileus including multiple air–fluid level and bowel dilatation as seen in index case. Evidence of perforation, such as free air under the diaphragm may be seen. Computerized tomographic (CT) scan may identify thickening or inflammation of the jejunum or localized abscess formation [8,9]. Some endoscopic procedures like capsule endoscopy, double-balloon enteroscopy are useful in diagnosing small bowel disorder [10]. However, these procedures cannot be done in emergency situation like intestinal obstruction or perforation. Minimal access surgery like diagnostic laparoscopy can be very useful in investigating patients with complications, making accurate occlusive diagnosis to be made, and thereby avoiding unnecessary laparotomy. When laparoscopic findings such as mechanical intestinal obstruction and perforation occur, exploratory is required with resection of the part of bowel involved and primary anastomosis as indicated. Where localized abscess collection occur, it has been reported that percutaneous CT-guided aspiration may be suitable and avoid need for surgery [11].

The treatment of choice for obstructive jejunal diverticula disease is prompt laparotomy with segmental intestinal resection and primary anastomosis. The extent of bowel resection depends upon the length of the bowel that is compromised and the patient's perioperative condition [12]. In extensive cases of diverticula, resection may have to be limited only to the segment involved in the obstruction and to leave a segment of small bowel to avoid short bowel syndrome [13].

In this index case, most of the diverticula were involved in the obstructing loop (Figs. 1 and 2) and considering her age, she underwent resection of obstructive loop containing most of the diverticula. She also had incidental appendicectomy and caecopexy for malpositioned appendix (Fig. 3) and redundant caecum, respectively.

In some cases, especially the acquired type of jejunal diverticula with an associated volvulus, adhesion band may be found and released [14]. This is unlike in our case, there was no adhesion band seen intraoperatively rather the mesenteric pedicle appeared to be thickened.

The histo-pathological result is represented in micrograph from Fig. 4 to Fig. 7 showing different sections. The congenital type of jejunal diverticula usually show muscular layer in its layers as seen in our case. In the acquired type, the mucosa and submucosa are seen without the muscular layer [15]. Two cases have been reported with familiar predisposition [16,17]. However, the fact that diverticula may develop as a result of being in an intermittent obstructed, high pressure closed loop may be a possibility too in index case despite lack of evidence from histopathology report. The size of the diverticula appears to correlate with obstructive complications. Diverticula greater than 3 cm in size is termed giant diverticula such as that reported by Falidas et al. [18] and our case, though ours had volvulus in addition.

#### 4. Conclusion

Diverticula disease of the jejunum though rare and usually asymptomatic, may lead to some chronic abdominal symptoms. It can also present as an acute condition as shown in this index case.

In the elderly, jejunal diverticula can cause significant morbidity and mortality hence should be suspected in those presenting with long term abdominal pains. If diagnosed, management should be instituted to reduce symptoms and risk of complications, associated with this condition. In rare situation, jejunal diverticula may

present as intestinal obstruction from volvulus warranting surgical exploration as the best treatment option.

### Previous scientific presentations

First presentation: International College of Surgeons (ICS) Conference Nigerian National Section Ile-Ife 2013 as “Obstructed jejunal diverticulosis: a case report”.

Second presentation: International College of Surgeons (ICS) Conference Asian Pacific Federation Congress 2013 (APFC held in Thailand) as “Obstructed jejunal diverticulosis: a case report”.

### Conflict of interest

Authors declare that there is no conflict of interest.

### Funding

No source of funding.

### Consent

Written informed consent was obtained from the patient involved.

### Author contribution

Case study design and writing was done by Patrick Okechukwu Igwe.

Contributing authors: E. Ray-Offor, A.B. Allison and E.F. Alufohai.

### Acknowledgement

We thank Dr. Aniebo C.C. for taking the pictures.

### References

- [1] J.S. Zager, J.E. Garbus, J.P. Shaw, M.G. Cohen, S.M. Garber, Jejunal diverticulosis: a rare entity with multiple presentations, a series of cases, *Dig. Surg.* 17 (2000) 643–645.
- [2] R.D. Wilcox, C.H. Shatney, Surgical implications of jejunal diverticula, *South. Med. J.* 81 (1998) 1386–1391.
- [3] A. Sibille, R. Willcox, Jejunal diverticulitis, *Am. J. Gastroenterol.* 87 (1992) 655–658.
- [4] R. Akhrass, M.B. Yaffe, C. Fischer, J. Ponsky, J.M. Shuck, Small-bowel diverticulosis: perceptions and reality, *J. Am. Coll. Surg.* 184 (1997) 383–388.
- [5] J.S. Butler, C.G. Collins, G.P. McEntee, Perforated jejunal diverticula: a case report, *J. Med. Case Rep.* 4 (2010) 172.
- [6] R.D. Wilcox, C.H. Shatney, Surgical significance of acquired ileal diverticulosis, *Am. Surg.* 56 (1990) 222–225.
- [7] K. Woods, E. William, W. Melvin, K. Sharp, Acquired jejunoileal diverticulosis and its complications: a review of the literature, *Am. Surg.* 74 (9) (2008) 849–854.
- [8] R. Hyland, A. Chalmers, CT features of jejunal pathology, *Clin. Radiol.* 62 (12) (2007) 1154–1162.
- [9] F. Fintelmann, M.S. Levine, S.E. Rubesin, Jejunal diverticulosis: findings on CT in 28 patients, *AJR Am. J. Roentgenol.* 190 (5) (2008) 1286–1290.
- [10] E.J. Carey, D.E. Fleischer, Investigation of the small bowel in gastrointestinal bleeding—enteroscopy and capsule endoscopy, *Gastroenterol. Clin. North Am.* 34 (4) (2005) 719–734.
- [11] J.S. Novak, J. Tobias, J.S. Barkin, Non-surgical management of acute jejunal diverticulitis: a review, *Am. J. Gastroenterol.* 92 (10) (1997) 1929–1931.
- [12] R. Mattioni, E. Lolli, A. Barbieri, M. D'Ambrosi, Perforated jejunal diverticulitis: personal experience and diagnostic with therapeutical considerations, *Ann. Ital. Chir.* 71 (1) (2000) 95–98.
- [13] J. Alvarez Jr., J. Dolph, J. Shetty, M. Marjani, Recurrent rupture of jejunal diverticula, *Conn. Med.* 46 (7) (1982) 376–378.
- [14] M.-Y. Hong, C.H. Chi, Small-intestinal volvulus, *N. Engl. J. Med.* 365 (2011) 358.
- [15] R. Williams, D.D. Davidson, A.L. Serota, S.E. Wilson, Surgical problems of diverticula of the small bowel, *Surg. Gynecol. Obstet.* 152 (1981) 621–626.
- [16] A.D. Koch, E.J. Schoon, Extensive jejunal diverticulosis in a family, a matter of inheritance? *Neth. J. Med.* 65 (2007) 154–155.
- [17] L.P. Andersen, B. Schjoldager, B. Halver, Jejunal diverticulosis in a family, *Scand. J. Gastroenterol.* 23 (1988) 672–674.
- [18] E. Falidas, K. Vlachos, S. Mathioulakis, F. Archontovasilis, C. Villias, Multiple giant diverticula of the jejunum causing intestinal obstruction: report of a case and review of the literature, *World J. Emerg. Surg.* 6 (2011) 8.

### Open Access

This article is published Open Access at [sciedirect.com](http://sciedirect.com). It is distributed under the [IJSCR Supplemental terms and conditions](#), which permits unrestricted non commercial use, distribution, and reproduction in any medium, provided the original authors and source are credited.