

Frequency of Diplopia after Intraoperative Nerve Disturbance in Trochlear Nerve Schwannoma: A Case Report and Systematic Review

Eiji FUJIWARA,¹ Kazuhide ADACHI,¹ Shinichiro TATEYAMA,¹
Mitsuhiro HASEGAWA,¹ and Yuichi HIROSE¹

¹Department of Neurosurgery, School of Medicine, Fujita Health University, Toyoake, Aichi, Japan

Abstract

Schwannomas of the trochlear nerve are relatively rare, and most patients present with preoperative diplopia because of trochlear nerve palsy. We describe the case of a 61-year-old male patient with a trochlear nerve schwannoma and no pre- and postoperative diplopia, despite his trochlear nerve being cut during the operation. We aimed to investigate the frequency of postoperative diplopia associated with intraoperative trochlear nerve disturbance by reviewing previous case reports, wherein postoperative diplopia did not occur after the trochlear nerve was cut intraoperatively. We recorded the frequency of diplopia because of intraoperative trochlear nerve disturbance, such as the trochlear nerve being cut, in cases without pre- and postoperative diplopia. We searched the PubMed, Medline, and Google Scholar databases for works published from 1976 to 2020 and followed the preferred reporting items for systematic reviews and meta-analyses guidelines. We reviewed 36 publications and found 92 cases of trochlear nerve schwannoma. Surgical resection was performed for 43 patients, of whom 40 were kept under observation and 9 were treated with radiation therapy. Of the 43 cases, 9 without preoperative diplopia underwent gross total resection. We analyzed ten cases (including ours) without preoperative diplopia to check for postoperative diplopia. In total, four cases, including ours, did not display postoperative diplopia despite the trochlear nerve being cut. This may be attributed to the preoperatively acquired motor and sensory fusion in the patient's vision because of tumor progression. Our findings may benefit neurosurgeons who treat patients with schwannomas and help them predict patients' outcomes.

Keywords: diplopia, fusion, trochlear nerve disturbance, trochlear nerve schwannoma

Introduction

The trochlear nerve is a pure motor nerve that controls the movement of the superior oblique muscle, which rotates the eyeballs toward the inner-downward position; thus, any kind of disturbance to the trochlear nerve leads to diplopia, whereby the eyes are made to look inward and downward. Intracranial schwannomas typically

originate from sensory nerves; schwannomas originating from the trochlear nerve are rare. As the first case report by King was published in 1976, limited cases of trochlear schwannoma have been reported,¹⁾ with only 91 cases being published between 1976 and 2020.^{1–36)}

Though there are several treatment options for trochlear nerve schwannoma, such as surgery, observation, and radiation, many symptomatic patients require aggressive interventions, such as surgical resection and/or radiation therapy. As many patients with schwannoma display preoperative diplopia, their vision is not affected when the trochlear nerve is cut during complete resection; however, for this reason, previous reports could not establish the frequency of postoperative diplopia.

Received March 23, 2021; Accepted June 7, 2021

Copyright© 2021 The Japan Neurosurgical Society
This work is licensed under a Creative Commons Attribution-NonCommercial-NoDerivatives International License.

We describe the case of a patient with a trochlear nerve schwannoma and no pre- and postoperative diplopia, despite that his trochlear nerve was cut intraoperatively. We considered this to be a novel case, although it was similar to surgeries for other pathologies; for example, neurosurgeons treating patients with petroclival meningioma who do not exhibit postoperative trochlear nerve palsy, despite having their nerve intraoperatively cut along the cerebellar tentorium edge.

To date, the frequency of postoperative diplopia because of intraoperative trochlear nerve disturbance has not been established. To bridge this knowledge gap, we aimed to investigate the frequency of postoperative diplopia associated with intraoperative trochlear nerve disturbance by reviewing our case report and previous case reports wherein postoperative diplopia did not occur after the trochlear nerve was cut intraoperatively.

Materials and Methods

Systematic review

For the systematic review, we searched PubMed, Medline, and Google Scholar databases for works published from 1976 to 2020, using the keywords “schwannoma,” “trochlear nerve,” “diplopia,” and “surgery” both alone and in various combinations, as per the preferred reporting items for systematic reviews and meta-analyses criteria. We screened the abstracts of the selected studies and decided to review those that stated their inclusion criteria in English and included imaging and follow-up/outcome data. From 36 publications, we identified 91 cases of schwannoma. Formal approval from a review board was not required for this type of study.

Case report

A 61-year-old man presented at our department with no significant medical history, normal laboratory results, and no suspicious findings of neurofibromatosis. The patient was treated for hydrocephaly at the neighborhood hospital and was referred to our hospital because his symptoms exacerbated owing to tumor progression. He presented with left hemiparesis (poor-to-fair grade of muscle movement), palsy of the right abducens nerve, and bilateral trigeminal neuralgia but did not show any signs of trochlear nerve palsy. Brain MRI findings revealed a well-demarcated extra-axial mass (Fig. 1) on the right lateral side of the midbrain. We resected the mass using a subtemporal transtentorial approach.

Intraoperatively, we found that the posterior portion of the trochlear nerve had fanned out and ran into a yellowish tumor, while the anterior

portion of the nerve ran along the tentorium ridge and entered the tentorium cerebelli (Fig. 2). We cut the trochlear nerve at the anterior side of the tumor and resected it, intentionally allowing a part of the nerve and tumor to adhere to the brainstem to avoid causing brain injury. After the operation, all symptoms improved, including diplopia with abducens nerve palsy and ocular motility disorder associated with trochlear nerve palsy without diplopia. Our final postoperative pathological diagnosis was a schwannoma arising from the trochlear nerve.

Results

Including our case, we identified a total of 92 cases of trochlear nerve schwannoma in this retrospective review. Preoperatively, 28 (30%) and 19 (20%) patients had diplopia and headaches, respectively. In total, 43 (47%), 40 (43%), and 9 (10%) patients were treated with surgical resection, underwent only observation, and received radiation therapy, respectively. Among the 43 cases of surgical resection, 13 patients had no preoperative diplopia and were treated with total or subtotal tumor resection.^{2,3,31} However, since subtotal resection cannot confirm whether the trochlear nerve was cut intraoperatively, we excluded the three cases of subtotal resection from this study. Finally, we included 10 patients (Table 1), including our patient whose trochlear nerve was certainly cut during the operation, who presented without preoperative diplopia, and were asymptomatic postoperatively despite denervation of their trochlear nerve. Therefore, out of 10 patients with surgical resection, 4 patients did not show postoperative diplopia despite that their trochlear nerve was cut intraoperatively (Fig. 3).

Discussion

As in our reported case, we aimed to discuss cases of trochlear nerve denervation during resection, but we found this was not possible in cases of subtotal resection because it was difficult to identify whether the trochlear nerve was cut intraoperatively. Therefore, we reviewed only cases where it was confirmed that the trochlear nerve was cut during surgery.

Patients without preoperative diplopia did not develop postoperative diplopia, despite the fact that their trochlear nerve had been cut intraoperatively, because they achieved fusion of visual function during tumor progression. Fusion is the ability to project correct images onto the retina and includes two types—motor and sensory fusion.³⁷ Motor fusion refers to the ability to correct the eye position to form an image at the corresponding point, whereas

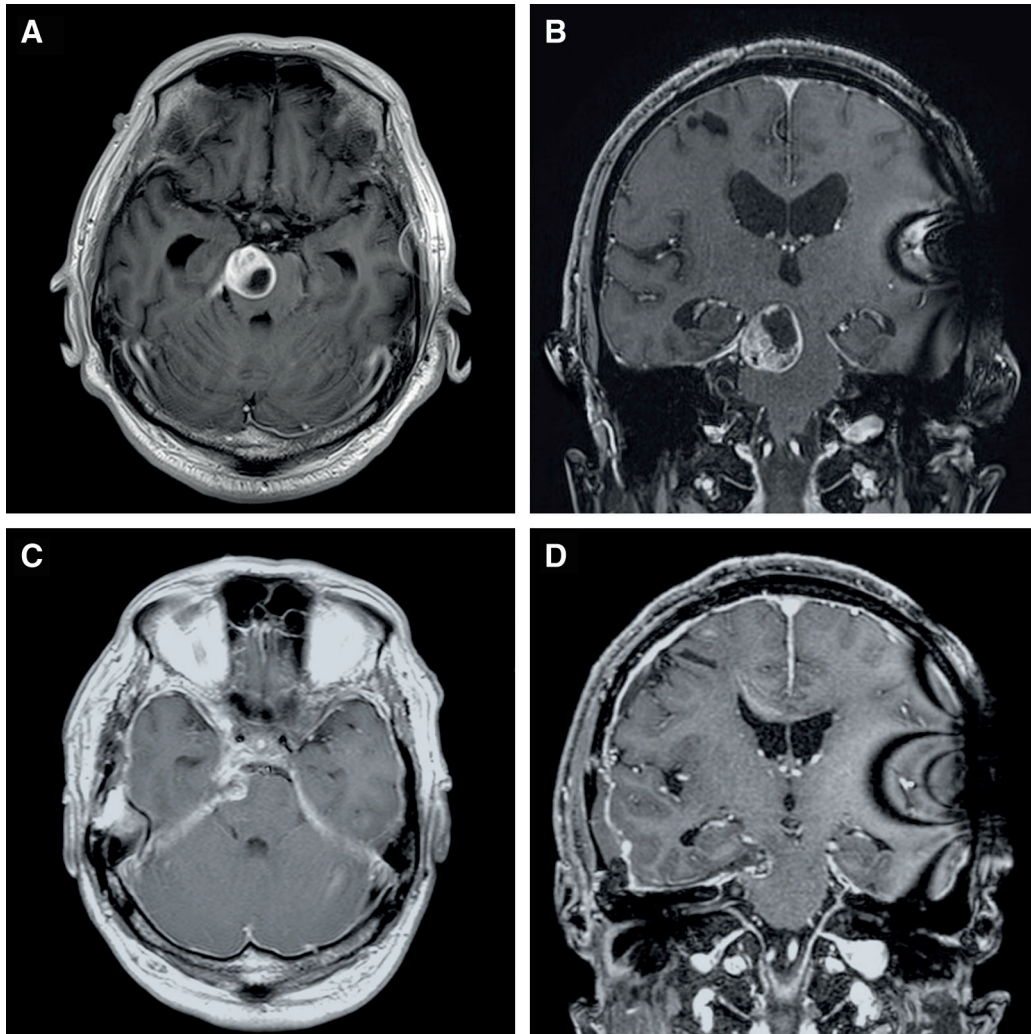


Fig. 1 Preoperative T1-weighted contrast MRI. MRI findings showing a mass measuring $25 \times 22 \times 25$ mm at the right lateral of the midbrain with a heterogeneously enhanced and partially included cystic change are presented (A and B). Postoperative T1-weighted contrast MRI showing a residual tumor adherent to the brainstem (C and D).

sensory fusion corresponds to the ability to construct two separate images in each eye and interpret them together as a single image.³⁸⁾ In superior oblique palsy, sensory fusion has a greater impact than motor fusion, although they both have important roles.³⁹⁾

Additionally, fusion is an important component of visual function; it helps maintain vision in the horizontal, vertical, and rotational directions (rotational direction maintains binocular vision).³⁸⁾ Superior oblique palsy is typically characterized by cyclovertical deviation. It is common among patients with an anomalous head position and is related to diplopia associated with cyclodeviation,⁴⁰⁾ but the area of rotatory fusion, which is well-developed in adults,^{41–45)} is wider than that of vertical fusion.⁴⁶⁾ Patients who acquire superior oblique muscle palsy

correct their excyclotropia by expanding the area of fusion to create incycloduction⁴⁰⁾; as they are not aware of their diplopia owing to sensory adaptation and suppression,⁴⁵⁾ they can achieve binocular single vision beyond the fusion area. Therefore, the reason that the patients did not experience postoperative diplopia despite their trochlear nerve being cut during surgery was attributed to the fact that motor fusion corrected their eye movement, sensory fusion, and suppression of the actual diplopia during tumor progression.

In cases of petroclival meningioma, some patients do not experience postoperative diplopia regardless of their trochlear nerve being cut during the transpetrosal surgical approach, consistent with the findings observed in our patient, perhaps because meningiomas and schwannomas are slow-growing

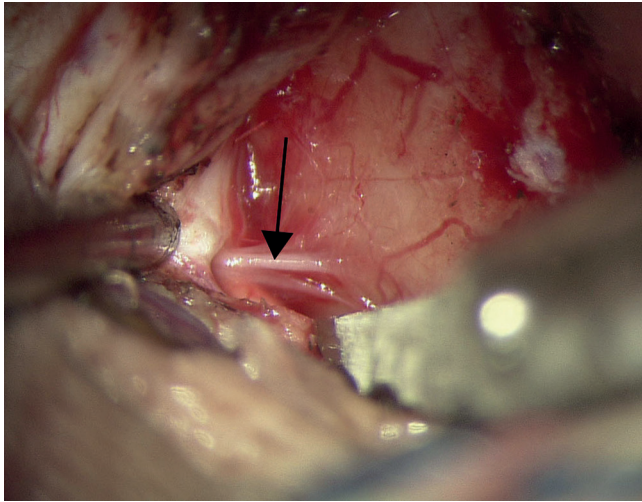


Fig. 2 Intraoperative photograph. An image showing the course of the trochlear nerve (black arrow) along the edge of and into the cerebellar tentorium is presented. This nerve spreads like a fan and transforms into the schwannoma.

tumors. Therefore, the patients remained unaware of their diplopia because vision fusion occurred preoperatively. Previous studies have similarly reported that sensory adaptation for cyclodeviation was greatly related to the onset age and visual environment and that sensory adaptation for cyclodeviation occurred regardless of the length of objective deviation.⁴⁷⁾ Alternatively, the function of the superior oblique muscle and trochlear nerve may be compensated by the extraocular muscles. Although in cases of congenital superior oblique palsy, the vertical rectus muscles compensate the action of superior oblique palsy,⁴⁸⁾ but there is limited evidence to support this theory.

Limitations

Our study was limited by its retrospective nature and the small number of cases of trochlear nerve schwannoma. None of the authors reporting cases of subtotal resection specified whether the trochlear

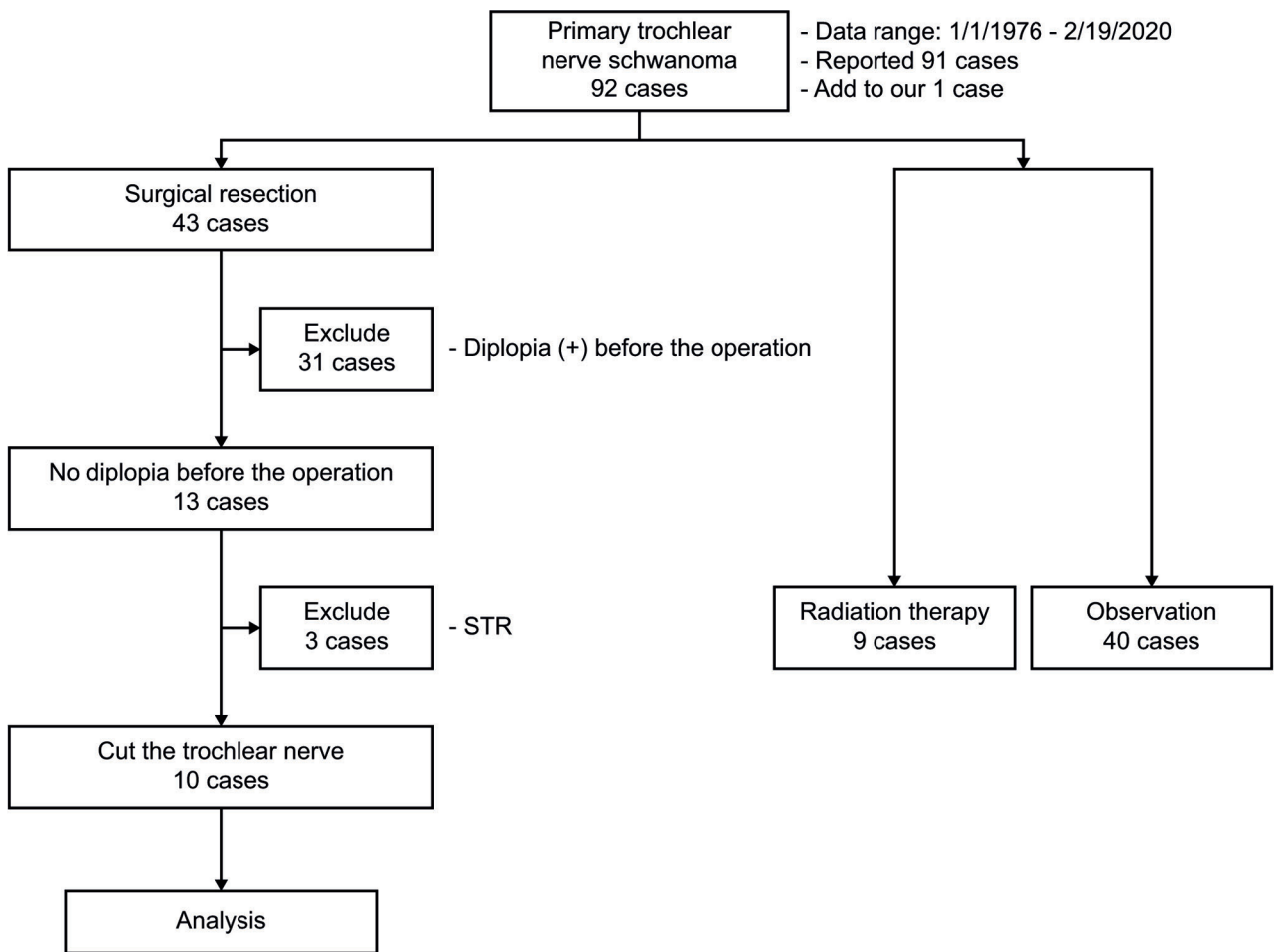


Fig. 3 Tree diagram showing our patient selection from all the trochlear nerve schwannoma cases. STR: subtotal resection.

Table 1 Ten cases of trochlear nerve schwannoma without pre- and postoperative diplopia

Case No.	Author(s) and year	Age	Sex	Other symptoms	Size (mm) and location	Approach	Postoperative diplopia
1	King et al. (1976) ¹⁾	55	F	Facial numbness, decreased corneal reflex, ataxia, hemihyphesthesia, headache, mild facial palsy	30 × 40 Cisternal	Subtemporal transtentorial	+
2	Garen et al. (1987) ¹³⁾	18	F	Mild left ptosis, mild and variable pupillary inequality	25 Cisternal	Subtemporal transtentorial	-
3	Santoreneos et al. (1997) ²⁸⁾	35	F	Headache, left hemiparesis, ataxia, right facial palsy	NA ^a Cisternal	Subtemporal transtentorial	+
4	Nadkarni and Goel (1999) ²³⁾	48	F	Pathological laughter, decreased right corneal reflex	NA ^a Cisternal	Pterional	+
5	Veshchev and Spektor (2002) ³³⁾	26	F	Left facial burning pain	NA ^a Cisternal	Subtemporal transtentorial	+
6	Shenoy and Raja (2004) ³⁰⁾	54	F	Headache, left hemiparesis, facial palsy, dysarthria, hoarseness, difficulty in swallowing, right ptosis	NA ^a Cisternal	Subtemporal transtentorial	-
7	Kohama et al. (2009) ¹⁸⁾	47	F	Left hemiparesis, cerebellar ataxia	40 Cisternal	Posterior transpetrosal	+
8	Chaudhry et al. (2016) ⁹⁾	24	F	Headache	24 × 22 × 31 Pineal	Paraoccipital transtentorial	+
9	Nesvick et al. (2017) ²⁴⁾	50	M	Left trigeminal neuralgia	17 × 9 × 8 Cisternal	Lateral suboccipital	-
10	Current study	61	M	Left hemiparesis, right sixth nerve palsy, bilateral fifth nerve palsy, gait disturbance	25 × 22 × 25 Cisternal	Subtemporal transtentorial	-

^aNA: Not available.

nerve was cut; thus, we had to exclude these cases from our study, further reducing the sample size. Though this study concluded that vision fusion prevented postoperative diplopia, we could not confirm that vision fusion truly occurred as the tumors grew within the patients.

Conclusion

We found that 4 out of 10 patients with trochlear nerve schwannoma without preoperative diplopia did not experience postoperative diplopia, although their trochlear nerve was certainly cut intraoperatively. Our findings may benefit ophthalmologists and neurologists who routinely treat patients with schwannomas and help them predict their patients' outcomes.

Ethics Approval and Consent to Participate

Formal approval from a review board was not required for the systemic review part of the study. For the case report, patient consent was obtained.

Author Contributions

All authors contributed to the study conception and design. Material preparation, data collection, and analysis were performed by Eiji Fujiwara and Kazuhide Adachi. The first draft of the manuscript was written by Eiji Fujiwara and Kazuhide Adachi, and all authors commented on previous versions of the manuscript. All authors read and approved the final manuscript.

Conflicts of Interest Disclosure

All the authors have no conflict of interest.

References

- 1) King JS: Trochlear nerve sheath tumor; case report. *J NeuroSurg* 44: 245–247, 1976
- 2) Abe T, Iwata T, Shimazu M, et al.: [Two cases of trochlear nerve neurinoma]. *No Shinkei Geka* 22: 371–375, 1994 (Japanese)
- 3) Abe T, Iwata T, Shimazu M, Matsumoto K: Trochlear nerve neurinoma associated with a giant thrombosed

- dissecting aneurysm of the contralateral vertebral artery. *Surg Neurol* 42: 438–441, 1994
- 4) Bartalena T, Leoni C, Trossello MP, et al.: Hourglass cystic schwannoma of the trochlear nerve. *Acta BioMed* 81: 147–150, 2010
 - 5) Beppu T, Yoshida Y, Wada T, et al.: Trochlear and abducens nerve neurinomas accompanied by a cerebellopontine angle meningioma--case report. *Neurol Med Chir (Tokyo)* 37: 416–421, 1997
 - 6) Boggan JE, Rosenblum ML, Wilson CB: Neurilemmoma of the fourth cranial nerve. *J NeuroSurg* 50: 519–521, 1979
 - 7) Boucher AB, Michael LM: The middle fossa approach for the removal of a trochlear schwannoma. *Case Rep Neurol Med* 2014: 672314, 2014
 - 8) Celli P, Ferrante L, Acqui M, Mastronardi L, Fortuna A, Palma L: Neurinoma of the third, fourth, and sixth cranial nerves: a survey and report of a new fourth nerve case. *Surg Neurol* 38: 216–224, 1992
 - 9) Chaudhry NS, Ahmad FU, Morcos JJ: Pineal region schwannoma arising from the trochlear nerve. *J Clin Neurosci* 32: 159–161, 2016
 - 10) Dolenc VV, Coscia S: Cystic trochlear nerve neurinoma. *Br J Neurosurg* 10: 593–597, 1996
 - 11) Du R, Dhoot J, McDermott MW, Gupta N: Cystic schwannoma of the anterior tentorial hiatus. Case report and review of the literature. *Pediatr Neurosurg* 38: 167–173, 2003
 - 12) Elmalem VI, Younge BR, Biousse V, et al.: Clinical course and prognosis of trochlear nerve schwannomas. *Ophthalmology* 116: 2011–2016, 2009
 - 13) Garen PD, Harper CG, Teo C, Johnston IH: Cystic schwannoma of the trochlear nerve mimicking a brainstem tumor. *J NeuroSurg* 67: 928–930, 1987
 - 14) Gentry LR, Mehta RC, Appen RE, Weinstein JM: MR imaging of primary trochlear nerve neoplasms. *AJNR Am J Neuroradiol* 12: 707–713, 1991
 - 15) Gerganov V, Amir S, Koerbel A, Brandes A, Stan A, Madjid S: Cystic trochlear nerve schwannoma. Case report. *Surg Neurol* 68: 221–225, 2007
 - 16) Hatae R, Miyazono M, Kohri R, Maeda K, Naito S: Trochlear nerve schwannoma with intratumoral hemorrhage presenting with persistent hiccups: a case report. *J Neurol Surg Rep* 75: e183–e188, 2014
 - 17) Jackowski A, Weiner G, O'Reilly G: Trochlear nerve schwannomas: a case report and literature review. *Br J Neurosurg* 8: 219–223, 1994
 - 18) Kohama M, Murakami K, Endo T, Watanabe M, Tomimaga T: Surgical and histological observations of trochlear neurinoma: case report. *Neurol Med Chir (Tokyo)* 49: 217–220, 2009
 - 19) Leunda G, Vaquero J, Cabezudo J, Garcia-Uria J, Bravo G: Schwannoma of the oculomotor nerves. Report of four cases. *J Neurol Surg* 57: 563–565, 1982
 - 20) Matsui T, Morikawa E, Morimoto T, Asano T: Presigmoid transpetrosal approach for the treatment of a large trochlear nerve schwannoma--case report. *Neurol Med Chir (Tokyo)* 42: 31–35, 2002
 - 21) Maurice-Williams RS: Isolated schwannoma of the fourth cranial nerve: case report. *J Neurol Neurosurg Psychiatry* 52: 1442–1443, 1989
 - 22) Murakawa T, Sh UT, Yokoyama K, Takada M, Yamada H: Trochlear neurinoma: case report. *Tak Red Cross Hosp Kiyou* 12: 163–167, 1988 (Japanese)
 - 23) Nadkarni TD, Goel A: Trochlear nerve neurinoma presenting as pathological laughter. *Br J Neurosurg* 13: 212–213, 1999
 - 24) Nesvick CL, Perry A, Graffeo CS, Raghunathan A, Hammack JE, Van Gompel JJ: Trochlear schwannoma presenting with isolated trigeminal neuralgia. *World Neurosurg* 103: e13–e20, 2017
 - 25) Torun N, Laviv Y, Jazi KK, et al.: Schwannoma of the trochlear nerve--an illustrated case series and a systematic review of management. *Neurosurg Rev* 41: 699–711, 2018
 - 26) Ohba S, Miwa T, Kawase T: Trochlear nerve schwannoma with intratumoral hemorrhage: case report. *Neurosurgery* 58: E791; discussion E791, 2006
 - 27) Samii M, Draf W, Lang J: *Surgery of the Skull Base*. ed 1. Heidelberg: Springer Science+Business Media, 1989
 - 28) Santoreneos S, Hanieh A, Jorgensen RE: Trochlear nerve schwannomas occurring in patients without neurofibromatosis: case report and review of the literature. *Neurosurgery* 41: 282–287, 1997
 - 29) Shenouda EF, Ghosh A, Coakham HB: Trochlear nerve schwannoma removed by combined petrosal approach. *Br J Neurosurg* 16: 600–604, 2002
 - 30) Shenoy SN, Raja A: Cystic trochlear nerve neurinoma mimicking intrinsic brainstem tumour. *Br J Neurosurg* 18: 183–186, 2004
 - 31) Tokuriki Y, Yamashita J, Kikuchi H, Asato R, Handa H: Trochlear nerve neurinoma--case report. *Neurol Med Chir (Tokyo)* 28: 70–73, 1988
 - 32) Türe U, Ozduman K, Elmaci I, Pamir MN: Infratentorial lateral supracerebellar approach for trochlear nerve schwannoma. *J Clin Neurosci* 9: 595–598, 2002
 - 33) Veshchev I, Spektor S: Trochlear nerve neuroma manifested with intractable atypical facial pain: case report. *Neurosurgery* 50: 889–891; discussion 891–892, 2002
 - 34) Yamamoto M, Jimbo M, Ide M, Kubo O: Trochlear neurinoma. *Surg Neurol* 28: 287–290, 1987
 - 35) Younes WM, Hermann EJ, Krauss JK: Cisternal trochlear nerve schwannoma: improvement of diplopia after subtotal tumour excision. *Br J Neurosurg* 26: 107–109, 2012
 - 36) Lan YH, Li YC, Chang CN, Zhang B, Lu YJ: Trochlear schwannoma arising from transition zone of nerve sheath in the pineal region: case report and review of the literature. *World Neurosurg* 137: 218–225, 2020
 - 37) Oppel O: On the importance of sensory and motor fusion in oculomotor paralysis. *Ber Zusammenkunft Dtsch Ophthalmol Ges* 9: 67–73, 1966
 - 38) Kawamura M: The examination for ocular position and binocular vision. *Japanese Orthoptic Journal* 14: 1–11, 1986 (Japanese)
 - 39) Makino S, Yamamoto Y: Cyclofusion and superior oblique palsy. *Neuro Ophthalmol* 30: 364–372, 2013 (Japanese)

- 40) Hirano K: Torsion in superior oblique muscle: part 1. Cyclofusion in acquired superior oblique palsy. *Journal of Japanese Association of Strabismus and Amblyopia* 101: 60–63, 2007 (Japanese)
- 41) Guyton DL: Clinical assessment of ocular torsion. *Am Orthopt J* 33: 7–15, 1983
- 42) von Noorden GK: Clinical and theoretical aspects of cyclotropia. *J Pediatr Ophthalmol Strabismus* 21: 126–132, 1984
- 43) Ruttum M, von Noorden GK: Adaptation to tilting of the visual environment in cyclotropia. *Am J Ophthalmol* 96: 229–237, 1983
- 44) Guyton DL, von Noorden GK: Sensory adaptations to cyclodeviations. In: Reinecke RD (ed): *Strabismus*. New York, Grune and Stratton, 1978, pp 399–403
- 45) von Noorden GK: Clinical observations in cyclodeviations. *Ophthalmology* 86: 1451–1461, 1979
- 46) Sharma P, Prasad K, Khokhar S: Cyclofusion in normal and superior oblique palsy subjects. *J Pediatr Ophthalmol Strabismus* 36: 264–270, 1999
- 47) Horikawa A, Hirai Y: Sensory adaptation to cyclodeviations in superior oblique palsy. *Ringan* 54: 1447–1450, 2000 (Japanese)
- 48) Irsch K, Guyton DL, Park HJ, Ying HS: Mechanisms of vertical fusional vergence in patients with “Congenital Superior Oblique Paresis” investigated with an eye-tracking haploscope. *Invest Ophthalmol Vis Sci* 56: 5362–5369, 2015

Corresponding author: Kazuhide Adachi, MD, PhD
Department of Neurosurgery, School of Medicine,
Fujita Health University, 1-98 Kutsukakechodenga-
kugakubo, Toyoake, Aichi 470-1192, Japan.
e-mail: kazu-adachi@rio.odn.ne.jp