

# Single access retroperitoneoscopic adrenalectomy: initial experience

Virgilijus Beiša, Edvinas Kildušis, Kęstutis Strupas

Vilnius University Hospital Santariskiu Clinics, Center of Abdominal Surgery, Lithuania

Videosurgery and Other Miniinvasive Techniques 2012; 7 (1): 45-49

DOI: 10.5114/wiitm.2011.25640

## Abstract

Today, endoscopic adrenalectomy has become a gold standard in endocrine surgery. To minimize the morbidity and improve cosmesis, single access retroperitoneoscopic adrenalectomy (SARA) has been developed as an alternative to traditional multiport laparoscopy and single port access (SPA) surgery, potentially exploiting even more the already proven benefits of minimally invasive surgery. We applied the SARA technique to adrenalectomy using the posterior retroperitoneal approach. The aim is to highlight the current situation regarding the feasibility and safety of single access retroperitoneoscopic adrenalectomy and to present our initial experience. Between October 2010 and February 2011, a 74-year-old woman (body mass index (BMI) – 31 kg/m<sup>2</sup>) with pheochromocytoma (1.2 cm in size) and 3 women, aged 45, 46 and 66 years (BMI – 27, 32, 33 kg/m<sup>2</sup>), respectively, and all diagnosed with Conn's adenoma (from 1.2 cm to 2.0 cm in size), underwent single access retroperitoneoscopic adrenalectomies. Operations were performed using conventional laparoscopic (STORZ) equipment. No conversions to the open or conventional retroperitoneal approach were necessary. There were no perioperative or postoperative complications. Operating time ranged from 60 min to 80 min. All patients left the hospital 2 days after surgery. The single access retroperitoneoscopic technique has been successfully applied to adrenalectomy as an available alternative to multiport laparoendoscopic adrenalectomy and single port access surgery. Exposure, visualization and dissection are the same as in retroperitoneal endoscopic adrenalectomy. The SARA surgery offers patient benefits such as faster convalescence, decreased postoperative scarring, better cosmetic effect and financial benefit.

**Key words:** endocrine surgery, adrenalectomy, retroperitoneoscopy, single access.

## Introduction

In the past two decades, laparoscopic surgery has almost replaced open surgery in most types of abdominal surgery, including adrenalectomies, for which it has become the method of choice in most cases [1-5]. The evolution of surgery today is toward less and less invasiveness [6], stimulated by the concept of natural orifice transluminal endoscopic surgery (NOTES) [7]. Our actual concept of SARA may supersede NOTES in adrenal surgery [1].

Since the first descriptions of endoscopic adrenal removals in 1992 [8, 9], minimally invasive adrenalectomy has become the gold standard in adrenal surgery [10, 11]. In 1994, minimally invasive adrenalectomy started to be performed using the posterior retroperitoneoscopic approach routinely using three ports [12]. Recently, we described a modification as a single-access procedure. This surgical technique may offer further progress in minimizing perioperative morbidity and increasing cosmesis [1].

### Address for correspondence

Virgilijus Beiša MD, Vilnius University Hospital Santariskiu Clinics, Center of Abdominal Surgery, Santariskiu 2, Vilnius 08661, Lithuania, phone: +37052365250, e-mail: virgilijus.beisa@santa.lt

Traditional laparoscopic techniques for adrenalectomy usually need several trocars for retraction of neighbouring visceral organs to expose the adrenal gland in the retroperitoneum. The posterior retroperitoneoscopic approach is thought to be the most promising method to perform single access surgery of the adrenal glands as it offers a direct way to the retroperitoneal organs [1]. This feature has made single access retroperitoneoscopic adrenalectomy a perfect solution for adrenal tumours.

The purpose of this article is to report on our first 4 cases of adrenalectomy in which the SARA technique was applied and to highlight the current situation regarding the feasibility and safety of performing single access retroperitoneoscopic adrenalectomy using conventional laparoscopic equipment in the Center of Abdominal Surgery at Vilnius University Hospital Santariskiu Clinics.

## Case report

In the Center of Abdominal Surgery at Vilnius University Hospital Santariskiu Clinics between October, 2010 and February, 2011, four single access retroperitoneoscopic adrenalectomies were performed using conventional laparoscopic (STORZ) equipment. The patients were 45, 46, 66 and 74 year old women with body mass index (BMI) of 27, 32, 33, 31 kg/m<sup>2</sup> respectively and who complained of high blood pressure.

All patients with adrenal gland tumours were thoroughly examined by an endocrinologist using ultrasound and computed tomography (CT) scans. Blood and urine levels of electrolytes and catecholamines and blood levels of aldosterone and cortisol were evaluated in all patients.

One patient had an increased level of catecholamines (adrenaline 300 ng/l and noradrenaline 900 ng/l) in the blood; the other 3 had increased levels of aldosterone in the blood (320 ng/l, 1126 ng/l, 694 ng/l). All patients underwent an abdominal CT scan: in the patient with increased blood levels of catecholamine 12 mm pheochromocytoma in the right adrenal gland was found (Figure 1). Patients with increased aldosterone showed 12 mm, 12 mm and 20 mm tumours in diameter in the right adrenal glands (Conn's adenomas).

After an explanation of the SARA method, all the patients gave their informed consent. Patients' data, operating time, estimated blood loss, perioperative and postoperative complications and outcomes were registered.

## Surgical technique

After induction of general anaesthesia, the patient is placed in the prone jack-knife position (Figure 2). Following a 2.5 cm transverse skin incision just beneath the tip of the 12<sup>th</sup> rib (Figure 3), the

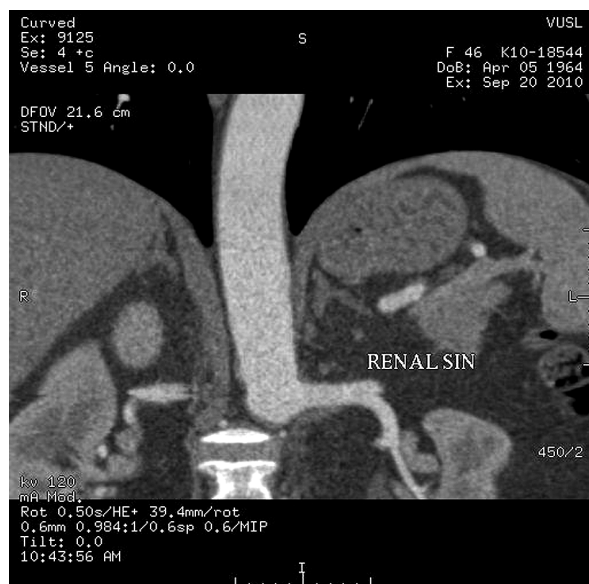

Figure 1. Computed tomography views of adrenal gland

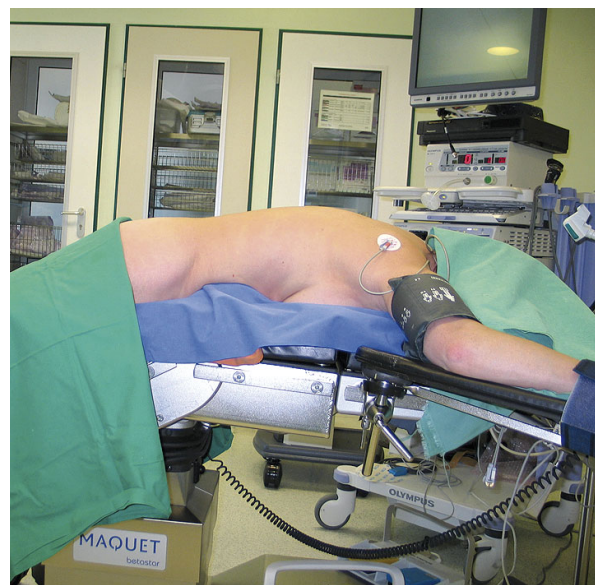
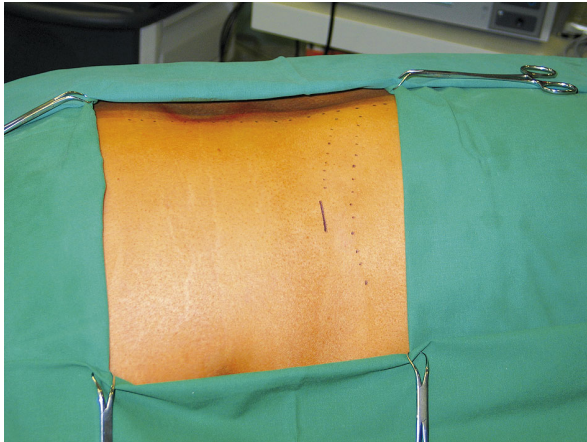
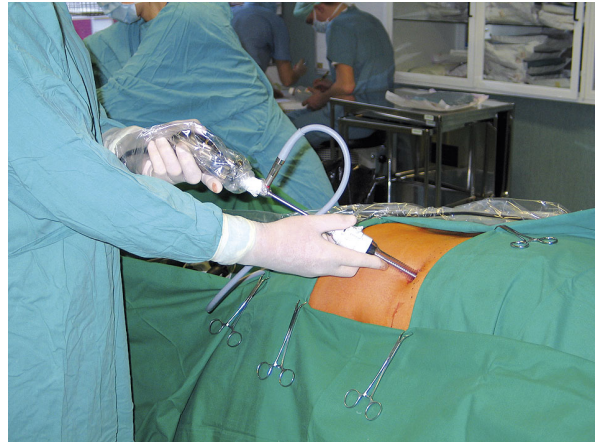

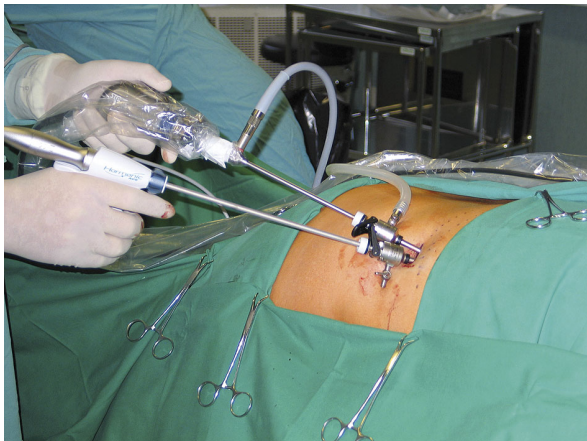
Figure 2. Prone jack-knife position



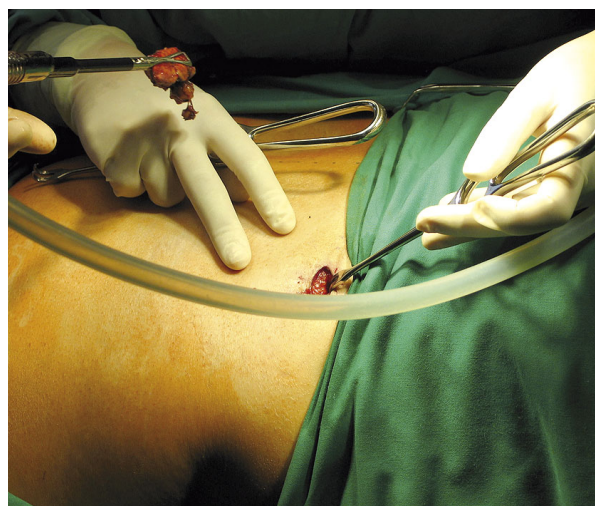
**Figure 3.** Marked line of skin incision



**Figure 4.** Trocar under endoscopic view



**Figure 5.** Single access retroperitoneoscopic adrenalectomy. Camera and bipolar scissors are introduced through one incision



**Figure 6.** Extraction of the specimen

retroperitoneum is entered with a 10 mm cutting optical trocar under endoscopic view (Figure 4). Retroperitoneoscopy is performed by a 10 mm 30° endoscope (Karl Storz Endoskope, Tuttlingen, Germany). The endoscope itself allows step-by-step creation of the retroperitoneal space by disruption of Gerota's fascia and by pushing the retroperitoneal fatty tissue bluntly downwards [1]. The capnoretroperitoneum is created by a carbon dioxide pressure of 20 mmHg.

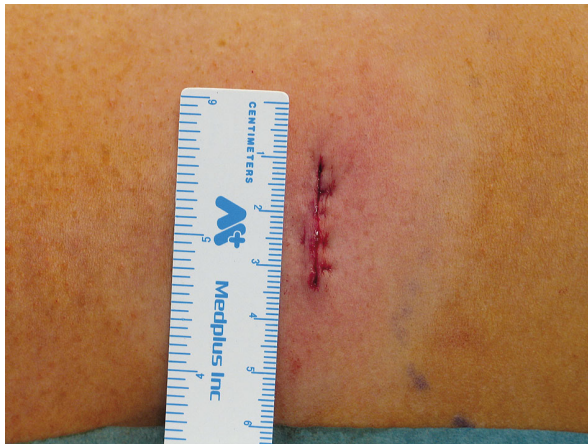
After extraction of the 10 mm trocar, through the same incision two 5 mm trocars for the introduction of conventional laparoscopic instruments (5 mm 30° endoscope and 5 mm ultrasonic dissector) were placed (Figure 5). The dissection is completely performed in a single hand technique. The non-domi-

nant hand holds the camera. After exposing the adrenal gland, the adrenal vein was dissected with the bipolar scissors (LigaSure®, Covidian, Neustadt, Germany).

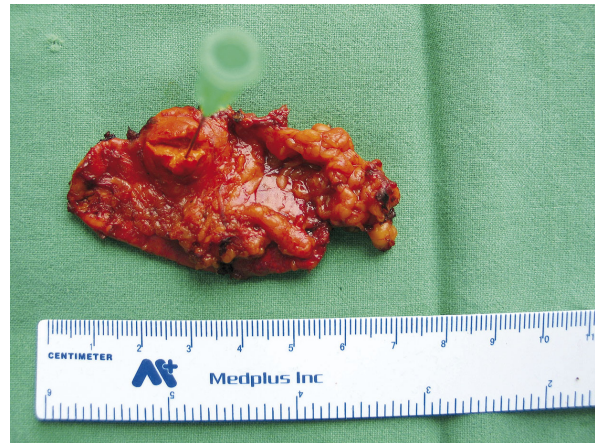One 5 mm trocar was pulled out, leaving the introducer, which helps to re-insert the 10 mm trocar. Through it with Bebbcock forceps (10 mm in diameter) the gland is captured and the specimen is extracted (Figure 6). No drain was inserted and the incision was closed subcutaneously (Figure 7).

No conversions to the open or conventional retroperitoneal approach were necessary. Mean operating time was 70 min (range: 60-80 min). Blood loss was insignificant (Table I). There were no preoperative or postoperative complications. None of the patients received pain medication postoperatively





**Figure 7.** Result after single access retroperitoneoscopic adrenalectomy operation



**Figure 8.** Adrenal gland tumour (opened and marked with needle)

after more than 10 h. Patients were discharged 2 days after adrenalectomy.

## Discussion

Over the last decade, standard laparoscopic and endoscopic retroperitoneal adrenalectomies have been the most popular [13]. Single access retroperitoneoscopic adrenalectomy with single port surgery represents the next generation in surgery. It uses a single skin incision, often concealed, to perform procedures with minimal scarring and reducing the trauma of surgical access, respecting the basic principles of adrenalectomy. The few published reports suggest a modest advantage for SARA surgery over standard laparoscopy, retroperitoneoscopy or SPA in terms of convalescence, postoperative pain, cosmetic effect or financial benefit [1, 7].

Attempts to perform adrenal surgery through a single incision began with a report by Kageyama *et al.* in 2004 [14] and later Hirano *et al.* in 2005 [15]. The latter investigators used a specialized resectoscope

tube with 4 cm diameter and standard laparoscopic instruments to perform a retroperitoneoscopic adrenalectomy without insufflation. Compared to SARA, feasibility, safety and cosmesis seem to be significantly poorer [1].

In 1994, minimally invasive adrenalectomy by the posterior approach was started by Walz *et al.* [12]. Now Walz and Alesina have developed and published the single-access retroperitoneoscopic adrenalectomy (SARA) method without any device as an access platform for placing instruments into the retroperitoneum [1]. The only generally accepted contraindication is obvious malignoma [1, 7].

If during operation with the TriPort it is necessary to convert to retroperitoneal endoscopic surgery, when three trocars are used, the TriPort remains unused. It increases the operation's cost. The SARA method does not require the expensive TriPort, and it is always possible to convert SARA into retroperitoneal endoscopic surgery with 3 trocars.

The cosmetic effect of SARA compared with the 3-trocar method is unquestionably better. The oper-

**Table I.** Characteristics of patients undergoing single access retroperitoneoscopic adrenalectomy

Patient	Age/sex	BMI [kg/m <sup>2</sup> ]	Site	Size [cm]	Diagnosis	Operative time [min]	Blood loss [ml]
1	46/F	32	R	1.2	Conn's adenoma	80	10
2	74/F	31	R	1.2	Pheochromocytoma	60	20
3	45/F	27	R	1.2	Conn's adenoma	80	20
4	66/F	33	R	2.0	Conn's adenoma	80	5

ation is limited to patients with tumours up to 2.5 cm in size, because only then is it possible to extract the adrenal gland in one piece, through the 2.5 cm incision. If the size of the specimen exceeds the size of the skin incision, the tissue needs to be morcellated [1].

The paucity of published studies makes it difficult to draw conclusions regarding complication rates with SARA adrenalectomy. Future studies should elucidate whether an additional benefit to this technique exists other than a favourable cosmetic result or financial benefit. These studies will probably require more sensitive metrics and longer postoperative follow-up to detect any existing differences.

## Conclusions

Single access retroperitoneoscopic adrenalectomy can be done safely by using conventional laparoscopic instruments.

## References

- Walz MK, Alesina PF. Single access retroperitoneoscopic adrenalectomy (SARA) – one step beyond in endocrine surgery. *Langenbecks Arch Surg* 2009; 394: 447-50.
- Łosin M, Czauderna P, Gołębiewski A, et al. Single incision laparoscopic adrenalectomy – initial experience. *Videosurgery and Other Miniinvasive Techniques* 2010; 5: 104-6.
- Myśliwiec P, Dadan J, Łukaszewicz J. Two tumours of the right adrenal gland treated videoscopically by the posterior retroperitoneal approach. *Videosurgery and Other Miniinvasive Techniques* 2009; 4: 126-30.
- Toutouchi S, Cieśla W, Krajewska E. Laparoscopic enucleation of a single adrenal tumour in a patient suffering from primary hyperaldosteronism. *Videosurgery and Other Miniinvasive Techniques* 2007; 2: 164-7.
- Otto M, Dzwonkowski J, Ciągła T. Laparoscopic adrenalectomy in elderly patients. *Videosurgery and Other Miniinvasive Techniques* 2006; 2: 54-8.
- Rattner D, Kaloo A. ASGE/SAGES working group on natural orifice transluminal endoscopic surgery. *Surg Endosc* 2006; 20: 329.
- Walz MK, Groeben H, Alesina PF. Single-Access Retroperitoneoscopic Adrenalectomy (SARA) Versus Conventional Retroperitoneoscopic Adrenalectomy (CORA): a case-control study. *World J Surg* 2010; 34: 1386-90.
- Gagner M, Lacroix A, Bolte E. Laparoscopic adrenalectomy in Cushing's syndrome and pheochromocytoma. *N Engl J Med* 1992; 327: 1033.
- Higashihara E, Tanaka Y, Horie S, et al. A case report of laparoscopic adrenalectomy. *Nippon Hinyokika Gakkai Zasshi* 1992; 83: 1130-3.
- Brunt LM. Minimal access adrenal surgery. *Surg Endosc* 2006; 20: 351-61.
- Cywiński J, Kuzdak K, Kołomecki K. One-incision approach (SILS) for retroperitoneal videoscopic adrenalectomy. *Videosurgery and Other Miniinvasive Techniques* 2010; 5: 70-1.
- Walz MK, Peitgen K, Hoermann R, et al. Posterior retroperitoneoscopy as a new minimally invasive approach for adrenalectomy: results of 30 adrenalectomies in 27 patients. *World J Surg* 1996; 20: 769-74.
- Beisa V, Simutis G, Strupas K. Evaluation of two methods of endoscopic adrenalectomy. *Zentralbl Chir* 2009; 134: 237-41.
- Kageyama Y, Kihara K, Kobayashi T, et al. Portless endoscopic adrenalectomy via a single minimal incision using a retroperitoneal approach: experience with initial 30 cases. *Int J Urol* 2004; 11: 693-9.
- Hirano D, Minei S, Yamaguchi K, et al. Retroperitoneoscopic adrenalectomy for adrenal tumors via a single large port. *J Endourol* 2005; 19: 788-92.