

Case Report

A Case of Anastomotic Stenosis of a Peripheral Arterial Bypass Graft Undetected in Indocyanine Green Angiography

Masaki Yamamoto, MD, PhD,^{1,2,3} Hitoshi Ninomiya, PhD,⁴ Miwa Tashiro, MD,² Hideaki Nishimori, MD, PhD,² Keiji Inoue, MD, PhD,^{3,5} Takayuki Sato, MD, PhD,^{3,6} Kazuhiro Hanazaki, MD, PhD,^{1,3,7} and Kazumasa Orihashi, MD, PhD^{2,3}

We report the case of a 75-year-old man who underwent right femoral-popliteal bypass surgery. Anastomotic stenosis was overlooked in indocyanine green (ICG) angiography due to opacification on the bypass graft. X-ray angiography revealed slit-shaped stenosis in the distal graft anastomosis that required revision. Although blood flow may be maintained despite of anastomotic stenosis, small decreases in blood flow cannot be detected in ICG angiography. We describe and discuss the pitfalls of qualitative graft assessment using ICG angiography, and compare ICG fluorescence luminance intensity between primary and revised grafts.

Keywords: indocyanine green angiography, bypass grafting, peripheral arterial disease

¹Department of Operating Management, Kochi Medical School, Kochi University, Kochi, Japan

²Department of Surgery 2, Kochi Medical School, Kochi University, Kochi, Japan

³Center for Photodynamic Medicine, Kochi Medical School, Kochi University, Kochi, Japan


⁴Integrated Centre for Advanced Medical Technologies, Kochi Medical School, Kochi University, Kochi, Japan

⁵Department of Urology, Kochi Medical School, Kochi University, Kochi, Japan

⁶Department of Cardiovascular Control, Kochi Medical School, Kochi University, Kochi, Japan

⁷Department of Surgery 1, Kochi Medical School, Kochi University, Kochi, Japan

Received: November 22, 2017; Accepted: January 21, 2018
Corresponding author: Masaki Yamamoto, MD, PhD. Department of Operating Management, Surgery 2, and Center for Photodynamic Medicine, Kochi Medical School, Kochi University, Kohasu, Oko-cho, Nankoku, Kochi 783-8505, Japan
Tel: +81-88-880-2375, Fax: +81-88-880-2376
E-mail: y-masaki@kochi-u.ac.jp

 ©2018 The Editorial Committee of Annals of Vascular Diseases. This article is distributed under the terms of the Creative Commons Attribution License, which permits use, distribution, and reproduction in any medium, provided the credit of the original work, a link to the license, and indication of any change are properly given, and the original work is not used for commercial purposes. Remixed or transformed contributions must be distributed under the same license as the original.

Introduction

Indocyanine green (ICG) angiography is used to evaluate anastomosis, as a substitute for ICG opacification through the graft, during peripheral arterial bypass grafting.¹⁾ However, detecting the presence of stenosis in the anastomosis is sometimes troublesome, because ICG angiography confirms blood flow through grafts but does not visualize vessel stenosis. We discuss a case of stenotic anastomosis that was overlooked in intraoperative ICG angiography during peripheral arterial bypass grafting.

Case Report

A 75-year-old man with arteriosclerosis obliterans underwent femoral-popliteal bypass grafting of the right lower limb. The right superficial femoral artery was occluded up to the knee, with 90% stenosis in the popliteal artery seen in contrast computed tomography (CT) imaging. The preoperative ankle-brachial pressure index (ABPI) value in the right lower extremity was 0.4. A reversed saphenous vein graft was also anastomosed to the popliteal artery below the knee, followed by graft assessment using ICG angiography (HyperEye Medical System; Mizuho Ikakogyo, Co., Ltd., Tokyo, Japan) (Figs. 1A–1C, Movie 1). Qualitative assessment using ICG angiography imaging revealed opacification of the bypass graft.²⁾ Postoperative ABPI (0.61) showed insufficient improvement. X-ray angiography revealed a slit-shaped stricture on the distal graft anastomosis (Fig. 2A). Surgical findings showed that the anastomotic suture was hooked onto the opposing inner membrane tissue, causing a stricture. After revision, blood flow was confirmed qualitatively using ICG angiography (Figs. 1D–1F, Movie 2). X-ray angiography showed patency of the anastomosis (Fig. 2B). The mean graft flow in the primary and revised graft was 21 and 57 mL/min, respectively, as measured using transit-time flowmetry (TTF; Veri Q System; Medi-Stim ASA, Oslo, Norway) (Figs. 2C and 2D). Postoperative progress of the patient was favorable (ABPI, 0.81).

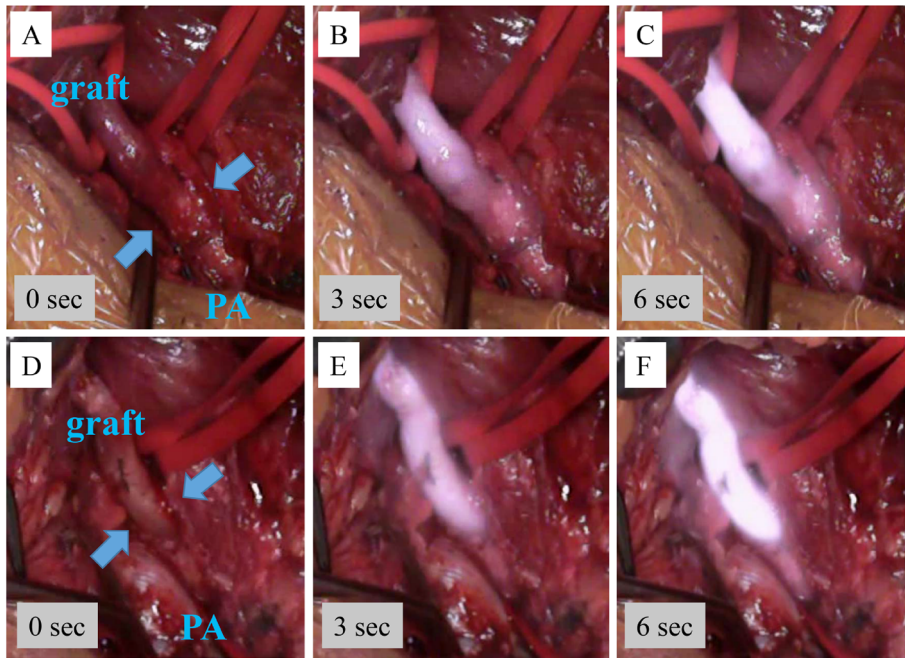


Fig. 1 Indocyanine green angiography. (A–C) Indocyanine green (ICG) opacification of the graft and popliteal artery (PA) during primary surgery. (D–F) ICG opacification of the graft and PA during revision surgery.

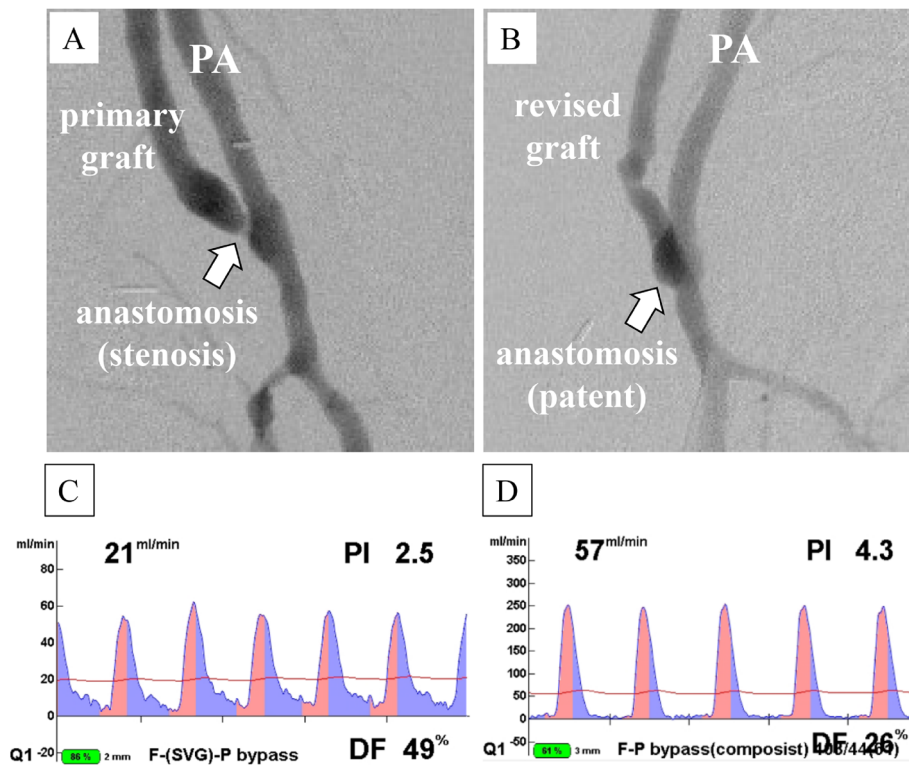


Fig. 2 X-ray angiography and transit-time flowmetry (TTF). Femoral-popliteal bypass grafting. (A) Severe anastomotic stenosis (arrow). (B) No stenotic anastomosis (arrow). (C, D) Graft flow measurements using TTF during primary surgery (C) and revision surgery (D). PA: popliteal artery

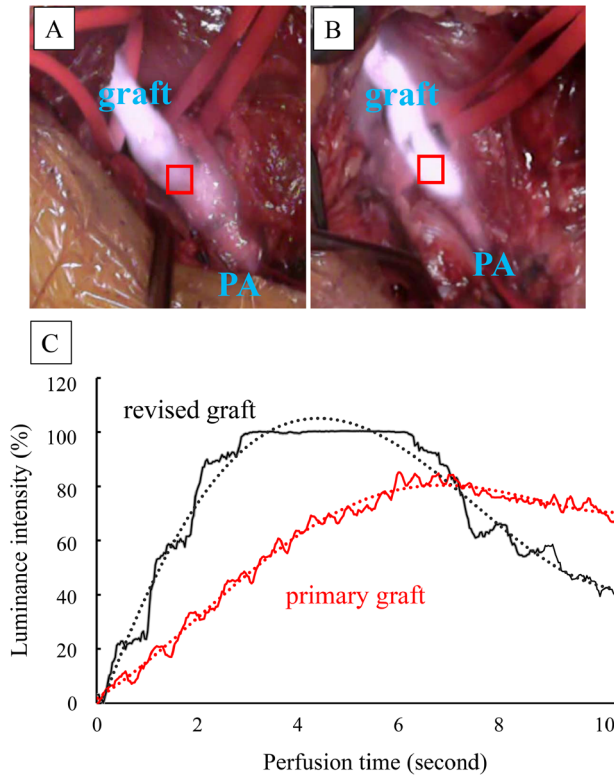


Fig. 3 Quantitative assessment of indocyanine green angiography. (A, B) The regions of interest (square) were measured using luminance intensity. PA: popliteal artery. (C) Time intensity curve of bypass grafts, depicting the primary graft (line) and revision graft (line). The continuous line depicts raw data, and the dotted line depicts the approximated curve.

ICG opacification luminance intensity of the graft was quantitatively measured retrospectively³⁾ (Fig. 3). Time intensity curves (TICs) of the bypass grafts of the patient were compared between the primary and revised grafts. The peak intensity was higher in the revised graft than in the primary graft, although statistical analysis could not be performed.

Discussion

We report the case of a patient who had severe stenosis despite showing smooth ICG opacification. We found that the primary graft had insufficient flow after retrospectively comparing ICG opacification between the primary and revised graft. It was impossible to identify graft failure based solely on ICG opacification of the primary graft. Furthermore, blood flow through the graft may be influenced by individual differences including peripheral arterial status, residual vascular bed, and muscle mass.⁴⁾

Therefore, it is preferable to use conventional X-ray angiography to assess anastomosis during peripheral arterial bypass grafting. Intraoperative ABPI is also useful to evaluate increase in peripheral blood flow. If ICG angiography is used for

graft assessment, quantitative assessment is an available option. Previous studies have reported that average acceleration of ICG luminance reflects anastomotic stenosis of coronary artery bypass grafts.^{3,5)} In our patient, acceleration of primary and revised grafts was 12.1 and 23.8 intensity/s², respectively, although it was not possible to compare them statistically. A procedure for ICG angiography with quantitative assessment of peripheral arterial bypass grafts has not been established; therefore, further studies are required in this direction.

Conclusion

This case report describes anastomotic failure of a bypass graft, which was not detected during ICG angiographic assessment of the peripheral arterial bypass graft.

Disclosure Statement

All authors declare that they have no conflicts of interest.

Supplementary Materials

The online version of this article contains supplementary materials.

Author Contributions

Study conception: MY

Data collection: MY

Analysis: MY, HN

Investigation: MY, HN

Writing: MY

Funding acquisition: none

Critical reviews and revision: all authors

Final approval of the article: all authors

Accountability for all aspects of the work: all authors

References

- 1) Yamamoto M, Orihashi K, Nishimori H, et al. Indocyanine green angiography for intra-operative assessment in vascular surgery. *Eur J Vasc Endovasc Surg* 2012; **43**: 426-32.
- 2) Yamamoto M, Orihashi K, Nishimori H, et al. Efficacy of intraoperative HyperEye Medical System angiography for coronary artery bypass grafting. *Surg Today* 2015; **45**: 966-72.
- 3) Yamamoto M, Nishimori H, Handa T, et al. Quantitative assessment technique of HyperEye medical system angiography for coronary artery bypass grafting. *Surg Today* 2017; **47**: 210-7.
- 4) D'Ancona G, Bartolozzi F, Bogers AJ, et al. Intraoperative graft patency verification in coronary artery surgery: modern diagnostic tools. *J Cardiothorac Vasc Anesth* 2009; **23**: 232-8.
- 5) Yamamoto M, Nishimori H, Fukutomi T, et al. Influence of vessel stenosis on indocyanine green fluorescence intensity assessed by near-infrared fluorescence angiography. *Surg Today* 2017; **47**: 877-82.