

Meckel's Diverticulitis Presenting with Abdominal Pain and Angina

Roberto Andres Novoa, B.A., and Kitt Shaffer, M.D., Ph.D.

Meckel's diverticulum is the most common congenital gastrointestinal anomaly, and 2-4% of patients with a Meckel's diverticulum will subsequently develop complications, including intestinal hemorrhage, intestinal obstruction, and diverticulitis. Meckel's diverticulitis is infrequently included in the differential diagnosis of abdominal pain in older adults. We present a case of Meckel's diverticulitis in a 74 year-old male who presented with non-specific abdominal pain and angina. Here, multi-detector computed tomography (MD-CT) imaging provided a pre-operative diagnosis of Meckel's diverticulitis. We then offer a review of the epidemiology, anatomy, radiologic findings, and differential diagnosis of Meckel's diverticulitis. This case presents coronal and sagittal MD-CT reconstructions of Meckel's diverticulitis that have yet to be well-described in the literature.

Introduction

Meckel's diverticulum is the most common congenital gastrointestinal anomaly. 2-4% of patients with a Meckel's diverticulum will subsequently develop complications, the most common being intestinal hemorrhage, intestinal obstruction, and diverticulitis. Classically,

these complications present in children, and Meckel's diverticulitis is infrequently included in the differential diagnosis of abdominal pain in older adults. Below, we present a case of Meckel's diverticulitis manifesting in an older adult as abdominal pain and angina. We also provide a review of the epidemiology, anatomy, and findings on computed tomography of Meckel's diverticulitis. This case includes coronal and sagittal multi-detector CT reconstructions of Meckel's diverticulitis that have yet to be well-described in the literature.

Citation: Novoa RA, Shaffer K. Meckel's diverticulitis presenting with abdominal pain and angina. *Radiology Case Reports*. [Online] 2008;3:166.

Copyright: © 2008 The Authors. This is an open-access article distributed under the terms of the Creative Commons Attribution-NonCommercial-NoDerivs 2.5 License, which permits reproduction and distribution, provided the original work is properly cited. Commercial use and derivative works are not permitted.

Abbreviations: CT, computed tomography; MRI, magnetic resonance imaging

Roberto Andres Novoa, B.A.(Email: Roberto_novoa@hms.harvard.edu), is a student at Harvard Medical School, Boston, MA, USA

Kitt Shaffer, M.D., Ph.D. (Email: kshaffer@challiance.org), is in the Department of Radiology, Cambridge Health Alliance and Harvard Medical School, Cambridge, MA, USA

Published: July 8, 2008

DOI: 10.2484/rcr.v3i3.166

Case Report

The patient was a 74 year-old male who presented to the emergency department with 26 hours of abdominal pain and chest pain described as "angina." The patient was in his usual state of health until 10 PM on the evening prior to presentation, when he experienced

Meckel's Diverticulitis Presenting with Abdominal Pain and Angina

the acute onset of sharp upper abdominal pain. This abdominal pain was accompanied by nausea without vomiting, and the patient denied any change in bowel habits, melena, or hematochezia. Two hours later, the patient developed a squeezing substernal chest pain similar to a previous myocardial infarction, and his abdominal pain changed to sharp, intermittent bilateral lower abdominal pain accompanied by subjective fever, chills, malaise, and mild dysuria without hematuria. In the emergency department, the patient reported subjective improvement of the chest pain with nitroglycerin and aspirin, but no improvement in his abdominal pain. The patient's past medical history was significant for coronary artery disease status-post myocardial infarction, alcoholism, transient atrial fibrillation, hypertension, and benign prostatic hypertrophy. His past surgical history included a triple coronary bypass graft surgery four years prior to presentation and a left inguinal hernia repair in the distant past.

The patient's medications included atorvastatin 10

mg daily, metoprolol 50 mg daily, lorazepam 1-2 mg daily as needed, and aspirin 81 mg daily. He had no known drug allergies, lived alone, and consumed 4-5 alcoholic drinks per day. On physical examination, the patient was a well-nourished older gentleman in no acute distress. His temperature was 101.3, with a blood pressure of 156/74, heart rate of 72, respiratory rate of 22, and oxygen saturation of 96% on room air. The patient's abdomen was soft and tender in both lower quadrants, with voluntary guarding but no rebound tenderness. The stool Guaiac test was negative. His labs revealed an increased white blood cell count of 13,500 per microliter, with 31% bands, and negative cardiac enzymes. His electrocardiogram showed a normal sinus rhythm with a rate of 75 beats per minute.

A supine abdominal radiograph revealed cholelithiasis and mildly dilated loops of small bowel, while an upright abdominal radiograph showed several air-fluid levels (Fig. 1). An abdominal and pelvic CT with oral and intravenous contrast was subsequently performed.

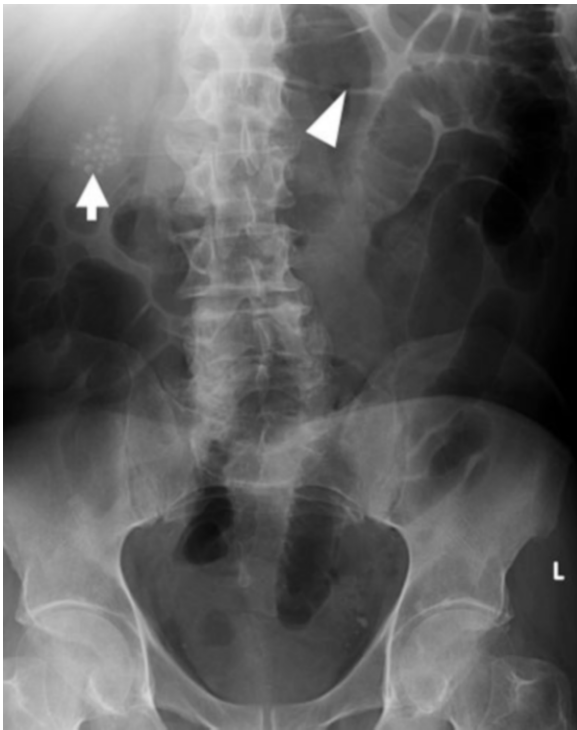


Figure 1A. 74-year-old man with Meckel's diverticulitis. Supine abdominal radiograph shows cholelithiasis (arrow) and dilated loops of small bowel (arrowhead)

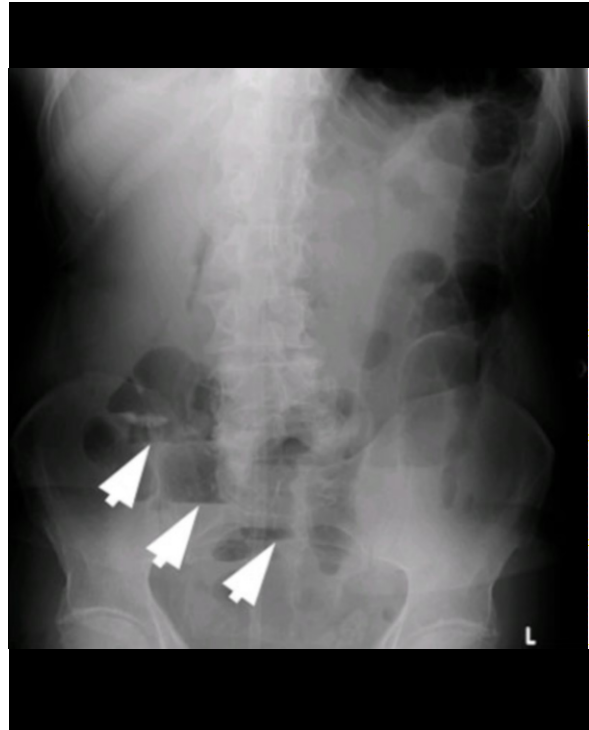


Figure 1B. Upright abdominal radiograph shows dilated loops of small bowel, with multiple air fluid levels (arrows)

Meckel's Diverticulitis Presenting with Abdominal Pain and Angina

Axial views revealed a midline 1.7 cm mass with central fluid attenuation adjacent to the distal ileum, with an enhancing wall and without oral contrast present in the lumen, representing a diverticulum or abscess (Fig. 2). Coronal and sagittal reconstructions showed an inflammatory fluid-filled diverticulum descending from

the anti-mesenteric border of a small bowel loop and impinging on an adjacent loop of bowel. There was no association with the bladder or the anterior abdominal wall that would suggest a urachal duct cyst, and the patient's appendix was visualized and found to be un-inflamed. Given the study's appearance, a pre-operative

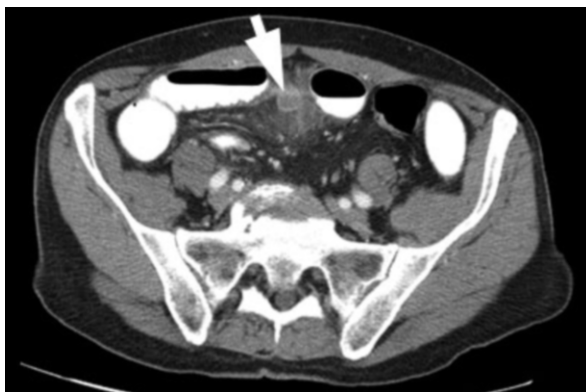

Figure 2A. CT axial images with oral and intravenous contrast. A fluid filled diverticulum associated with the neighboring bowel can be seen at the midline (arrow).

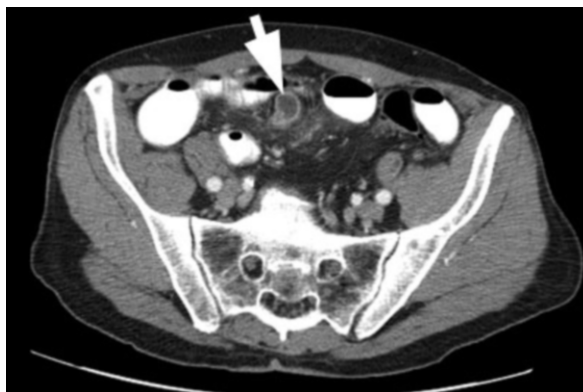


Figure 2B. There is enhancement of the diverticulum's walls and fat stranding in the surrounding tissues.

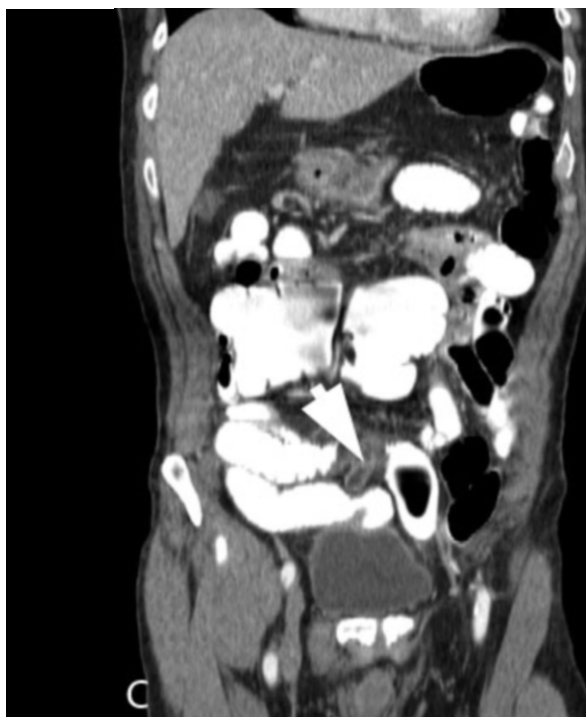
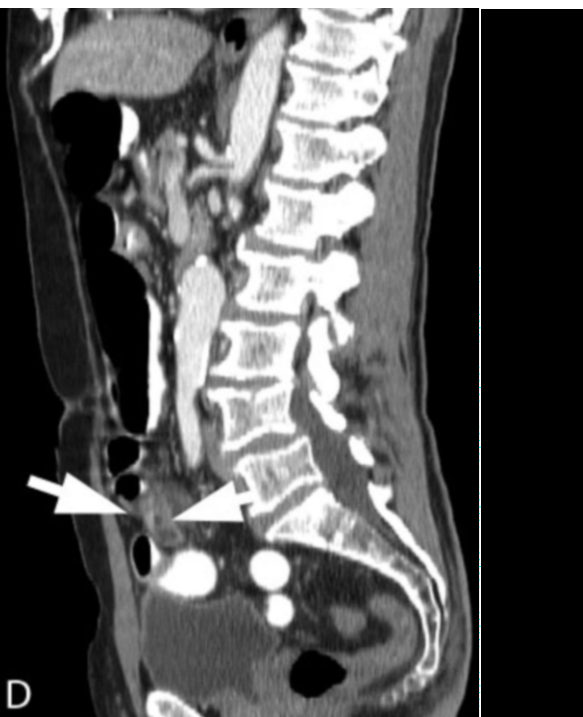
Figure 2C-D. (C) Coronal CT reconstruction shows fluid-filled diverticulum (arrow) emerging from anti-mesenteric border of bowel. (D) Sagittal CT reconstruction shows a diverticulum descending from the inferior border of the small bowel (arrow).



Meckel's Diverticulitis Presenting with Abdominal Pain and Angina

diagnosis of Meckel's diverticulitis was made.

The patient was taken to the operating room and underwent a segmental resection of the diverticulum and 10 cm of associated ileum with a laparoscopic to open approach. Fig. 3 is a photograph of the inflamed diverticulum captured by the laparoscope during the procedure and Fig. 4 is a photograph of the gross pathologic specimen. Gross and histologic examination revealed a diverticulum near the anti-mesenteric border of the bowel, with ectopic colonic-type mucosa and transmural diverticulitis. There were no intra-operative complications and the patient tolerated the surgery well. His post-operative course was marked by transient atrial fibrillation responsive to metoprolol and by several days of loose stools cultured for clostridium difficile and empirically treated with metronidazole. The patient subsequently recovered without incident and was discharged on the sixth post-operative day.

Discussion

Although first described by Fabricius Hildanus in 1598, Meckel's diverticulum derives its eponym from Johann Friedrich Meckel, who carefully described its anatomy and embryologic origins in 1809 [1]. The diverticulum is a remnant of the omphalomesenteric, or vitelline, duct, which connects the growing embryo's midgut to the yolk sac during early development. In most embryos, this duct spontaneously involutes during the sixth to eighth weeks of gestation.[2] Incomplete involution can result in various abnormalities, including patent omphalomesenteric ducts, omphalomesenteric

fistulas, enterocysts, and Meckel's diverticula, both with and without fibrous bands connecting them to the umbilicus [3]. A Meckel's diverticulum is the most common of these abnormalities, present in 0.4-4% of the population [4, 5, 6] and most often located on the anti-mesenteric surface of the distal ileum. Though classically described as 2 cm in length, it can vary broadly in size, with 90% ranging between 1 and 10 cm [7, 8]. Similarly, ninety percent of Meckel's diverticula occur within 90 cm of the ileocecal valve[9]. The diverticulum derives its blood supply from remnants of the vitelline artery, which arises from either the ileal or ileocolic branches of the superior mesenteric artery. Up to fifty percent of diverticula exhibit ectopic mucosa, with the most common of these being gastric mucosa, followed by pancreatic. Colonic epithelium such as that found in our patient is quite unusual, occurring in less than six percent of patients [2].

Approximately 4 to 6.4% of patients with a Meckel's diverticulum experience symptoms at some point in their lives [5, 10], and one of the largest studies of symptomatic patients indicated that 40% of these present before the age of 10 [8]. Adults with complications most commonly suffer from small bowel obstruction secondary to intussusception or volvulus, gastrointestinal bleeding, or diverticulitis [5, 10]. On occasion, a Meckel's diverticulum can also be the site of malignancy, with the most common tumors being sarcomas, followed by carcinoid tumors and adenocarcinomas [2].

While rare, multiple case reports and case series show that geriatric patients such as ours may also develop complications from a Meckel's diverticulum

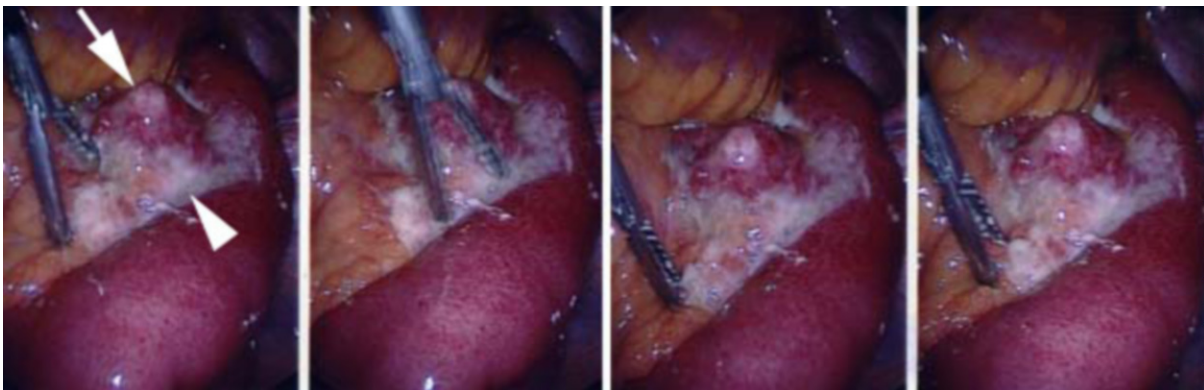


Figure 3. Laparoscopic images of diverticulum (arrow) surrounded by purulent exudate (arrowhead).

Meckel's Diverticulitis Presenting with Abdominal Pain and Angina

[11,12,13] particularly diverticulitis. Patients with Meckel's diverticulitis often present with non-specific symptoms such as abdominal pain, nausea, vomiting, fever, and leukocytosis [14]. Given these circumstances, clinical diagnosis in older patients can be quite challenging, and it is often difficult to differentiate Meckel's diverticulitis from more common intra-abdominal processes such as appendicitis or sigmoid diverticulitis on clinical grounds. In these circumstances, imaging studies can be of tremendous value.

Multiple radiologic modalities have been used in the detection of Meckel's diverticula, with varying degrees of success. Plain-film radiography is quite non-specific, but can demonstrate complications from a Meckel's diverticulum, such as obstruction and perforation [15]. Technetium-99 pertechnetate scanning can be useful in the diagnosis of occult bleeding due to a Meckel's diverticulum, as the ectopic gastric mucosa takes up the radioactive technetium and appears bright on a nuclear imaging study. The sensitivity of this test approaches 90% in children, but only achieves 60% in adults, as older patients are less likely to have diverticula containing gastric mucosa [16]. Ultrasound is an appealing modality for pediatric patients, where sonographic findings typical of a Meckel's diverticulum include either a blind tubular structure, resembling an abnormal appendix, or a cystlike structure with the appearance of bowel [17]. These structures are typically hyperemic, lacking peristalsis, and often demonstrate an irregular internal

mucosa, as opposed to the smooth internal lining of cysts [18].

CT diagnosis of an uninfamed Meckel's diverticulum can prove difficult due to the similar attenuation of the diverticulum and the bowel wall [19]. Also, a small bowel obstruction secondary to a Meckel's diverticulum may prevent oral contrast from reaching the distal ileum and the site of the lesion. CT imaging of an inflamed di-

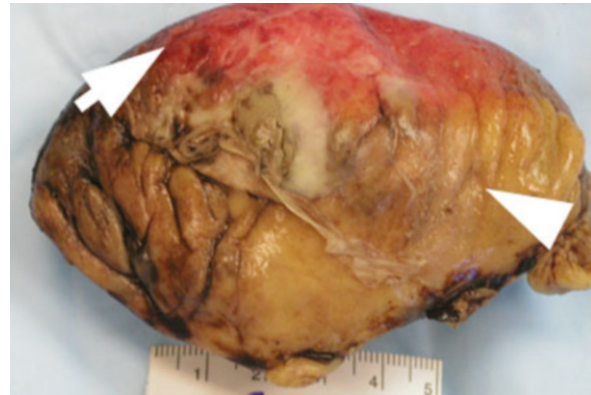

Figure 4. Gross pathologic specimen, showing the mesenteric surface of a resected segment of ileum (arrow) and its mesentery (arrowhead). The surface of the ileum shows marked inflammation and erythema. The diverticulum (not pictured) is located on the anti-mesenteric surface of the ileum. Courtesy of Rebecca Osgood, M.D., Cambridge Hospital Department of Pathology.

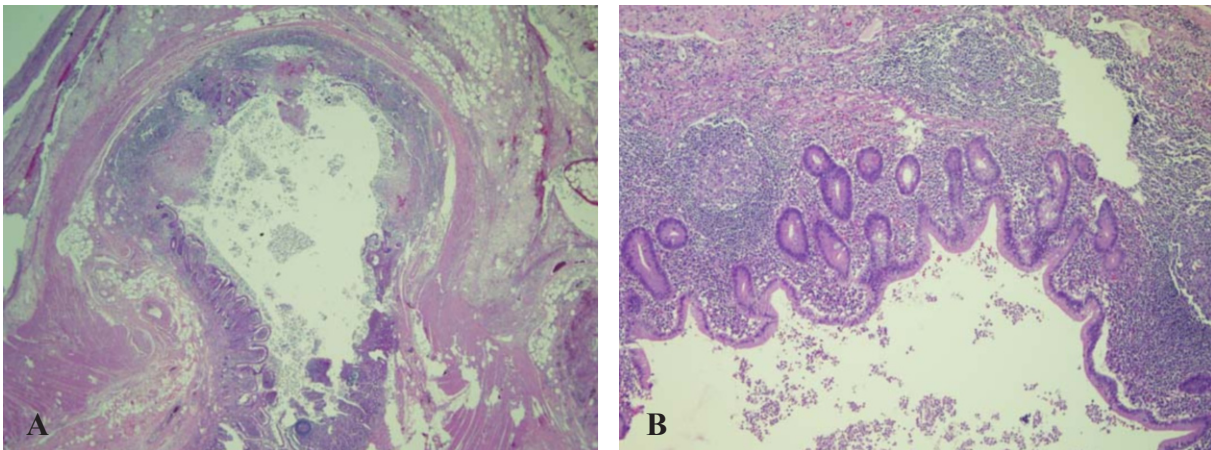


Figure 5. Photomicrographs at low power (A) and medium power (B) show ectopic colonic-type mucosa and transmuritis. Courtesy of Rebecca Osgood, M.D., Cambridge Hospital Department of Pathology.

Meckel's Diverticulitis Presenting with Abdominal Pain and Angina

verticulum, however, typically reveals tubular collections of air and fluid with mural thickening and wall enhancement [20]. There are also a few case reports describing enteroliths obstructing the diverticulum and leading to ischemia and inflammation [21, 22]. Meckel's diverticula are most often found in the midline, although they can also be found in other locations, including the left and right lower quadrants and the right paracolic gutter [23].

Meckel's diverticulitis may be confused with appendicitis, and so identification of the appendix is critical to interpretation of the CT [23]. Other items to include on the radiologic differential diagnosis include Crohn's disease, ileal diverticulitis, and infected urachal duct cysts. Crohn's disease frequently involves the terminal ileum and causes asymmetric wall thickening of the mesenteric border of the bowel, leading to outpouchings and pseudodiverticula along the antimesenteric border that can resemble Meckel's diverticulitis. However, Crohn's disease frequently causes marked narrowing of the lumen ("string" sign) and involves distant segments of small and large bowel. It is also marked by fatty infiltration of the bowel wall or by a "halo" sign of high attenuation along inner and outer edges of the bowel's edematous submucosa [24]. Urachal duct cysts represent an incomplete closure of the urachus, a cord-like structure connecting the primitive bladder to the umbilicus in early embryonic formation [25]. When infected, they present as a pocket of fluid with brightly enhancing walls, and frequently occur at the midline. Although urachal duct cysts can appear quite similar to a Meckel's diverticulum, they tend to follow the anatomic path of the urachus itself, and so occur in very close proximity to either the anterior abdominal wall or the bladder, without an association with the bowel [26]. Nevertheless, the two entities can sometimes be extremely difficult to distinguish from one another. Finally, while rare, small bowel diverticula do occur, decreasing in frequency from the duodenum to the terminal ileum [27]. Like colonic diverticula, small bowel diverticula contain only mucosa and submucosa, and protrude through the weak areas of the muscularis where it is penetrated by the vasa recta. Consequently, small bowel diverticula almost always run along the mesenteric border, and when inflamed, they appear as mesenteric collections of fluid and air abutting thickened bowel [28, 29].

This is an unusual case in several respects. First, the

patient was elderly, an age group in which Meckel's diverticulitis has very low prevalence. Secondly, the diagnosis was complicated by his symptoms of chest pain relieved with nitroglycerin and his history of coronary artery disease with prior myocardial infarctions. Although his angina may have been secondary to fever or anxiety, it could easily have proven to be a dangerous red herring. To our knowledge, there are no case reports of patients with Meckel's diverticulitis presenting with angina. Third, the presence of colonic epithelium within his diverticulum is quite rare. Finally, the coronal reconstructions shown in this case have not yet been well-described in the diagnosis of Meckel's diverticulitis, and clearly demonstrate an inflamed fluid-filled sac emerging from the antimesenteric surface of the distal ileum, dramatically narrowing the differential diagnosis. In summary, older patients with Meckel's diverticulitis who present with non-specific findings may well benefit from the advantages provided by MD-CT imaging, leading to greater accuracy in diagnosis and treatment.

References

1. Yahchouchy EK, Marano AF, Etienne JC, Fingerhut AL. Meckel's diverticulum. *J Am Coll Surg.* 2001 May;192(5):658-62. [PubMed]
2. Odze, Robert D. Goldblum, John R., Crawford, James M. *Surgical Pathology of the GI tract, Liver, Biliary Tract, and Pancreas.* Elsevier, Philadelphia 2004. 177-179. ISBN: 0721693180
3. Ameh EA, Mshelbwala PM, Dauda MM, Sabiu L, Nmadu PT. Symptomatic vitelline duct anomalies in children. *S Afr J Surg.* 2005 Aug;43(3):84-5. [PubMed]
4. Turgeon DK, Barnett JL. Meckels Diverticulum. *Am J Gastroenterol.* 85: 777-781, 1990. [PubMed]
5. Cullen, JJ, Kelly KA: Current management of Meckels diverticulum. *Adv Surg.* 29: 207-214, 1996. [PubMed]
6. Lüdtke FE, Mende V, Kohler H, Lepsien G. Incidence and frequency of complications and management of Meckel's diverticulum. *Surg Gynecol Obstet* 1989.

Meckel's Diverticulitis Presenting with Abdominal Pain and Angina

169: 537542. [PubMed]

7. Dumper J, Mackenzie S, Mitchell P, Sutherland F, Quan ML, Mew D. Complications of Meckel's diverticula in adults. *Can J Surg*. 2006 Oct;49(5):353-7. [PubMed]

8. Yamaguchi M, Takeuchi S, Awazu S. Meckel's Diverticulum. Investigation of 600 patients in the patients in the Japanese literature. *Am J Surg* 1978; 136: 247-249. [PubMed]

9. Williams RS. Management of Meckel's diverticulum. *Br J Surg* 1981;68:477-80. [PubMed]

10. Leijonmarck CE, Bonman-Sandelin K, Frisell J, et al. Meckel's diverticulum in the adult. *Br J Surg*. 1986; 73:146-149. [PubMed]

11. Feller AA, Movson J, Shah S. Meckel's diverticulum: a geriatric disease masquerading as common gastrointestinal tract disorders *Arch Intern Med*. 2003 Sep 22;163(17):2093-6. [PubMed]

12. Srinivas GN, Cullen P. Intestinal obstruction due to Meckel's diverticulum: a rare presentation. *Acta Chir Belg*. 2007 Jan-Feb;107(1):64-6. [PubMed]

13. Nagler J, Clarke JL, Albert SA. Meckel's diverticulitis in an elderly man diagnosed by computed tomography. *J Clin Gastroenterol*. 2000 Jan;30(1):87-8. [PubMed]

14. Martin JP, Connor PD, Charles K. Meckel's diverticulum. *Am Fam Physician*. 2000 Feb 15;61(4):1037-42, 1044. [PubMed]

15. Ghahremani GG. Radiology of Meckel diverticulum. *CRC Crit Rev Diagn Imaging* 1986; 26: 1-43. [PubMed]

16. Schwartz MJ, Lewis JH. Meckel's diverticulum: pitfalls in scintigraphic detection in the adult. *Am J Gastroenterol*. 1984 Aug;79(8):611-8. [PubMed]

17. Baldisserotto M, Maffazoni DR, Dora MD. Sonographic findings of Meckel's diverticulitis in children.

AJR Am J Roentgenol 2003; 180:425-428. [PubMed]

18. Baldisserotto M. Color Doppler sonographic findings of inflamed and perforated Meckel diverticulum. *J Ultrasound Med*. 2004 Jun;23(6):843-81 [PubMed]

19. Rossi P, Gourtsoyiannis N, Bezzi M, et al. Meckel's diverticulum: imaging diagnosis. *AJR Am J Roentgenol*. 1996 Mar;166(3):567-73. [PubMed]

20. Levy AD, Hobbs CM. From the archives of the AFIP. Meckel diverticulum: radiologic features with pathologic Correlation. *Radiographics*. 2004 Mar-Apr;24(2):565-87. [PubMed]

21. Pantongrag-Brown L, Levine MS, Buetow PC, et. al. Meckel's enteroliths: clinical, radiologic, and pathologic findings. *AJR Am J Roentgenol*. 1996 Dec;167(6):1447-50. [PubMed]

22. Higginson AP, Hall RI. Meckel's diverticulitis due to an obstructing enterolith: ultrasound and CT appearances. *Clin Radiol*. 2001 Jul;56(7):593-5. [PubMed]

23. Bennett GL, Birnbaum BA, Balthazar EJ. CT of Meckel's diverticulitis in 11 patients. *AJR Am J Roentgenol*. 2004 Mar;182(3):625-9. [PubMed]

24. Thoeni RF, Cello JP. CT imaging of colitis. *Radiology*. 2006 Sep;240(3):623-38. [PubMed]

25. McCrystal DJ, Ewing MJ, Lambrianides AL. Acquired urachal pathology: presentation of five cases and a review of the literature. *ANZ J Surg*. 2001 Dec;71(12):774-6. [PubMed]

26. Yu JS, Kim KW, Lee HJ. Urachal remnant diseases: spectrum of CT and US findings. *Radiographics*. 2001 Mar-Apr;21(2):451-61. [PubMed]

27. Coulier B, Maldague P, Bourgeois A, Broze B. Diverticulitis of the small bowel: CT diagnosis. *Abdom Imaging*. 2007 Mar-Apr;32(2):228-33. Epub 2006 Sep 12. [PubMed]

28. Gayer G, Zissin R, Apter S, Shemesh E, Heldenberg E. Acute diverticulitis of the small bowel: CT findings.

Meckel's Diverticulitis Presenting with Abdominal Pain and Angina

Abdom Imaging. 1999 Sep-Oct;24(5):452-5. [PubMed]

29. Maglinte DD, Chernish SM, DeWeese R, Kelvin FM, Brunelle RL. Acquired jejunoileal diverticular disease: subject review. Radiology. 1986 Mar;158(3):577-80. [PubMed]