

Forensic Identification of Endodontically Treated Teeth after Heat-Induced Alterations: An *In Vitro* Study

 Aashray PATEL,  Vaishali PAREKH,  Niraj KINARIWALA,  Abraham JOHNSON,
 Mona Somani GUPTA

ABSTRACT

Objective: The study aimed to highlight the relationship between forensic science and endodontics by illustrating CBCT records can be used as legal evidence for forensic analysis and evaluate the effect of elevated temperature on the endodontically treated teeth.

Methods: The present study was conducted on 40 extracted permanent mandibular premolars, which were divided into two groups based on predetermined incineration temperature: Group I - 400°C & Group II - 800°C subjected for 15 minutes holding time in a digital burnout furnace. The root canal treatment was performed for both the groups and a Pre-incineration CBCT scan was taken for both the groups as an ante-mortem data. Following heating analysis, root canal treated teeth were examined using a stereomicroscope at 20x resolution to evaluate the morphological changes. The post-incineration CBCT scan was taken as the post-mortem record for each group. Both ante-mortem records and post-mortem records were compared for the forensic analysis.

Results: The endodontically treated teeth display a series of macroscopic and stereo-microscopic changes for each temperature scale. The CBCT records identify the thermal stress-induced 3D alterations in the gutta-percha filled teeth.

Conclusion: Knowledge of changes in human dentition and traces of the endodontically treated teeth can help forensic experts for the identification of the fire victims.

Keywords: Cone-beam computed tomography, forensic dentistry, forensic identification, incineration, root canal therapy, stereomicroscope

Please cite this article as: Patel A, Parekh V, Kinariwala N, Johnson A, Gupta MS. Forensic Identification of Endodontically Treated Teeth after Heat-Induced Alterations: An *In Vitro* Study. *Eur Endod J* 2020; 3: 271-6

From the Department of Conservative Dentistry and Endodontics (A.P. ✉ patel.aashray@gmail.com, V.P., N.K., M.S.G.), Karnavati School of Dentistry, Gujarat, India; Department of Forensic Odontology (A.J.), School of Forensic Science, National Forensic Sciences University, Gujarat, India

Received 29 June 2020,
Accepted 27 October 2020

Published online: 07 December 2020
DOI 10.14744/eej.2020.37450

This work is licensed under a Creative Commons Attribution-NonCommercial 4.0 International License.



HIGHLIGHTS

- This CBCT study highlights the relationship between forensic science and endodontology by illustrating that CBCT records can be used as legal evidence for forensic analysis by observing the macroscopic and stereomicroscopic changes at elevated temperature on endodontically treated teeth.
- The CBCT records identify the three-dimensional changes in the root canal obturated teeth after incineration.
- The endodontically treated teeth showed a change in color, as well as the morphological structure of the tooth, observed under a stereomicroscope.
- No significant alterations in the root and root canal morphology were observed even at elevated temperatures (up to 800° C). Thus it enables the forensic expert to easily compare both anti-mortem & post-mortem records for the forensic identification of the fire victims.

INTRODUCTION

Forensic odontology is a unique discipline credited to the pioneer of forensic odontology, Dr. Oscar Amoeda (1). Forensic odontology is the application of dental science to legal investigations, mostly by recognizing human remains based on dental records, that involves identifying the victim. Forensic specialists examine incidents regarding excessive temperatures (e.g., aircraft crashes, environmental catastrophes, and house fires). As such, the understanding of tissue changes from high temperatures in forensic scenarios can be better understood with experimental studies (2).

As teeth are the hardest structure of the human body, and are non-flammable, they are the most

likely to remain intact in scenarios where the body has become unrecognisable (3). Over the past few decades, the root canal treatment has become a common part of dentistry. Due to the in-

creasing incidence of litigation around the world, accurate documentation of dental procedures has become more important over time (2, 4). Forensic identification performed by comparing the state of dentition with post-mortem dentition. This makes it possible to identify the individuals or human remains based not only on their morphological characteristics but also on the dental treatment records such as root canal therapy (5).

With the recent developments in the endodontic imaging technology, the endodontic research and practice are at the core of extending knowledge on root and root canal anatomy (6). In this context, the endodontic cone-beam computed tomography (CBCT) records of the root canal anatomy and post-treatment provide particularly rich sources of the characteristics that promote individualization.

To date, limited studies have been done on the 3-D technology using the CBCT for the forensic analysis of the endodontically treated teeth in human identification. Hence, the present study aimed to highlight the relationship between forensic science and endodontics by illustrating CBCT records as legal evidence for forensic analysis and observing the macroscopic and stereo-microscopic changes at elevated temperature on the endodontically treated teeth.

MATERIALS AND METHODS

In this research, 40 intact human permanent mandibular premolars extracted for orthodontic purposes were collected and cleaned with an ultrasonic scaler (Satelec, Acteon, France). An access opening was performed using an endo-access and an endo-Z bur (Dentsply Maillefer, Ballaigues, Switzerland). The patency of the canal was verified using a size 10 K file (Mani, Inc., Tochigi, Japan). The working length was determined using a digital radiographic method (Vista Scan Mini Easy, H341139151, Dürr Dental, Germany). Digital periapical images were recorded using a photostimulable phosphor plate (PSP) of "size 2" and X-ray generator operated at 70 kVp and 8 mA and an image exposure time of 0.18 seconds. After that the exposed phosphor plates were scanned in vistascan mini easy machine immediately after exposure. Image recording was set at a 40-mm pixel size, 14-bit grayscale, and 12.5 lp/mm spatial resolution in DBSWIN imaging software for measuring working length.

The chemomechanical preparation was performed with the Hero Shaper (Micro-Mega, Besançon, France) rotary file system in all the samples, and the apical enlargement was done up to 25/06%. Root canal irrigation was performed using alternating 5.25% sodium hypochlorite (NaOCl) and normal saline. All the teeth were obturated using gutta-percha with a single cone obturation technique using calcium hydroxide based root canal sealer (Sealapex, Kerr Corporation, California, USA). The post-endodontic restoration was performed with a Nano-hybrid composite (Tetric-N-Ceram, Ivoclar Vivadent AG, Schaan, Liechtenstein).

The 40 extracted permanent mandibular premolars were divided into two groups of 20 each ($n=20$) based on incinerating at specific elevated temperatures:

GROUP I: 400°C for 15 minutes

GROUP II: 800°C for 15 minutes

The pre-incineration CBCT images of all the samples were taken by the KAVO 3D system (KaVo Dental, Biberach, Germany) as an ante-mortem record (Fig. 1).

Teeth of specific subgroups were placed on a ceramic plate in a digital burnout furnace (Dentsply Ney Vulcan 3-550 multi-stage programmable burnout oven, USA) and subjected to the respective predetermined temperature, 400°C and 800°C with an incremental frequency of 30°C/minute for 15 minutes holding time for each group. Teeth were allowed to cool to room temperature after being removed from the burnout furnace.

All the specimens were then placed under a stereomicroscope (Carl Zeiss Stemi DV4 Stereo Zoom Microscope, Jena, Germany) at 20x resolution to evaluate the morphological changes. The post-incineration CBCT images were taken for all the samples as the post-mortem records. Both ante-mortem and post-mortem records were compared morphologically and radiologically for the forensic purposes. The incinerated endodontically treated teeth were examined with the naked eye, stereomicroscope, and CBCT records for forensic analysis to evaluate the changes taking place on the root canal obturated teeth.

RESULTS

The impact of elevated temperatures on the root canal obturated teeth was identified morphologically and radiographically under stereomicroscope and CBCT, respectively.

Macroscopic analysis of the color changes of the endodontically treated teeth is given in Figure 2.

- At 400°C: Root canal treated samples showed dark-brown to blackish discoloration (Fig. 2a).
- At 800°C: The color of the endodontically treated teeth changes to a frosty white appearance (Fig. 2b).

Stereomicroscopic analysis of the morphological changes of the endodontically treated teeth is given in Figure 3 and Figure 4.

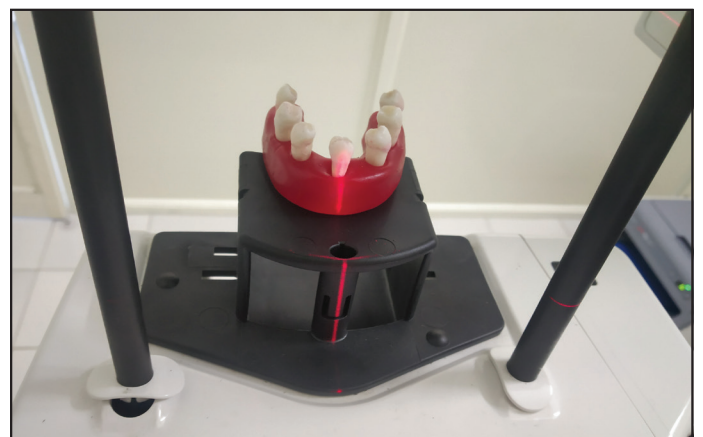

Figure 1. Pre-incineration CBCT of the samples




Figure 2. (a), (b) Macroscopic analysis of the color changes of the endodontically treated teeth seen using the naked eye when heated at predetermined elevated temperature, 400°C and 800°C respectively




Figure 3. (a), (b) Stereo-microscopic analysis of the elevated temperature on the endodontically treated teeth at 400°C

- At 400°C: Teeth remains intact except in one case where the crown portion gets dislodged from the root portion. The crown and root portions showed the horizontal and vertical fracture lines. The composite restorations have undergone marginal retractions (Fig. 3).
- At 800°C: Teeth became very fragile when subjected to 800°C. The crown was displaced from the root with the horizontal and vertical crack lines present on the root surface. Most of the cracks were found in the region of

the dentin-enamel junction (DEJ). In contrast, the root portion remains intact. At this temperature, the dentinal surface shows a bluish-grey color change. The gutta-percha remains intact which can be visible through the fragmented portion of the crown under a stereomicroscope (Fig. 4).

CBCT evaluation of the ante-mortem and post-mortem records of the endodontically treated teeth are illustrated in Figure 5 and Figure 6.

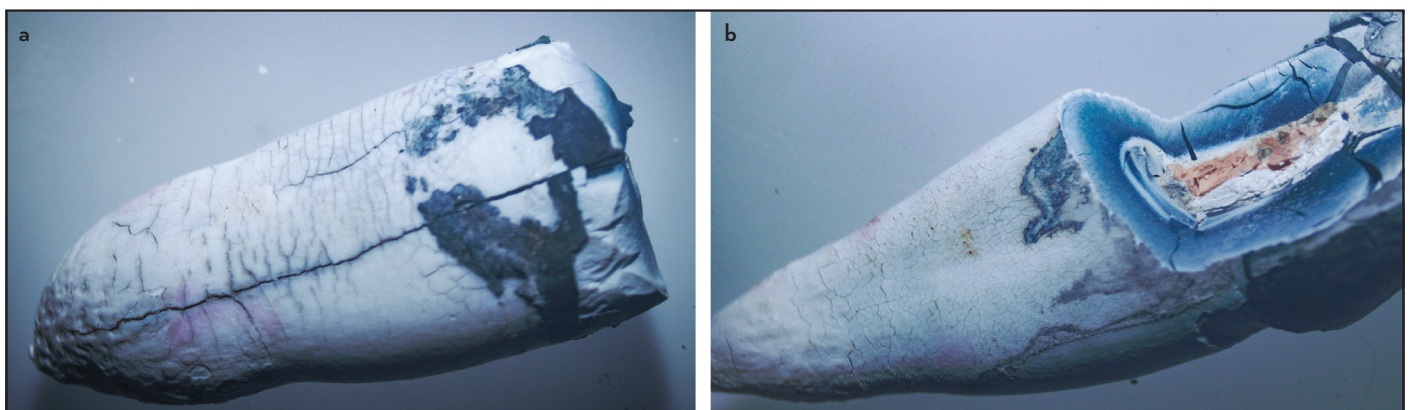


Figure 4. (a), (b) Stereo-microscopic analysis of the elevated temperature on the endodontically treated teeth at 800°C

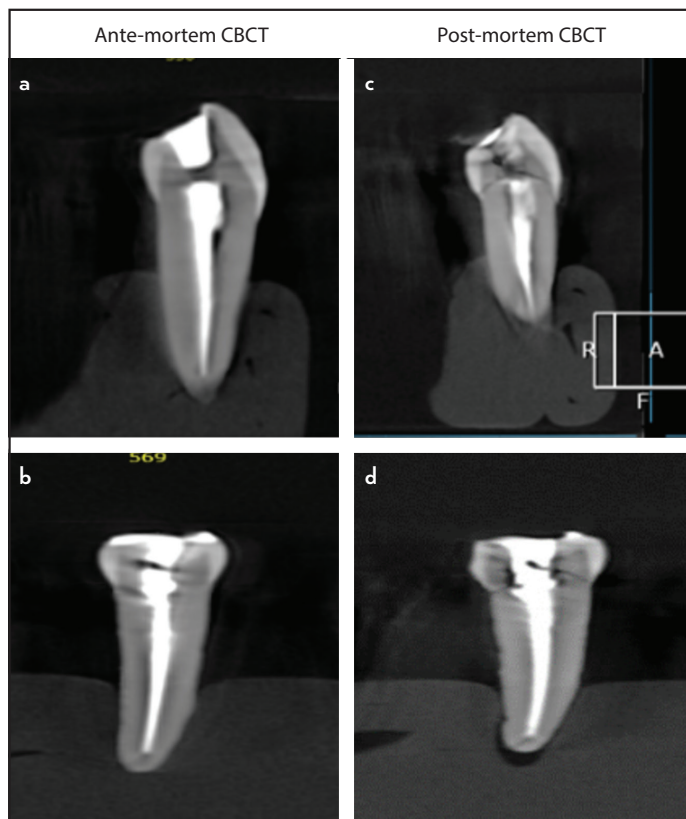


Figure 5. CBCT evaluation of the ante-mortem CBCT records (a, b) and the post-mortem CBCT records (c, d) of the endodontically treated teeth for forensic analysis at 400°C

- At 400°C: Comparing the ante-mortem CBCT (Fig. 5a, 5b) with the post-mortem CBCT (Fig. 5c, 5d), the gutta-percha shows minimal shrinkages, and minimal irregularity is seen in its radio-opacity. In one of all the samples, the composite restorations was dislodged from the crown portion of the tooth with the visible crack lines.
- At 800°C: Voids were seen without dissolution of the gutta-percha showing honeycomb appearance. The composite restorations were shattered off the teeth. On comparing the ante-mortem CBCT records (Fig. 6a, 6b) and the post-mortem CBCT records (Fig. 6c, 6d), there were no significant alterations observed in the root and root canal morphology at such elevated temperatures. Of note, the gutta-percha tends to remain intact without inducing significant alterations at 800°C temperature. These results provides the information which can enable a forensic expert to easily compare both the ante-mortem and the post-mortem records for forensic analysis of the root canal treated teeth.

DISCUSSION

Forensic dental analysis of the burns victims is difficult due to total loss of soft tissues. In such situations, forensic odontology is of importance in the medico-legal investigations because the dental remains may prove beneficial as they are extremely hard and can withstand temperatures to a certain extent. Teeth that are exposed to high temperatures are not only able to help them understand the conditions around the fire, but

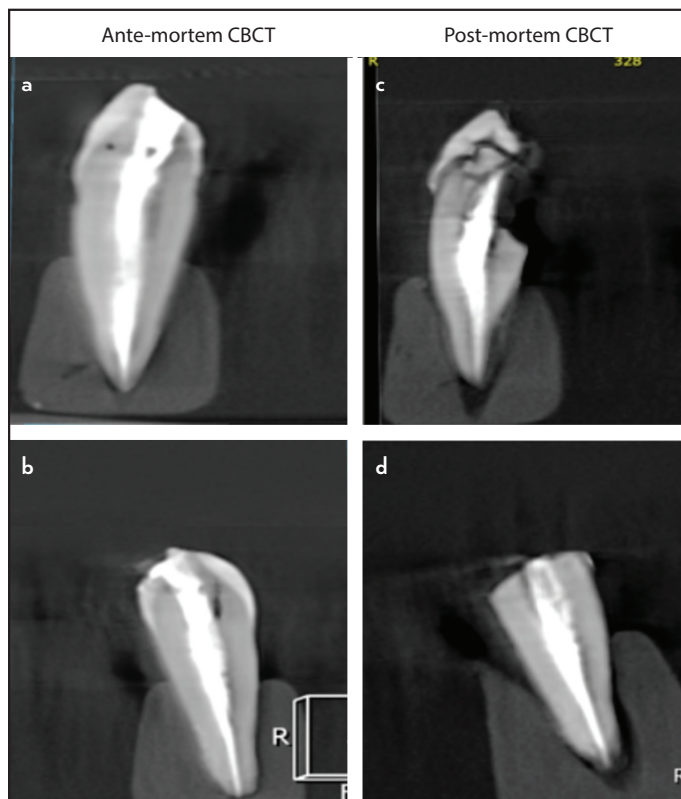


Figure 6. CBCT evaluation of the ante-mortem CBCT records (a, b) and the post-mortem CBCT records (c, d) of the endodontically treated teeth for forensic analysis at 800°C

also to provide temperature information (7). The characteristic outline of the teeth and root restorations, even the endodontic procedures, can also be readily detected by the examination of radiographs. It has also been noted that the color of the teeth is a reliable indicator of their relative fragility. This supports the previous research, which suggests that the blackened teeth are less fragile in comparison with remains than grey or white color teeth (2). Information of charred human dentition and traces of filling materials will indeed aid in the forensic examination of burnt dental remains (8).

In this analysis, the teeth were subjected to two different temperatures of 400°C and 800°C, simulating temperatures for various fire incidents. The human body is exposed to distinct temperatures during a fire crash. Incidents such as the burning of gasoline occur at around 800-1000°C, deceased cremation happens at around 760-983°C and domestic fires of up to 649°C (9). The temperature of fires depends on different factors, including whether the place of the incident is an open or closed space, the duration of the combustion, the quality of the oxidant and the materials used to stop the fire (10). In the previous studies by Gupta et al. (11) and Merlati et al. (7), it had been observed that at 500°C, that teeth showed multiple small fracture lines in the crown portion and appeared dark grey, and the root was still intact. At 600°C, the samples were greyish at the coronal portion, the crowns were disintegrated, and the enamel fragments were detached. The root portion appeared brownish with minute cracks. It was also noted that at 700°C, the color of teeth turned into dark bluish at the crown portion with the prominent fracture lines, whereas the root

portion showed whitish in color with multiple small fracture lines, and at 900°C, the enamel portion of the crown popped out like a crown with numerous fracture lines in the root portion. Thus, 400°C and 800°C temperature settings were taken into consideration to assess the teeth without any significant alterations at the radicular portion.

In addition to the direct visual inspection of the dental remains, the stereomicroscopic investigation is useful in evaluating the morphological changes at elevated temperature on the endodontically treated teeth. It can be beneficial to study the finer aspects of the dental tissues and a good picture in identifying the dental remains that would otherwise have gone unnoticed in the extensive fire debris, especially when only fragments of the teeth remain available for the forensic examination (8).

The application of CBCT provides valid baseline data for forensic personal identification. The cone-beam computed tomography (CBCT) records can help the forensic odontologist to identify three-dimensional changes in the root and root canal morphology, root canal filling material, and anatomical variations such as missed canals for the forensic analysis. This novel, non-invasive imaging technique helps in the proper understanding of 3D changes caused by thermal stress in endodontic teeth for forensic examination.

In our study, at 800°C, fragmentation of the crown was observed whereas the radicular portion remained intact due to the different material properties of enamel and dentin. The bursting of enamel in the cervical region and the subsequent separation of the crown from the rest of the tooth is one of the most distinctive changes in tooth structure. This phenomenon happens because of dentin contracts with a high organic and 12% water content due to dehydration when exposed to high temperatures (12). This fact imparts a definite amount of resistance to dentin as it is covered by enamel and periodontal tissue (root dentin), due to the elasticity of dentin. Whereas enamel has a high concentration of inorganic matter (96%), its mineral composition consists of significant amounts of calcium phosphate in the form of hydroxyapatite crystals. As a result, when the enamel is exposed to high temperatures, along with the collagen matrix, it loses its scarce water content, resulting in a strong contraction that induces changes in the organization of these crystals. Thus the crown gets separated, whereas the root portion remains intact in our analysis, which reduces the amount of external heat transfer from outside to the inner core of the root portion, leaving the gutta-percha unaltered with no significant changes at 800°C temperature scale.

Another aspect of gutta-percha is that it is a thermoplastic material, which is characterized by soft consistency from 60°C (melting point). The physical properties of tensile strength, stiffness, brittleness, and radiopacity depend on the organic (Gutta-percha polymer and resins/wax) and inorganic components (zinc oxide and metal sulfates) (13). At 800°C, the radiopacity of the gutta-percha is still visible because it contains a radiopacifier, barium sulphate. The atomic weight of barium is 138, which is best suited for the absorption of x-rays and having a high melting point (1580°C). Thus the endodontic treat-

ments were recognizable at 800°C for the forensic analysis. A similar situation was reported in the study by Savio et al. (14).

The clinical significance of the study is related to the forensic personal identification based on endodontic records. The role of an endodontist is to maintain the ante-mortem records for the forensic identification of an individual for future perspective. We found visual and three-dimensional CBCT changes to root canal treated teeth throughout our research due to heat changes. The root canal obturated teeth showed a shift in color and a change in the morphological structure of the tooth in our research. At 800°C, the color of the endodontically treated teeth changes to a frosty white appearance. This lightening of the dental tissues correlates to the gradual depletion of water and tissue dehydration, along with the removal of the organic compounds. This relates directly to the level of carbonization and teeth incineration process (15). There is a strong correlation between the temperature of exposure and the associated changes, and valid baseline data can be established (16). In real-life situations, this data may be used to evaluate the temperature to which the hard dental structures may have been exposed (17). As a result, a small fragmented portion of teeth can be distinguished from burn's remains, and an accurate estimate of the exposure temperature can be made (18).

In addition to comparing the ante-mortem and the post-mortem radiograph images, accurate and relevant ante-mortem dental records can be used to classify the individuals who have undergone a surgical or non-surgical root canal treatment on the basis of the post-mortem elemental analysis of the obturation material. This database of elementary fingerprints of the root canal filling materials can also be used as a reference for the forensic odontologists (19).

Teeth and dental treatments have a wide number of characteristics that alone, or in combination, can contribute to a positive identification. At times, the root anatomy remains unaltered in certain flash fire cases leaving the tooth broken off at the gingival margin. However, the roots are protected by the insulating properties of the maxilla or mandible. The roots are unique in their anatomy, and the obturating material can provide positive information in forensic identification. A systematic approach in a forensic dental investigation, with the help of an endodontist, can prevent the loss of potential information about the obturation on the endodontically treated teeth (1, 19).

Since this is an *in vitro* study, it cannot fully replicate the *in vivo* conditions that occur in real-life incidents due to defense from the adjacent tissues and bone covering the tooth structure. As the tooth specimens have been removed and cooled to room temperature, the root canal filling content has been exposed to the controlled thermal conditions.

CONCLUSION

The implementation of the 3D technological advances offers a more accurate method for assessment of the root and root canal anatomy for the forensic human identification. Our results indicate that following exposure to elevated temperatures of up to 800°C, the root canal treated teeth will provide

a link of forensic evidence, suggesting that this information could be used as a basis of comparison to identify the victims of the fire accidents.

Disclosures

Conflict of Interest: No conflict of interest for this study.

Ethics Committee Approval: The current research does not contain any studies with human participants and does not require ethical committee approval.

Peer-review: Externally peer-reviewed.

Financial Disclosure: This study has received no financial support.

Authorship contributions: Concept – A.P., V.P.; Design – A.P., A.J.; Supervision – V.P., N.K., M.S.G.; Funding - None; Materials - M.S.G., A.P.; Data collection &/ or processing – V.P., A.P., A.J.; Analysis and/or interpretation – A.P., N.K., M.S.G.; Literature search – A.P., N.K.; Writing – A.P.; Critical Review – A.J., V.P.

REFERENCES

- Delattre VF. Burned beyond recognition: systematic approach to the dental identification of charred human remains. *J Forensic Sci* 2000; 45(3):589–96.
- Reesu GV, Augustine J, Urs AB. Forensic considerations when dealing with incinerated human dental remains. *J Forensic Leg Med* 2015; 29:13–7.
- Rothwell BR. Principles of dental identification. *Dent Clin North Am* 2001; 45(2):253–70.
- Silva RF, Franco A, Picoli FF, Nunes FG, Estrela C. Dental identification through endodontic radiographic records: A case report. *Acta Stomatol Croat* 2014; 48(2):147–50.
- Ahmed HM. Endodontics and forensic personal identification: An update. *European Journal of General Dentistry* 2017; 6(1):5–8.
- Robinson FG, Rueggeberg FA, Lockwood PE. Thermal stability of direct dental esthetic restorative materials at elevated temperatures. *J Forensic Sci* 1998; 43(6):1163–7.
- Merlati G, Savio C, Danesino P, Fassina G, Menghini P. Further study of restored and un-restored teeth subjected to high temperatures. *J Forensic Odontostomatol* 2004; 22(2):34–9.
- Pol CA, Ghige SK, Gosavi SR, Hazarey VK. Effects of elevated temperatures on different restorative materials: An aid to forensic identification processes. *J Forensic Dent Sci* 2015; 7(2):148–52.
- Phillips VM, Scheepers CF. Comparison between fingerprint and dental concordant characteristics. *J Forensic Odontostomatol* 1990; 8(1):17–9.
- Merlati G, Danesino P, Savio C, Fassina G, Osculati A, Menghini P. Observations on dental prostheses and restorations subjected to high temperatures: experimental studies to aid identification processes. *J Forensic Odontostomatol* 2002; 20(2):17–24.
- Gupta KK, Johnson A. A morphological and radiological assessment of teeth in variable incinerated temperature-An experimental study. *Journal of Punjab Academy of Forensic Medicine & Toxicology* 2020; 20(1).
- Moreno S, León M, Marín L, Moreno F. In vitro behavior of the dental tissues and some dental materials subjected to high temperatures with forensic purposes. *Colombia Médica* 2008; 39(1):28–46.
- Vishwanath V, Rao HM. Gutta-percha in endodontics - A comprehensive review of material science. *J Conserv Dent* 2019; 22(3):216–22.
- Savio C, Merlati G, Danesino P, Fassina G, Menghini P. Radiographic evaluation of teeth subjected to high temperatures: experimental study to aid identification processes. *Forensic Sci Int* 2006; 158(2-3):108–16.
- Eastwood BA, Fletcher J, Laird WR. The value of dental restorations in post-mortem identification. *J Forensic Sci Soc* 1984; 24(6):569–76.
- Bush MA, Bush PJ, Miller RG. Detection and classification of composite resins in incinerated teeth for forensic purposes. *J Forensic Sci* 2006; 51(3):636–42.
- Rötzscher K, Grundmann C, Benthaus S. The effects of high temperatures on human teeth and dentures. *Int Poster J Dent Oral Med* 2004; 6(1):213.
- O'Brien WJ. *Dental materials and their selection*. 3rd ed. Canada: Quintessence Publishing; 2002. p. 13.
- Bonavilla JD, Bush MA, Bush PJ, Pantera EA. Identification of incinerated root canal filling materials after exposure to high heat incineration. *J Forensic Sci* 2008; 53(2):412–8.