



Case Report

Brain Edema after Repeat Gamma Knife Radiosurgery for a Large Arteriovenous Malformation: A Case Report

Joo Whan Kim¹, Hyun-Tai Chung¹, Moon Hee Han²,
Dong Gyu Kim¹ and Sun Ha Paek^{1*}

Departments of ¹Neurosurgery, ²Radiology, Seoul National University Hospital, Seoul 03080, Korea

Brain edema due to venous thrombosis following stereotactic radiosurgery for a cerebral arteriovenous malformation (AVM) has rarely been reported. We report a patient with a large AVM in the eloquent area, and brain edema developed in this area after repeat Gamma knife stereotactic radiosurgery (GKRS). An 18-year-old female presented with a 4-year-history of persistent headache. Magnetic resonance imaging and transfemoral carotid angiogram revealed a high-flow large AVM in the left parieto-occipital area. Brain edema developed and aggravated patient's symptoms after time-staged GKRS. The cause of edema was thought to be the failure of the surrounding venous channels to drain the venous flow from the normal brain and the drainage was hampered by the persistent shunt flow from the AVM, which was due to the thrombosis of one huge draining vein of the AVM. The microsurgical resection of the AVM nidus eliminated shunt flow and completely normalized the brain edema. Microsurgical resection of the AVM nidus completely normalized the brain edema due to thrombosis of a draining vein of an AVM develops after SRS.

Key words: Intracranial Arteriovenous Malformations, Radiosurgery, Brain Edema

INTRODUCTION

For several decades, stereotactic radiosurgery (SRS) such as gamma knife radiosurgery (GKRS) has been increasingly utilized for the management of arteriovenous malformations (AVMs) located in the eloquent area of the brain. However, in the case of large AVMs, their complex vascular structures and hemodynamic characteristics make it difficult to safely treat them without overt risks [1-3]. Several studies have showed disappointing results with

a low obliteration rate and a high incidence of radiation-related complications when treating large AVMs [4, 5]. The majority of these radiation-related complications are radiation necrosis, cyst formation, hemorrhage, an increased frequency of seizure, arterial stenosis, etc. [6]. Han et al [4] reported that by using a reduced radiation dose, the obliteration rate of small AVMs was good with a good outcome, but the outcome of large AVMs showed a low obliteration rate. To overcome this problem, several tactics such as the time staged SRS and the staged volume SRS have been developed to reduce the dose-volume problems when treating large AVMs [7]. Unexpected severe radiation-related complications have sometimes been reported even with these methods. As one of these complications, brain edema has been occasionally reported to cause rather miserable consequences after SRS for the management of large AVMs. Several reports have

Received April 25, 2016, Revised June 8, 2016,
Accepted June 16, 2016

*To whom correspondence should be addressed.
TEL: 82-2-2072-3993, FAX: 82-2-744-8459
e-mail: paeksh@snu.ac.kr

suggested venous hypertension due to venous thrombosis as one of the culprits to cause the brain edema or hemorrhage after SRS, based on the clinical and radiological evidence [8-10]. Here we report on a case of an 18-year-old female patient with a large AVM in the eloquent area, and brain edema developed after repeat SRS, and the microsurgical resection of the AVM nidus completely normalized the brain edema.

CASE REPORT

An 18-year-old female presented with a 4-year-history of persistent headache. She had neither visual symptoms nor a visual field defect. Magnetic resonance imaging (MRI) revealed a high-flow large AVM in the left parieto-occipital lobe (Fig. 1A). The AVM had a nidus with a diameter greater than 5 cm at its greatest dimension. The transfemoral carotid angiogram (TFCA) revealed multiple, tortuous feeding arteries and dilated draining veins that showed the high shunt flow of an AVM. Considering high risk of microsurgical resection, we decided the patient should undergo time-staged gamma knife radiosurgery (GKRS) with a 3-year

interval. A marginal dose of 13 Gy was delivered to 24.5 cc of the AVM nidus at the 50% iso-dose line for the initial GKS. A follow-up TFCA taken 3 years after the first GKS revealed the residual AVM nidus with sustained dilated draining veins towards the superior sagittal sinus (SSS) and the transverse sinus (TS) (Fig. 2). A repeat GKS was performed as planned. A marginal dose of 15 Gy was delivered to 17cc of the residual AVM nidus at the 50% iso-dose line for the repeat GKS. Three years later, the patient complained of severe and progressive headache despite of a high dose of steroid. A follow-up brain MRI showed high signal intensity changes in the left fronto-parieto-occipital area and brain swelling (Fig. 3A, B). A TFCA revealed a slightly decreased size of the residual AVM nidus and the disappearance of the large draining vein from the AVM to TS which had been shown at the arterial phase in the previous study (Fig. 3C). High shunt flow through this large vein was disappeared due to partial obliteration of the AVM. This draining vein was shown at the venous phase, which implied the drainage of the normal brain areas. However, the distal part of the vein was not shown due to thrombosis and this could lead to the compromise of the venous drainage of the

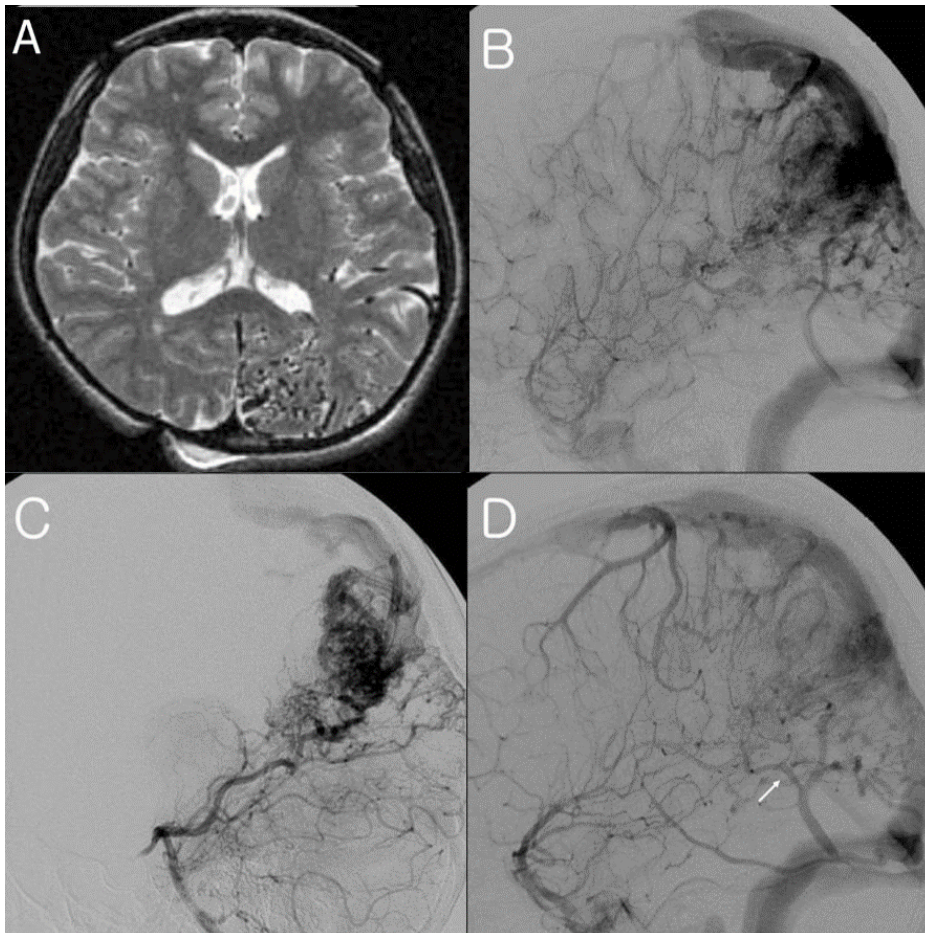


Fig. 1. Magnetic resonance imaging (MRI) revealed a high-flow large AVM in the left parieto-occipital lobe. (Fig. 1A) The AVM had a nidus with a diameter greater than 5 cm at its greatest dimension. The transfemoral carotid angiogram (TFCA) revealed multiple, tortuous feeding arteries and dilated draining veins that showed the high shunt flow of an AVM.

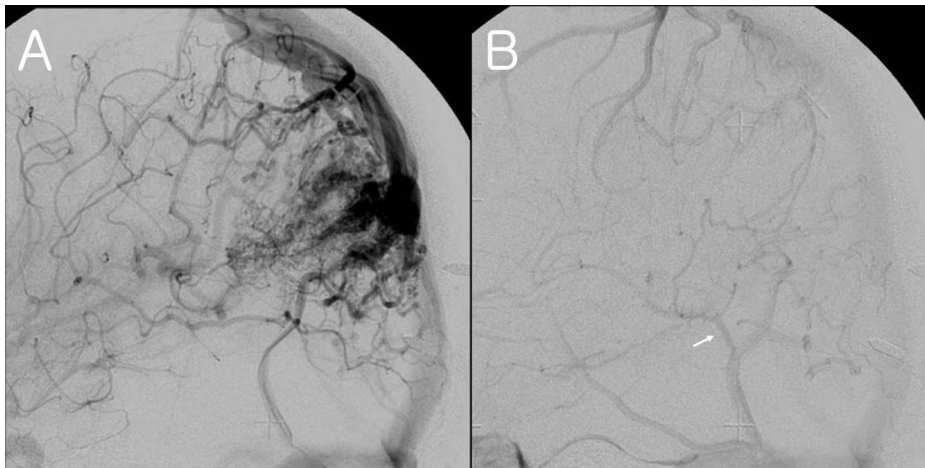


Fig. 2. Follow-up angiograms obtained 3 years after the first GKS. The lateral projection (A) showed the nidus of the AVM decreased and the venous phase (B) showed a normal drainage (white arrow).

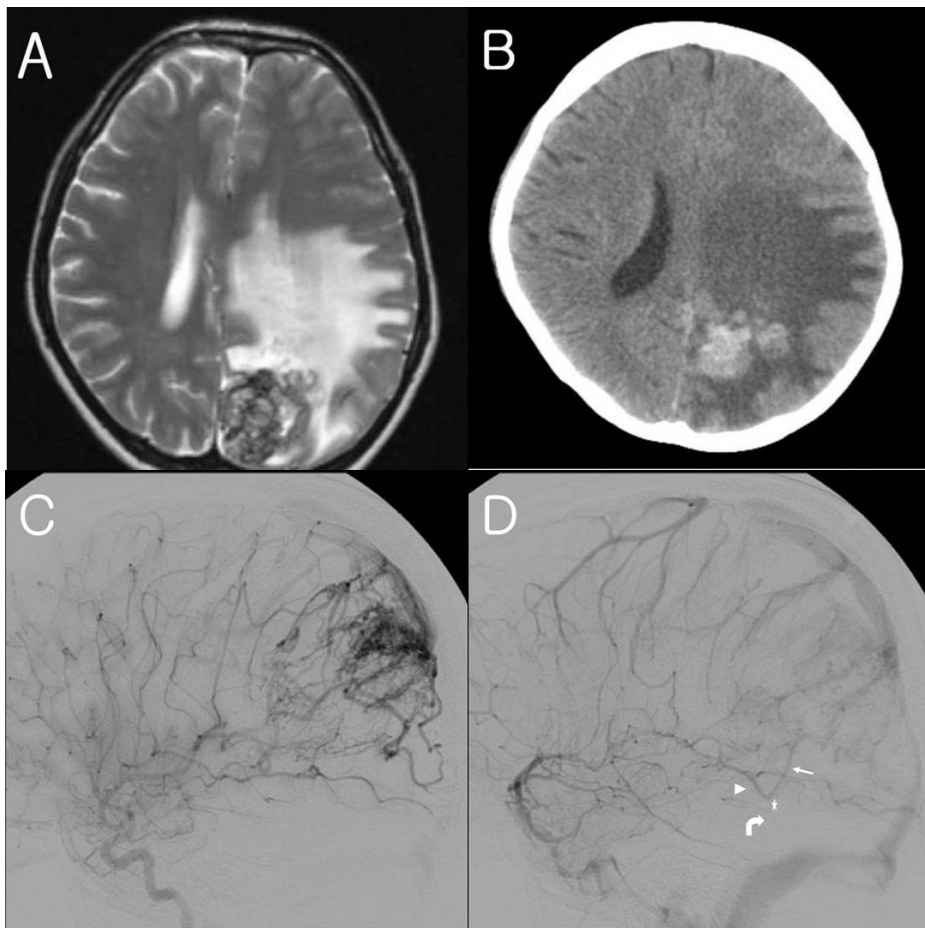


Fig. 3. After the patient complained of severe headache at 3 years after the 2nd GKS, magnetic resonance imaging (MRI) scan (A) show extensive brain edema. The follow up computed tomography (CT) scan (B) showed the progression of the brain edema. The angiograms (C) show a slight decrease of the size of the AVM compared with the previous angiograms and the disappearance of the whole draining vein of the AVM to the TS at the arterial phase. But at the venous phase (D), the proximal part of the vein of the AVM to the TS and a normal drainage were shown, but the distal part of this vein (white arrow) was not shown and the blood staining of the AVM nidus.

normal brain areas. (Fig. 3D). Thus, the cause of the brain edema was thought to be the consequence of the failure of draining the venous flow from the normal brain areas due to venous thrombosis. This edema was persistent and it was assumed that the compensation of collateral venous drainage was hampered by the persistent shunt flow of the residual AVM nidus which induced

venous hypertension.

The patient had been treated with steroid for eight months, but its effect was minimal and the steroid was ineffective to improve her symptoms of increased intracranial pressure. With full discussion with the patient and her family regarding the possible neurological deterioration due to the increased intracranial

pressure and a possible postoperative neurological deficit, microsurgical resection was chosen to control the increased intracranial pressure by eliminating the persistent shunt flow. The AVM was totally removed and the severe preoperative brain edema surrounding the AVM nidus completely dissolved. Grade IV right hemiparesis and right homonymous hemianopsia with mild dysphasia developed after surgery. The right hemiparesis and mild dysphasia gradually improved over time. The TFCA performed after microsurgical resection revealed the complete disappearance of the AVM nidus in the left parieto-occipital lobe (Fig. 4A, B). After two and half years, she has completely recovered from the weakness and dysphasia with a residual deficit of the right homonymous hemianopsia.

DISCUSSION

The post-radiosurgery imaging (PRI) changes after SRS for an AVM, which show high intensity signal change of the white matter on T2-weighted MRI, have been reported in the several studies with high incidence [4, 11, 12]. Han et al [4] reported that 98 (62%) of 157 patients had PRI changes after GKRS for an AVM and severe adverse symptoms developed in 30 patients among the 98 patients with PRI changes.

There are two possible causes to develop PRI changes after SRS for an AVM. First, the brain injury by radiation effect to parenchyma adjacent to the AVM could be considered. Han et al [4] reported that PRI changes was higher in the medium AVM group that had received radiation dose near the Kjellberg 1% isoeffective line for brain necrosis. Miyawaki et al [12] showed that 22% of the incidence of radiation necrosis requiring surgical resection in the study which reported the incidence of PRI changes was 72% after SRS for the large AMVs

Another possible cause is the hemodynamic changes after SRS for an AVM. The PRI changes develop in not only the vicinity of the lesions, but remote brain areas far from the lesions [11]. This changes are also generally transient and more common after SRS for an AVM than that for tumors [10]. So, the hemodynamic changes might be considered as the cause of these PRI changes.

Based on radiologic evidence, thrombosis of the draining veins of an AVM has been suggested to induce these hemodynamic changes after SRS. Pollock [10] and Chapman et al [9] suggested the concept of occlusive hyperemia that thrombosis of the draining vein after SRS as the cause of these hemodynamic changes which compromises the normal venous drainage of the brain with resultant congestion and swelling.

In the present case, both these two causes could be assumed to develop the brain edema after SRS for the AVM. As was suggested above, SRS for a large AVM has a chance to develop the radiation necrosis inducing brain edema requiring surgical resection. However, the vein occlusion was certainly identified at the distal part of the large draining vein of the AVM on TFCA of our patient when the symptoms developed (Fig. 3D). This large draining vein had also been shown at the late venous phase in the previous TFCA before the repeat GKRS (Fig. 2B). It was reasonable to assume that this large draining vein was in charge of the drainage of the normal brain areas. As a consequence, the thrombosis of the draining vein could induce the compromise of the venous drainage of the normal brain areas. This hemodynamic changes was considered as the more contributing cause of our patient's brain edema.

The underlying mechanism of venous thrombosis after SRS for an AVM has been previously reviewed in the literature. The impaired venous microcirculation induced by radiation-induced vascular changes after SRS for an AVM could stagnate the blood

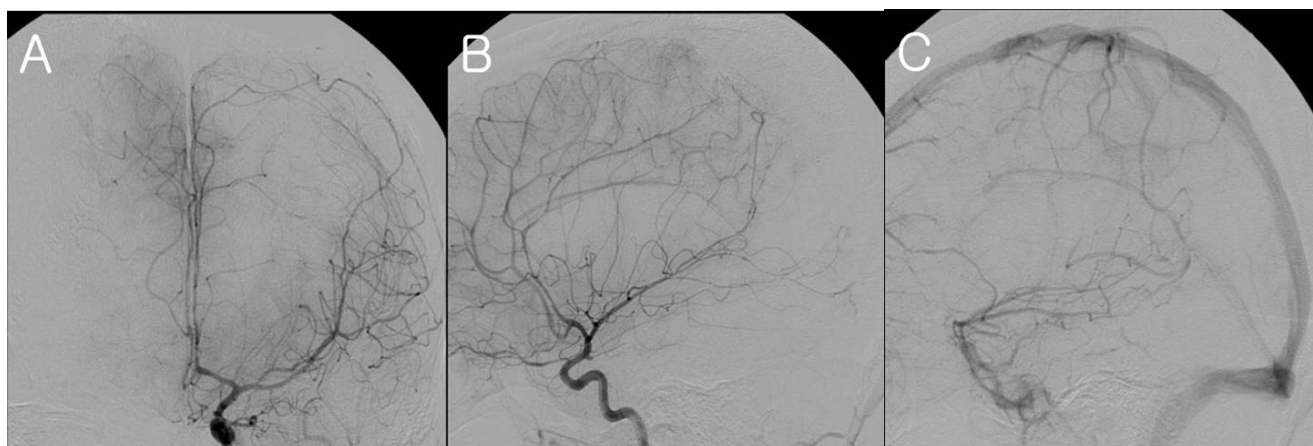

Fig. 4. After microsurgical resection of the AVM, the angiograms (A-C) showed total removal of the AVM, implying no shunted blood.

flow and produce clot formation in large draining veins [8, 10, 13]. In the present case, this mechanism was supported by the radiologic evidence that showed the occlusion of distal part of the draining vein due to the decreased flow caused by partial obliteration of the AVM.

The effect of repeat SRS on thrombosis of major draining veins from an AVM is unclear. However, considering the hypothetical underlying mechanism of the formation of venous thrombosis as affected by radiation, repeat SRS could increase the risk of venous thrombosis of an AVM due to the cumulative adverse radiation effects.

Such venous thrombosis caused by SRS for an AVM could result in various consequences, including fatality (Table 1). Patient 3 in Chapman's cases showed progressive neurological deterioration and the patient died of massive brain swelling and the patient received only non-surgical medical treatment [9, 10]. It is certainly necessary to discuss the policy of treatment because of the disastrous situation. But the previous studies did not concretely discuss the rationale for deciding the policy of treatment for brain edema caused by thrombosis of draining veins.

For the appropriate treatment of such a complication, it is necessary to understand the hemodynamic status of the AVM nidus of a patient who presents with brain edema due to venous thrombosis after SRS. It is suggested that venous compromise due to thrombosis could induce the development of collateral venous drainage being capable of restoring the venous flow [11]. However, in the present case, the brain edema could not be improved for a prolonged period. The possible explanation for persistent brain edema is that the high flow of the residual AVM might disturb the development of collateral venous channel. Thus, the compensation for abnormal venous drainage failed and the brain edema was persistent.

In case reports of Table 1, three of all the AVM nidi were completely obliterated. The AVM of patient 1 became smaller and it was expected to be obliterated because of its small size (2 cm). So, as

the obliteration of an AVM nidus progresses, such complications might be improved. Exceptionally, patient 3 did not recover from the brain edema despite the total obliteration of the AVM nidus. In that case, the hemodynamic changes caused further occlusion of another vein and authors thought that the mechanism of further occlusion was obscure.

In the present case, the size of the large AVM nidus slightly decreased, but it did not disappear even three years after repeat GKRS. The venous flow from the normal brain was hampered by the persistent shunt flow from the large residual AVM, and this caused persistent and severe brain edema and it might have endangered the patient's life. Therefore, assertively eliminating the shunt flow from the AVM nidus should be considered to resolve the disturbed normal venous drainage.

Another important point of deciding the policy of treatment is the time to eliminate the shunt flow by removal of the AVM nidus. Some large AVMs might be incompletely obliterated and it takes more time to obliterate a large AVM after SRS and even repeat SRS. Thus, brain edema could not be resolved by the compensation with venous collateral drainage due to persistent high flow of the residual AVM. Beside, this might make an accumulation of venous flow of normal brain areas, which could aggravate the brain edema. The follow up CT scan showed progression of the brain edema despite of steroid administration. So, prompt treatment should be performed to resolve such potentially fatal brain edema.

Microsurgical resection or endovascular embolization could be considered to eliminate shunt flow from the residual AVM and to normal the venous drainage system. It is difficult to completely obliterate AVMs with endovascular embolization alone, especially for large AVMs having complex vasculature [14]. Moreover, as a mentioned above, radiation necrosis could have a possibility to develop brain edema after SRS for a large AVM. Complete microsurgical resection of a residual AVM nidus could control the high intracranial pressure as well as normalize the abnormal hemodynamic change. Thus, surgical removal of a AVM nidus

Table 1. The case reports of extensive brain edema after radiosurgery

	<i>Size</i>	<i>Location</i>	<i>Impaired vein</i>	<i>Nidus</i>	<i>Treatment</i>	<i>Result</i>
Pollock, 2000						
Patient 1	small	F, Rt	Varix	D	Conservative	Stable
Patient 2	large	Cbll, Rt	Bilateral TS, SS	O	Thrombolysis	Stable
Chapman et al., 2004						
Patient 3	large	F, Rt	Vein to SSS	O	Conservative	Expire
Patient 4	large	Thal, Rt	Vein to Basal vein	O	Conservative	Stable
The present case	large	PO, Lt	Vein to TS	D	Resection	Stable

Abbreviations : F, Frontal lobe; PO, Parieto-occipital area; Cbll, Cerebellum; Thal, Thalamus; SSS, Superior sagittal sinus; TS, Transverse sinus; SS, Sigmoid sinus; N, Not decrease; D, Decrease; O, Obliteration.

was considered as the appropriate management to immediately eliminate the high shunt flow of the AVM nidus. A microsurgical resection could also resolve brain edema induced by radiation necrosis [15]. In the present case, the patient had undergone microsurgical resection before falling into a more dangerous situation and she finally showed stabilization of her brain edema despite of some neurologic deficits.

CONCLUSION

Brain edema due to venous thrombosis following SRS for an AVM has occasionally been reported. We reported here on a case of 18-year-old female patient with a large AVM in the eloquent area. Thrombosis of draining vein of an AVM was considered as the main cause although radiation necrosis could not be excluded. We completely resected the AVM nidus and this normalized the brain edema. It is suggested that assertive surgical treatment should be taken into consideration when brain edema due to thrombosis of a draining vein of an AVM develops after SRS.

REFERENCES

- Hernesniemi JA, Dashti R, Juvela S, Väärt K, Niemelä M, Laakso A (2008) Natural history of brain arteriovenous malformations: a long-term follow-up study of risk of hemorrhage in 238 patients. *Neurosurgery* 63:823-829.
- Heros RC, Tu YK (1987) Is surgical therapy needed for unruptured arteriovenous malformations? *Neurology* 37:279-286.
- Söderman M, Andersson T, Karlsson B, Wallace MC, Edner G (2003) Management of patients with brain arteriovenous malformations. *Eur J Radiol* 46:195-205.
- Han JH, Kim DG, Chung HT, Park CK, Paek SH, Kim JE, Jung HW, Han DH (2008) Clinical and neuroimaging outcome of cerebral arteriovenous malformations after gamma knife surgery: analysis of the radiation injury rate depending on the arteriovenous malformation volume. *J Neurosurg* 109:191-198.
- Pan DH, Guo WY, Chung WY, Shiao CY, Chang YC, Wang LW (2000) Gamma knife radiosurgery as a single treatment modality for large cerebral arteriovenous malformations. *J Neurosurg* 93 Suppl 3:113-119.
- Izawa M, Hayashi M, Chernov M, Nakaya K, Ochiai T, Murata N, Takasu Y, Kubo O, Hori T, Takakura K (2005) Long-term complications after gamma knife surgery for arteriovenous malformations. *J Neurosurg* 102 Suppl:34-37.
- Jones J, Jang S, Getch CC, Kepka AG, Marymont MH (2007) Advances in the radiosurgical treatment of large inoperable arteriovenous malformations. *Neurosurg Focus* 23:E7.
- Celix JM, Douglas JG, Haynor D, Goodkin R (2009) Thrombosis and hemorrhage in the acute period following gamma knife surgery for arteriovenous malformation. Case report. *J Neurosurg* 111:124-131.
- Chapman PH, Ogilvy CS, Loeffler JS (2004) The relationship between occlusive hyperemia and complications associated with the radiosurgical treatment of arteriovenous malformations: report of two cases. *Neurosurgery* 55:228-233.
- Pollock BE (2000) Occlusive hyperemia: a radiosurgical phenomenon? *Neurosurgery* 47:1178-1182.
- van den Berg R, Buis DR, Lagerwaard FJ, Lycklama à Nijeholt GJ, Vandertop WP (2008) Extensive white matter changes after stereotactic radiosurgery for brain arteriovenous malformations: a prognostic sign for obliteration? *Neurosurgery* 63:1064-1069.
- Miyawaki L, Dowd C, Wara W, Goldsmith B, Albright N, Gutin P, Halbach V, Hieshima G, Higashida R, Lulu B, Pitts L, Schell M, Smith V, Weaver K, Wilson C, Larson D (1999) Five year results of LINAC radiosurgery for arteriovenous malformations: outcome for large AVMS. *Int J Radiat Oncol Biol Phys* 44:1089-1106.
- Achrol AS, Guzman R, Varga M, Adler JR, Steinberg GK, Chang SD (2009) Pathogenesis and radiobiology of brain arteriovenous malformations: implications for risk stratification in natural history and posttreatment course. *Neurosurg Focus* 26:E9.
- Yoshimoto T, Takahashi A, Kinouchi H, Mizoi K, Jokura H (1995) Role of embolization in the management of arteriovenous malformations. *Clin Neurosurg* 42:313-327.
- Foroughi M, Kemeny AA, Lehecka M, Wons J, Kajdi L, Hatfield R, Marks S (2010) Operative intervention for delayed symptomatic radionecrotic masses developing following stereotactic radiosurgery for cerebral arteriovenous malformations--case analysis and literature review. *Acta Neurochir (Wien)* 152:803-815.