




# Cardiogenic shock triggered by phaeochromocytoma crisis after an oral glucose tolerance test: a case report

Bahira Shahim <sup>1\*</sup>, Ulrika Ljung Faxén <sup>1,2</sup>, Rebecka Stern<sup>3</sup>, and Anna Freyschuss <sup>1</sup>

<sup>1</sup>Cardiology Unit, Department of Medicine, Karolinska Institutet, 171 76 Stockholm, Sweden; <sup>2</sup>Perioperative Medicine and Intensive Care Unit, Department of Medicine, Karolinska Institutet, Karolinska University Hospital, 17176 Stockholm, Sweden; and <sup>3</sup>Pulmonary Unit, Department of Medicine, Karolinska Institutet, Karolinska University Hospital, 17176 Stockholm, Sweden

Received 1 April 2019; first decision 4 June 2019; accepted 17 September 2019; online publish-ahead-of-print 11 October 2019

## Background

Phaeochromocytomas are rare catecholamine-producing tumours which typically present with comparatively benign symptoms such as headache, palpitations, sweating, hypertension, and insulin resistance. In rare cases, severe cardiac manifestations have been reported. We describe a patient who developed severe hypoglycaemia after an oral glucose tolerance test (OGTT), potentially triggering a phaeochromocytoma crisis and cardiogenic shock. To the best of our knowledge, only four other cases of hypoglycaemia after OGTT have been reported in patients with phaeochromocytoma, of which none developed a phaeochromocytoma crisis.

## Case summary

A 53-year-old woman with hypertension, dyslipidaemia, and prediabetes presented to the Emergency Department with hypoxia, hyperglycaemia, lactic acidosis, severe left ventricular dysfunction, and pulmonary oedema followed by cardiogenic shock. Onset of symptoms was only few hours after an OGTT during which she had developed severe transient hypoglycaemia. Angiography was performed due to elevated troponin levels and showed a midventricular contraction pattern typical of takotsubo. This was subsequently confirmed by cardiac magnetic resonance imaging. The patient's condition improved during the first 36 h and she was discharged home on Day 7. A positive catecholamine test prompted readmission to the Endocrinology Unit, where computer tomography confirmed the diagnosis of phaeochromocytoma. An adrenalectomy was performed, and the diagnosis was verified histopathologically.

## Discussion

The possibility of a phaeochromocytoma must be considered as a potential triggering factor in patients presenting with takotsubo cardiomyopathy, in particular, when blood glucose levels fluctuate between severe hypo- and hyperglycaemia.

## Keywords

Acute pulmonary oedema • Oral glucose tolerance test • Takotsubo cardiomyopathy • Phaeochromocytoma • Hypoglycaemia • Hyperglycaemia • Case report

## Learning points

- The possibility of a phaeochromocytoma should be considered in patients with takotsubo cardiomyopathy, particularly if occurring in connection with potentially triggering physical factors such as severely fluctuating blood glucose.
- The diagnosis of phaeochromocytoma may be easy to miss but important to keep in mind if abnormal reactions to a provocative procedure as oral glucose tolerance test.
- Multidisciplinary management and expanded testing are important in patients with takotsubo and atypical presentation.

\* Corresponding author. Tel: +46 705 347 350, Email: [bahirashahim@gmail.com](mailto:bahirashahim@gmail.com)

Handling Editor: Christian Fielder Camm

Peer-reviewers: Mohamed Hassan and Lilit Baghdasaryan

Compliance Editor: Rahul Mukherjee

Supplementary Material Editor: Peregrine Green

© The Author(s) 2019. Published by Oxford University Press on behalf of the European Society of Cardiology.

This is an Open Access article distributed under the terms of the Creative Commons Attribution Non-Commercial License (<http://creativecommons.org/licenses/by-nc/4.0/>), which permits non-commercial re-use, distribution, and reproduction in any medium, provided the original work is properly cited. For commercial re-use, please contact [journals.permissions@oup.com](mailto:journals.permissions@oup.com)

## Introduction

Phaeochromocytomas are catecholamine-producing tumours of the chromaffin cells of the adrenal medulla (80–85%) or extra-adrenal tissues, i.e. paraganglioma (15–20%).<sup>1</sup> The prevalence in the western population has been estimated to 1:4500–1700 and the annual incidence 3–8 cases/million, with 10% of phaeochromocytomas being malignant, and 10–20% familial.<sup>2</sup> Patients with phaeochromocytomas typically present with symptoms associated with excess levels of catecholamines: hypertension (98%) and the triad of headache, sweating, and palpitations (50–60%).<sup>1</sup> Phaeochromocytomas are associated with impaired glucose tolerance or even overt diabetes in 20–40% of cases. Post-operative hypoglycaemia is a well-recognized feature of phaeochromocytoma, whereas hypoglycaemia as an initial symptom seems to be very rare.<sup>3–6</sup>

More severe presentations of phaeochromocytomas, such as non-cardiogenic pulmonary oedema, acute renal failure, acute myocardial infarction, myocarditis, or other forms of acute cardiomyopathy, with or without cardiogenic shock, are described.<sup>7</sup> A catecholamine crisis is defined as acute and severe haemodynamic instability and collapse is a rare, but dreaded, complication of phaeochromocytoma. Stress or takotsubo cardiomyopathy is one of the most commonly reported cardiac complications of a catecholamine crisis.<sup>8</sup>

## Timeline

## Case presentation

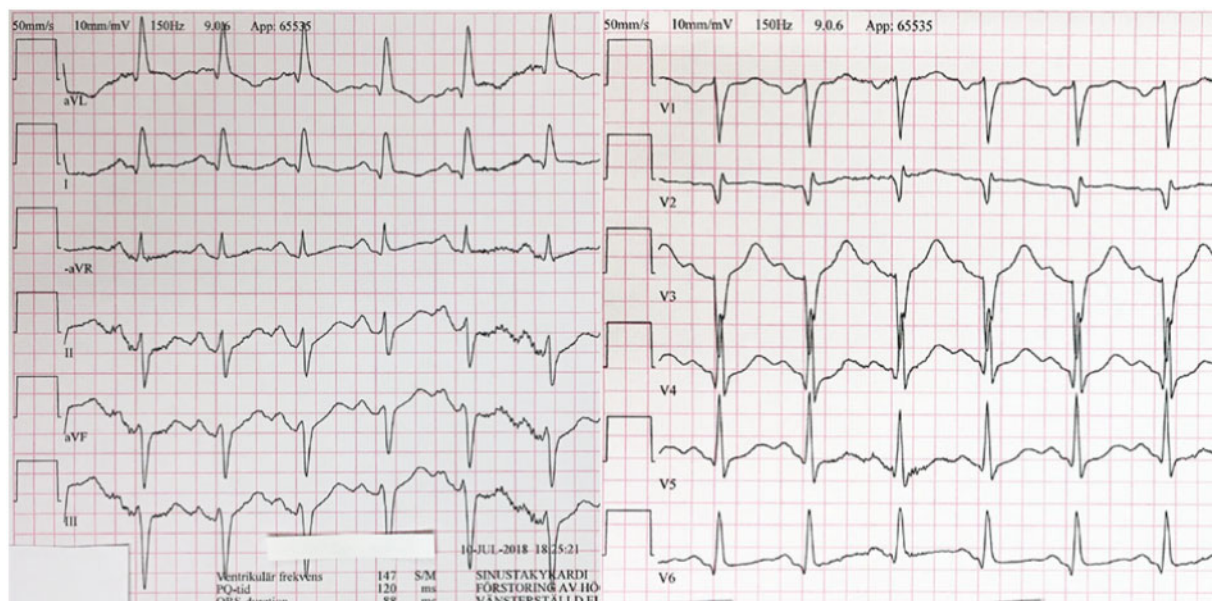
A 53-year-old Caucasian female presented to the Emergency Department (ED) with acute onset of dyspnoea, chest tightness, dizziness, palpitations, nausea, and vomiting a few hours after an oral glucose tolerance test (OGTT) during which she developed transient hypoglycaemia (P-glucose 3.4, 2.9, and 2.5 mmol/L). She improved after intake of sweetened juice and had been sent home after the OGTT performed at the primary care centre.

She was referred for the OGTT due to impaired fasting glucose (6.9 mmol/L) and borderline haemoglobin A1c (47 mmol/L; 6.4%). She had a history of hypertension, dyslipidaemia, and secondary hyperparathyroidism. She was on treatment with simvastatin 20 mg o.d., calcium carbonate/cholecalciferol 500 mg/800 IE b.i.d., metoprolol 50 mg o.d., and losartan 50 mg o.d. She did not smoke, denied excessive drinking, and exercised regularly.

On admission, she was mentally lucid, had pale skin, dyspnoea, cool extremities with weak radial pulses, and prolonged capillary refilling time. Her respiratory rate was 40 breaths/min and oxygen saturation by pulse oximetry was 80%. The pulse was regular with a heart rate of 114 b.p.m. and the blood pressure was 111/75 mmHg after administration of Ringer's acetate. Clinical examination revealed bilateral inspiratory crackles. The abdomen was soft without tenderness or palpable mass. There were no focal neurological deficits and body temperature was 37.7°C.

Blood gas analysis showed hypoxaemia (PaO<sub>2</sub> 5.3 kPa; arterial oxygen saturation 65% with 10 L/min supplementary oxygen), metabolic

Day/month	Event
Day 0	Oral glucose tolerance test is performed in the morning at the primary care centre. The patient feels unwell and hypoglycaemia is diagnosed. Discharged home after recovery.
Day 0	The patient presents a few hours later at the Emergency Department with dyspnoea and chest tightness. On evaluation, she is hyperglycaemic, has lactic acidosis, severe left ventricular dysfunction, and pulmonary oedema. Acute coronary angiography reveals a midventricular takotsubo contraction pattern with a left ventricular ejection fraction (LVEF) of 15%. She develops cardiogenic shock, hypoxia, and serum lactate is persistently elevated. Transfer to intensive care where treatment with non-invasive ventilation support, norepinephrine, insulin, antibiotics, and later levosimendan is initiated.
Day 1	LVEF has improved to 20–25%. No further need for ventilatory support or vasopressors. Confidence interval has improved from 2.1 to 3.0 L/min/m <sup>2</sup> .
Day 2	LVEF has improved to 40%. Transfer back to regular ward in the department of cardiology.
Day 4	Serum catecholamines were sent for analysis.
Day 7	Cardiac magnetic resonance imaging confirms the diagnosis of takotsubo cardiomyopathy. The patient is discharged home.
Day 17	Readmission to the department of endocrinology due to abnormal results from catecholamine tests. Pharmacological adrenergic blockade is instituted.
Day 21	Computer tomography revealed a 10 × 9 × 7 cm sized mass indicative of a left adrenal phaeochromocytoma.
Day 60	Left adrenalectomy is performed and pharmacological adrenergic blockade is stopped.
Day 64	The patient is discharged home.
Day 106	On follow-up visit, the patient is doing well.
5 months	Computer tomography, catecholamine testing, and follow-up visit scheduled.



**Figure 1** The initial electrocardiogram showed sinus tachycardia without apparent signs of ischaemia even if baseline shifting made analysis of ST-segments somewhat difficult.

acidosis (pH 7.26; PaCO<sub>2</sub> 5.0 kPa; bicarbonate 16 mmol/L; lactate 5.9 mmol/L; and base deficit -10 mmol/L), and hyperglycaemia (P-glucose 31 or 54 mg/dL). Further laboratory analyses revealed elevated cardiac troponin T (1250 ng/L, normal range 0–15 ng/L), normal C-reactive protein (<1 mg/L), leucocytosis ( $16 \times 10^9/L$ ) and acute kidney injury stage 1 (creatinine, 93  $\mu\text{mol/L}$ ; Glomerular filtration rate 39 mL/min/1.73 m<sup>2</sup>).

The initial electrocardiogram showed sinus tachycardia without specific signs of ischaemia (Figure 1). A transthoracic echocardiogram revealed hypokinesia in the mid-inferior and apical segments and a left ventricular ejection fraction (LVEF) of 15%. A pulmonary ultrasound showed multiple B-lines over more than 50% of the scanning site, i.e. indicated interstitial oedema.

The primary suspected diagnosis was acute myocardial infarction causing pulmonary oedema. However, coronary angiography disclosed normal coronaries (Figure 2) while the left ventriculogram revealed a midventricular takotsubo-type contraction pattern (Supplementary material online, Video S1). An acute chest X-ray showed considerable amount of basal opacities suggestive of pulmonary oedema and pulmonary congestion in which consolidation could not be excluded.

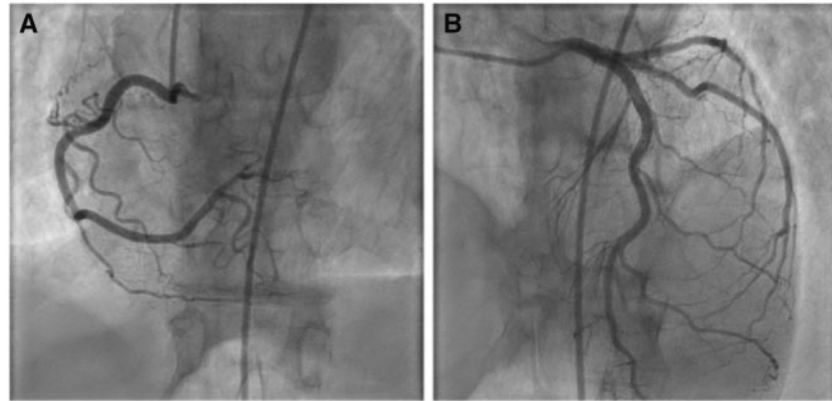
She was transferred to the intensive care unit where she developed fever (38.5°C), lactate increased, and urinary output decreased. Her heart rate was 122 b.p.m., systolic blood pressure 85 mmHg, cardiac index 2.1 L/min/m<sup>2</sup>, mean pulmonary artery pressure 23 mmHg. Norepinephrine and levosimendan were initiated as well as with non-invasive ventilatory support, antipyretics (paracetamol), and anxiolytics (morphine/midazolam). The condition improved and 24 h post-admission cardiac index was 3 L/min/m<sup>2</sup> and LVEF was 20–25% (Supplementary material online, Video S2), improving to 40–45% the following day (Supplementary material online, Video S3). She was

weaned from norepinephrine while levosimendan was continued until 24 h. Insulin therapy was initiated early due to severe hyperglycaemia. Empiric broad-spectrum antibiotic therapy (cefotaxim and later meropenem) initiated due to suspicion of sepsis was terminated upon negative cultures.

On Day 7, she underwent cardiac magnetic resonance imaging (MRI) which on Modified Look-Locker Inversion Recovery T1 maps showed mildly increased activity (Figure 3A and E) and increased extracellular volume in the midventricular regions (Figure 3B and F), together indicating mild oedema. There was hypokinesia/akinesia in the midventricular region (Figure 3C and G). No focal ischaemic or non-ischaemic scar was found (Figure 3D and H). Hence, the findings confirmed the diagnosis of a midventricular takotsubo cardiomyopathy.

S-cortisol was elevated (290 nmol/L, reference range for morning value <100) but S-renin, S-aldosterone, S-thyroid stimulating hormone, S-T3, and S-T4 were normal. Serum catecholamines were measured but the test results did not arrive until after the patient was discharged home on Day 7. Elevated levels of metanephrine (10 nmol/L, reference range <0.3 nmol/L) and normetanephrine (190 nmol/L, reference range <0.9 nmol/L) indicated phaeochromocytoma. Plasma methoxytyramine (2.4 nmol/L, reference range <0.2) and chromogranin A (37 nmol/L, reference range <6.0 nmol/L) were also increased.

The patient was immediately rehospitalized and computer tomography revealed a 10 × 9 × 7 cm sized mass indicative of a left adrenal phaeochromocytoma (Figure 4), which was also, in retrospect, visible on the cardiac MRI. Pharmacological adrenergic blockade (doxazosin) was instituted and left adrenalectomy was performed 60 days after initial admission. Histological and immune-histochemical examination revealed a phaeochromocytoma with vascular and capsular



**Figure 2** Right coronary artery (A) and left coronary artery (B), showing absence of coronary artery lesions.

invasion and fat infiltration with a Pheochromocytoma of the Adrenal gland Scaled Score (PASS) of 8. Post-operative recovery was uneventful and the patient was discharged home. She was doing well on follow-up visit 6 weeks later and has been scheduled for follow-up computed tomography and lab testing since a tumour with a PASS  $\geq 4$  has the potential of recurrence or metastasizing.<sup>9</sup>

## Discussion

We report a case of pulmonary oedema and cardiogenic shock due to takotsubo cardiomyopathy a few hours after an OGTT during which the patient developed hypoglycaemia, where the patient was later diagnosed with a pheochromocytoma. A pheochromocytoma crisis, such as in the present patient, is a life-threatening catecholamine-induced haemodynamic disturbance which in this case apparently was triggered by the severe hypoglycaemia. There are only very few reports of such complications to OGTT.

Autopsy studies have shown that significant numbers of pheochromocytomas remain undiagnosed until death and that up to 50% of these unrecognized tumours may have contributed to patient mortality.<sup>2</sup> About 20–30% of patients with pheochromocytomas are asymptomatic or have only minor signs and symptoms. Thus, the diagnosis is easily missed, often with tragic consequences.<sup>2</sup>

### Takotsubo cardiomyopathy and pheochromocytoma

It has been reported that 3% of patients with pheochromocytoma present with takotsubo cardiomyopathy. A review by Agarwal et al.<sup>10</sup> comparing 38 cases of takotsubo associated with pheochromocytoma with 254 cases of takotsubo in the absence of pheochromocytoma. In those with takotsubo associated with pheochromocytoma, complication rates were higher compared to those without pheochromocytoma including cardiogenic shock (34.2% vs. 4.2%,  $P < 0.01$ ).

Proposed mechanisms underlying catecholamine-mediated cardiomyopathy include excess sympathetic stimulation with increased

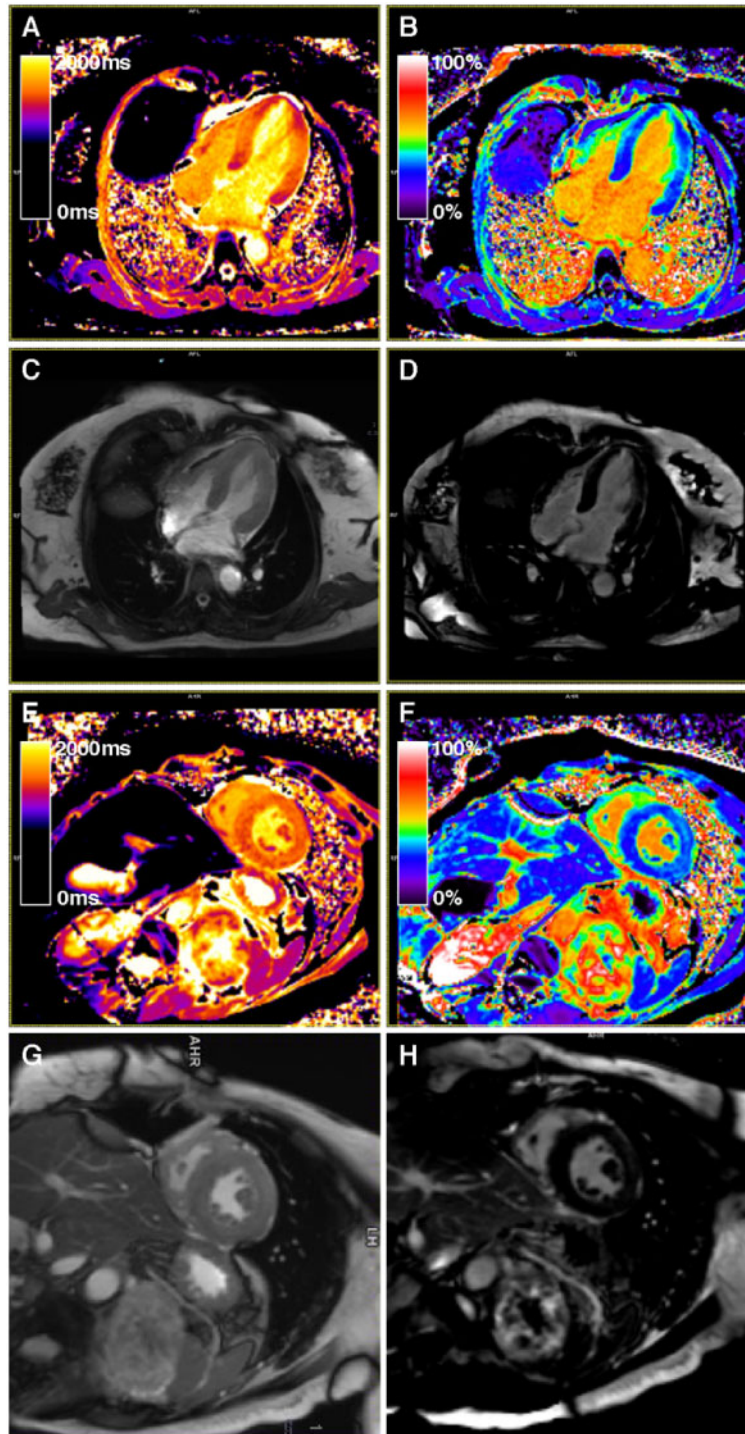
inotropy, chronotropy, and afterload. Furthermore, the beta-adrenergic receptors may be down-regulated inducing suboptimal function of myofibres, a decreasing number of contracting units, coronary arterial constriction, and/or microvascular spasm via  $\alpha_1$ -adrenoreceptor activation. Elevated intracellular concentrations of calcium may furthermore cause cellular necrosis and damage due to oxidation of catecholamines during stress with the generation of reactive oxygen species. Contraction band necrosis, neutrophil infiltration, and fibrosis are typical histological features in pheochromocytoma associated cardiomyopathy.<sup>11</sup>

Resection of the pheochromocytoma may improve the cardiomyopathy in 96% of patients, while conservative treatment has been associated with death or cardiac transplantation in 44%. Emergency surgery is generally strongly discouraged. It is recommended that surgery should be preceded by adrenergic blockade and volume expansion in order to minimize the risk of adverse events related to catecholamine-induced haemodynamic fluctuations during anaesthesia or surgical tumour resection.<sup>8</sup>

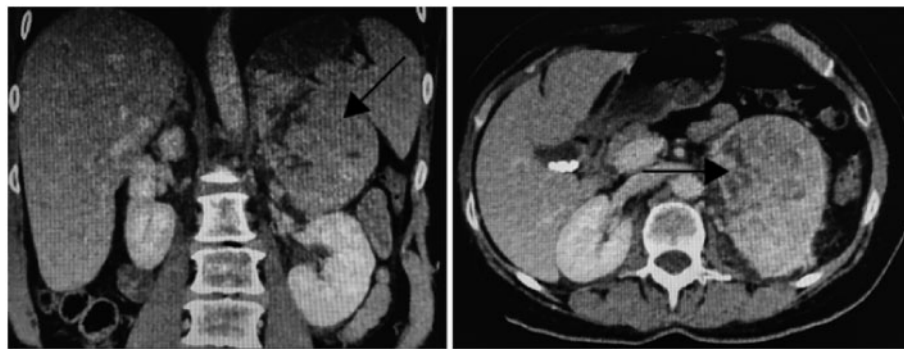
### Pulmonary oedema and pheochromocytoma

Pulmonary oedema, both non-cardiac and cardiogenic, as the first presentation of pheochromocytoma is rare and usually life-threatening.<sup>12</sup> The proposed mechanism is that catecholamines increase pulmonary capillary pressure thereby enhancing fluid filtration into the pulmonary interstitial tissue. In addition, by activation of pro-inflammatory cytokines may lead to pulmonary capillary leakage. Finally, catecholamines play an important role in the regulation of alveolar fluid clearance.<sup>12</sup> The pulmonary oedema observed in our patient was probably a consequence of backward left ventricular failure in combination with impaired pulmonary vascular integrity. Some case reports demonstrate a good clinical outcome for pheochromocytoma-induced pulmonary oedema if the patient receives early and aggressive treatment, as in this case. However, Sardesai et al.<sup>13</sup> described six patients with pheochromocytoma, who presented with acute pulmonary oedema of whom five died within 24 h of the onset of symptoms, suggesting a very poor prognosis.





**Figure 3** Cardiac magnetic resonance imaging showing typical signs of midventricular takotsubo. (A–D) Four-chamber (long axis) slices. (A) Modified Look-Locker Inversion Recovery pre-contrast T1 map (normal pre-contrast T1 range for myocardium at 3 T: 1200–1400 ms). Basal and apical regions: 1400 ms. Midventricular regions ~1600 ms. (B) Extracellular volume map (from pre- and post-contrast Modified Look-Locker Inversion Recovery T1-maps; normal range for myocardium 20–30%) demonstrates increased extracellular space in the midventricular regions (35%) and normal values in the apical and basal regions (26–30%). (C) Cine steady-state free precession image at end-systole with hypokinesia/akinesia in the mid-ventricular region. (D) Phase-sensitive inversion recovery late gadolinium enhancement showing no focal scar. (E–H) Basal-midventricular short-axis slices. (E) Modified Look-Locker Inversion Recovery pre-contrast T1-map (normal pre-contrast T1 range at 3 T: 1200–1400 ms). Pink/yellow regions 1550 ms. (F) ECV map (normal range for myocardium 20–30%). Anterior and lateral regions: ~35% and inferoseptal regions: 29%. (G) Cine SSFP image at end-systole with hypokinesia/akinesia. (H) PSIR LGE showing no focal scar. ECV, extracellular; LGE, late gadolinium enhancement; PSIR, phase sensitive inversion recovery; SSFP, steady-state free precession.



**Figure 4** Computed tomography displaying abnormal contrast uptake within a left adrenal pheochromocytoma.

## Blood glucose and pheochromocytoma

Catecholamines exert their action on glucose homeostasis through  $\alpha$ - and  $\beta$ -adrenoreceptors. Stimulation of  $\beta$ -adrenoreceptors by catecholamines causes enhanced hepatic glycogenolysis and gluconeogenesis causing a transient increase in glucose production.<sup>14</sup> Direct stimulation of the pancreatic  $\alpha$ -adrenoreceptors by norepinephrine causes inhibition of insulin release, whereas stimulation of  $\beta$ -adrenoreceptors by epinephrine results in insulin release, especially in conditions where glycogen stores are depleted.<sup>14</sup> In most situations, the  $\alpha$ -receptor-mediated insulin inhibition predominates over  $\beta$ -insulin-releasing actions causing impairment of glucose tolerance.

Hypoglycaemia in pheochromocytoma is very rare. Reviewing the existing literature, we found a total of eight case reports of patients with pheochromocytoma presenting with hypoglycaemia. The first three reports were by Hagiwara *et al.*,<sup>15</sup> Oki *et al.*,<sup>16</sup> and Hiramatsu *et al.*<sup>17</sup> They described transient hyperinsulinaemia after an OGTT, followed by severe hypoglycaemia in patients with undetected pheochromocytoma without hypertension. In the report by Hiramatsu *et al.*,<sup>17</sup> a second OGTT was performed but the hypoglycaemia could not be reproduced. In 2014, Thonangi *et al.*,<sup>18</sup> reported a case of reactive hypoglycaemia and hyperinsulinaemia after OGTT where the patient was later diagnosed with pheochromocytoma.

Kieler *et al.*<sup>19</sup> reported in 1984 of a 22-year-old woman who presented to an ED with hypoglycaemia and shock. Ultrasound revealed a tumour in the left adrenal gland but due to hypoglycaemia and absence of hypertensive symptoms, the diagnosis of pheochromocytoma was not considered. The patient died within a few hours. Innerman *et al.*<sup>1</sup> and Hambra *et al.*<sup>20</sup> reported metastatic pheochromocytomas presenting with hypoglycaemia. The authors proposed that hypoglycaemia was due to secretion of insulin or a substance with insulin-like activity by the tumour, increased utilization of glucose by the malignant cells, and a local effect of the tumour on the hepatic parenchyma. Frankton *et al.*<sup>4</sup> reported a case of pheochromocytoma crisis presenting with profound hypoglycaemia and subsequent hypertension. The authors postulated that in conditions of depleted stores of glycogen in the liver and skeletal muscles, a dominant  $\beta$ -adrenoceptor mediated release of insulin from the pancreas overrides the  $\alpha$ -adrenoceptor mediated inhibition of insulin release and hence inappropriately high insulin levels result in hypoglycaemia.

The pheochromocytoma in our patient was large and with a PASS score of 8, increasing the chance of malignancy. In such cases, humoral hypoglycaemia can be secondary to the ectopic secretion of factors related to insulin-like growth factor-2. Another explanation supported by the mentioned studies is that our patient developed hyperinsulinaemia after glucose ingestion, which led to hypoglycaemia.

The diagnosis of pheochromocytoma is easily missed and may have tragic consequences. Pulmonary oedema as first presentation is rare and potentially life-threatening. This case demonstrates the importance of considering the possibility of a pheochromocytoma as a triggering factor in patients with takotsubo cardiomyopathy, especially when occurring subsequent to severely fluctuating blood glucose levels.

## Lead author biography



Bahira Shahim is a 33-year-old Cardiology Fellow at Karolinska University Hospital, Stockholm, Sweden. Currently, she holds a postdoctoral fellowship in Interventional Cardiology at Cardiovascular Research Foundation,

Columbia University, New York. She defended her PhD thesis 'Screening Strategies for Dysglycaemia in relation to Cardiovascular risk' at the Karolinska Institute, 8 February 2019.

## Supplementary material

Supplementary material is available at *European Heart Journal - Case Reports* online.

## Acknowledgements

The authors wish to acknowledge all those who cared for this patient. A special thanks to Magnus Lundin and Peder Sörensson at Karolinska University Hospital cardiac MRI group for assisting with the MRI images and professor Lars Rydén for his feedback on this case.

**Slide sets:** A fully edited slide set detailing this case and suitable for local presentation is available online as [Supplementary data](#).

**Consent:** The author/s confirm that written consent for submission and publication of this case report including image(s) and associated text has been obtained from the patient in line with COPE guidance.

**Conflict of interest:** none declared.

## References

- Lenders JW, Eisenhofer G, Mannelli M, Pacak K. Pheochromocytoma. *Lancet* 2005;**366**:665–675.
- Kantorovich V, Pacak K. Pheochromocytoma and paraganglioma. *Prog Brain Res* 2010;**182**:343–373.
- Fujino K, Yamamoto S, Matsumoto M, Sunada M, Ota T. Paraganglioma associated with hypoglycemia. *Intern Med* 1992;**31**:1239–1241.
- Frankton S, Baithun S, Husain E, Davis K, Grossman AB. Pheochromocytoma crisis presenting with profound hypoglycaemia and subsequent hypertension. *Hormones (Athens)* 2009;**8**:65–70.
- Uysal M, Temiz S, Gul N, Yarman S, Tanakol R, Kapran Y. Hypoglycemia due to ectopic release of insulin from a paraganglioma. *Horm Res* 2007;**67**:292–295.
- Immerman SC, Sener SF, Khandekar JD. Causes and evaluation of tumor-induced hypoglycemia. *Arch Surg* 1982;**117**:905–908.
- Riester A, Weismann D, Quinkler M, Lichtenauer UD, Sommerey S, Halbritter R, Penning R, Spitzweg C, Schopohl J, Beuschlein F, Reincke M. Life-threatening events in patients with pheochromocytoma. *Eur J Endocrinol* 2015;**173**:757–764.
- Zhang R, Gupta D, Albert SG. Pheochromocytoma as a reversible cause of cardiomyopathy: analysis and review of the literature. *Int J Cardiol* 2017;**249**:319–323.
- Thompson L. Pheochromocytoma of the Adrenal Gland Scaled Score (PASS) to separate benign from malignant neoplasms: a clinicopathologic and immunophenotypic study of 100 cases. *Am J Surg Pathol* 2002;**26**:551–566.
- Agarwal V, Kant G, Hans N, Messerli FH. Takotsubo-like cardiomyopathy in pheochromocytoma. *Int J Cardiol* 2011;**153**:241–248.
- Singal PK, Kapur N, Dhillon KS, Beamish RE, Dhalla NS. Role of free radicals in catecholamine-induced cardiomyopathy. *Can J Physiol Pharmacol* 1982;**60**:1390–1397.
- Rassler B. The role of catecholamines in formation and resolution of pulmonary oedema. *Cardiovasc Hematol Disord Drug Targets* 2007;**7**:27–35.
- Sardesai SH, Mourant AJ, Sivathandon Y, Farrow R, Gibbons DO. Pheochromocytoma and catecholamine induced cardiomyopathy presenting as heart failure. *Br Heart J* 1990;**63**:234–237.
- Porte D. A receptor mechanism for the inhibition of insulin release by epinephrine in man. *J Clin Invest* 1967;**46**:86–94.
- Hagiwara M, Koyama Y, Deguchi O. A case of normotensive pheochromocytoma with hypoglycemia. *Horumon To Rinsho* 1981;**29**:287.
- Okii S, Kuno S, Nakao K, Imura H, Endo K, Torizuka K. [A case of pheochromocytoma of paroxysmal type detected from a paradoxical response in GTT with ten years' clinical course]. *Nippon Naika Gakkai Zasshi* 1985;**74**:1720–1725.
- Hiramatsu K, Takahashi K, Kanemoto N, Arimori S. A case of pheochromocytoma with transient hyperinsulinemia and reactive hypoglycemia. *Jpn J Med* 1987;**26**:88–90.
- Thonangi RP, Bhardwaj M, Kulshreshtha B. A case report of reactive hypoglycemia in a patient with pheochromocytoma and it's review of literature. *Indian J Endocrinol Metab* 2014;**18**:234–237.
- Kieler C, Helpap B, Dapp A. [Hypotension and shock in pheochromocytoma]. *Dtsch Med Wochenschr* 1984;**109**:1885–1889.
- Habra MA, Núñez R, Chuang H, Ayala-Ramirez M, Rich T, Kyle K, Jimenez C. Fatal hypoglycemia in malignant pheochromocytoma: direct glucose consumption as suggested by (18)F-2-fluoro-2-deoxy-D-glucose positron emission tomography/computed tomography imaging. *Endocrine* 2010;**37**:209–212.