

# Newborn nasal obstruction due to congenital nasal pyriform aperture stenosis

Thiago L. I. Serrano, M.D., Leopoldo Pfeilsticker, M.D., Ph.D., Vanessa Silva, M.D., Igor Hazboun, M.D., Jorge Paschoal, M.D., Ph.D., Rebecca Maunsell, M.D., Ph.D., and Eulalia Sakano, M.D., Ph.D.

## ABSTRACT

**Introduction:** Nasal obstruction is an important condition that can lead to severe respiratory distress in newborns. There are several differential diagnoses, and one of them is congenital nasal pyriform aperture stenosis (CNPAS). CNPAS is a rare case of respiratory distress caused by excessive growth of the nasal process of the maxilla and leads to narrowing of the anterior third of the nasal cavity. Diagnosis, associated anomalies, and treatment strategies are reviewed by the following presentation of two cases.

**Case Presentation:** We report two cases of infants diagnosed with CNPAS. The patients in the first case had no concomitant comorbidities, and the outcome was successful after surgical correction of stenosis. The patient in the second case had an associated holoprosencephaly, and although surgical correction and nasal cavity patency, the patient remains dependent on tracheostomy due to dysphagia and neurologic impairment.

**Discussion:** Airway obstruction affects 1 in 5000 children, and CNPAS is a diagnosis frequently forgotten and even unknown to neonatal and pediatric intensivists. Newborns are obligate nasal breathers, and, nasal obstruction, therefore, can lead to severe respiratory distress. CNPAS is not only rare but, many times, is not easily recognized. It is important to bear in mind the diagnostic criteria when evaluating infants with nasal obstruction. Conservative treatment should be prioritized, but surgical treatment is required in severe cases with failure to thrive and persistent respiratory distress. Respiratory distress and dysphagia may persist to some degree despite correction of the stenotic pyriform aperture due to associated narrowing of the entire nasal cavity and association with other anomalies.

**Final Comments:** CNPAS is a rare condition and may be lethal in newborns. Differential diagnosis of nasal obstruction must be remembered to recognize this anomaly, and the otolaryngologist must be familiarized with this condition and its diagnosis. Precise surgical treatment in severe cases have high rates of success in children without other comorbidities.

(Allergy Rhinol 7:e37–e41, 2016; doi: 10.2500/ar.2016.7.0146)

Newborns are obligate nasal breathers at all times, and this condition becomes more prominent during lactation.<sup>1–3</sup> Congenital nasal obstruction, therefore, can cause swallowing disorders, failure to thrive, cyanosis, and apneic episodes that revert with crying.<sup>3</sup> The most common cause of nasal obstruction is mucous edema; nevertheless, less-frequent differential diagnoses must be remembered. These include bilateral choanal atresia, congenital stenosis of nasal bones, and congenital stenosis of the pyriform aperture.<sup>2</sup>

The pyriform aperture is limited laterally by the nasal process of the maxilla, inferiorly by the junction of the horizontal process of the maxilla and the anterior nasal spine, and superiorly by the nasal bones.<sup>4</sup> In

congenital nasal pyriform aperture stenosis (CNPAS), an overgrowth of the nasal process of the maxilla is the cause of narrowing of the pyriform aperture.<sup>2</sup> We report two cases of newborn infants with congenital nasal obstruction and respiratory distress. A diagnosis of CNPAS was found after investigation. The aim of this review was to bring attention to this condition in the differential diagnosis of nasal obstruction in newborns. Criteria for diagnosis, treatment, and recognition of the frequently associated comorbidities are presented. Treatment and outcome are also discussed.

## CASE PRESENTATION

### Case 1

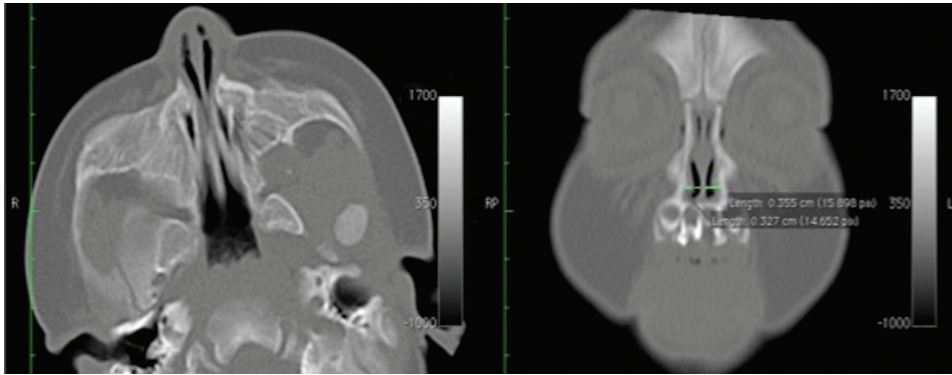
A full-term female infant was delivered naturally. Soon, in the first days, she was diagnosed with physiologic stenosis of the pulmonary branches, holoprosencephaly, and patent oval foramen. While in the neonatal intensive-care unit, she was evaluated by the otolaryngology team due to respiratory distress and difficulty feeding. A deviated columella could be seen

---

From the Department of Otorhinolaryngology, Head and Neck Surgery, University of Campinas, Campinas, São Paulo, Brazil

The authors have no conflicts of interest to declare pertaining to this article  
Address correspondence to Thiago L. I. Serrano, M.D., Department of Otorhinolaryngology, Head and Neck Surgery, P.O. Box 6111, 13081-970, São Paulo, Brazil  
E-mail address: thiagoserrano@uol.com.br

Copyright © 2016, OceanSide Publications, Inc., U.S.A.



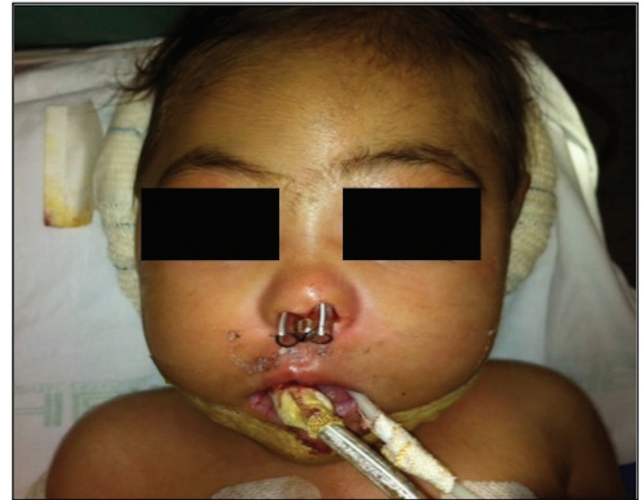**Figure 1.** Computed tomography of the sinuses. Left, Axial section, showing the region of patent choanae without atresia signals. Right, Coronal section, showing narrowing of pyriform aperture. Right nostril size is 0.32 cm and left nostril size is 0.35 cm.

externally, and the nasal cavities were not patent to a 3.2-mm flexible nasofibroscope. The child managed to feed orally with conservative measures and nutritional orientation, and she was seen monthly in the outpatient clinic. For 4 months, she thrived and gained weight, always in the inferior limit of normality, and maintained moderate although intermittent respiratory distress. At 5 months of age, after an upper airway infection, the child was admitted to the hospital with respiratory insufficiency and sepsis. After admission to the pediatric intensive care unit, the child was intubated and kept on mechanical ventilation for 25 days. A tracheostomy was performed after failure to extubate due to apnea and an insufficient respiratory drive. No evidence of laryngotracheal inflammation or disease was observed during examination before tracheostomy. A 4-mm and a 2.7-mm diameter telescope were used at this time in an attempt to visualize the nasal cavities, but the pyriform apertures could not be passed. A computed tomography (CT) of the nasal cavity revealed no choanal atresia but a pyriform aperture of 0.67 cm and an obstructive deviated nasal septum (Fig. 1).

Surgical correction of the CNPAS was performed by using a sublabial approach. The nasal process of the maxilla was exposed through subperiosteal blunt dissection and the pyriform aperture was drilled and enlarged. A septoplasty and a partial inferior turbinectomy was also performed to enlarge the midnasal portion of the nasal cavity. Two pieces of 3.0 endotracheal tubes were used as stents bilaterally to allow suction and irrigation, and to ensure patency (Fig. 2). In 7 days, the stents were removed. The patient was followed up for a year, and nasal cavities remained patent (Fig. 3), with good visualization through a nasofibroscope. The patient still had a tracheostomy due to neurologic impairment and persistent dysphagia.

### Case 2

A full-term female infant was presented with anoxia and seizures after delivery and needed immediate oro-tracheal intubation. She was transferred to the neonatal

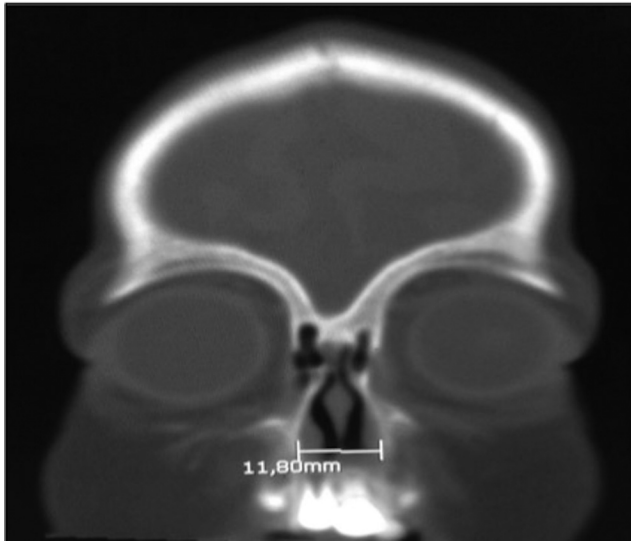


**Figure 2.** Final appearance in the immediate postoperative period, with the tracheal tube no. 3 set in both nostrils to keep airways and allow cleaning.

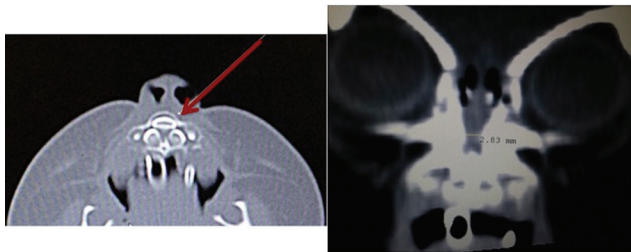
intensive care unit after 42 days of receiving medical treatment for seizures and a presumed diagnosis of choanal atresia. No external oral or nasal malformations were observed, but a nasofibroscope could not pass the nasal vestibule bilaterally. A CT revealed a patent choana but a narrowed pyriform aperture of approximately 2.8 mm associated with a solitary median maxillary central incisor (Figs. 4 and 5). After a diagnosis of CNPAS was confirmed, the child underwent surgical correction through a sublabial approach (Figs. 6 and 7) and stenting with adapted endotracheal tubes. Twenty-four hours after surgery, the respiratory distress resolved. Stenting was removed after 5 days. The nasal cavities remained patent, and the patient was able to feed orally.

### DISCUSSION

CNPAS was first described by Douglas in 1952.<sup>5</sup> In 1989, it was defined by O. E. Brown as a cause of respiratory distress in children.<sup>1</sup> Symptoms are respiratory distress, stertor, apneic episodes, inability to feed, and sudden obstruction of the airway reversed by



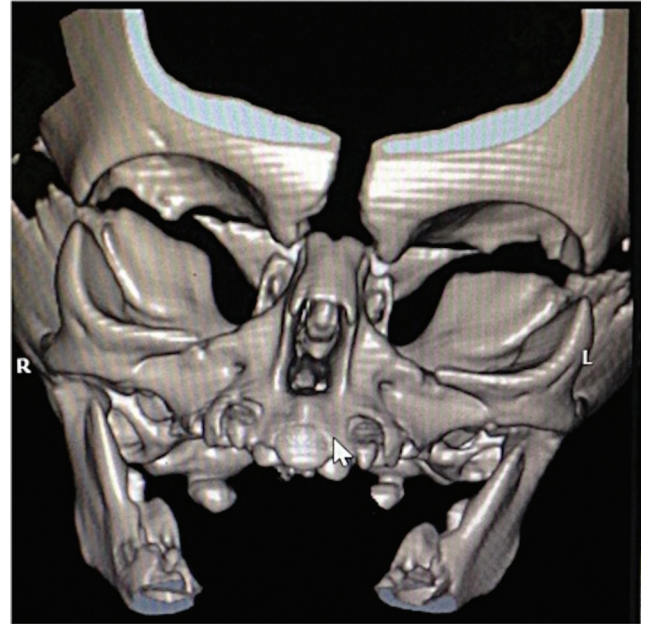**Figure 3.** Computed tomography of the sinuses. Postoperative aspect with enlargement of pyriform aperture.



**Figure 4.** Computed tomography of sinuses. Left, Axial section, showing solitary median maxillary central incisor (arrow). Right, Coronal section, showing 2.8 mm pyriform aperture size.

crying. These signs may occur soon after delivery or during the first months of life, depending on the grade of the stenosis.<sup>6</sup>

Differential diagnosis of bilateral nasal obstruction in newborns with these features include the following: choanal atresia; nasal trauma, such as septal hematomas and septal subluxation; dermoid cysts; skull base malformations, such as meningoencephaloceles and encephaloceles; tumors (rhabdomyosarcomas, hemangiomas, gliomas, lymphangiomas, and teratomas); and nasal hypoplasia.<sup>6</sup> CNPAS should be considered in any child with bilateral nasal obstruction and with no major facial anomalies when a 2.2-mm fibroscope cannot enter the nasal cavity and a CT reveals a distance between the nasal processes of the maxilla of <11 mm. This should be measured in the axial plane at the level of the inferior meatus.<sup>2,7</sup> A plain radiograph that shows a pyriform aperture of <8–10 mm in a full-term newborn can also indicate CNPAS.<sup>4</sup> Reeves *et al.*,<sup>3</sup> in an attempt to establish radiologic criteria for diagnosis found that probably the 11-mm reference for normality should be lower because normal infants may present with pyriform apertures of ~10 mm. These researchers



**Figure 5.** Computed tomography 3-D reconstruction, showing solitary median maxillary central incisor (arrow) and pyriform aperture stenosis.

also found that, in their six cases, not only the pyriform aperture was narrowed but the entire nasal cavity, which thus justified the need for turbinectomy.

Although the cause is unknown, stenosis occurs due to the overgrowth of the nasal process of the maxilla during the third to fourth month of pregnancy. CNPAS may present as an isolated condition or, more often, associated with other congenital anomalies, especially craniofacial conditions, *e.g.*, holoprosencephaly.<sup>4,7</sup> Holoprosencephaly is a cerebral malformation resultant of incomplete cleavage of the proencephalon into right and left hemispheres. The prevalence of holoprosencephaly is 1 in 16,000 newborns, with a wide spectrum of presentation that may include palatal fissure and cerebral malformations.<sup>8</sup> The presence of a solitary median maxillary central incisor that is considered a less-severe form of presentation in the holoprosencephaly spectrum occurs in 50–63% of CNPAS cases.<sup>7,9</sup> Therefore, it is recommended to actively investigate for holoprosencephaly for all patients diagnosed with CNPAS by looking for congenital anomalies closely related to this entity. Nevertheless, the hypothalamic-pituitary-adrenal axis should also be investigated as part of the possible developmental defect.<sup>9</sup> Anomalies of the hypophysis can be observed in 40% of patients.<sup>6</sup>

Treatment depends on the severity of obstruction, symptoms, and prognosis of the child. Establishing a secure airway is the priority.<sup>6</sup> Conservative treatment may be prioritized, with close follow up until growing expansion of the nasal cavity.<sup>9</sup> This will prevent surgical distress and long-term effects on

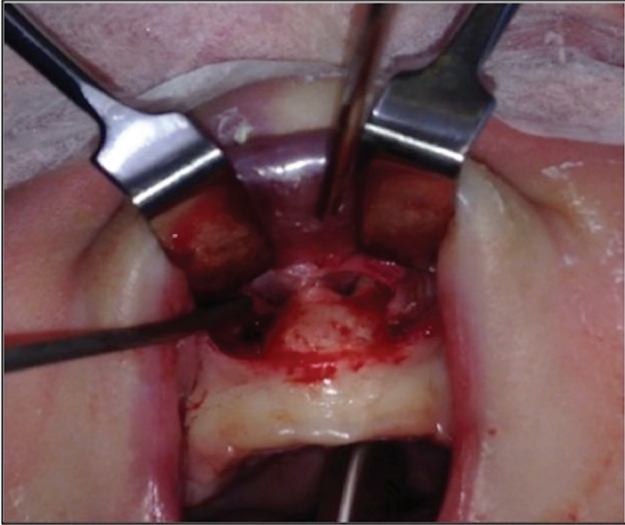


Figure 6. Sublabial approach.

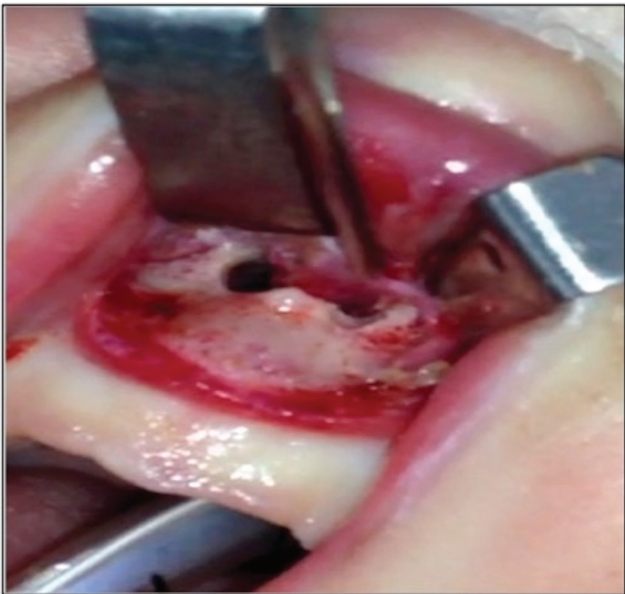


Figure 7. Intraoperative, showing postcorrection aspect in the right side.

maxillofacial growth, *e.g.*, asymmetry. Nasal humidification and irrigation, topical steroids, decongestants, and aspiration are used. This conservative management was recommended in those patients with multiple anomalies and a poor prognosis.<sup>6</sup> Nevertheless, in refractory cases or in cases with severe initial presentation, surgical treatment should be indicated.<sup>2</sup> Difficulty feeding and respiratory distress are important factors to be considered when indicating surgical treatment, and this may not be related to the actual size of the pyriform aperture.<sup>9,10</sup> Success is related to with associated comorbidities, and the need for reinterventions is usually seen in cases of craniofacial dysmorphism.<sup>10</sup>

Surgical access can be transnasal or sublabial.<sup>6</sup> The transnasal access does not apply to newborns due to the small dimensions and poor exposure that increases the risk of trauma to soft tissue.<sup>4,6</sup> In the sublabial approach, a subperiosteal flap is bluntly dissected to expose the pyriform aperture. A diamond burr is used to enlarge the lateral and inferior walls of the pyriform aperture anterior to the inferior turbinate to prevent lesion to the nasolacrimal duct. A satisfactory opening is achieved when a 3.5-mm diameter endotracheal cuffed tube can be pushed through the nose.<sup>4,6</sup> Usually stents are positioned and fixed in both nostrils to avoid granulation tissue and restenosis, and can be left in for 3 to 14 days.<sup>6</sup>

Surgical complications are related to bone dissection and granulation tissue formation. Trauma to the periosteum, nasal mucosa, dental roots, and nasolacrimal duct should be avoided. Patients with stents should be closely followed up due to a risk of restenosis when removed early or tissue necrosis when removed too late.<sup>4,6</sup> Merea *et al.*<sup>11</sup> published a series of six patients who underwent the classic sublabial procedure associated with bilateral inferior turbinectomy without stenting. These researchers reported successful follow-up, with no cases of restenosis or septal perforations. Interference with facial growth may be a complication but is not frequently reported.<sup>6</sup>

A different treatment modality, which is less invasive and has a lower risk of complications, has been proposed by Gungor and Reiersen.<sup>12</sup> The researchers reported a case of CNPAS dilation with a 7-mm balloon and stenting for 12 days. In this report, the researchers justified the use of stents due to the natural plasticity of the bone and cartilages of the maxillofacial structure secondary to the effects of estrogen. They reported 1 year of follow-up with no restenosis. Dysphagia and swallowing disorders should be evaluated after surgery even in those cases with isolated CNPAS because some symptoms may persist. Sultan *et al.*<sup>13</sup> reported an elevated risk of malnutrition and failure to thrive even after surgical correction.

## CONCLUSION

CNPAS is a rare but potentially lethal cause of airway obstruction in newborns that is unknown to a large number of neonatologists and pediatric intensivists. CNPAS may occur in an isolated form or may be associated with other anomalies and should always be considered in the differential diagnosis of newborns who present with nasal obstruction associated with difficulty in passing a small catheter through the anterior nasal valve. Surgical correction and proper stenting showed high levels of success, but these procedures are not mandatory in all cases.

## REFERENCES

1. Erdem T, Ozturan O, Erdem G, et al. Nasal pyriform aperture stenosis in adults. *Am J Rhinol* 18:57–62, 2004.
2. Wine TM, Dedhia K, and Chi DH. Congenital nasal pyriform aperture stenosis: Is there a role for nasal dilation? *JAMA Otolaryngol Head Neck Surg* 140:352–356, 2014.
3. Reeves TD, Discolo CM, and White DR. Nasal cavity dimensions in congenital pyriform aperture stenosis. *Int J Pediatr Otorhinolaryngol* 77:1830–1832, 2013.
4. Sesenna E, Leporati M, Brevi B, et al. Congenital nasal pyriform aperture stenosis: Diagnosis and management. *Ital J Pediatr* 38:28–33, 2012.
5. Douglas B. The relief of vestibular nasal obstruction by partial resection of the nasal process of the superior maxilla. *Plast Reconstr Surg* 9:42–51, 1952.
6. Baker KA, and Pereira KD. Congenital nasal pyriform aperture stenosis. *Oper Tech Otolaryngol* 20:178–182, 2009.
7. Visvanathan V, and Wynne DM. Congenital nasal pyriform aperture stenosis: A report of 10 cases and literature review. *Int J Pediatr Otorhinolaryngol* 76:28–30, 2012.
8. Bharti G, Groves L, Sanger C, and Argenta LC. Congenital pyriform aperture stenosis. *J Craniofac Surg* 22:992–994, 2011.
9. Lee JJ, Bent JP, and Ward RF. Congenital nasal pyriform aperture stenosis: Non-surgical management and long-term analysis. *Int J Pediatr Otorhinolaryngol* 60:167–171, 2001.
10. Gonik NJ, Cheng J, Lesser M, et al. Patient selection in congenital pyriform aperture stenosis repair: 14 year experience and systematic review of literature. *Int J Pediatr Otorhinolaryngol* 79:235–239, 2015.
11. Merea VS, Lee AH, Peron DL, et al. CPAS: Surgical approach with combined sublabial bone resection and inferior turbinate reduction without stents. *Laryngoscope* 125:1460–1464, 2015.
12. Gungor AA, and Reiersen DA. Balloon dilatation for congenital nasal pyriform aperture stenosis (CNPAS): A novel conservative technique. *Am J Otolaryngol* 35:439–442, 2014.
13. Sultan B, Lefton-Greif MA, Brown DJ, and Ishman SL. Congenital nasal pyriform aperture stenosis: Feeding evaluation and management. *Int J Pediatr Otorhinolaryngol* 73:1080–1084, 2009. □