

Relative anterior microphthalmos in oculodentodigital dysplasia

Orsolya Orosz¹, Mariann Fodor¹, István Balogh²,
Gergely Losonczy^{1,3}

Here, we report a patient with oculodentodigital dysplasia (ODDD) caused by the c. 413G>A, p.Gly138Asp mutation in the gap junction protein alpha-1 gene. The patient suffered from characteristic dysmorphic features of ODDD. Ophthalmological investigation disclosed microcornea and a shallow anterior chamber, as expected. Surprisingly, the patient had a normal axial length and moderate myopia on both eyes. To the best of our knowledge, this is the first report on ODDD associated with relative anterior microphthalmos and myopia.

Key words: Microcornea, mutation, myopia, oculodentodigital dysplasia

Oculodentodigital dysplasia (ODDD, OMIM 164200) is an extremely rare congenital autosomal dominant disorder caused by mutations in the gap junction alpha 1 (GJA1; MIM#121014) gene on chromosome 6q22-q23.^[1,2] It affects mainly the development of the face, eyes, fingers, and teeth. The most frequent ocular findings in ODDD include microphthalmia,

microcornea, and glaucoma.^[2-4] Microcornea can be associated with numerous other ophthalmological symptoms.^[5] However, microcornea associating to myopia is a very rare phenotype in any disorders.^[6] Here, we report an ODDD case with a GJA1 mutation who presented with an extremely rare combination of microcornea and myopia.

Case Report

A 28-year-old male patient was investigated with dysmorphic features suggestive of ODDD such as the long and narrow nose, abnormally shaped small teeth with enamel hypoplasia, and high arched palate. The patient was the only child of the parents. He was born with bilateral syndactyly of fingers IV-V which was surgically treated [Fig. 1a-c]. His toes were normal. The patient's corneal diameter was 9.51 and 9.56 mm right eye (OD) and left eye (OS), respectively, representing microcornea on both sides. His best-corrected visual acuity was 1.0 on both eyes; however, his refractive error was $-6.0 + 3.0 \times 90$ in his OD and $-5.0 + 2.5D \times 70$ in his OS. Axial length (22.63 mm, OD and 22.49 mm, OS), corneal thickness (542 μ m, OD and 544 μ m, OS), and intraocular pressure (14 mmHg in both eyes) were normal. Optic nerve head appeared healthy in both eyes. The anterior chamber depth was 2.34 mm (OD) and 2.26 mm (OS) and the anterior chamber angle was 23.8–26.7 (OD) and 22.9–25.4 (OS) representing a shallow anterior chamber with a narrow anterior chamber angle [Fig. 1d]. Gonioscopy also revealed a narrow angle; however, it reached as much as Schaffer Grade III. The ocular fundus was normal in both eyes. The parents of the patient were free from any symptoms of ODDD. The father of the patient had no refractive errors; however, the mother had moderate myopia (spherical equivalent [SE] -6.0 D in OD/ -4.5 D in OS). Moreover, the father of the mother had high myopia (SE -18.0 D in OD and -20.0 D in OS). Clinical data of the patient are summarized in Table 1.

Access this article online	
Quick Response Code:	Website: www.ijo.in
	DOI: 10.4103/ijo.IJO_756_17

¹Department of Ophthalmology, University of Debrecen, ²Department of Laboratory Medicine, Division of Clinical Genetics, University of Debrecen, Debrecen, Hungary, ³Department of Ophthalmology, Zuyderland Hospital, Eyescan BV, Sittard, The Netherlands

Correspondence to: Dr. Gergely Losonczy, Department of Ophthalmology, University of Debrecen, H-4032, Nagyterdei Krt 98, Debrecen, Hungary. E-mail: losigeri@gmail.com

Manuscript received: 30.08.17; Revision accepted: 27.11.17

This is an open access article distributed under the terms of the Creative Commons Attribution-NonCommercial-ShareAlike 3.0 License, which allows others to remix, tweak, and build upon the work non-commercially, as long as the author is credited and the new creations are licensed under the identical terms.

For reprints contact: reprints@medknow.com

Cite this article as: Orosz O, Fodor M, Balogh I, Losonczy G. Relative anterior microphthalmos in oculodentodigital dysplasia. Indian J Ophthalmol 2018;66:334-6.

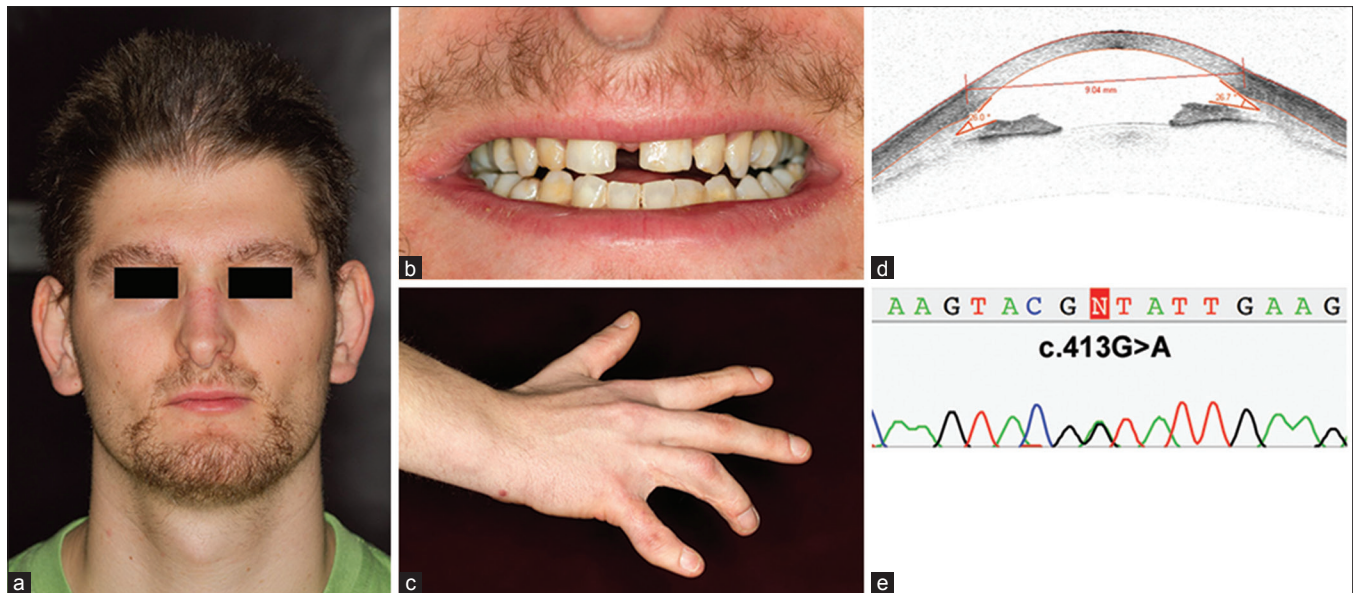


Figure 1: Clinical and laboratory findings. The proband showed typical dysmorphic signs of oculodentodigital dysplasia: (a) long narrow nose, (b) abnormal dentition and (c) syndactyly of the 4th–5th digits. (d) Anterior segment optical coherence tomography of the right eye. (e) Electropherogram of the missense mutation in the gap junction alpha 1 gene

Table 1: Clinical characteristics of the patient

	OD	OS
Refraction (D)	-6.0 + 3.0×90	-5.0 + 2.5×70
Best corrected visual acuity	1.0	1.0
Axial length (mm)	22.63	22.49
Central corneal thickness (um)	542	544
Anterior chamber depth (mm)	2.34	2.26
Keratometry 1 (D)	46.81	46.79
Keratometry 2 (D)	50.05	50.26
White-to-white distance (mm)	9.51	9.56
Anterior chamber angle	23.8-26.7	22.9-25.4

Anterior chamber angle was measured using the visante anterior segment OCT (Carl Zeiss Meditec, Inc., Dublin, California, USA). Other parameters were measured using the Lenstar equipment (Haag-Streit Diagnostics, Bern, Switzerland). OD: Right eye, OS: Left eye, OCT: Optical coherence tomography

To confirm the clinical diagnosis, genetic analysis was performed. Informed consent was obtained from the patient. The research was performed according to the Declaration of Helsinki and was approved by the local Institutional Review Board. Genomic DNA was isolated from ethylenediaminetetraacetic acid-anticoagulated blood using the QIAamp Blood Mini kit according to the manufacturer's instructions (Qiagen GmbH, Hilden, Germany). We amplified the *GJA1* exon 2 using polymerase chain reaction and designed primer pairs with mismatches to avoid the amplification of the *GJA1P1* pseudogene. The amplicons were identified with ABI BigDye Terminator Cycle Sequencing kit version 3.1 (Applied Biosystems, Foster City, CA, USA) on an ABI310 sequencer (Applied Biosystems). Sequence analysis detected a pathogenic heterozygous missense mutation, c.413G>A, p.Gly138Asp in the cytoplasmic loop of connexin 43 protein [Fig. 1e]. This mutation was previously reported in a patient with ODDD.^[7]

Discussion

ODDD is an extremely rare congenital disorder caused by mutations in the *GJA1* gene (MIM#121014) coding the connexin 43 protein, which has an important role in ocular development. The majority of ODDD cases are inherited in an autosomal dominant pattern; however, autosomal recessive and sporadic cases have also been reported.^[1] The clinical manifestation of the disease is highly variable and affects mainly the development of the face, dentition, eyes, and fingers. Syndactyly of the 4th–5th fingers, tooth anomalies, and narrow nose are the key features of the syndrome. Its main ophthalmic features include microcornea, microphthalmia, and glaucoma.^[2-4] There are >60 connexin 43 mutations reported in the *GJA1* gene so far.^[3] However, for most of these mutations, a detailed genotype-phenotype correlation has not yet been documented. Microphthalmia and microcornea in ODDD were first reported in a large four-generation Italian family.^[8,9] Simultaneous presence of microcornea and myopia is a rare combination in any other conditions.^[6] To the best of our knowledge, neither relative anterior microphthalmos, nor its combination with myopia was ever before reported in ODDD patients.

We identified a patient with characteristic facial features of ODDD [Fig. 1a-c]. A detailed ophthalmologic investigation detected a shallow anterior chamber with a narrow anterior chamber angle, microcornea, a normal axial length, and refractive myopia in both eyes referring to relative anterior microphthalmos^[10] [Fig. 1d and Table 1].

Genetic analysis detected a heterozygous missense mutation in the *GJA1* gene (c.413G>A, p.Gly138Asp) [Fig. 1e]. This mutation was reported previously in a patient with ODDD, and here we provide the first confirmation of this association.^[7] However, the ophthalmological phenotype of the present case differs from those observed in ODDD patients so far, in that our patient had a normal axial length. To the best of our knowledge,

this is the first report on ODDD associated with relative anterior microphthalmos and myopia.

Conclusion

Connexin 43 protein has a crucial role in ocular development.^[7] Our results indicate that microphthalmos is not an obligate feature of ODDD and microcornea can associate with a normal axial length in ODDD patients. This observation expands the known phenotypic spectrum of the ODDD and may add to the understanding of genetic factors influencing the axial length of the eyeball.

Declaration of patient consent

The authors certify that they have obtained all appropriate patient consent forms. In the form, the patient has given his consent for his images and other clinical information to be reported in the journal. The patient understands that name and initials will not be published and due efforts will be made to conceal identity, but anonymity cannot be guaranteed.

Financial support and sponsorship

This study was financially supported by the Ministry of National Economy, Hungary GINOP-2.3.2- 15-2106-00039.

Conflicts of interest

There are no conflicts of interest.

References

1. Loddenkemper T, Grote K, Evers S, Oelerich M, Stögbauer F. Neurological manifestations of the oculodentodigital dysplasia syndrome. *J Neurol* 2002;249:584-95.
2. Paznekas WA, Boyadjiev SA, Shapiro RE, Daniels O, Wollnik B, Keegan CE, *et al.* Connexin 43 (GJA1) mutations cause the pleiotropic phenotype of oculodentodigital dysplasia. *Am J Hum Genet* 2003;72:408-18.
3. Paznekas WA, Karczeski B, Vermeer S, Lowry RB, Delatycki M, Laurence F, *et al.* GJA1 mutations, variants, and connexin 43 dysfunction as it relates to the oculodentodigital dysplasia phenotype. *Hum Mutat* 2009;30:724-33.
4. Gorlin RJ, Miskin LH, St. Geme JW. Oculodentodigital dysplasia. *J Pediatr* 1963;63:69-75.
5. Kanski JJ, editor. Congenital corneal anomalies. In: *Clinical Ophthalmology*. Oxford, U.K: Butterworth-Heinemann; 2003. p. 139-40.
6. Sohajda Z, Holló D, Berta A, Módis L. Microcornea associated with myopia. *Graefes Arch Clin Exp Ophthalmol* 2006;244:1211-3.
7. Fenwick A, Richardson RJ, Butterworth J, Barron MJ, Dixon MJ. Novel mutations in GJA1 cause oculodentodigital syndrome. *J Dent Res* 2008;87:1021-6.
8. Vingolo EM, Steindl K, Forte R, Zompatori L, Iannaccone A, Sciarra A, *et al.* Autosomal dominant simple microphthalmos. *J Med Genet* 1994;31:721-5.
9. Vitiello C, D'Adamo P, Gentile F, Vingolo EM, Gasparini P, Banfi S, *et al.* A novel GJA1 mutation causes oculodentodigital dysplasia without syndactyly. *Am J Med Genet A* 2005;133A: 58-60.
10. Auffarth GU, Blum M, Faller U, Tetz MR, Völcker HE. Relative anterior microphthalmos: Morphometric analysis and its implications for cataract surgery. *Ophthalmology* 2000;107:1555-60.