

[ CASE REPORT ]

## A Novel Method of Diagnosing Aberrant Pancreas: Needle-based Confocal Laser Endomicroscopy

Muneji Yasuda<sup>1</sup>, Kazuo Hara<sup>1</sup>, Yusuke Kurita<sup>1</sup>, Hiroki Tanaka<sup>1</sup>, Masahiro Obata<sup>1</sup>,  
Naosuke Kuraoka<sup>1</sup>, Shimpei Matsumoto<sup>1</sup>, Ayako Ito<sup>1</sup>, Hiromichi Iwaya<sup>1</sup>,  
Kazuhiro Toriyama<sup>2</sup>, Nozomi Okuno<sup>1</sup>, Takamichi Kuwahara<sup>1</sup>, Susumu Hijioka<sup>1</sup>,  
Nobumasa Mizuno<sup>1</sup>, Sachiyo Onishi<sup>2</sup>, Yutaka Hirayama<sup>2</sup>, Makoto Ishihara<sup>2</sup>,  
Tsutomu Tanaka<sup>2</sup>, Masahiro Tajika<sup>2</sup> and Yasumasa Niwa<sup>2</sup>

### Abstract:

Aberrant pancreas is defined as pancreatic tissue present outside of the pancreas and is often found incidentally during esophagogastroduodenoscopy. Obtaining sufficient tissue to differentiate aberrant pancreas from other subepithelial lesions is sometimes difficult. Due to the lack of a definitive diagnosis, patients often undergo unnecessary surgery. We herein report the first case of aberrant pancreas in which the concomitant use of needle-based probe confocal laser endomicroscopy and fine-needle aspiration supported the final diagnosis. Needle-based probe confocal laser endomicroscopy provides a real-time *in vivo* histopathology evaluation and may be a feasible means of diagnosing aberrant pancreas.

**Key words:** aberrant pancreas, needle-based probe confocal laser endomicroscopy, fine-needle aspiration

(Intern Med 57: 2827-2831, 2018)

(DOI: 10.2169/internalmedicine.0449-17)

### Introduction

Although aberrant pancreas is classically seen in the gastric antrum during routine esophagogastroduodenoscopy (EGD) as a subepithelial lesion (SEL), a standard biopsy examination with EGD usually cannot differentiate from other SELs. They have similar appearances but require different treatment strategies. A gastrointestinal stromal tumor (GIST) carries a risk of malignant transformation and is an indication for surgical resection. Conversely, aberrant pancreas does not require any treatment or follow-up in the absence of symptoms. An effective way of diagnosing aberrant pancreas would therefore be helpful in stratifying patient management.

Endoscopic ultrasonography (EUS) is commonly used to assess gastric SELs, but EUS findings cannot establish the diagnosis. Rosch et al. reported that the sensitivity and specificity of EUS for differentiating between malignant and benign submucosal tumors were only 64% and 80%, respec-

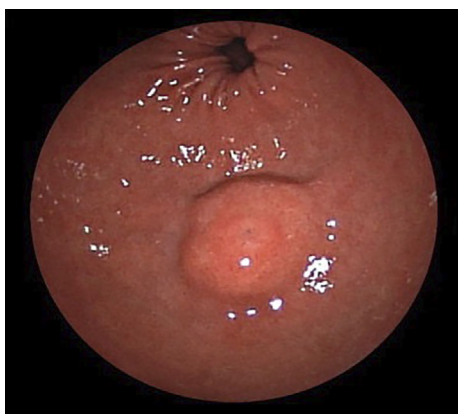
tively (1). Karaca et al. reported that EUS alone had an accuracy rate of 30.8% and 66.7%, respectively, for the diagnosis of neoplastic and non-neoplastic lesions (2).

EUS-fine-needle aspiration (EUS-FNA) is performed to diagnose gastric SELs. Obtaining a histopathological diagnosis by EUS-FNA seems to be a low-invasive and reasonable approach. However, the sensitivities of EUS-FNA have been reported to range from 65-79% in some prospective studies (3-7). EUS-FNA therefore remains inadequate for accurately diagnosing SEL and sometimes leads to a misdiagnosis, with the lesion being resected as GIST (8). Furthermore, EUS-FNA requires several punctures to obtain a large enough tissue sample for a diagnosis. Attwell et al. reported two cases of acute ectopic pancreatitis after two to six passes of EUS-FNA for aberrant pancreas in nine patients (9). Although various methods, such as endoscopic submucosal-mucosal resection and a trucut biopsy, have been reported (2, 4, 10), their accuracies are not superior to that of EUS-FNA. A less invasive and more sensitive method of diagnosing aberrant pancreas is therefore desir-

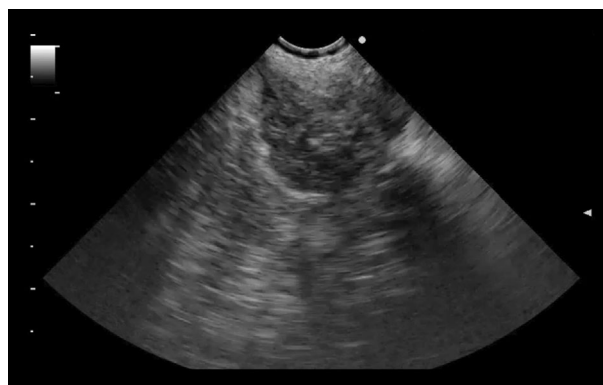<sup>1</sup>Department of Gastroenterology, Aichi Cancer Center, Japan and <sup>2</sup>Department of Endoscopy, Aichi Cancer Center Hospital, Japan

Received: December 20, 2017; Accepted: February 21, 2018; Advance Publication by J-STAGE: May 18, 2018

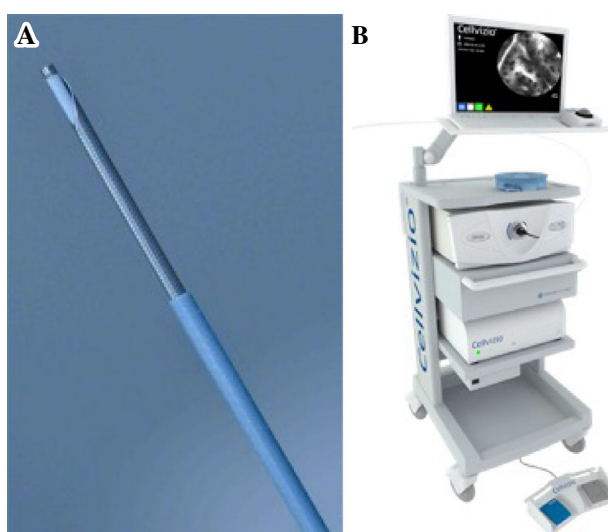
Correspondence to Dr. Kazuo Hara, khara@aichi-cc.jp



**Figure 1.** Esophagogastroduodenoscopy revealed a subepithelial lesion with umbilication on the greater curvature of the antrum.



**Figure 2.** Endoscopic ultrasonography showed a hypoechoic mass with a heterogeneous high echoic part in the subepithelial lesion.



**Figure 3.** A: The needle-based confocal laser endomicroscopy probe protruding from a 19-G fine-needle aspiration needle (AQ-Flex™19) (quoted from cellvizio.net). B: Cellvizio® Mauna Kea Technology, Paris, France (quoted from cellvizio.net).

able.

Needle-based confocal laser endomicroscopy (nCLE) is a newly developed modality that allows for a real-time optical biopsy at the time of EUS. It is widely used in the assessment of pancreatic cysts (11, 12). We herein report a case of aberrant pancreas diagnosed by nCLE.

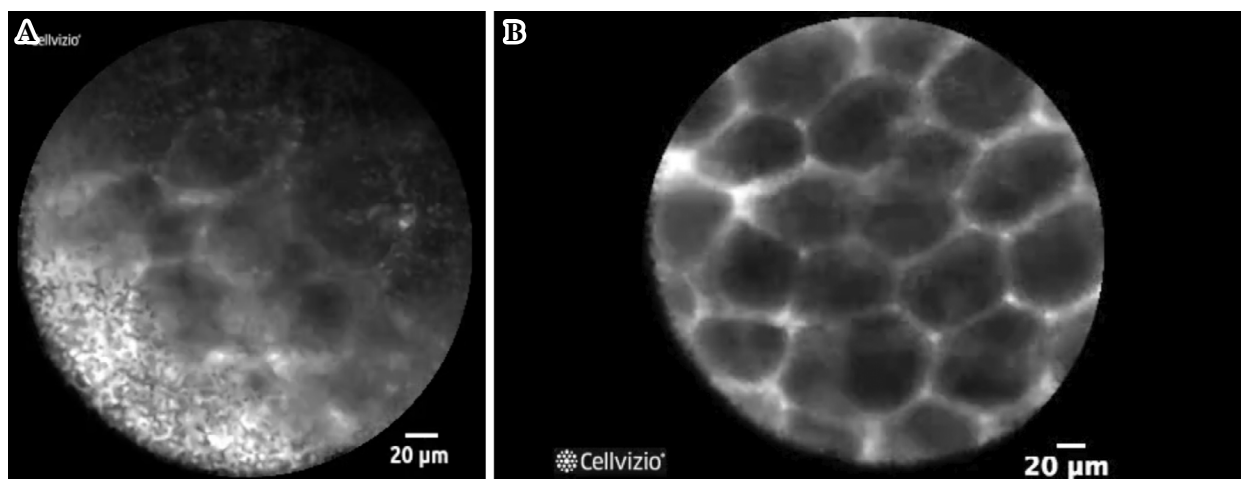
### Case Report

The patient involved in this study gave his written informed consent authorizing the use and disclosure of his protected health information.

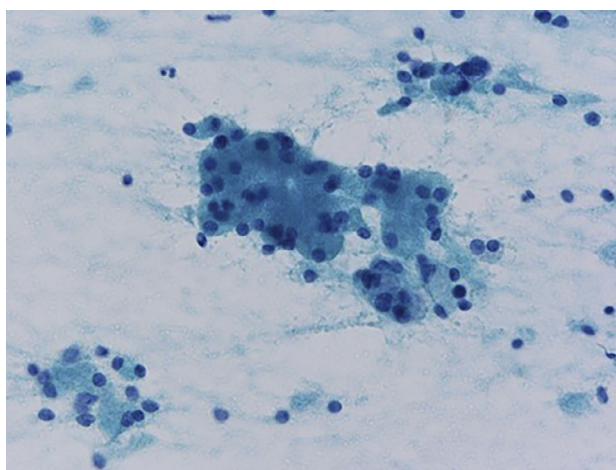
A 47-year-old man was referred to our medical center for the investigation of an SEL that had been detected on EGD during a medical checkup. He had no remarkable medical history and no symptoms. EGD revealed an 18-mm SEL with its umbilication on the greater curvature of the antrum

(Fig. 1). There was a high-density mass on the same lesion on contrast-enhanced computed tomography. EUS showed a hypoechoic mass with a partially high-echoic lesion, arising from the third layer of the gastric wall (Fig. 2).

The AQ-Flex 19 probe (Mauna Kea Technologies, Paris, France) was preloaded into a 19-gauge EUS needle and locked into position, with 2 mm being exposed beyond the tip (Fig. 3). This SEL was punctured, and 2 mL of fluorescein sodium was injected. nCLE findings revealed a dark lobular stricture similar to “coffee beans,” which is typical for normal pancreas acinus (13, 14) (Fig. 4). Then, with the nCLE probe, EUS-FNA was performed using the slow pull method. There were no complications. The cytology result was compatible with pancreatic acinus (Fig. 5). We diagnosed the patient with aberrant pancreas based on EGD, EUS, cytology and nCLE findings.



**Figure 4.** A: Normal pancreas acinus on needle-based probe confocal laser endomicroscopy. A dark lobular structure similar to “coffee beans” can be seen. B: Typical image of pancreatic acinus on confocal microendoscopy (quoted from cellvizio.net).



**Figure 5.** Pancreatic normal acinar cells: Individual cells show granular cytoplasm, round nuclei at the basal layer, and fine, granular chromatin (×400).

## Discussion

Aberrant pancreatic tissue is typically hypoechoic and limited to the third (submucosal) layer, sometimes extending to the fourth (muscle) layer (15). The most common site of the aberrant pancreas is in the gastrointestinal tract, such as the stomach, especially in the antrum (38-26%), duodenum (28-36%), and jejunum (16%) (16, 17). The characteristic EUS features of an aberrant pancreas are indistinct borders, lobulated margins, the presence of anechoic duct-like structures, a mural growth pattern, and localization within two or more layers (18, 19).

EUS-FNA has been performed to obtain pathological diagnoses from SELs, but the accuracies of such diagnoses are not high enough (Table) (3-5, 7, 20-26). Like GISTs, aberrant pancreas, leiomyoma and schwannoma, the cells comprising gastric SELs are so strongly connected that it is dif-

ficult to obtain sufficient tissue to make a diagnosis using EUS-FNA. An alternative modality for making a histological diagnosis of SELs is therefore needed.

nCLE enables a real-time *in vivo* histopathology evaluation during EUS. With nCLE, cellular imaging and the evaluation of tissue architecture at the focal plane can be performed during endoscopy (27). Fluorescein is usually administered immediately before imaging. Optimum images are obtained within 30 seconds to 8 minutes after injection but can be interpreted for as long as 60 minutes (28). A normal pancreas looks similar to “coffee beans”, an appearance that corresponds to the histological structures of acinus (13, 14). Given our findings, nCLE seems to be a feasible method for diagnosing aberrant pancreas, overcoming difficulties in obtaining sufficient tissue for a diagnosis. The only adverse event reported to be associated with nCLE is allergic reactions to intravenous fluorescein, but most such cases are mild.

**Table. A Review of the Diagnostic Yield of Endoscopic Ultrasonography Fine-needle Aspiration in Upper Gastrointestinal Subepithelial Lesions.**

| Year, Study Design      | N   | Most frequent tumors | Mean size | Mean number of FNA† passes | Diff-Quick stain | Needle                           | Accuracy | The number of reserch centers |
|-------------------------|-----|----------------------|-----------|----------------------------|------------------|----------------------------------|----------|-------------------------------|
| 2004, retrospective(20) | 60  | carcinoma, 40%       | -         | -                          | presence         | 22G                              | 89%      | single center                 |
| 2007, prospective(6)    | 53  | GIST*, 62%           | -         | 2.4(1-6)                   | presence         | 22G                              | 82%      | single center                 |
| 2009, retrospective(21) | 112 | GIST*, 31%           | 28.5      | 5.3(3-9)                   | presence         | 22G                              | 83.9%    | two centers                   |
| 2009, prospective(22)   | 53  | GIST*, 73%           | 40        | 4(3-5)                     | absence          | 19G                              | 63%      | single center                 |
| 2010, prospective(4)    | 40  | GIST*, 68%           | 43        | 2.1                        | presence         | 22G                              | 70%      | single center                 |
| 2010, prospective(23)   | 50  | leiomyoma, 34%       | -         | 3.7(2-5)                   | presence(80%)    | 19G in 6cases<br>22G in 49cases§ | 80%      | two centers                   |
| 2010, retrospective(24) | 141 | GIST*, 59%           | 29.9      | 1-5                        | presence         | 22G                              | 82.3%    | single center                 |
| 2010, prospectove(5)    | 47  | GIST*, 51%           | -         | -                          | absence          | 19G in 19cases<br>22G in 35cases | 74.4%    | two centers                   |
| 2011, retrospective(25) | 65  | GIST*, 68%           | -         | 2.3(1-5)                   | presence(65%)    | 19G and 22G¶                     | 80%      | two centers                   |
| 2012, retrospective(26) | 46  | GIST*, 52%           | -         | -                          | absence          | 22G in 27cases<br>25G in 27cases | 80.4%    | single center                 |
| 2015, prospective(3)    | 20  | GIST*, 35%           | 23.6      | 1-4                        | absence          | 22G                              | 65%      | single center                 |
| 2016, prospective(7)    | 20  | leiomyoma, 27%       | 16        | 2.6(1-5)                   | presence         | 22G                              | 75%      | multi centers                 |

\*gastrointestinal stromal tumor

†fine-needle aspiration

§The needles of 19G and 22G were used in 5cases.

¶details are not reported.

This case represents the first experience in which nCLE led to a gastric SEL being diagnosed as aberrant pancreas. nCLE can increase the diagnostic yield of aberrant pancreas and may reduce the rate of post-FNA complications, such as pancreatitis and hemorrhaging, as it requires fewer passes and punctures than FNA. Indeed, one pass is enough when specific features are observed on nCLE, as obtaining enough tissue from gastric SEL for a diagnosis is usually difficult with EUS-FNA even with multiple passes. In the present case, we performed only one pass for EUS-FNA along with nCLE by a slow pull method without ROSE. We were able to identify the typical features of pancreatic acinus on nCLE; this suggests that multiple FNA procedures may become unnecessary and that omitting ROSE may be feasible, allowing for the repeated use of specimens for cytology. Case series are needed to confirm the diagnostic performance of nCLE for detecting aberrant pancreas.

In conclusion, although EUS-FNA is the widely used gold standard for the histological and cytological diagnosis of aberrant pancreas, nCLE may be a less-invasive diagnostic modality or at least provide an additional evaluation method.

**The authors state that they have no Conflict of Interest (COI).**

## References

- Rosch T, Kapfer B, Will U, et al. Accuracy of endoscopic ultrasonography in upper gastrointestinal submucosal lesions: a prospective multicenter study. *Scand J Gastroenterol* **37**: 856-862, 2002.
- Karaca C, Turner BG, Cizginer S, Forcione D, Brugge W. Accuracy of EUS in the evaluation of small gastric subepithelial lesions. *Gastrointest Endosc* **71**: 722-727, 2010.
- Ikehara H, Li Z, Watari J. Histological diagnosis of gastric submucosal tumors: A pilot study of endoscopic ultrasonography-guided fine-needle aspiration biopsy vs mucosal cutting biopsy. *World J Gastrointest Endosc* **7**: 1142-1149, 2015.
- Fernandez-Esparrach G, Sendino O, Sole M, et al. Endoscopic ultrasound-guided fine-needle aspiration and trucut biopsy in the diagnosis of gastric stromal tumors: a randomized crossover study. *Endoscopy* **42**: 292-299, 2010.
- Philipper M, Hollerbach S, Gabbert HE, et al. Prospective comparison of endoscopic ultrasound-guided fine-needle aspiration and surgical histology in upper gastrointestinal submucosal tumors. *Endoscopy* **42**: 300-305, 2010.
- Akahoshi K, Sumida Y, Matsui N, et al. Preoperative diagnosis of gastrointestinal stromal tumor by endoscopic ultrasound-guided fine needle aspiration. *World J Gastroenterol* **13**: 2077-2082, 2007.
- Schlag C, Menzel C, Gotzberger M, et al. Endoscopic ultrasound-guided tissue sampling of small subepithelial tumors of the upper gastrointestinal tract with a 22-gauge core biopsy needle. *Endosc Int Open* **5**: E165-E171, 2017.
- Goto S, Okasaki T, Koga H, et al. Ectopic pancreas presenting as a submucosal gastric tumor: case report and literature review. *Pediatr Surg Int* **27**: 107-109, 2011.
- Attwell A, Sams S, Fukami N. Diagnosis of ectopic pancreas by endoscopic ultrasound with fine-needle aspiration. *World J Gastroenterol* **21**: 2367-2373, 2015.
- Alper E, Onur I, Arabul M, Unsal B. Endoscopic ultrasound-guided tissue sampling: How can we improve the results? *Turk J Gastroenterol* **27**: 1-3, 2016.
- Becker V, Wallace MB, Fockens P, et al. Needle-based confocal endomicroscopy for in vivo histology of intra-abdominal organs: first results in a porcine model (with videos). *Gastrointest Endosc* **71**: 1260-1266, 2010.
- Karia K, Waxman I, Konda VJ, et al. Needle-based confocal endomicroscopy for pancreatic cysts: the current agreement in interpretation. *Gastrointest Endosc* **83**: 924-927, 2016.
- Giovannini M. Needle-based confocal laser endomicroscopy. *Endosc Ultrasound* **4**: 284-288, 2015.
- Bastidas AB, Holloman D, Lankarani A, Nieto JM. Endoscopic ultrasound-guided needle-based probe confocal laser endomicroscopy (nCLE) of intrapancreatic ectopic spleen. *ACG Case Rep*

- J 3: 196-198, 2016.
15. Barrocas A, Fontenelle LJ, Williams MJ. Gastric heterotopic pancreas: a case report and review of literature. *Am Surg* **39**: 361-365, 1973.
  16. Min YW, Park HN, Min BH, Choi D, Kim KM, Kim S. Preoperative predictive factors for gastrointestinal stromal tumors: analysis of 375 surgically resected gastric subepithelial tumors. *J Gastrointest Surg* **19**: 631-638, 2015.
  17. Seo SW, Hong SJ, Han JP, et al. Accuracy of a scoring system for the differential diagnosis of common gastric subepithelial tumors based on endoscopic ultrasonography. *J Dig Dis* **14**: 647-653, 2013.
  18. Park SH, Kim GH, Park DY, et al. Endosonographic findings of gastric ectopic pancreas: a single center experience. *J Gastroenterol Hepatol* **26**: 1441-1446, 2011.
  19. Matsushita M, Hajiro K, Okazaki K, Takakuwa H. Gastric aberrant pancreas: EUS analysis in comparison with the histology. *Gastrointest Endosc* **49**: 493-497, 1999.
  20. Vander Noot MR 3rd, Eloubeidi MA, Chen VK. Diagnosis of gastrointestinal tract lesions by endoscopic ultrasound-guided fine-needle aspiration biopsy. *Cancer* **102**: 157-163, 2004.
  21. Hoda KM, Rodriguez SA, Faigel DO. EUS-guided sampling of suspected GI stromal tumors. *Gastrointest Endosc* **69**: 1218-1223, 2009.
  22. Polkowski M, Gerke W, Jarosz D. Diagnostic yield and safety of endoscopic ultrasound-guided trucut [corrected] biopsy in patients with gastric submucosal tumors: a prospective study. *Endoscopy* **41**: 329-334, 2009.
  23. Turhan N, Aydog G, Ozin Y, Cicek B, Kurt M, Oguz D. Endoscopic ultrasonography-guided fine-needle aspiration for diagnosing upper gastrointestinal submucosal lesions: a prospective study of 50 cases. *Diagn Cytopathol* **39**: 808-817, 2011.
  24. Mekky MA, Yamao K, Sawaki A, et al. Diagnostic utility of EUS-guided FNA in patients with gastric submucosal tumors. *Gastrointest Endosc* **71**: 913-919, 2010.
  25. Watson RR, Binmoeller KF, Hamerski CM, et al. Yield and performance characteristics of endoscopic ultrasound-guided fine needle aspiration for diagnosing upper GI tract stromal tumors. *Dig Dis Sci* **56**: 1757-1762, 2011.
  26. Rong L, Kida M, Yamauchi H, Okuwaki K, et al. Factors affecting the diagnostic accuracy of endoscopic ultrasonography-guided fine-needle aspiration (EUS-FNA) for upper gastrointestinal submucosal or extraluminal solid mass lesions. *Dig Endosc* **24**: 358-363, 2012.
  27. American Society for Gastrointestinal Endoscopy Technology Committee. Confocal laser endomicroscopy. *Gastrointest Endosc* **80**: 928-938, 2014.
  28. Becker V, von Delius S, Bajbouj M, Karagianni A, Schmid RM, Meining A. Intravenous application of fluorescein for confocal laser scanning microscopy: evaluation of contrast dynamics and image quality with increasing injection-to-imaging time. *Gastrointest Endosc* **68**: 319-323, 2008.

The Internal Medicine is an Open Access article distributed under the Creative Commons Attribution-NonCommercial-NoDerivatives 4.0 International License. To view the details of this license, please visit (<https://creativecommons.org/licenses/by-nc-nd/4.0/>).