

LETTER TO THE EDITOR

Clinicopathological features of pseudomyogenic hemangioendothelioma and precision therapy based on whole exome sequencing

Dear Editor

Pseudomyogenic hemangioendothelioma (PHE) is a newly recognized subtype of hemangioendothelioma characterized by the presence of fibrohistiocytic and myoid cells arranged in a fibroma-like or dermatofibroma-like pattern [1]. This rare type of tumor was first named by Hornick and Fletcher [2] and categorized as the novel soft tissue tumor classification system of the World Health Organization in 2013 [3]. Prior to this, it was referred to as fibroma-like variant of epithelioid sarcoma (ES) and epithelioid sarcoma-like hemangioendothelioma [4].

Reported literature describing PHE showed that more than 65% of cases present with multifocal lesions may involve the derma, subcutaneous tissue, muscle, and bone simultaneously [5], and may make some lesions difficult to resect [5]. Furthermore, PHE has been found to be associated with a significant risk of local-regional recurrence of nearly 36% after surgical resection [2]. Clearly, the therapeutic dilemma of PHE is challenged by unresectability and high recurrence risk. However, as a rare subtype of hemangioendothelioma, no effective systemic therapy has been established for unresectable PHE.

In the present study, we report two PHE patients who suffered from recurrence and metastasis after an initial operation. Their initial pathological diagnosis was misdiagnosed as ES based on previous histological examination.

Case 1 is from a 51-year-old woman who presented with a recurrent soft tissue tumor combined with skin ulceration in her right calf after local resection at the Tianjin Changzheng Hospital (Hongqiao District, Tianjin, China) on December 15, 2017. She was referred to our department, where paraffin-embedded sections from the previous operations were reviewed for immunohistochemistry staining which

was positive for cytokeratin (CK), CK19, vimentin, CD31, ETS-related gene (ERG), Freund's leukemia integration site 1 (FLI-1), and integrase interactor 1 (INI-1), but negative for CD34, CD68, CK5/6, CK8/18, epithelial membrane antigen (EMA), smooth muscle actin (SMA), desmin, and S-100. The patient was thereby diagnosed as PHE based on pathological characteristics and immunohistochemical staining. Furthermore, multifocal lesions in the initial operation area, namely, the subcutis of the right lower leg, and the anterior of the right ankle joint, femur, tibia, acetabulum and ischium, were found via positron emission tomography-computed tomography (PET-CT). Subsequently, on January 25, 2018, she underwent a wide surgical resection of the subcutaneous lesions in her right calf and right ankle joint, as well as bone lesions in her right ilium. Tumor tissue samples were stained by hematoxylin and eosin (H&E) and for immunohistochemical markers (Supplementary Figure 1). The neoplastic cells had a rounded epithelioid shape with a prominent eosinophilic cytoplasm and immunohistochemistry findings were in agreement with the aforementioned immunohistochemistry results. Considering that the tumor was recurrent and residual bone lesions were unresectable, whole exome sequencing (WES) of the fresh neoplasm tissue and adjacent normal tissues was performed to identify tumor-related mutations and formulate the next-step for personalized treatment.

Case 1 had mutation of the S-phase kinase-associated protein 2 gene (*SKP2*, Nucleotide variation: c.536+63_536+64insT) detected by WES (Supplementary Table 1). The gene mutation status for Case 1 is summarized in Figure 1. Because *SKP2* is associated with the mammalian target of rapamycin (mTOR) signaling pathway in the Kyoto Encyclopedia of Genes and Genomes database

Abbreviations: CK, cytokeratin; EA, epithelial angiosarcoma; EHE, epithelial hemangioendothelial; EMA, epithelial membrane antigen; ERG, ETS-related gene; ES, epithelioid sarcoma; FLI-1, freund's leukemia integration site 1; INI-1, integrase interactor-1; PET-CT, positron emission tomography-computed tomography; PHE, pseudomyogenic hemangioendothelioma; SKP2, phase kinase-associated protein 2; SMA, smooth muscle actin; WES, whole exome sequence.

This is an open access article under the terms of the Creative Commons Attribution-NonCommercial-NoDerivs License, which permits use and distribution in any medium, provided the original work is properly cited, the use is non-commercial and no modifications or adaptations are made.

© 2020 The Authors. *Cancer Communications* published by John Wiley & Sons Australia, Ltd. on behalf of Sun Yat-sen University Cancer Center

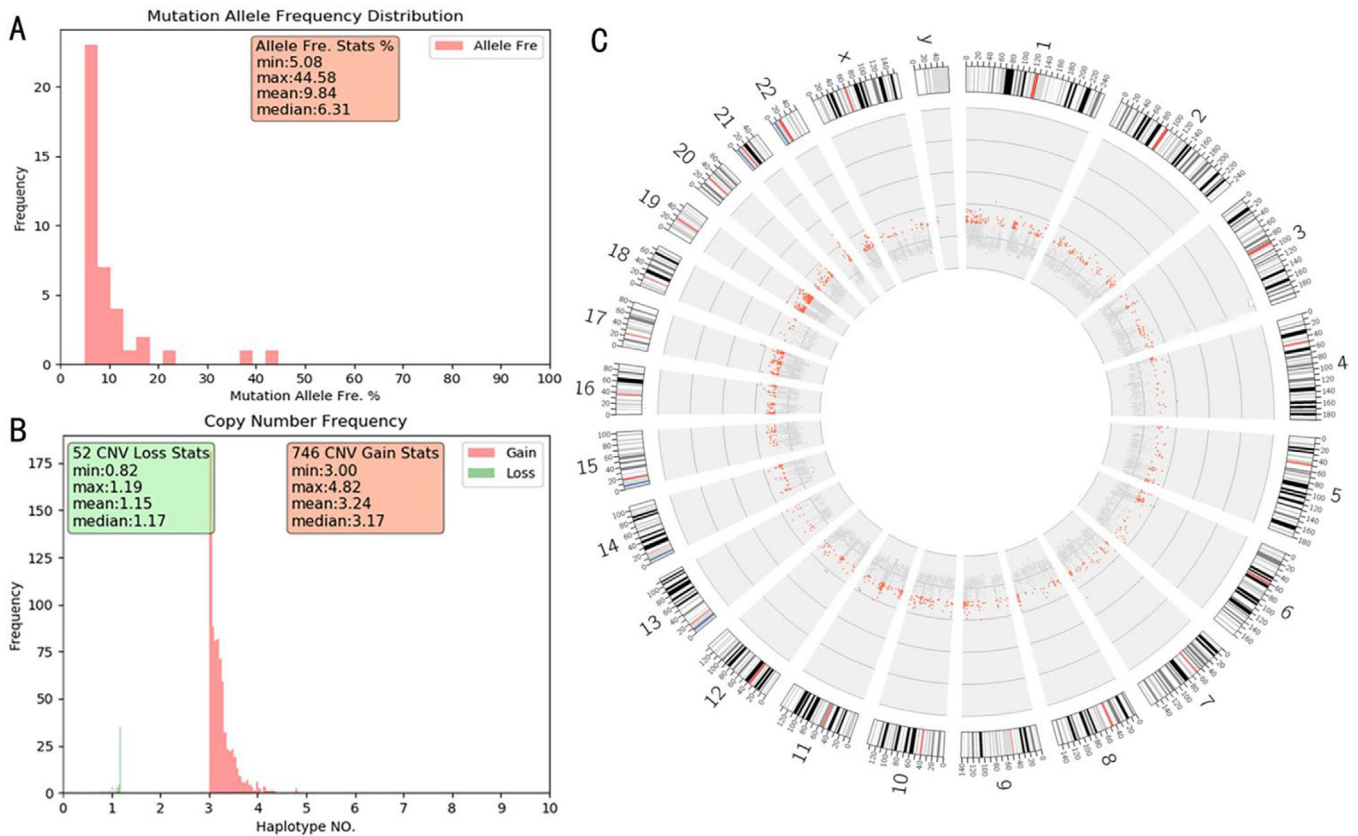


FIGURE 1 The gene mutation status for Case 1. (A) Mutant allele frequency distribution. The allele frequency of mutated genes was 5.08% to 44.58%, with a mean of 9.84%, and median of 6.31%. (B) The frequency of copy number variation (CNV): 52 genes had the CNV of loss status, from 0.82 to 1.19 times; 746 genes had the CNV of gain status, from 3.00 to 4.82 times. (C) The CNV distribution in autosome and sex chromosome

(Supplementary Figure 2), the mTOR inhibitor everolimus was recommended for treatment and was approved by the review board at Tianjin Medical University Cancer Hospital. Written informed consent for everolimus as adjuvant therapy was obtained from the patient. Everolimus (Novartis Pharma Schweiz AG, Schaffhauserstrasse, 4332 Stein, Switzerland) treatment was started at 0.8 mg/m²/d on March 1, 2018, and dose adjustments were made to maintain the drug at a therapeutic level of 10–15 ng/mL. No relapse occurred and the bone lesions were all stable at the last radiological follow-up on March 3, 2019 (Figure 2A–2H). Additionally, the abundance of circulating tumor DNA (ctDNA) in the whole peripheral blood was examined and was 0.17 on February 2, 2018, and was 0.13 on May 19, 2018, and April 10, 2019 (Figure 2I). The overall clinical course of this patient is shown in Figure 2I. The cost of treatment and examination were covered by the patient.

Case 2 is from a 28-year-old male who was admitted to the Tianjin Hospital (Hexi District, Tianjin, China) with a pathological left femoral neck fracture and received total hip arthroplasty on April 21, 2017. ES was diagnosed by pathological examination after surgery. However, because of emerging skin lesions (Figure 2J) in his buttock and

left calf after 2 weeks, he visited our bone and soft tissue tumor clinic after ES was diagnosed by initial pathological examination. The tumor section of the bone and an excisional biopsy sample of his dermis lesions were re-examined by H&E and immunohistochemistry staining. Tumor cell morphology showed plump spindle neoplastic cells in plexiform configurations with abundant eosinophilic cytoplasm. The cells of interest were immunoreactive for CK, CD31, ERG, FLI-1, B-cell lymphoma 2 (Bcl-2) and INI-1, and negative for EMA, CD34, SMA, S-100, Sry-related HMG box gene 10 (SOX-10), and D2-40. The bone and dermis lesions were all confirmed to be PHE not ES on May 5, 2017. Simultaneously, multifocal subcutaneous and bone lesions were identified by PET-CT (Figure 2K–2P). However, the patient refused sequencing and treatment due to a health insurance problem, and eventually, he stopped attending our clinic.

To date, available data on PHE cases include the 2 current cases and 187 cases from literature have been reviewed (Supplementary Table 2). Of the patients, it was revealed that 142 cases were male and 47 were females, with a male: female ratio of approximately 3:1. The average age was 36 years and the median age was 42 (10–82 years) years. PHE often occurs in different tissue planes. There were 120 (63.5%) cases with

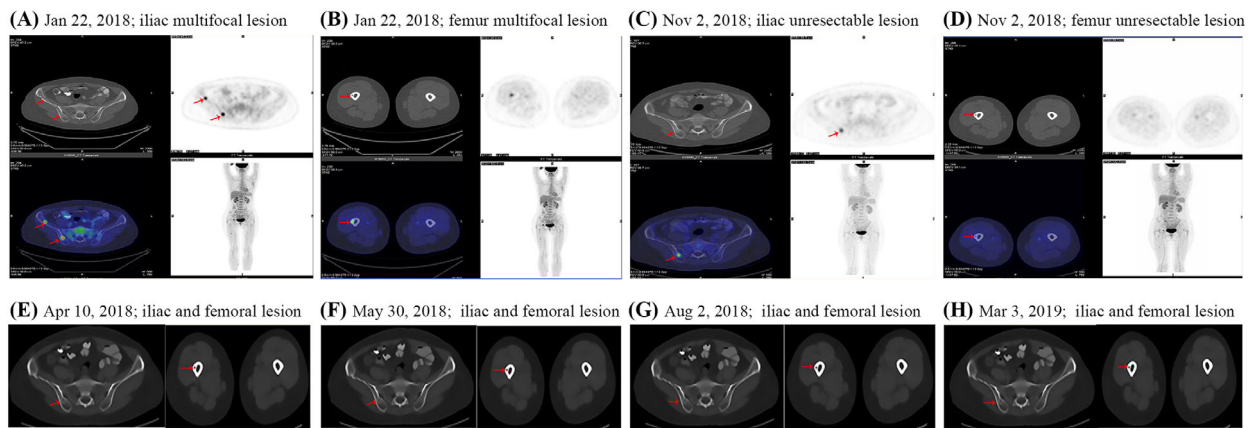
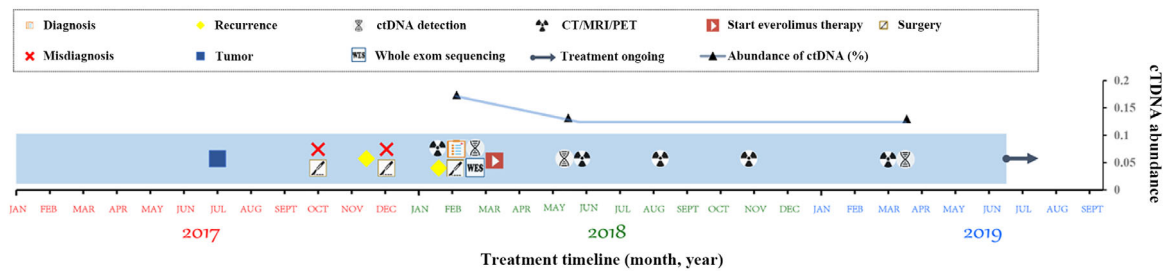
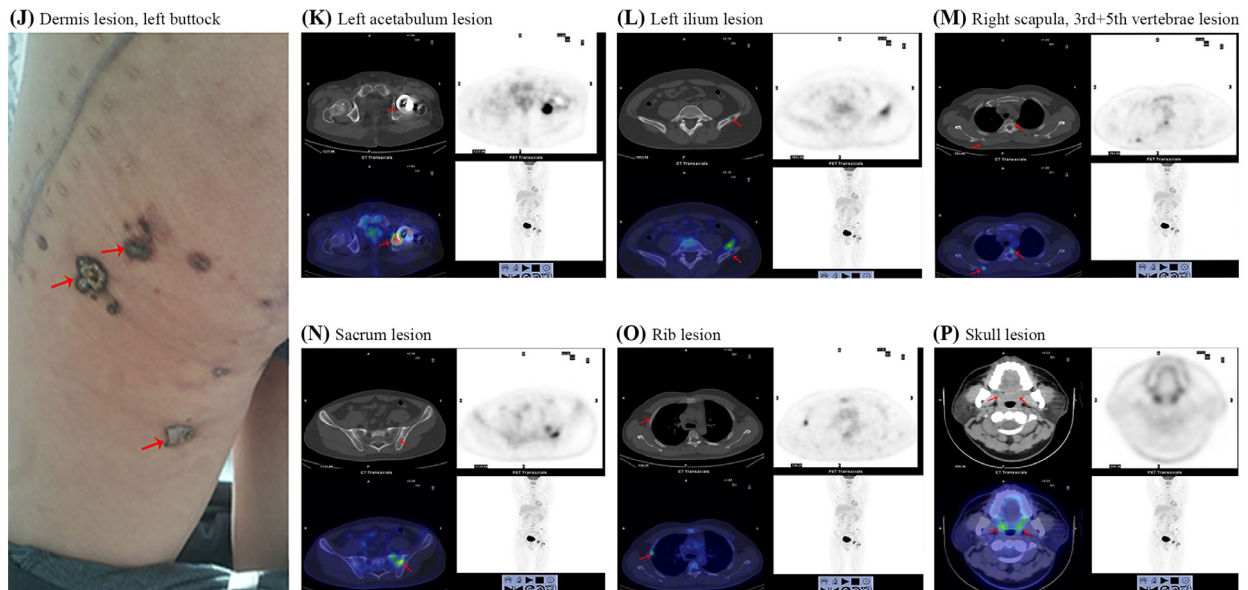
(A-I) Case number 1:**(I) Schematic diagram of the clinical course and follow-up for Case 1.****(J-P) Case number 2:**

FIGURE 2 Clinical representation of the presented 2 cases. The red arrows represent the location of the corresponding lesions. (A-I) The radiological images and treatment course at different time points of Case 1. PET-CT showing the multifocal lesions in the (A) iliac and (B) femur on admission to our hospital on January 22, 2018, and the standard uptake value (SUV) for 18F-fluorodeoxyglucose (18F-FDG) was 8.7 in lesions of the iliac and femur. PET-CT showing the SUV index for the unresectable lesions in the (C) iliac and (D) femur was decreased to 3.2 during the everolimus treatment. (E-H) The residual lesions in the iliac and femur for was stable on CT-scan during the everolimus treatment on (E) April 10, 2018, (F) May 30, 2018, (G) August 2, 2018, and (H) March 3, 2019. (I) The schematic diagram illustrating the clinical course and follow-up time for Case 1. The abundance of ctDNA was 0.17 after the wide surgical resection and decreased to 0.13 during the everolimus therapy. Lesions were indicated with a red arrow. (J-P) The images of Case 2 lesions at different time points. (J) Dermis lesions at the left buttock. (K-P) PET-CT images showing multifocal distribution of Case 2 lesions at (K) the left acetabulum, (L) left ilium, (M) right scapula, and the third and fifth thoracic vertebrae, (N) sacrum, (O) rib and (P) skull

a multifocal distribution involving the dermis, subcutaneous tissue, deep muscle tissue, or bone involvement. A solitary lesion existed in 69 (36.5%) cases (Supplementary Table 2). Moreover, the tumor always involved different anatomic regions. For instance, based on the anatomical regions of the lesions in PHE patients reported in literature, the anatomical regions of the human body were divided into the limbs (upper and lower limbs), head and neck, and trunk. The extremities (137/189, 72.5%) were the most common region for PHE, especially the lower extremities (106/189, 56.1%), followed by the upper limb (31/189, 16.4%). The neck and head regions were affected in 11 cases (5.8%) and 41 cases (21.7%) were located in the trunk region (Supplementary Table 2).

Based on the reported literature, PHE has a high similarity with ES in its histological profile. The neoplastic cells showed a rounded epithelioid shape with a prominent eosinophilic cytoplasm, mitotic activity was low and nuclear pleomorphism was mild to moderate. The tumors were characterized by sheets and ill-defined nodules, which is why Billings et al. termed them as ES-like hemangioendotheliomas [4, 6]. The rate of misdiagnosis was approximately 39.2% (74/189) for initial pathological diagnosis between 1992 and 2019 (Supplementary Table 2). Moreover, not only ES but also epithelial hemangioendothelioma (EHE) and epithelial angiosarcoma (EA) should be considered as its differential diagnosis (Supplementary Table 3) [4]. Endothelial markers such as CD31, FLI-1 and CD34 were found to be positive in ES, EA and EHE by immunohistochemical staining. However, CD34 was observed to be consistently negative in PHE, while the other endothelial markers were positive. Furthermore, positive INI-1 staining and negative S-100, EMA and SMA immunohistochemical staining are meaningful in the differential diagnosis. In addition, frequent *SERPINE1-FOSB* or *ACTB-FOSB* fusion genes can be detected in PHE, not in ES, EA or EHE (Supplementary Table 3). Compared with ES and EA, PHE has a low potential distant metastasis in biological behavior (Supplementary Table 3). Above all, the specific clinical characteristics, immunohistochemical staining and recurrent fusion genes can be used to establish a correct diagnosis. In our presented cases, the two patients were both initially misdiagnosed as ES. They were both referred to our department after which paraffin-embedded sections from previous operations were reviewed for immunohistochemistry staining, and were found to be positive for CK, vimentin, CD31, ERG, FLI-1 and INI-1 but negative for CD34, EMA, SMA, desmin, and S-100 (Supplementary Figure 1B-D). Although the FOSB fusion status was not tested in our cases, the diagnosis of PHE was established based on clinical features, HE staining and immunohistochemistry staining.

PHE has an indolent biological behavior with a high rate of local recurrence and low-risk for metastasis after resection

[5]. In 110 patients with available follow-up data, the tumors of 62 patients (56.4%) relapsed or metastasized to adjacent organs after initial surgical resection, and even radical surgical resection such as amputation could not prevent the local recurrence and metastasis (Supplementary Table 2). Based on the published literature, adjuvant chemotherapy or radiotherapy did not satisfactorily control the disease. In 13 patients with available adjuvant treatment data, 5 (38.5%) patients had disease that progressed after chemotherapy or radiotherapy (Supplementary Table 2). In contrast, 3 chemoresistant PHE cases achieved promising results after target therapy [7-10]. Therefore, this suggests that targeted therapy seems to be more beneficial than traditional treatment in PHE.

The two cases that we reported both progressed after initial treatment. It has been confirmed that *SKP2* is an important oncogene in many types of cancer, a negative regulator of the mTOR complex and can thereby be targeted by mTOR inhibitors [11-13]. Reported literature demonstrated that the mTOR inhibitor has achieved satisfactory results in treating chemo-resistance PHE cases [7-10]. As mentioned above, case 1 received everolimus treatment which produced a notable local maintenance effect. This is the first study reporting *SKP2* mutations in PHE patients. Combined with our cases and reported literature, precision therapy for gene mutations seems to be a strategy for the treatment of this rare type of hemangioendothelioma, especially for the residual or unresectable lesions. The treatment experience in Case 1 also presents a good example of the application of precision therapy in rare diseases. Although patients could achieve a stable status with mTOR inhibitors, a longer follow-up period is still needed because of the indolent biological behavior of PHE. Therefore, we still cannot confirm whether mTOR inhibitors have a curative effect on recurrent or unresectable PHE but they can be used as maintenance therapy with no major side effects.

PHE is a rare tumor characterized by multifocal distribution involving different tissue planes. It can be easily misdiagnosed, so specific immunochemical staining is advised to establish an accurate diagnosis. Based on the findings from the presented 2 cases, tumor cells positive for epithelial (CK) and endothelial markers (CD31, FLI-1), but negative to myogenic markers (EMA, SMA, vimentin and S-100) are vital to diagnose PHE. For unresectable or recurrent lesions, precision therapy targeting mutations detected by WES is a promising option that warrants further investigation.

FUNDING

This work was supported by the Key Nature Science Foundation of Tianjin (grant nos. 18YFZCSY00550 to Jilong Yang)

ACKNOWLEDGEMENT

Not applicable

AUTHORS CONTRIBUTIONS

JQW, ZCL, GZ, YY and JLY made substantial contributions to the conception and design of this work and the acquisition, analysis and interpretation of data. NN, CZ and JL made substantial contributions to the acquisition, analysis, and interpretation of data for the work. All authors have read and approved the final manuscript.

AVAILABILITY OF DATA AND MATERIALS

The datasets used and/or analyzed during the current study are available from the corresponding author on reasonable request

ETHICS APPROVAL AND CONSENT TO PARTICIPATE

The mTOR inhibitor everolimus was recommended for treatment and was approved by the review board at Tianjin Medical University Cancer Hospital. Written informed consent for everolimus as adjuvant therapy was obtained from the patient in accordance with the Declaration of Helsinki.

CONSENT FOR PUBLICATION

Not applicable

COMPETING INTERESTS

The author reports no conflicts of interest in this work.

Junqiang Wei^{1,2,4,*}

Zhichao Liao^{1,2,*}

Gang Zhao^{2,3}

Nazmun Nahar^{1,2,5}

Chao Zhang^{1,2}

Jia Lu^{1,2}

Yun Yang^{1,2}

Jilong Yang^{1,2}

¹Department of Bone and Soft Tissue Tumors, Tianjin Medical University Cancer Institute and Hospital, Tianjin 300060, P. R. China

²National Clinical Research Center for Cancer, Key Laboratory of Cancer Prevention and Therapy, Tianjin's Clinical Research Center for Cancer, Tianjin Medical University Cancer Institute and Hospital, Tianjin 300060, P. R. China

³Department of Pathology, Tianjin Medical University Cancer Institute and Hospital, Tianjin 300060, P. R. China

⁴Department of Orthopedics, Affiliated Hospital of Chengde Medical College, Chengde, Hebei 067000, P. R. China

⁵International Medical School, Tianjin Medical University, Tianjin 300061, P. R. China

Correspondence

Prof. Jilong Yang, Huanhu Xi Road, Ti Yuan Bei, Hexi District, Tianjin Medical University Cancer Institute and Hospital, Tianjin 300060, P. R. China.

Email: yangjilong@tjmuch.com

*Junqiang Wei and Zhichao Liao contributed equally to this work.

REFERENCES

- Mirra JM, Kessler S, Bhuta S, Eckardt J. The fibroma-like variant of epithelioid sarcoma. A fibrohistiocytic/myoid cell lesion often confused with benign and malignant spindle cell tumors. *Cancer*. 1992;69(6):1382–1395.
- Hornick JL, Fletcher CD. Pseudomyogenic hemangioendothelioma: a distinctive, often multicentric tumor with indolent behavior. *Am J Surg Pathol*. 2011;35(2):190–201.
- Jo VY, Fletcher CD. WHO classification of soft tissue tumours: an update based on the 2013 (4th) edition. *Pathology*. 2014;46(2):95–104.
- Billings SD, Folpe AL, Weiss SW. Epithelioid sarcoma-like hemangioendothelioma. *Am J Surg Pathol*. 2003;27(1):48–57.
- Inyang A, Mertens F, Puls F, Sumathi V, Inwards V, Folpe A, et al. Primary Pseudomyogenic Hemangioendothelioma of Bone. *Am J Surg Pathol*. 2016;40(5):587–598.
- Billings SD, Folpe AL, Weiss SW. Epithelioid Sarcoma-like hemangioendothelioma (pseudomyogenic hemangioendothelioma). *Am J Surg Pathol*. 2011;35(7):1088–1089.
- Ozeki M, Nozawa A, Kanda K, Hori T, Nagano A, Shimada A, et al. Everolimus for Treatment of Pseudomyogenic Hemangioendothelioma. *J Pediatr Hematol Oncol*. 2017;39(6): e328–e331.
- Gabor KM, Sapi Z, Tiszlavicz LG, Fige A, Bereczki C, Bartyk K. Sirolimus therapy in the treatment of pseudomyogenic hemangioendothelioma. *Pediatr Blood Cancer*. 2018;65(2): e26781–e26785.
- Danforth OM, Jamulonis K, Vavra K, Oh C, Brickman A, Ebersole J, et al., Effective Use of Sirolimus and Zoledronic Acid for Multicentric Pseudomyogenic Hemangioendothelioma of the Bone in a Child: Case Report and Review of Literature. *J Pediatr Hematol Oncol*. 2019; 41(5): 382–387.
- Joseph J, Wang WL, Patnana M, Ramesh N, Benjamin R, Patel S, et al. Cytotoxic and targeted therapy for treatment of pseudomyogenic hemangioendothelioma. *Clin Sarcoma Res*. 2015;5: 22–28.
- Shapira M, Kakiashvili E, Rosenberg T, Hershko DD. The mTOR inhibitor rapamycin down-regulates the expression of the ubiquitin ligase subunit Skp2 in breast cancer cells. *Breast Cancer Res*. 2006;8(4):46–55.
- Geng Q, Liu J, Gong Z, Chen S, Chen S, Li X, et al. Phosphorylation by mTORC1 stabilizes Skp2 and regulates its oncogenic function in gastric cancer. *Mol Cancer*. 2017;16(1):83–95.
- Jin G, Lee SW, Zhang X, Cai Z, Gao Y, Chou PC, et al. Skp2-Mediated RagA Ubiquitination Elicits a Negative Feedback to Prevent Amino-Acid-Dependent mTORC1 Hyperactivation by Recruiting GATOR1. *Mol Cell*. 2015;58(6):989–1000.

SUPPORTING INFORMATION

Additional supporting information may be found online in the Supporting Information section at the end of the article.