



Topological Analysis for Arteriovenous Malformations via Computed Tomography Angiography: Part 1: Mathematical Concepts

Yuki Hata, MD*

Keigo Osuga, MD, PhD†

Tateki Kubo, MD, PhD*

Ken Matsuda, MD, PhD*

Koichi Tomita, MD, PhD*

Mamoru Kikuchi, MD, PhD*

Takashi Fujiwara, MD*

Kenji Yano, MD, PhD*

Ko Hosokawa, MD, PhD*

Background: Evaluating the progression of soft-tissue arteriovenous malformation (AVMs) is still problematic. To establish a quantitative method, we took a morphological approach.

Methods: Normal blood vessels in early-phase 3D-computed tomography angiography images are theoretically expected to be tree-like structures without loops, whereas AVM blood vessels are expected to be mesh-like structures with loops. Simplified to the utmost limit, these vascular structures can be symbolized with wire-frame models composed of nodes and connecting edges, in which making an extra loop always needs one more of edges than of nodes.

Results: Total amount of abnormal vascular structures is estimated from a simple equation: Number of vascular loops = 1 - ([Number of nodes] - [Number of edges]).

Conclusion: Abnormalities of AVM vascular structures can be mathematically quantified using computed tomography angiography images. (*Plast Reconstr Surg Glob Open* 2014;2:e205; doi: 10.1097/GOX.000000000000163; Published online 28 August 2014.)

Soft-tissue arteriovenous malformations (AVMs) progress asymptotically or recur indistinguishably from normal blood vessels. Despite that, understanding of their progression usually relies on approximate staging according to symptoms¹ or qualitative visual assessment of imaging examinations. Against this dilemma, numerous attempts have been made to establish quantitative evaluation methods.

From the *Department of Plastic Surgery, Osaka University Graduate School of Medicine, Osaka, Japan; and †Department of Diagnostic and Interventional Radiology, Osaka University Graduate School of Medicine, Osaka, Japan.

Received for publication December 27, 2013; accepted June 25, 2014.

Copyright © 2014 The Authors. Published by Lippincott Williams & Wilkins on behalf of The American Society of Plastic Surgeons. *PRS Global Open* is a publication of the American Society of Plastic Surgeons. This is an open-access article distributed under the terms of the Creative Commons Attribution-NonCommercial-NoDerivatives 3.0 License, where it is permissible to download and share the work provided it is properly cited. The work cannot be changed in any way or used commercially.

DOI: 10.1097/GOX.000000000000163

From a functional viewpoint, evaluation of total shunt blood flow using transarterial lung perfusion scans²⁻⁴ and measurement of blood pool volume with whole-body blood pool scans by Lee et al^{2,4,5} are the most quantitative methods. However, these methods based on nuclear medicine are problematic for their invasion and limited site of application.

From a morphometric viewpoint, Kaji et al⁶ used magnetic resonance imaging and World Health Organization Response Criteria (product of lesion major and minor axes in cross-section). However, it is difficult to apply it to vascular malformations, which are irregular in shape with indistinct borders, easily expanding and collapsing.

Considering these unmet needs, we searched for another approach to meet the anatomical nature of AVMs and set the first research objective to establish a morphological solution to quantify abnormalities of AVM vascular structures.

Disclosure: The authors have no financial interest to declare in relation to the content of this article. The Article Processing Charge was paid for by the authors.

METHODS

We anticipated utilization of computed tomography angiography (CTA) results for retrospective evaluation because it is a widespread, less-invasive method of testing AVMs. Moreover, because of their relatively higher contrast, obtaining clear and stable vascular segmentation⁷ is easier than Magnetic Resonance Angiography (MRA).⁸⁻¹⁰

We also applied 2 mathematical theories, namely topology and graph theory, to quantify abnormalities of vascular structures.

Simplification via Topological Homeomorphism

Topology is a relatively new field of geometry that focuses on the continuity of regions. For example, as both a coffee cup and a donut share the feature of having only one hole (loop), they are considered homeomorphic with deformation.

Viewed through homeomorphic simplification, the number of loops in an early-phase 3D-CTA image of a normal blood vessel is theoretically expected to be close to zero except for physiological vascular rings, such as at the base of the brain. It is because arteries branch off repeatedly from the aorta and are not rendered with the standard CT resolution after they become arterioles (approximate diameter, 0.1–0.2 mm) (Fig. 1).

Meanwhile, the presence of a described arteriovenous shunt is depicted on early-phase 3D-CTA images as a series of pathways from the feeding artery to the drainage vein. Furthermore, the more abnormal intervascular shortcut appears, the more external loop develops or an existing loop divides.

Quantification of Connectivity with Graph Theory

The appropriate method for loop measurement is graph theory, which is being utilized for engineering problems such as electric circuits and train routes.

If one focuses only on connectivity and dispenses with all other data such as thickness and length, the vascular structure can ultimately be symbolized into a “graph” composed of nodes and edges joining them. The number of loops in the graph can be calculated by a simple calculation using the number of nodes and edges. The principle can be verified and understood by using our “spaghetti and marshmallows vascular model.” This model can be actually manipulated according to only one rule that a marshmallow (node) must be positioned on the tip of each piece of spaghetti (edge).

When a model only diverges and expands repeatedly like the branches or roots of a tree, the total number of nodes keeps one more than edges. It

is because one node is needed for every new edge when branches are added or divided (Fig. 2A).

However, when nodes and edges are added to increase the number of loops, the number of edges will only increase by one extra piece each time. This is because even if a new loop is added or the existing loop is divided, one more edge is needed compared with nodes (Fig. 2B).

RESULTS

Aforementioned mathematical concepts lead to a principle that abnormal connectivities within an AVM lesion can be quantified with the increase of difference between the number of nodes and edges comprising its wire-framed network model. This principle is depicted by the following simple equation:

$$\text{Number of vascular loops} = 1 - ([\text{Number of nodes}] - [\text{Number of edges}]).$$

DISCUSSION

Fundamental Limitation

In clinical applications, there is an inevitable limitation that the number of vascular loops calculated from CTA images is not necessarily the histological amount of arteriovenous shunts within the actual lesion but “describable” shunts to the utmost. However, it is rather the common fundamental limitation for all imaging examinations.

Resolution Constancy

There are 2 important points regarding this technique. The first is that image resolution affects the detection of continuity. For example, the relationship of a blood vessel with its accompanying vessel 0.3 mm away can be sometimes correctly displayed on an image with 0.27 × 0.27 mm pixel size but invari-

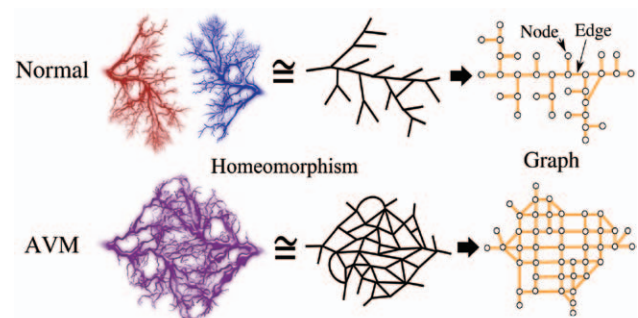


Fig. 1. Conceptual workflow images of homeomorphic simplification and symbolization of vascular structures. AVM graphs are assumed to be more perforated than normal blood vessel graphs.

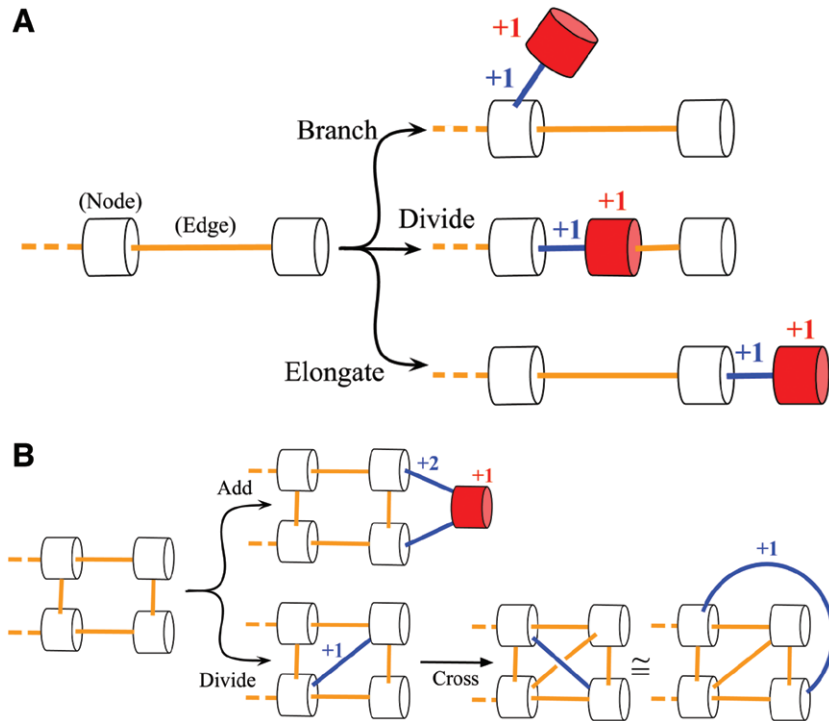


Fig. 2. Verification of graph theory with “spaghetti and marshmallows vascular models.” A, Tree-type growth: when a model only diverges and expands repeatedly like the branches or roots of a tree, the gap of nodes and edges never changes. B, Mesh-type growth: when nodes and edges are added to increase the number of loops from that of the original model, the number of edges will only increase by one extra piece each time. This principle holds true even in 3-dimensionally (3D) complex angioarchitecture because an internal 3D crossing is topologically homeomorphic with an external handle.

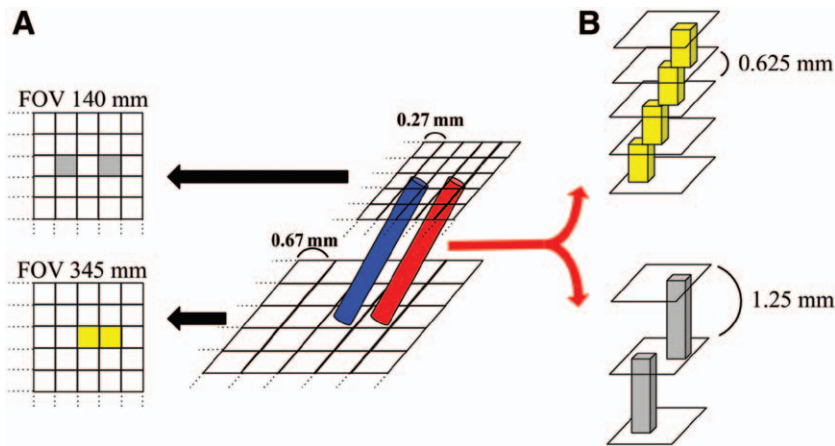


Fig. 3. The influence of imaging conditions. A, When a computed tomography section is provided as a 512×512 pixel image, the relationship of a blood vessel with its accompanying vessel 0.3 mm away can be sometimes correctly displayed on a 140-mm field-of-view (FOV) (pixel size, 0.27×0.27 mm) image of the peripheral extremities, while the same 2 vessels can invariably be displayed as being connected on a 345-mm FOV (pixel size, 0.67×0.67 mm) image of the trunk. B, Vessels rendered as continuous on images with a section thickness of 0.625 mm might appear to be not continuous on images with section thicknesses of 1.25 mm.

ably be displayed as being connected on an image with 0.67×0.67 mm pixel size (Fig. 3A).

Conversely, oblique vessels rendered as continuous on images with a section thickness of 0.625 mm might appear to be not continuous on images with section thicknesses of 1.25 mm (Fig. 3B).

Field of view and section thickness must be identical to compare test results obtained at different times from a same patient. In addition, even in patients with a common lesion site, the closer the test field of view and section thickness are, the more meaningful the comparison is.

Region of Interest Constancy

The second point is that one cannot be sure that region of interest has been uniformly maintained through the series of results especially when efficient procedure causes drastic change to the lesion hemodynamics. Region of interest must be identical before and after treatment, which is possible if clear, fixed points such as the junctions of well-known blood vessels or feeding arteries are used as reference points.

CONCLUSIONS

It seems that the mathematical concepts of topology and graph theory can be used to quantify abnormalities of AVM vascular structures from CTA images. Careful assessment of validity through practical application is necessary for this novel concept.¹¹

Yuki Hata, MD

Department of Plastic Surgery
Osaka University Graduate
School of Medicine, Osaka, Japan
E-mail: yukihata@gmail.com

REFERENCES

1. Kohout MP, Hansen M, Pribaz JJ, et al. Arteriovenous malformations of the head and neck: natural history and management. *Plast Reconstr Surg*. 1998;102:643–654.
2. Lee BB, Do YS, Yakes W, et al. Management of arteriovenous malformations: a multidisciplinary approach. *J Vasc Surg*. 2004;39:590–600.
3. Vaišnytė B, Vajauskas D, Palionis D, et al. Diagnostic methods, treatment modalities, and follow-up of extracranial arteriovenous malformations. *Medicina (Kaunas)*. 2012;48:388–398.
4. Lee BB, Mattassi R, Kim YW, et al. Advanced management of arteriovenous shunting malformation with transarterial lung perfusion scintigraphy for follow-up assessment. *Int Angiol*. 2005;24:173–184.
5. Lee BB, Mattassi R, Kim BT, et al. Contemporary diagnosis and management of venous and arterio-venous shunting malformation by whole body blood pool scintigraphy. *Int Angiol*. 2004;23:355–367.
6. Kaji N, Kurita M, Ozaki M, et al. Experience of sclerotherapy and embolosclectherapy using ethanolamine oleate for vascular malformations of the head and neck. *Scand J Plast Reconstr Surg Hand Surg*. 2009;43:126–136.
7. Moore EA, Grieve JP, Jäger HR. Robust processing of intracranial CT angiograms for 3D volume rendering. *Eur Radiol*. 2001;11:137–141.
8. Suazo L, Foerster B, Fermin R, et al. Measurement of blood flow in arteriovenous malformations before and after embolization using arterial spin labeling. *Interv Neuroradiol*. 2012;18:42–48.
9. Albert CS, Chung JAN. Statistical 3d vessel segmentation using a rician distribution. Available at: <http://citeseerx.ist.psu.edu/viewdoc/summary?doi=10.1.1.75.2885>. Accessed June 27, 2013.
10. Bullitt E, Aylward S, Bernard EJ, et al. Computer-assisted visualization of arteriovenous malformations on the home personal computer. *Neurosurgery* 2001;48:576–582; discussion 582–583.
11. Hata Y, Osuga K, Uehara S, et al. Topological analysis for arteriovenous malformations via computed tomography angiography: part 2: practical application. *Plast Reconstr Surg Glob Open* 2014. doi: 10.1097/GOX.0000000000000151.