

Contents lists available at [ScienceDirect](http://www.sciencedirect.com)

## International Journal of Surgery Case Reports

journal homepage: [www.casereports.com](http://www.casereports.com)

## Adrenohepatic fusion: Adhesion or invasion in primary virilizing giant adrenal carcinoma? Implications for surgical resection. Two case report and review of the literature



Antonio Alastrué Vidal<sup>a</sup>, Jordi Navinés López<sup>a,\*</sup>, Juan Francisco Julián Ibáñez<sup>a</sup>, Napoleón De la Ossa Merlano<sup>b</sup>, Mireia Botey Fernandez<sup>a</sup>, Jaume Sampere Moragues<sup>c</sup>, María del Carmen Sánchez Torres<sup>d</sup>, Eva Barluenga Torres<sup>e</sup>, Jaime Fernández-Llamazares Rodríguez<sup>a</sup>

<sup>a</sup> Department of General Surgery, Endocrinology and Hepato-Biliary-Pancreatic Units, Hospital Universitari Germans Trias i Pujol, Barcelona, Spain

<sup>b</sup> Department of Pathology, Hospital Universitari Germans Trias i Pujol, Barcelona, Spain

<sup>c</sup> Department of Angioradiology, Hospital Universitari Germans Trias i Pujol, Barcelona, Spain

<sup>d</sup> IDI Magnetic Resonance Unit, Hospital Universitari Germans Trias i Pujol, Barcelona, Spain

<sup>e</sup> Department of Radiology, Hospital Universitari Germans Trias i Pujol, Barcelona, Spain

## ARTICLE INFO

## Article history:

Received 26 April 2015

Received in revised form 12 October 2015

Accepted 13 October 2015

Available online 27 November 2015

## ABSTRACT

**INTRODUCTION:** Adrenohepatic fusion means union between the adrenal gland and the liver, intermingling its parenchymas. It is not possible to identify this condition by image tests. Its presence implies radical and multidisciplinary approach.

**PRESENTATION OF CASES:** We report two female cases of 45 and 50 years old with clinical virilization and palpable mass on the abdominal right upper quadrant corresponding to adrenocortical carcinoma with hepatic fusion. The contrast-enhanced tomography showed an indistinguishable mass involving the liver and the right adrenal gland. In the first case, the patient had a two-time operation, the former removing only the adrenal carcinoma, and the second performing a radical surgery after an early relapse. In the second case, a radical right en bloc adrenohepatectomy was performed. Both cases were pathologically reported as liver-infiltrating adrenal carcinoma. Only in the second case the surgery was radical effective as first intention to treat, with 3 years of disease-free survival.

**DISCUSSION:** ACC is a rare entity with poor prognosis. The major indicators of malignancy are tumour diameter over 6 cm, local invasion or metastasis, secretion of corticosteroids, virilization and hypertension and hypokalaemia. The parenchymal fusion of the adrenal cortical layer can be misdiagnosed as hepatocellular carcinoma with adhesion with the Glisson capsule. AHF in such cases may be misinterpreted during surgery, what may impair its resectability, and therefore the survival. The surgical treatment must be performed en bloc, often using liver vascular control. Postoperative treatment must be offered immediately after surgery.

**CONCLUSION:** We report two consecutive rare cases of adrenohepatic fusion in giant right adrenocortical carcinoma, not detectable by imaging, what has important implications for the surgical decision-making. As radical surgery is the best choice to offer a curative treatment, it has to be performed by a multidisciplinary well-assembled team, counting with endocrine and liver surgeons, and transplant surgeons in case of vena cava involvement, in order to maximize the disease-free survival.

© 2015 The Authors. Published by Elsevier Ltd. on behalf of IJS Publishing Group Ltd. This is an open access article under the CC BY-NC-ND license (<http://creativecommons.org/licenses/by-nc-nd/4.0/>).

### 1. Introduction

Adrenohepatic fusion (AHF) means partial or complete lack of capsular elements between the adrenal gland and the liver, allowing parenchymatous intermingling [1]. In contrast, adhesion

(E. Barluenga Torres), [jfernandezllamazares.germanstrias@gencat.cat](mailto:jfernandezllamazares.germanstrias@gencat.cat)  
(J. Fernández-Llamazares Rodríguez).

\* Corresponding author.

E-mail addresses: [aaalstrue.germanstrias@gencat.cat](mailto:aaalstrue.germanstrias@gencat.cat) (A. Alastrué Vidal), [drnavines@gmail.com](mailto:drnavines@gmail.com) (J. Navinés López), [jfjulian.germanstrias@gencat.cat](mailto:jfjulian.germanstrias@gencat.cat) (J.F. Julián Ibáñez), [ndelaossa.germanstrias@gencat.cat](mailto:ndelaossa.germanstrias@gencat.cat) (N. De la Ossa Merlano), [mbotey.germanstrias@gencat.cat](mailto:mbotey.germanstrias@gencat.cat) (M. Botey Fernandez), [jsampere.germanstrias@gencat.cat](mailto:jsampere.germanstrias@gencat.cat) (J. Sampere Moragues), [mcsanchez.germanstrias@gencat.cat](mailto:mcsanchez.germanstrias@gencat.cat) (M.d.C. Sánchez Torres), [ebarluenga.germanstrias@gencat.cat](mailto:ebarluenga.germanstrias@gencat.cat)

implies an intact connective tissue septum layer. There is no previous reports of parenchymal fusion in functional giant adrenal carcinomas, and its clinical significance has been rarely described. As it is not possible to identify this condition by image tests, its presence implies radical and multidisciplinary approach to achieve radical excision. Hereby we present a two-case report of adrenocortical carcinoma (ACC) with AHF, presented as malignant hepatic tumour by imaging.

## 2. Presentation of cases

Two previously healthy caucasian women of 45 and 50 years old with history of 9 and 6 months of clinical virilization and palpable mass on the right abdominal upper quadrant were submitted consecutively to our hospital from primary care. Both patients presented with clinical signs of virilization (centripetal obesity, hirsutism, facial acne, hypertension and oligo/amenorrhea), although the second case presented with mild hirsutism and oligomenorrhea. Both were studied by ultrasonography (US), computerized tomography (CT) and nuclear magnetic resonance (MRI), observing an indistinguishable mass involving the liver and the right adrenal gland (Fig. 1). Hormone laboratories dehydroepiandrosterone (DHEA) and its sulphate metabolite (DHEAS), cortisol and testosterone were significative for functional suprarenal tumour. The two cases are reported in line with the CARE criteria.

### 2.1. Radiologic features

In the first case (Fig. 2), a large solid mass of  $16.2 \times 13.2 \times 12.7$  cm in craniocaudal, laterolateral, and anteroposterior (CC, LL, AP) diameters was seen on a non-contrast CT, occupying the main part of the right liver lobe (RLL) and pulling down the right kidney, with heterogeneous intravenous (IV) contrast enhancement. The inferior vena cava (IVC) was stenosed, from the left renal vein to the main hepatic veins (MHV). No thrombus was seen within the portal vein (PV). In this case no ulterior radiological exam was considered previous to surgery.

In the second case (Fig. 3), a large hypo-dense mass of  $20.3 \times 17.5 \times 15.6$  cm (CC, LL, AP) was seen at on a non-contrast CT, affecting the RLL, but also caudate lobe and segment 4b, with an annular-peripheral arterial hyper-density after contrast enhanced CT, as well as intratumoural hypertrophic vessels. The splenoportal axis were permeable but pulled onto front. The retro-hepatic IVC was extremely stenosed. When looked at on a contrast-enhanced MRI (Multihance) imaging, there was a large mass of non-fatty solid

density with central foci of haemorrhagic necrosis, and peripheral neovessels. Iliocavography showed an extrinsic IVC compression from the back, with azygos, hemiazygos, lumbar veins and paravertebral vein plexus dilated, which are pathognomonic signs of adrenal mass, but cannot discard a large hepatic tumour with extracapsular spreading. The transesophageal echocardiogram (TEE) ruled out atrial cardiac tumoural thrombus before US-guided trans-hepatic core-biopsy was performed, being positive for adrenal carcinoma.

### 2.2.1. Surgical technique proceedings

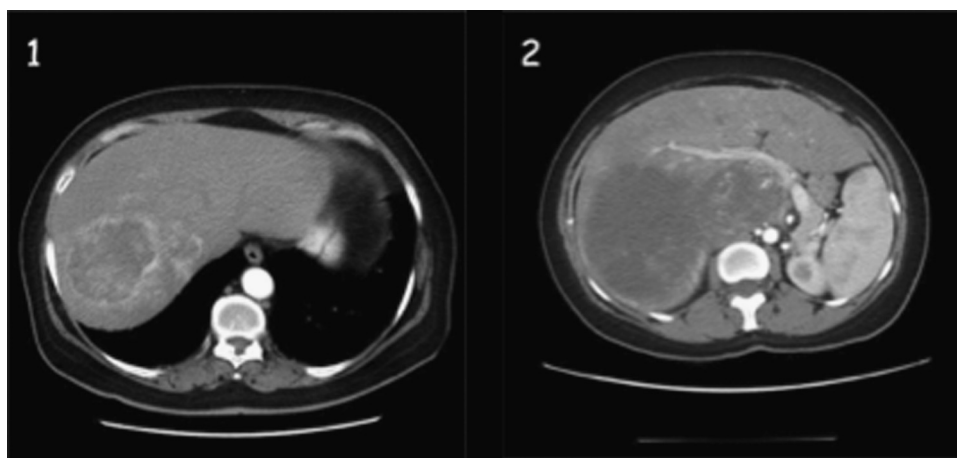
Both cases were operated in one month interlude. The former patient had a medial laparotomy extended to 9th costal arc. As first step, proximal and distal IVC and renal veins control was obtained with vessel loops. A right nephrectomy was required due to the critical proximity with the lesion. A blunt dissection along the cleavage plain identified a large part of the lesion infiltrating the RLL, which was enucleated in a second time (Fig. 2).

The latter case was preceded by the placement of a security balloon catheter in the cardiac atrium, via retrohepatic IVC, and selective femoral transarterial right hepatic embolization with 150–300  $\mu$ m microspheres. The patient had a Chevron bilateral subcostal laparotomy with xiphoid extension. After liver mobilization and total vascular control, piggy-back manoeuvre was performed, avoiding venovenous by-pass (VVB). As the cleavage plane between the mass and the liver was inexistent, a right extended hepatectomy was performed (Fig. 4).

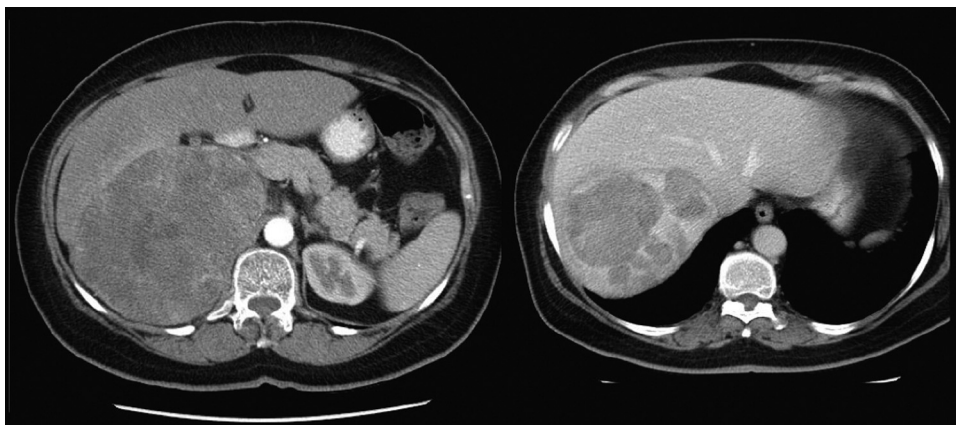
Both patients received preoperative prophylaxis and cortisol adrenal preconditioning, and 2 unit blood transfusion intraoperatively. Pain was successfully managed through a patient-controlled analgesia pump. The postoperative course was uneventful and the patients were discharged after 12 and 9 days respectively.

### 2.2.2. Anatomopathological findings

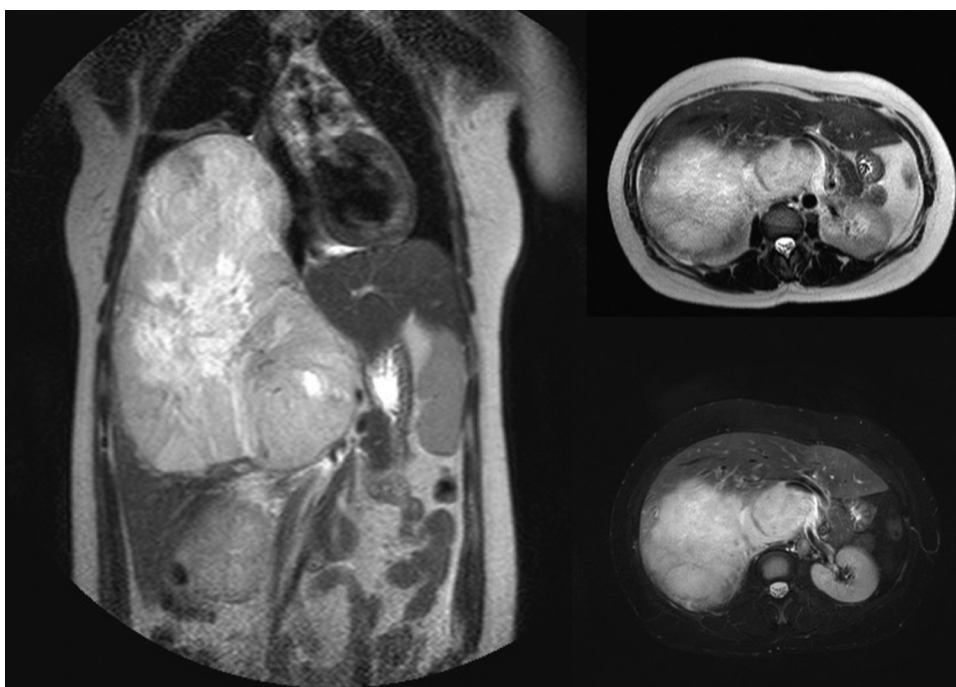
Both specimens were solid and firm. The cut surface appeared yellowish grey (Fig. 5), with haemorrhagic areas. The hepatic capsule included the adrenal gland in both cases. Microscopically, the tumour consisted of nests or trabeculae interrupted by a thin sinusoidal capillary web. The tumoural cells were round polygonal and had clear microvesicular cytoplasm with ovoid nuclei. More compact areas consisting of smaller cells with eosinophilic granular cytoplasm were also found. Cellular atypia were infrequent and no mitotic figures were identified. A thin fibrous capsule separated the adrenal gland and the liver over the most part of their respective surfaces. However, multiple foci of infiltration were identified



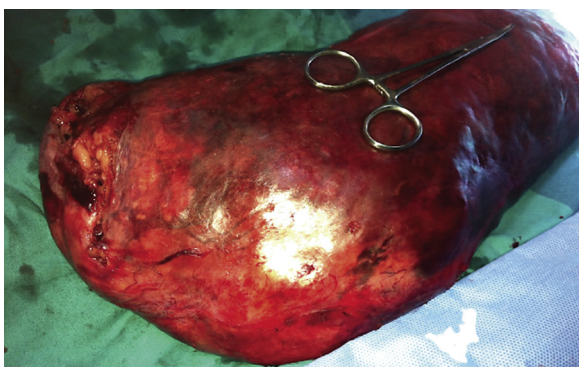**Fig. 1.** CT scan comparing the two initial image studies. Both patients showed virilization symptoms and right lobe liver mass. Diagnosis was adrenal carcinoma. 1: First case. 2: Second case.



**Fig. 2.** First case. Large adrenal mass compressing right liver lobe and displacing vena cava and right renal vein. No thrombus shown. Right: on portal equilibrium phase, large areas of low attenuation coefficient, attributed to tumoral necrosis, surrounded by a hyperattenuated capsule.



**Fig. 3.** Second case. Large mass displacing but also merging with the liver. It can be seen IVC and right renal vein stenosis. The mass pulls out the diaphragm and compresses the hepatic veins, as also contacts with the right atrium, without invading IVC.

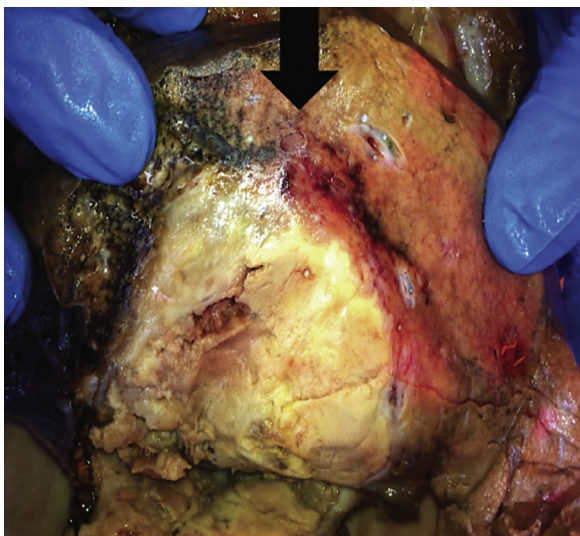


**Fig. 4.** Second case. Macroscopic picture of the adrenohepatic resection en bloc specimen.

where the parenchyma of the two organs had direct contact with each other. This finding was consistent with AHF, but including also cellular atypia and neoplastic infiltration, so the final anatomicopathological diagnosis was infiltrating adrenal carcinoma.

**2.2.3. Follow-up**

In the first case, a one month postoperative CT demonstrated a liquid-density collection besides the liver and showed progression after 3 months, suggesting early neoplastic recurrence, so mitotane treatment was started. A positron emission tomography (PET) scan 9 months after, revealed local relapse, but also ruled out distant metastases, so a salvage right hepatectomy was performed. The postoperative course was uneventful. The liver specimen revealed again neoplastic infiltration. After 2 years the patient died from metastatic recurrence. In the second case, the CT scan after 6 months showed no relapse. Nevertheless, after 3 years disease-free follow-up, the patient was diagnosed with pulmonary metastases.



**Fig. 5.** Second case. Anatomopathological macroscopical aspect of the AHF detailing infiltration line (black arrow).

### 3. Discussion

ACC is a rare entity with an estimated incidence of 1 per 1.7 million [2], representing around 0.02% of all neoplasia. It has bimodal age distribution, peaking at first and fifth decade. It is more common in women [3], but its presentation as virilization is rare [4]. ACC aetiology is idiopathic, and its prognosis is very poor due to its aggressive behavior [5]. The diagnosis is made frequently late and incidentally, often after vascular invasion [6]. According to Schechter [7], AHF is one sort of aberrant adrenal tissue heterotopia, in contrast to the adrenohepatic adhesion, and has partially lacking connective tissue septum [8].

#### 3.1. Differential diagnosis

Before an abdominal right upper quadrant mass it should be ruled out adrenal cortical adenoma, clear cell hepatocellular carcinoma, pheochromocytoma, paraganglioma (including multiple endocrine neoplasia (MEN) type 2, Von Hippel Lindau disease or familial paragangliomas), adrenal collision or composite tumour, adrenal rest tumour, and also adrenal metastasis. It is important to discard pheochromocytoma and functional paraganglioma prior to treatment, in order to receive hormonal suppression and/or be embolized previous to surgery [9].

Hormone labs are helpful. In women, malignant tumour is unlikely present if serum DHEAS and urinary 17-ketosteroid (17-KS) excretion are between basal range and serum cortisol after dexamethasone is below 3.3  $\mu\text{g/dL}$ , with sensitivity and specificity of 100% [5]. In our two cases, normal 24-h urine vanillylmandelic

acid (VMA) depicted the non-functional nature of the tumour. Percutaneous preoperative biopsy must be done with extreme caution, as it can potentially result in life-threatening crisis [9]. In the second case, a full precaution core biopsy was taken, being positive for carcinoma.

ACC is defined as the tumour meets the Weiss classic standard criteria [10]. The pathologic diagnosis is based on the recognition of at least three of nine morphological parameters by optic microscopy (Table 1). The Weiss scoring system is the most widely employed score [11]. Well-established histopathological items and Ki-67 expression can specifically distinguish adrenocortical adenoma from carcinoma [12]. Immunohistochemical study of adrenal steroidogenic factor 1 (SF-1), can help. Moreover, the major indicators of malignancy are tumour diameter over 6 cm, documented local invasion or metastasis, secretion of more than one class of corticosteroids, virilization and associated hypertension and/or hypokalaemia [13].

The clinical adrenal-induced virilization can be confirmed by measuring serum testosterone, serum adrenal androgens (DHEA and DHEAS) and 24-h 17-KS. As proposed by Ross and Aron [14], potassium and total urinary catecholamine and metanephrine should be evaluated to rule out pheochromocytoma specially in patients with hypertension, so it was done in both cases.

Plasma and urinary steroids (including DHEA and DHEAS), androstenediol, 4-androstenedione, pregnenolone, 17-hydroxypregnenolone and 11-deoxycortisol as well as urinary 17-ketosteroid (17-KS), 17-hydroxycorticosteroid (17-OHCS) and the tetrahydrometabolite of 11-deoxycortisol may be elevated because in ACC many steroid enzymes are defective. Reviewed series [4] show that the most common steroids assayed were 24-h urinary excretion of 17-KS and 17-OHCS, but also plasma DHEA and DHEAS. Hormonally active ACC express the insulin-like growth factor II (IGF-II) gene. In addition, levels of both transforming growth factor alpha (TGF- $\alpha$ ) and epidermal-like growth factor (ELGF) receptor expression were markedly higher in adrenocortical carcinomas than in benign tumours.

Despite to be a rare tumour, Honma [15] reported that AHF is a rather not uncommon autopsy incidental finding, reaching 10%, what way suggest that it may be an acquired age-related phenomenon [7], although hepatocellular carcinoma can invade the right adrenal gland with AHF [16]. The development process of AHF has been proposed to be a differentiation failure of the intervening fat tissue [7], as a defective formation of the organ capsules from the periadrenal mesenchymal stroma during the embryonic development [17]. The role of the intercellular communication disruption in adrenocortical adrenal tumourigenesis was introduced by Marx et al. [18]. To our knowledge, there are many few cases of adrenal cortical tumour with AHF described in the literature [19], what lead us to think that the adhesion between the liver and the adrenal gland can be an acquired condition [20].

**Table 1**

Weiss criteria for malignancy.

Original Weiss criteria for malignancy, requires 3+ of these factors:
>5 mitotic figures/50HPF (40 $\times$ objective), counting 10 random fields in area of greatest number of mitotic figures on 5 slides with greatest number of mitoses
Nuclear grade III or IV based on Fuhrman criteria
Presence of atypical mitotic figures (abnormal distribution of chromosomes or excessive number of mitotic spindles)
Clear or vacuolated cells comprising 25% or less of tumor
Diffuse architecture (more than 1/3 of tumor forms patternless sheets of cells; trabecular, cord, columnar, alveolar or nesting pattern is not considered to be diffuse)
Microscopic necrosis
Venous invasion (veins must have smooth muscle in wall; tumor cell clusters or sheets forming polypoid projections into vessel lumen or polypoid tumor thrombi covered by endothelial layer)
Sinusoidal invasion (sinusoid is endothelial lined vessel in adrenal gland with little supportive tissue; consider only sinusoids within tumor)
Capsular invasion (nests or cords of tumor extending into or through capsule with a stromal reaction); either incomplete or complete

### 3.2. Radiologic highlights

The radiologic study must count on US and CT/MRI, what may serve as a guide for a safe biopsy. The performance of a TEE may rule out the possibility of atrium thrombus. As seen on Abdominal Doppler US and CT/MRI scan, malignant tumours have heterogeneous zones with intratumoural haemorrhage, necrosis and fibrosis, irregular margins and calcifications. High density measurement of Hounsfield units (>10 HU) in an unenhanced CT is indicative for a low fat content, providing strong evidence of malignancy with 71% sensitivity and 98% specificity [21]. However, 20HU may be an acceptable density cut-off value for a mass <4cm in absence of malignancy history [22]. It is recommendable to use sulphur hexafluoride surfactant-stabilized microbubbles as contrast in US liver imaging before percutaneous fine-needle aspiration cytology (FNAC) or CT/US-guided core-biopsy, in order to minimize the haemorrhagic risk [23]. Open biopsy is then only required in doubtful cases.

The attachment between the hepatic lesion and the adrenal gland could be seen by careful review of the thin-section CT data set with the multiplanar reformation technique (MPR). However, fat plane is not always visible on CT in thin patients. The intrahepatic presence of the adrenal cortical layer can then be misdiagnosed as hepatocellular carcinoma, both radiologically [16] and pathologically [24]. AHF in such cases may be misinterpreted during the surgery, as happened in the first case. This is particularly important in the perioperative decision-making process. Notwithstanding, the resection must be performed with negative margins (R0), what may include lymphadenectomy or open cava thrombectomy en bloc, often using liver transplant techniques to mobilize the liver off the IVC [25].

### 3.3. Surgical highlights

The importance of the IVC control is a key factor during the surgical act [26]. It is critical to perform a proper piggy-back manoeuvre, as well as clamping the MHV when needed [27]. Occasionally, this type of procedures may be technically challenging for the surgeon, sometimes requiring veno-venous bypass (VVB) or cardiopulmonary bypass (CPB) if the cardiac atrium is involved [27]. MHV and PV must be controlled as a first step to surgical resection [28], allowing a right hepatectomy en bloc with the adrenal gland and/or the right kidney. In the two hereby presented cases the vascular control consisted of infrarenal vena cava vessel loop and Pringle manoeuvre, while in the second case a cardiac atrium balloon-occluding catheter was used for a superior vena cava control.

Complete surgical excision is the only palliative option in most cases [29] and provides acceptable results in survival and quality of life, but also significant morbidity and mortality rates. IVC wall invasion and the tumour thrombus extension are major determinants for the surgical approach [28], even requiring CPB and DHCA. In addition, there may be paracaval lymph node involvement that may be resected. In our two cases, the lymph node dissection showed no IVC infiltration.

IVC can be stenosed or occluded by tumour thrombus with low extremity oedema, thus developing collateral circulation [8]. In these cases, IVC must be resected. Autogenous vein graft substitution might not be technically feasible for long segments [26]. PTFE [29], Dacron and Gore-Tex 18–20 mm ringed grafts are currently the best choice [30]. Anticoagulation has not proven any benefit, although proposed empirically by some authors (low dose heparin along with long-term maintenance aspirin) [30].

### 3.4. Postoperative management

The prognosis of ACC is poor if untreated with a 20% 1-year survival. Functioning tumours have larger survivals than non-functioning. Distant metastases may narrow 5-year survival from 50% to 0%. Only 30% of patients are diagnosed in early stages (I–II), so 70% do it in advanced stages (III–IV). 5-year survival is 60% for stage I, 58% for stage II, 24% for stage III, and 0% for stage IV, respectively. Relapse is estimated around 84% even after R0 surgery [31].

Adjuvant chemotherapy must be offered immediately after surgery. Mitotane is the first election drug, associated or not with cytotoxic treatment [32], by cortisol metabolism 11-beta-hydroxylase inhibition. Recently an albumin-binding matrix-associated protein has been proposed as a mechanism to increase the efficacy of the antimicrotubular drug Paclitaxel (nab-paclitaxel) [33]. In our study both patients received mitotane as adjuvant treatment, but only the second had relative long-term disease-free survival. This fact reaffirms the author's notion that a radical en bloc first intention-to-treat surgical resection is mandatory.

## Conclusions

Virilizing adrenal carcinoma is a rare entity that must be discarded before a large mass in the RLL, by imaging studies (US, CT or MRI) and hormone expression labs. To our best knowledge, there is no ACC presented with AHF reported in the literature. Radiologists should be aware of this potential occurrence in order to help the surgical decision-making, as the biopsy may be crucial to rule out the possibility of ACC prior to consider aggressive surgical treatment.

The surgical resection must include the RHL en bloc with the right adrenal gland when AHF is suspected. A multidisciplinary well-assembled team, counting with endocrine and liver surgeons, and transplant surgeons in case of IVC involvement, what may require venous bypass, or even IVC open exploration, should perform this surgical procedure.

Considering radical surgery as the best choice to offer significant disease-free survival, we strongly recommend a radical surgery including the RHL en bloc with the right adrenal gland, as done in the second case presented.

Thus, surgery must be performed in a radical, but also extreme and well-planned manner.

## Conflict of interest

The authors declare no conflict of interest.

## Funding

None.

## Ethical approval

Written and signed informed consent from patients were obtained previous to publishing the case report.

## Consent

Written informed consent was obtained from the patient for publication of this case report and accompanying images. A copy of the written consent is available for review by the Editor-in-Chief of this journal on request.

## Author contribution

Antonio Alastrué Vidal: Study concept and design, data collection, analysis and interpretation, writer of the paper. Jordi Navinés López: Data analysis and interpretation, writer of the paper. Juan Francisco Julian Ibáñez: Study concept and design, and data collection. Napoleón De la Ossa Merlano: Data collection, and interpretation. Mireia Botey Fernandez: Data collection, and analysis. Jaume Sampere Moragues: Data collection, data analysis and interpretation. María del Carmen Sánchez Torres: Data analysis and interpretation. Eva Barluenga Torres: Data analysis and interpretation. Jaime Fernández-Llamazares Rodríguez: Team chief. Study concept and interpretation.

## Guarantor

Antonio Alastrué Vidal. Jordi Navinés López. Juan Francisco Julian Ibáñez.

## References

- [1] M. Dolan, N. Janovski, Adreno-hepatic union (adrenal dystopia), *Arch. Pathol.* 86 (1968) 22–24.
- [2] R. Mihai, J. Farndon, Diagnosis and treatment of adrenal tumors, *Surgery* 9 (1996) 145–153.
- [3] M. Didolkar, R. Bescher, E. Elias, R. Moore, Natural history of adrenal cortical carcinoma: a clinicopathologic study of 42 patients, *Cancer* 47 (1981) 2153–2161.
- [4] J. Derksen, S. Nagesser, A. Meinders, H. Haak, C. van-de-Velde, Identification of virilizing adrenal tumors in hirsute women, *N. Engl. J. Med.* 331 (1994) 968–973.
- [5] G. Prager, G. Heinz-Peer, C. Passler, Surgical strategy in adrenal masses, *Eur. J. Radiol.* 41 (2002) 70–77.
- [6] B. Allolio, S. Hahner, D. Weismann, M. Fassnacht, Management of adrenocortical carcinoma, *Clin. Endocrinol.* 60 (3) (2004) 273–287.
- [7] D. Schechter, Aberrant adrenal tissue, *Ann. Surg.* 167 (1968) 421–426.
- [8] M. Dolan, N. Janovski, Adreno-hepatic union (adrenal dystopia), *Arch. Pathol.* 86 (1968) 22–24.
- [9] S. Roman, J. Sosa, Functional paragangliomas presenting as primary liver tumors, *South Med. J.* 100 (February (2)) (2007) 195–196.
- [10] L. Weiss, L. Medeiros, A. Vickery, Pathologic features of prognostic significance in adrenocortical carcinoma, *Am. J. Surg. Pathol.* 13 (3) (1989) 202–206.
- [11] M. Papotti, R. Libè, E. Duregon, M. Volante, J. Bertherat, F. Tissier, The Weiss score and beyond—histopathology for adrenocortical carcinoma, *Horm. Cancer* 2 (6) (2011) 333–340.
- [12] A. Stojadinovic, M. Brennan, A. Hoos, Adrenocortical adenoma and carcinoma: histopathological and molecular comparative analysis, *Mod. Pathol.* 16 (2003) 742–751.
- [13] M. Lockhart, J. Smith, P. Kenney, Imaging of adrenal masses, *Eur. J. Radiol.* 41 (2002) 95–112.
- [14] N. Ross, D. Aron, Hormonal evaluation of the patient with an incidentally discovered adrenal mass, *N. Engl. J. Med.* 323 (1990) 1401–1405.
- [15] K. Honma, Adreno-hepatic fusion: an autopsy study, *Zentralbl. Pathol.* 137 (1991) 117–122.
- [16] K. Okano, H. Usuki, H. Maeta, Adrenal metastasis from hepatocellular carcinoma through an adrenohepatic fusion, *J. Clin. Gastroenterol.* 38 (2004) 912–919.
- [17] L. Honoré, K. O'Hara, Combined adrenorenal fusion and adrenohepatic adhesion: a case report with review of the literature and discussion of pathogenesis, *J. Urol.* 115 (1976) 323–325.
- [18] C. Marx, M. Ehrhart-Bornstein, W. Scherbaum, S. Bornstein, Regulation of adrenocortical function by cytokines—relevance for immune-endocrine interaction, *Rev. Horm. Metab. Res.* 30 (June–July (6–7)) (1998) 16–20.
- [19] L. Wilkins, M. Ravitch, cortical tumor arising in the liver of a three-year-old boy with signs of virilism and cushing's syndrome, *Pediatrics* 9 (1951) 671–681.
- [20] S. Mousa, E. van-Esch, Two cases of adreno-hepatic fusion in cynomolgus monkeys (*Macaca fascicularis*), *Toxicol. Pathol.* 32 (2004) 511–513.
- [21] E. Caoili, M. Korobkin, I. Francis, et al., Adrenal masses: characterization with combined unenhanced and delayed enhanced CT, *Radiology* 222 (3) (2002) 629–633.
- [22] T. Gopan, E. Remer, A. Hamrahian, Evaluating and managing adrenal incidentalomas, *Clin. J. Med.* 73 (6) (2006) 561–568.
- [23] D. Choi, S. Kim, J. Lim, et al., Preoperative detection of hepatocellular carcinoma: ferumoxides-enhanced mr imaging versus combined helical CT during arterial portography and CT hepatic arteriography, *AJR Am. J. Roentgenol.* 176 (February (2)) (2001) 475–482.
- [24] S. Prasad, H. Wang, H. Rosas, et al., Fat-containing lesions of the liver: radiologic-pathologic correlation, *Radiographics* 25 (March–April (2)) (2005) 321–331.
- [25] G. Ciancio, C. Hawke, M. Soloway, The use of liver transplant techniques to aid in the surgical management of urological tumors, *J. Urol.* 164 (September (3 Pt. 1)) (2000) 665–672.
- [26] G. Ciancio, A. Livingstone, M. Soloway, Surgical management of renal cell carcinoma with tumor thrombus in the renal and inferior vena cava: the University of Miami experience in using liver transplantation techniques, *Eur. Urol.* 51 (April (4)) (2007) 988–994, discussion 94–95. Epub 2006 Dec 8.
- [27] C. Margarit, J. Lázaro, E. Hidalgo, et al., Cross-clamping of the three hepatic veins in the piggyback technique is a safe and well tolerated procedure, *Transpl. Int.* 11 (Suppl. 1) (1998) S248–S250.
- [28] G. Ciancio, J. Gonzalez, S. Shirodkar, J. Angulo, M. Soloway, Liver transplantation techniques for the surgical management of renal cell carcinoma with tumor thrombus in the inferior vena cava: step-by-step description, *Eur. Urol.* 59 (March (3)) (2011) 401–406, <http://dx.doi.org/10.1016/j.eururo.2010.07.028>, Epub Aug 3.
- [29] S. Delis, C. Dervenis, D. Lytras, C. Avgerinos, M. Soloway, G. Ciancio, Liver transplantation techniques with preservation of the natural venovenous bypass: effect on surgical resection of renal cell carcinoma invading the inferior vena cava, *World J. Surg.* 28 (June (6)) (2004) 614–619.
- [30] A. Hemming, A. Reed, M. Langham, S. Fujita, R. Howard, Combined resection of the liver and inferior vena cava for hepatic malignancy, *Ann Surg.* 239 (May (5)) (2004) 712–719, discussion 9–21.
- [31] M. Terzolo, A. Angeli, M. Fassnacht, et al., Adjuvant mitotane treatment for adrenocortical carcinoma, *N. Engl. J. Med.* 356 (June (23)) (2007) 2372–2380.
- [32] M. Terzolo, F. Daffara, A. Ardito, et al., Management of adrenal cancer: a 2013 update, *J. Endocrinol. Invest.* 37 (March (3)) (2014) 207–217.
- [33] M. Demeure, E. Stephan, S. Sinari, et al., Preclinical investigation of nanoparticle albumin-bound paclitaxel as a potential treatment for adrenocortical cancer, *Ann. Surg.* 255 (January (1)) (2012) 140–146, <http://dx.doi.org/10.1097/sla.0b013e3182402d21>.

## Open Access

This article is published Open Access at [sciendo.com](http://sciendo.com). It is distributed under the [IJSCR Supplemental terms and conditions](#), which permits unrestricted non commercial use, distribution, and reproduction in any medium, provided the original authors and source are credited.