

Contents lists available at [ScienceDirect](http://www.sciencedirect.com)

International Journal of Surgery Case Reports

journal homepage: www.casereports.com

Treatment of malreduced pilon fracture: A case report and the result in the long-term follow-up



Mehmet Bulent Balioğlu*, Yunus Emre Akman, Hakan Bahar, Akif Albayrak

Baltalimani Metin Sabanci Bone Diseases Training and Research Hospital, Baltalimani, Istanbul, Turkey

ARTICLE INFO

Article history:

Received 25 September 2015

Received in revised form 5 December 2015

Accepted 17 December 2015

Available online 23 December 2015

Keywords:

Ankle injuries

Intra-articular fractures

Osteoarthritis

Transplantation

Autologous bone graft

ABSTRACT

INTRODUCTION: The risk for post-traumatic osteoarthritis (POA) following tibial plafond joint trauma has been reported to be as high as 70–75%. In the treatment of more severe joint pathologies, with incongruity and intra-articular defects, internal or external fixations techniques may be required.

PRESENTATION OF CASE: We report the orthopedic management of a pilon fracture in a 30-year-old male with malunion and implant failure after initial mal-reduction of the fracture 9-months earlier. Tricortical iliac crest autologous bone grafting (TCG) was used in combination with internal fixation to restore distal tibial articular. The procedure resulted in a pain free ankle, sufficient range of motion for function and patient satisfaction.

DISCUSSION: Early surgical intervention and anatomical reduction with appropriate fixation are recommended for intra-articular tibial pilon fractures. Autogenous bone grafting is a reliable treatment option to augment structural stability, bone defects and bone-healing. Indications for bone grafting include delayed union or nonunion, malunion, arthrodesis, limb salvage, and reconstruction of bone voids or defects. The application of TCG in the management of a malreduced tibial plafond fracture has not been described before.

CONCLUSION: We performed TCG with internal fixation in order to restore stability, congruency and alignment in a young patient in whom a biological restoration was feasible due to good bone quality. In suitable cases, TCG might provide an alternative to arthrodesis or arthroplasty.

© 2015 The Authors. Published by Elsevier Ltd. on behalf of IJS Publishing Group Ltd. This is an open access article under the CC BY-NC-ND license (<http://creativecommons.org/licenses/by-nc-nd/4.0/>).

1. Introduction

The risk for post-traumatic osteoarthritis (POA) following significant joint trauma has been reported to be as high as 11–75%. The incidence of POA is particularly high for intra-articular fractures, such as fractures of the tibial plafond fractures, which are associated with a 70–75% of POA. In fact, intra-articular fractures, including tibial plafond fractures, have been associated with a 20-fold increase in the risk for POA [1–4]. In the treatment of more severe joint pathologies with incongruity and intra-articular defects, internal or external fixations techniques may be required [5]. In cases of non- or mal-union, tricortical iliac crest autologous bone grafting (TCG) may be applied to improve fracture healing. In the current clinical literature, application of TCG in combination with internal fixation has not been described as an option for the treatment of post-traumatic articular defects. Yet, the combination of TCG and internal fixation could be effective in the management of

selected intra-articular fractures, such as restoring the distal joint surfaces following fractures involving the tibial plafond. The aim of our case report was to describe the clinical and radiological results of applying TCG in combination with internal fixation as an alternative treatment to single use of external or internal fixation for intra-articular fractures.

2. Presentation of case

A 30-year-old male patient underwent open reduction and internal fixation for a traumatic right pilon fracture at another trauma center. Nine months post-operatively, the patient was referred to our clinic with complaints of persisting ankle pain, swelling and difficulty walking, with no history of neurological disease. The fracture was classified as OTA/AO Type 43-C3 fracture. Pseudarthrosis of the distal tibial metaphysis, implant failure and an intra-articular defect were identified on imaging (Fig. 1A–E). Extraction of the failed implants, joint debridement and application of TCG with internal fixation were performed.

Under general anesthesia, the patient was positioned in a supine position and a tourniquet applied to the thigh. Medial and lateral longitudinal incisions were made. Visual inspection confirmed breakage of the internal fixation material on the lateral side of the

* Corresponding author at: Bone Diseases Training and Research Hospital, Rumeli Hisari Caddesi No: 62 Baltalimani, Istanbul 34470, Turkey. Fax: +90 212 323 70 82.

E-mail addresses: mbbalibey@gmail.com, mehmetbalioglu2003@yahoo.com (M.B. Balioğlu), yemreakman@gmail.com (Y.E. Akman), drhakanbahar@gmail.com (H. Bahar), albayrakakif@gmail.com (A. Albayrak).

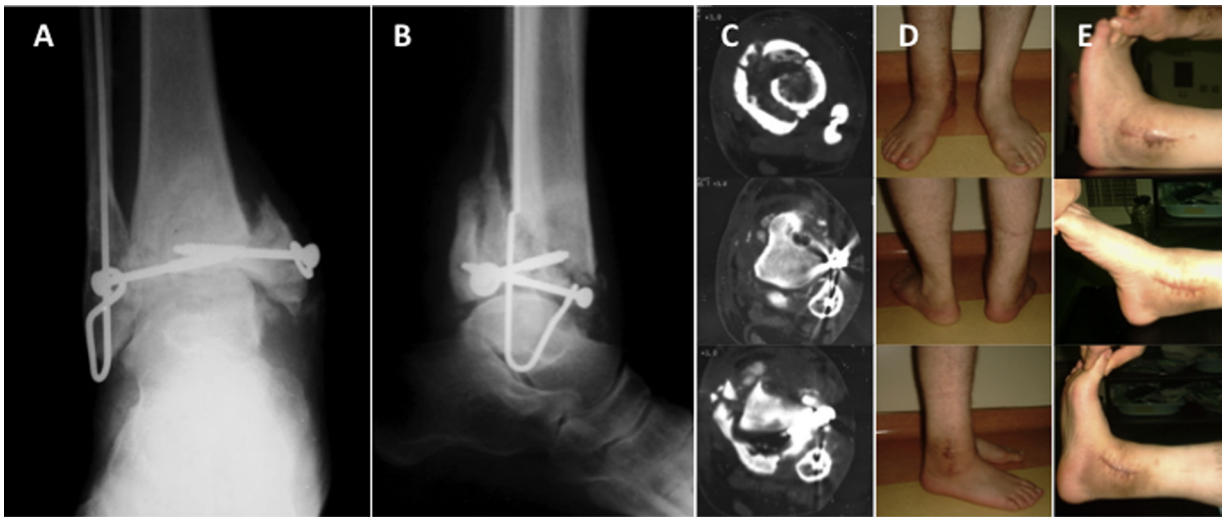

Fig. 1. Assessment of ankle joint; (A, B) anterior–posterior and lateral radiographs, showing implant failure, pseudarthrosis and joint destruction; (C) CT image; and (D, E) weight bearing and ankle movements after initial surgery.

joint, with implant material identified inside the medial aspect of the joint. The distal joint surface of the tibia was destroyed and the implant material irritated the surface of the talus. For fracture reduction and stabilization, the fibula was fixed first with a plate and the fibular length restored. The articular surface of the

tibia was then debrided through the medial incision. A TCG was harvested from the right iliac crest. The autograft was adapted on the tibial plafond as the cortex of the concave side articulating with the talus, and the autograft internally fixed. A short leg cylinder cast was applied and maintained for 6 weeks post-surgery

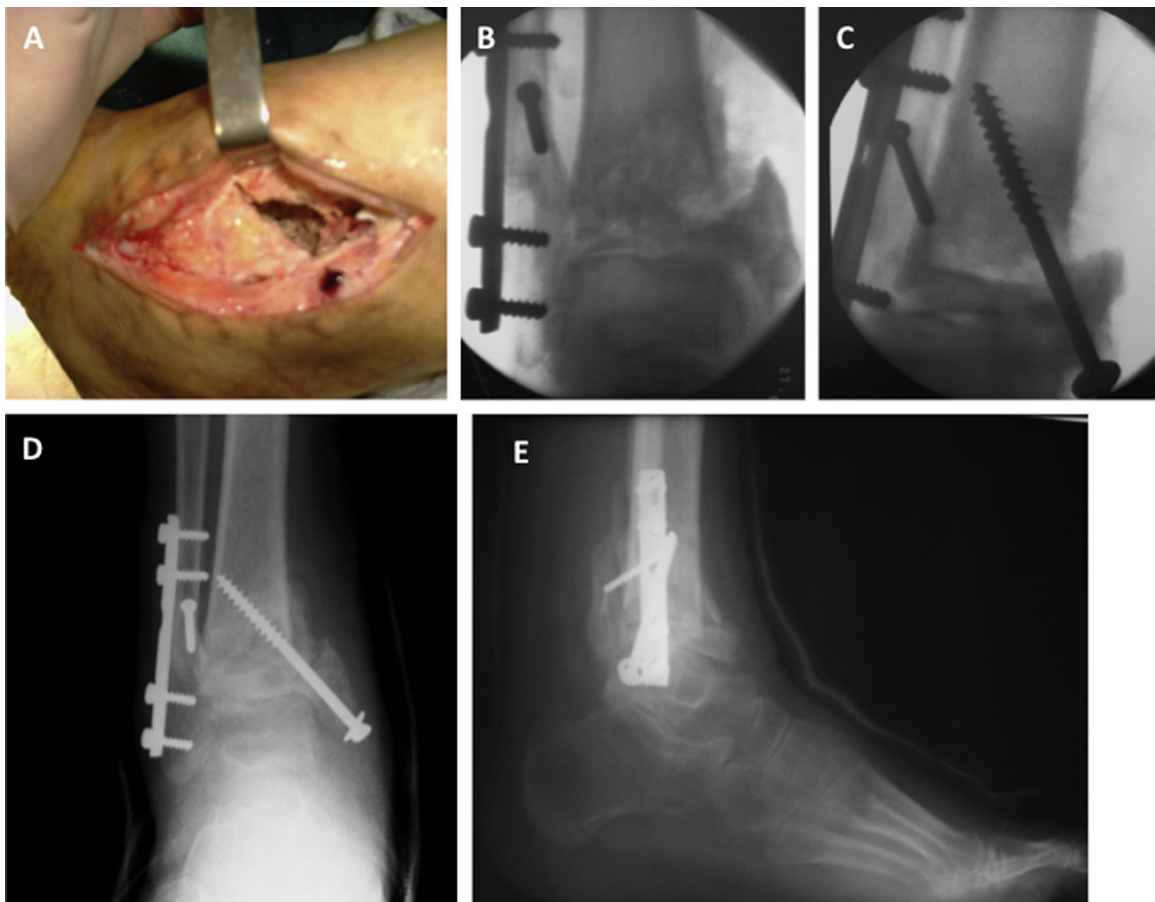


Fig. 2. Appearance of the medial ankle joint defect after removal of the implants (A); application of tricortical iliac crest autologous bone grafting (TCG) to the tibial plafond of the ankle joint surface (B); pre-operative fluoroscopy images before and after autografting (C); and anterior–posterior and lateral radiographs in the early post-operative period with cast *in situ* (D, E).

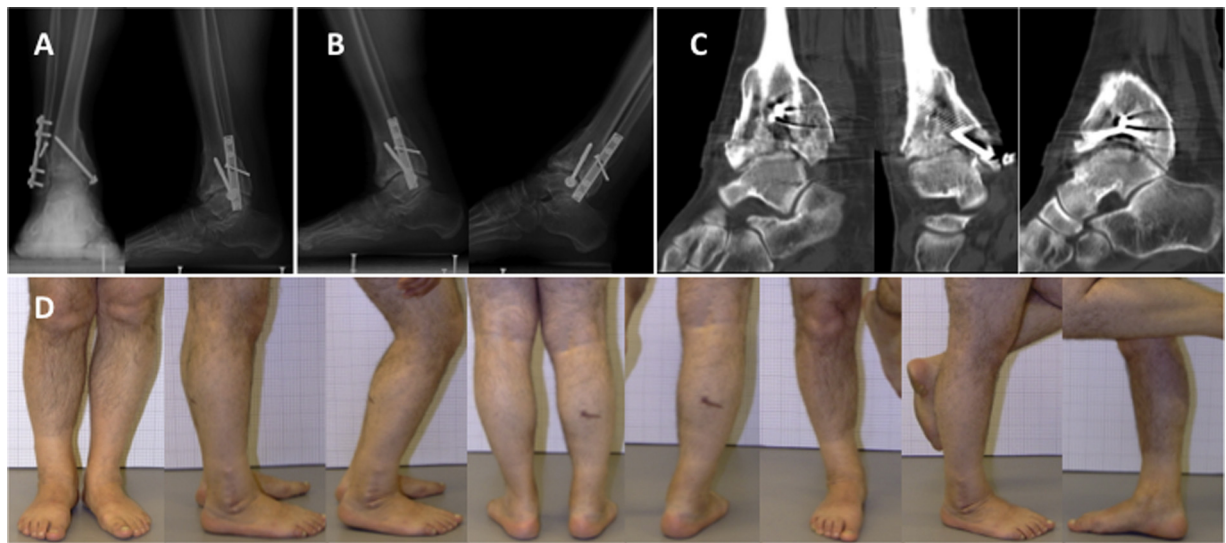


Fig. 3. Radiological and clinical results in post-operative year 13; (A) standing anterior–posterior radiographs; (B) lateral radiographs in maximum plantar and dorsal flexion positions; (C) coronal, sagittal and axial computed tomography images of the tibiotalar joint; and (D) clinical results.

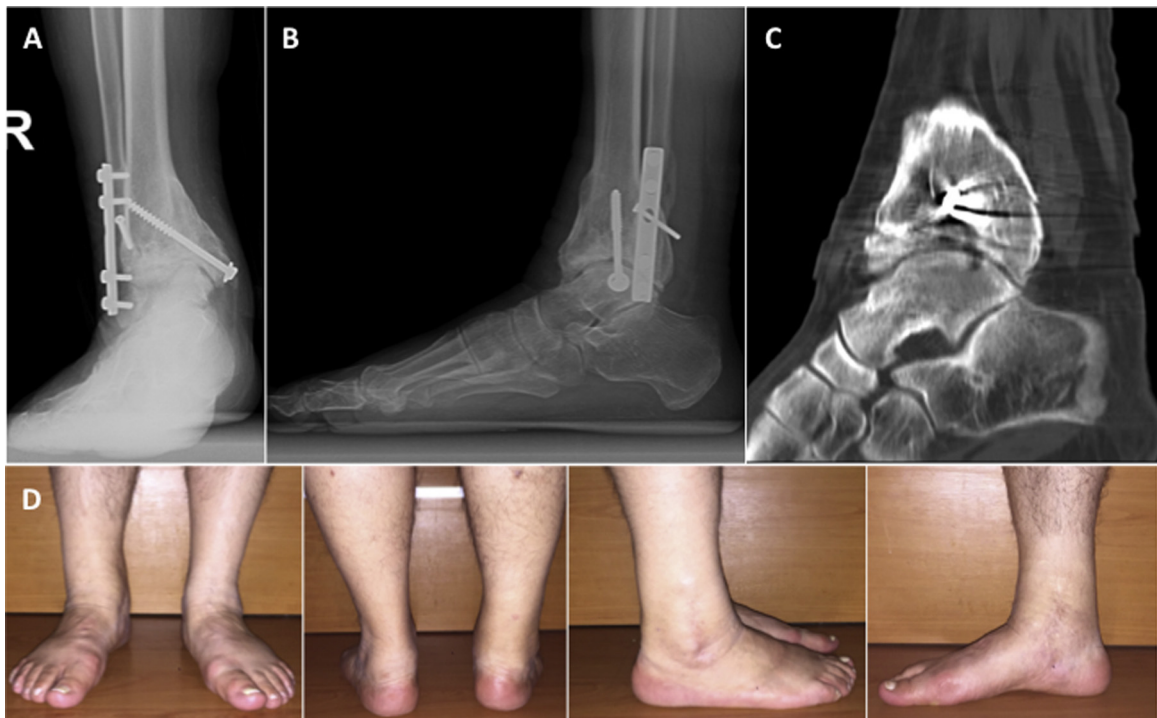


Fig. 4. Clinical and radiological results during the final check of our patient at postoperative 14 years. Anterior–posterior and lateral radiographies of ankle (A, B), ankle's BT display (C) and ankle's clinical photographs (D).

(Fig. 2A–D). Weight bearing and physiotherapy were initiated at 2 months post-operatively. The patient gradually resumed his daily routine of activities and work 3 months post-operatively, with a functional ankle joint, albeit with restricted range of motion, and no pain. The patient was followed annually for 14 years, with no indication of implant failure.

Anterior–posterior and lateral radiographs, at maximum ankle plantar flexion and dorsiflexion, were obtained at the 14 year follow-up. Radiographs indicated narrowing and sclerosis of the articular surfaces of the ankle joint, and a varus deformity of 12°

in the coronal plane, measured between the proximal ankle joint surface and the tibial axis. Computed tomography (CT) images demonstrated remodeling of the TCG in congruity with the talar dome and preservation of the joint space (Figs. 3A–D and 4A–D).

On clinical assessment, range of motion was 50° in plantar flexion and 10° in dorsiflexion, with a VAS pain score of '1' and an American Orthopedic Foot and Ankle Society (AOFAS) score of 92. Clinical assessment of the donor site was unremarkable. The patient had been able to return to his usual work, which required strenuous body activity, and is still active in his profession.

3. Discussion

POA is a complication of traumatic joint fractures that disrupt the articular surface as well as of injuries that lead to joint instability [1,6]. After severe ankle trauma involving the tibial plafond, the incidence of POA has been reported to be as high as 70–75% [2]. Several factors are likely to contribute to this high incidence of POA associated to tibial plafond fractures, including acute injury to the cartilage; biological processes, such as bleeding and inflammation; instability; joint incongruity; and chronic joint overloading due to malalignment [7]. Patient age and injury severity score also contribute to poor clinical outcome and to progressive joint degeneration [1]. Unsuccessful surgical intervention may further increase the risk of POA. As seen in our case, inappropriate initial surgical technique or post-operative implant failure is a significant risk factor for POA, due to joint instability, incongruity and malalignment.

Early surgical intervention and anatomical reduction with appropriate fixation are essential in the management of intra-articular fractures. The best clinical approach to decrease the risk for POA is restoration of the three basic factors: congruity, stability and alignment [1]. Various techniques have been proposed for the reduction of intra-articular fractures, with arthroscopy-assisted surgery being the treatment of choice for malleolar and pilon fractures of the ankle [8]. The combination of surgical methods and new molecular techniques are emerging as an approach to decrease and to prevent progressive tissue damage triggered by joint injury [7]. The focus of clinical research in the treatment of osteoarthritis is the improvement of biological interventions, including tissue engineering methods to decrease, and possibly prevent, POA in patients having sustained intra-articular fractures.

POA after intra-articular fractures may be due to various factors including cartilage destruction; necrosis of the chondrocytes; disruption of the matrix; release of pro-inflammatory cytokines and reactive oxygen; as well as mechanical factors related to joint instability, incongruity and malalignment [1,7]. In a recent study, Tochigi et al. [9] simulated an intra-articular tibial plafond fracture by delivering a direct impact to fresh human cadaver ankles. These researchers observed a reproducible pattern of injury to the tibial plafond and chondrocyte death, with significantly more chondrocyte death adjacent to the fracture lines, compared to locations distant from the fracture (25.9% and 8.6% chondrocyte death at adjacent and distal locations, respectively). Chondrocyte death progressed over 48 h after the initial injury [9].

Autogenous bone grafting is a reliable treatment option to augment structural stability, bone defects and bone-healing. The iliac crest remains the most common donor site for autogenous bone grafting [10]. Indications for bone grafting include delayed union or nonunion, malunion, arthrodesis, limb salvage, and reconstruction of bone voids or defects [11,12]. Using TCG to manage a malreduced pilon fracture in an ankle which cannot be reconstructed, has not been previously described. We performed TCG with internal fixation in order to restore stability, congruency and alignment in a young patient in whom a biological restoration was feasible due to good bone quality. Our technique was successful in providing the patient with a pain-free and functional ankle. Although favorable clinical outcomes were achieved, the TCG with internal fixation technique is not designed to preserve articular cartilage.

Despite the joint damage, its functions were not damaged to an advanced degree, and in our young case with delayed treatment, we used TCG as if it was a joint's surface. We observed that it could be implemented without fusion when restoring chondral defect and metaphyseal damage. During the long term follow-up of our case, we obtained a high satisfaction without an evident functional restriction and pain. The treatment technique we applied is not a method that we implement as a standard for multi-fragmented fractures. As it has been in our case, we believe that it may be

implemented in the cases which are in accordance with irreversible damage and deformity on the tibial articulation surface of ankle as a result of post-trauma insufficient surgical treatment. Furthermore, in addition to the restoration of the existing damage, it may be implemented on restricted cases to prepare for the completion of the actual surgical treatment. Researching on the effect of the method we implement for the joint surface damage in the future may be beneficial.

4. Conclusions

For a young patient in whom the tibial plafond was destroyed due to a comminuted, intra-articular fracture and a reconstructive procedure was not feasible due to insufficient initial treatment, a painless ankle, without restriction of functional activities, was obtained using a combination of TCG and internal fixation. In suitable cases, TCG might provide an alternative that may be considered prior to arthrodesis or arthroplasty.

Conflict of interest

The authors declare that they have no conflict of interest.

Patient consent

The patient has consented to the submission of the case report for submission to the journal.

Funding

The authors declared that this study has received no financial support.

Author contribution

MBB proceeded surgery and clinical evaluation. MBB, YEA, HB, and AA were involved in the conception, design and interpretation. MBB and YEA, wrote the manuscript. MBB and HB collected data, reviewed relevant published reports and provided the images. MBB, YEA, HB and AA drafted the article or revised it critically for important intellectual content. All authors read and approved the final manuscript.

Guarantor

Mehmet Bulent Balioglu.

References

- [1] M.L. Schenker, R.L. Mauck, J. Ahn, S. Mehta, Pathogenesis and prevention of post-traumatic osteoarthritis after intra-articular fracture, *J. Am. Acad. Orthop. Surg.* 22 (2014) 20–28.
- [2] J.L. Marsh, D.P. Weigel, D.R. Dirschl, Tibial plafond fractures: how do these ankles function over time? *J. Bone Joint Surg. Am.* 85 (2003) 287–295.
- [3] D.D. Anderson, S. Chubinskaya, F. Guilak, et al., Post-traumatic osteoarthritis: improved understanding and opportunities for early intervention, *J. Orthop. Res.* 29 (2011) 802–809.
- [4] P.V. Giannoudis, M.R. Grotz, C. Papakostidis, et al., Operative treatment of displaced fractures of the acetabulum: a meta-analysis, *J. Bone Joint Surg. Br.* 87 (2005) 2–9.
- [5] S.A. Labib, S.M. Raikin, J.T. Lau, et al., Joint preservation procedures for ankle arthritis, *Foot Ankle Int.* 34 (2013) 1040–1047.
- [6] T.D. Brown, R.C. Johnston, C.L. Saltzman, et al., Post-traumatic osteoarthritis: a first estimate of incidence, prevalence, and burden of disease, *J. Orthop. Trauma* 20 (2006) 739–744.

- [7] D.D. Anderson, S. Chubinskaya, F. Guilak, et al., Post-traumatic osteoarthritis: improved understanding and opportunities for early intervention, *J. Orthop. Res.* 29 (2011) 802–809.
- [8] K. Atesok, M.N. Doral, T. Whipple, et al., Arthroscopy-assisted fracture fixation, *Knee Surg. Sports Traumatol. Arthrosc.* 19 (2011) 320–329.
- [9] Y. Tochigi, J.A. Buckwalter, J.A. Martin, et al., Distribution and progression of chondrocyte damage in a whole-organ model of human ankle intra-articular fracture, *J. Bone Joint Surg. Am.* 93 (2011) 533–539.
- [10] C. Myeroff, M. Archdeacon, Autogenous bone graft: donor sites and techniques, *J. Bone Joint Surg. Am.* 93 (2011) 2227–2236.
- [11] C.G. Finkemeier, Bone-grafting and bone-graft substitutes, *J. Bone Joint Surg. Am.* 84 (2002) 454–464.
- [12] S.C. Brawley, R.B. Simpson, Results of an alternative autogenous iliac crest bone graft harvest method, *Orthopedics* 29 (2006) 342–346.

Open Access

This article is published Open Access at sciedirect.com. It is distributed under the [IJSCR Supplemental terms and conditions](#), which permits unrestricted non commercial use, distribution, and reproduction in any medium, provided the original authors and source are credited.