

## A modified-simple technique of removing the lens cortex during cataract surgery

*Kyung Eun Han, Se Hoon Han<sup>1</sup>, Dongkwon Lim<sup>2</sup>,  
Min Chul Shin<sup>1</sup>*

Access this article online	
Quick Response Code:	Website: www.ijo.in
	DOI: 10.4103/ijo.IJO_456_14

Department of Ophthalmology, Ewha Womans University School of Medicine, Mok-dong Hospital, Seoul, <sup>1</sup>Department of Ophthalmology, Hallym University College of Medicine, Chuncheon Sacred Heart Hospital, Chuncheon, <sup>2</sup>Moonsan Jaeil Eye Center, Paju, South Korea

**Correspondence to:** Dr. Min Chul Shin, Department of Ophthalmology, Hallym University College of Medicine, Chuncheon Sacred Heart Hospital, 77 Sakju-ro, Chuncheon 24253, South Korea. E-mail: mcshin@hallym.ac.kr

Manuscript received: 02.07.14; Revision accepted: 14.12.16

We describe here a surgical technique of removing the remaining cortex after phacoemulsification without performing the conventional irrigation/aspiration (I/A) procedure. In this technique, the remaining cortex attached to the posterior capsule was separated and dissected into several pieces by continuous irrigation with balanced salt solution, which was supplied through a syringe attached to a bent, blunt-tip needle. Approximately, 10 s of manual irrigation separated most of the remaining cortex from the posterior capsule. Then, the capsular bag was inflated with an ophthalmic viscoelastic device (OVD), and this pushed the separated cortex toward the capsular fornix mechanically. An intraocular lens was inserted into the capsular bag, following which the remaining cortex and OVD were removed concomitantly using an automated I/A handpiece. This technique is a simple and easy maneuver to remove the cortex from all areas, including the subincisional area, and reduce the possibility of a posterior capsule tear.

**Key words:** Cataract surgery, cortex removal, irrigation and aspiration

This is an open access article distributed under the terms of the Creative Commons Attribution-NonCommercial-ShareAlike 3.0 License, which allows others to remix, tweak, and build upon the work non-commercially, as long as the author is credited and the new creations are licensed under the identical terms.

**For reprints contact:** reprints@medknow.com

**Cite this article as:** Han KE, Han SH, Lim D, Shin MC. A modified-simple technique of removing the lens cortex during cataract surgery. Indian J Ophthalmol 2017;65:59-61.

© 2017 Indian Journal of Ophthalmology | Published by Wolters Kluwer - Medknow

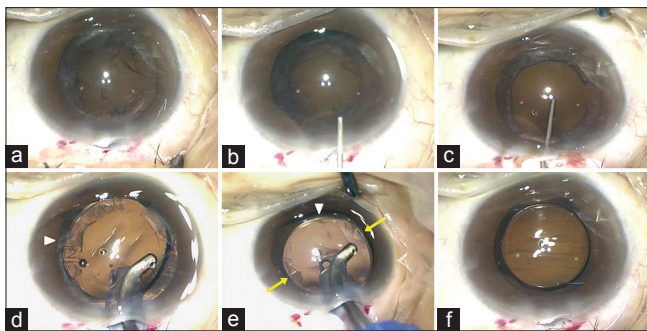
Posterior capsule tear is not rare but it can be a significant complication of cataract surgery. It occurs in 2.6%–9.9% of resident-performed<sup>[1,2]</sup> and 0.45%–2.5% of expert-performed phacoemulsification surgeries.<sup>[3,4]</sup> Even though half of posterior capsule tears occur during phacoemulsification, 30% of this complication occurs during the irrigation/aspiration (I/A) step.<sup>[3,4]</sup>

In addition, aspiration of the subincisional cortex is a challenging step. Some surgeons use a bimanual I/A, curved I/A tip, or Mcntyre-Binkhorst J-cannula.<sup>[5]</sup> However, to perform these options, additional instruments or high-level skills are needed.

Herein, we describe a simple technique of removing the cortex from all directions without performing the conventional I/A step.

## Materials and Methods

The initial steps of cataract surgery, including phacoemulsification, were the same as those in the standard cataract surgery. In most patients, after removal of the fractured nucleus, a part of the cortex remains on the posterior capsule and in the capsular bag space [Fig. 1a]. Instead of using an automated I/A system to remove the remaining cortex, we used a 2.5 ml syringe containing balanced salt solution (BSS®, Alcon Laboratories, Inc., Fort Worth, TX, USA). The syringe was attached to a bent, blunt-tip needle. Any kind of blunt-tip needle made for ophthalmological surgery can be used. We used the bent, blunt-tip needle that was packed with ophthalmic viscoelastic devices (OVDs). Carefully introducing the needle tip into the anterior chamber, the plunger was pushed with consistent power to continuously irrigate the space between the cortex and the posterior capsule with BSS [Fig. 2a]. Due to posterior pressure, the central part of the posterior capsule slightly protrudes anteriorly compared to the peripheral parts; therefore, starting irrigation with BSS from the central part makes the cortex to be peeled off easily from the posterior capsule. After separating the cortex from



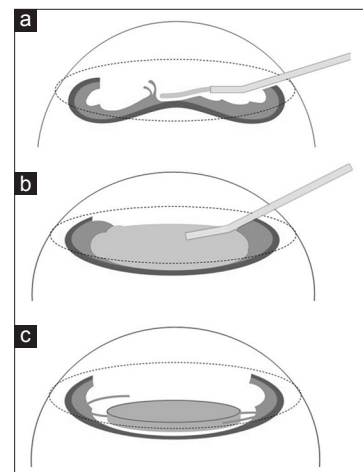
**Figure 1:** A modified-simple technique of removing cortex using a cannula. (a) After removing the nucleus, some cortical materials were remained. (b) Irrigation of balanced salt solution separated the cortex from the posterior capsule. (c) An ophthalmic viscoelastic device pushed the separated cortical materials toward the equator of lens capsule. (d) After insertion of the intraocular lens, the cortex was aspirated by the automated irrigation/aspiration handpiece. (e) When the cortex was trapped by the haptic of the intraocular lens, rotation of the intraocular lens with the irrigation/aspiration tip facilitated removal of the trapped cortex (yellow arrows). The white arrowheads in Fig. 1d and e indicate the same leading haptic. (f) The cortex was removed completely without any remnant by this modified-simple technique

the central part, irrigation with BSS was performed at the mid-periphery while exercising in caution not to go beyond the anterior capsulorhexis area. During this procedure, the irrigated BSS were continuously flushed through the incision site to avoid pressure rise in the anterior chamber. The cortex was then completely peeled from the posterior capsule and divided into several pieces [Fig. 1b]. Afterward, the OVD was injected into the capsular bag space, and the cortex was mechanically pushed toward the capsular fornix by the OVD [Figs. 1c and 2b]. Then, an intraocular lens (IOL) was inserted into the capsular bag [Fig. 2c]. The automated I/A handpiece was introduced into the anterior chamber, and excess OVD was aspirated first. To remove the cortex, the tip of the I/A handpiece was slightly tilted toward the subcapsular cortex, which the surgeon wanted to remove [Fig. 1d]. If the cortex in the capsular fornix was trapped by the haptic of the IOL, a 90° rotation of the IOL in the capsular space helped loosen the firmly attached cortex from the capsule [Fig. 1e]. Additional rotation of the IOL facilitated to peel off the subincisional cortex from the optic edge and haptic of the IOL. In case any cortical material remains between the IOL and the posterior capsule, BSS irrigation underneath the IOL can easily get rid of the cortex through the corneal incision site. Finally, the cortical materials can be completely removed without any remnant [Fig. 1f]

Exclusion criteria of this procedure are the complicated conditions such as anterior or posterior capsular tear, pseudoexfoliation, or any zonular weakness because the intact capsulorhexis and zonule are the major preconditions. This technique can be employed regardless of the size and placement of corneal incision and the number, shape, or material of haptic of the IOL, except for full-optic IOLs such as WIOL-CF® (GELMED, Praha, Czech Republic). We performed approximately 3500 cases of cataract surgeries during the last 4 years with various types of IOLs including one-piece, three-piece, and multiple haptic IOLs.

## Results

The technique described here can help remove the remaining cortex easily, safely, and completely during cataract surgery,



**Figure 2:** Illustrations demonstrating the plane of irrigation (a), pushing the cortex from the center to the capsular fornix with ophthalmic viscoelastic device (b), and immediately after intraocular lens insertion (c)

without using additional surgical instruments. In most patients, it took approximately 10 s and required ~2.5 ml of BSS irrigation to complete separation of the cortex from the posterior capsule. The automated I/A was performed only once after insertion of the IOL to remove the cortex and OVD concomitantly.

Among the 3500 cases, a total of four posterior capsule rupture cases occurred during the period: One case occurred during this cortical removal technique, two cases occurred because of extension of anterior capsular tear, and one case occurred during the phacoemulsification step.

## Discussion

Posterior capsule tear is one of the most common complications encountered during cataract surgery. Vitreous prolapse into the anterior chamber or tilting and decentration of the IOL may occur despite proper execution of the maneuver.

Using our technique, the posterior capsule can be saved from being unintentionally sucked into the automated I/A tip because the IOL acts as a mechanical barrier between the capsule and the suction pressure of automated aspiration. In addition, the anterior chamber and intracapsular space remain stable during the automated I/A procedure because the IOL prevents abrupt collapse of the anterior chamber. Rotation of the IOL in the capsular space dislodges the cortex from the capsule in all areas, including the subincisional area.

We performed this technique with various IOLs, including the three-piece IOLs, one-piece IOLs, and IOLs with multiple haptic designs, and could successfully remove the cortex without encountering any additional significant difficulties.

A cortex removal technique using the J-shaped cannula which was described by Dewey<sup>[5]</sup> has shown good surgical results.<sup>[6]</sup> However, to perform that technique, an additional instrument, the J-cannula, is needed. Moreover, because of the shape of the cannula, intraocular tissues including the iris, anterior and/or posterior capsule, or cornea may get hooked at the tip, as the authors described. We modified the Dewey' technique using the ordinary bent, blunt-tip needle, and OVD which are familiar with surgeons; therefore, to spend a lot of time or effort is not required to learn and perform this technique.

There are some limitations to perform our cortex removing technique. First, this technique is applicable only to the patients whose zonule and posterior capsule are intact; therefore, special cases such as posterior polar cataract or traumatic cataract would not be the indication of this technique. Second, because careless insertion of the irrigation needle may result in the posterior capsule rupture, surgeons have to pay attention not to touch the posterior capsule with the irrigation needle tip during this maneuver.

Previous studies reported that posterior capsule rupture occurred in 0.13%–0.69% during the conventional I/A technique;<sup>[3,4]</sup> on the other hand, we experienced only one case of posterior capsule rupture in 0.02% (1/3600) during the cortical removal using this technique.

In conclusion, this technique has the advantages of being time-saving and effective in removing the cortical materials and reducing the risk of posterior capsule tear, without using any additional instruments during routine cataract surgery.

## Financial support and sponsorship

Nil.

## Conflicts of interest

There are no conflicts of interest.

## References

1. Blomquist PH, Morales ME, Tong L, Ahn C. Risk factors for vitreous complications in resident-performed phacoemulsification surgery. *J Cataract Refract Surg* 2012;38:208-14.
2. Briszi A, Prahs P, Hillenkamp J, Helbig H, Herrmann W. Complication rate and risk factors for intraoperative complications in resident-performed phacoemulsification surgery. *Graefes Arch Clin Exp Ophthalmol* 2012;50:1315-20.
3. Gimbel HV, Sun R, Ferensowicz M, Anderson Penno E, Kamal A. Intraoperative management of posterior capsule tears in phacoemulsification and intraocular lens implantation. *Ophthalmology* 2001;108:2186-9.
4. Pingree MF, Crandall AS, Olson RJ. Cataract surgery complications in 1 year at an academic institution. *J Cataract Refract Surg* 1999;25:705-8.
5. Dewey SH. Cortical removal simplified by J-cannula irrigation. *J Cataract Refract Surg* 2002;28:11-4.
6. Sudan R, Dada VK, Muralidhar R. Cortical removal simplified by J-cannula irrigation. *J Cataract Refract Surg* 2002;28:1720-1.