

Intraoperative Retinal Changes May Predict Surgical Outcomes After Epiretinal Membrane Peeling

Lekha K. Mukkamala^{1,*}, Jaycob Avaylon^{2,*}, R. Joel Welch¹, Amirfarbod Yazdanyar¹, Parisa Emami-Naeini¹, Sophia Wong¹, Jordan Storkersen², Jessica Loo³, David Cunefare³, Sina Farsiu³, Ala Moshiri¹, Susanna S. Park¹, and Glenn Yiu¹

¹ Department of Ophthalmology & Vision Science, University of California, Davis, Sacramento, CA, USA

² California Northstate University, College of Medicine, Elk Grove, CA, USA

³ Department of Biomedical Engineering, Duke University, Durham, NC, USA

Correspondence: Glenn Yiu, University of California, Davis, 4860 Y Street, Suite 2400, Sacramento, CA 95817, USA.
e-mail: gyiu@ucdavis.edu

Received: October 16, 2020

Accepted: January 12, 2021

Published: February 23, 2021

Keywords: epiretinal membrane; intraoperative optical coherence tomography; vision

Citation: Mukkamala LK, Avaylon J, Welch RJ, Yazdanyar A, Emami-Naeini P, Wong S, Storkersen J, Loo J, Cunefare D, Farsiu S, Moshiri A, Park SS, Yiu G. Intraoperative retinal changes may predict surgical outcomes after epiretinal membrane peeling. *Trans Vis Sci Tech.* 2021;10(2):36.
<https://doi.org/10.1167/tvst.10.2.36>

Purpose: To investigate whether intraoperative retinal changes during epiretinal membrane (ERM) peeling affect anatomic or functional outcomes after surgery.

Methods: We measured retinal thickness using an intraoperative optical coherence tomography (iOCT) device in patients undergoing pars plana vitrectomy with membrane peeling for idiopathic ERM. Changes in intraoperative central macular thickness (iCMT) were compared with postoperative improvements in CMT and best-corrected visual acuity (VA).

Results: Twenty-seven eyes from 27 patients (mean age 68 years) underwent iOCT-assisted ERM peeling surgery. Before surgery, mean VA was logMAR 0.50 ± 0.36 (Snellen 20/63), and mean baseline CMT was 489 ± 82 μm. Mean iCMT before peeling was 477 ± 87 μm, which correlated well with preoperative CMT ($P < 0.001$). Mean change in iCMT was -39.6 ± 37 μm (range -116 to $+77$ μm). After surgery, VA improved to logMAR 0.40 ± 0.38 (Snellen 20/50) at month 1 and logMAR 0.27 ± 0.23 (Snellen 20/37) at month 3, whereas CMT decreased to 397 ± 44 μm and 396 ± 51 μm at months 1 and 3. Eyes that underwent greater amount of iCMT change (absolute value of iCMT change) were associated with greater CMT reduction at month 1 ($P < 0.001$) and month 3 ($P = 0.010$), whereas those with greater intraoperative thinning (actual iCMT change) showed a trend toward better VA outcomes at months 1 ($P = 0.054$) and 3 ($P = 0.036$).

Conclusions: Intraoperative changes in retinal thickness may predict anatomic and visual outcomes after idiopathic ERM peeling surgery.

Translational Relevance: Our study suggests that intraoperative retinal tissue response to ERM peeling surgery measured by iOCT may be a prognostic indicator for restoration of retinal architecture and for visual acuity outcomes.

Introduction

Surgical removal of idiopathic epiretinal membranes (ERMs) has the ability to restore retinal architecture and improve visual acuity, but outcomes vary between individual patients.^{1,2} Predictors of visual improvement after membrane peeling surgery include clinical factors such as preoperative visual acuity and duration of symptoms,^{3,4} as well as structural biomarkers such as photoreceptor integrity as

seen on optical coherence tomography (OCT) before or after surgery.³⁻⁵ However, these prognostic factors do not consider the anatomic changes that occur during surgery, and whether retinal response to tissue handling and instrumentation may impact surgical success.

Intraoperative OCT (iOCT) provides high-resolution cross-sectional visualization of the neurosensory retina during vitreoretinal surgery and may help guide surgical decision-making.⁶⁻¹⁴ In the Prospective Intraoperative and Perioperative

Ophthalmic Imaging with Optical Coherence Tomography (PIONEER) study, posterior segment surgeons reported that iOCT altered surgical decision in 29% of cases. For ERM surgery, iOCT identified occult residual membranes in 12% of cases that necessitated additional membrane peeling, and confirmed completion of removal in 9% of cases that helped to reduce unnecessary surgical maneuvers.¹⁵ The iOCT also allows structural changes in retinal architecture to be visualized with exquisite detail. Past studies have demonstrated intraoperative changes in retinal thickness and increased separation of outer retinal layers immediately after membrane peeling. However, the prognostic value of these structural changes remains unclear.¹⁶

In this study, we investigate whether intraoperative changes in retinal anatomy may affect functional or anatomic outcomes after idiopathic ERM surgery. Specifically, we hypothesize that greater tissue elasticity, as demonstrated by retinal thickness changes measured using a microscope-integrated iOCT immediately after membrane peeling, may allow better restoration of retinal architecture and rehabilitation of vision.

Methods

Patient Selection

We reviewed the medical records and OCT images of all consecutive patients who underwent pars plana vitrectomy and membrane peeling for idiopathic ERMs at the University of California Davis Eye Center from October 1, 2015, to March 30, 2020, with at least 3 months of clinical follow-up. All patients who underwent membrane surgery during this study period underwent iOCT-assisted idiopathic ERM surgery using the Rescan 700 iOCT device (Carl Zeiss Meditec, Dublin, CA, USA). Eyes with other ocular comorbidities or history of ocular surgery except uncomplicated cataract extraction were excluded. We collected demographic and clinical data including best-corrected visual acuity (BCVA), lens status, and central macular thickness (CMT) at the preoperative visit, and at postoperative months 1 and 3 visits. BCVA were measured using Snellen testing, and converted to logMAR for statistical analysis. The study was approved by the Institutional Review Board of University of California, Davis, and was performed in accordance with the tenets of the Declaration of Helsinki.

OCT Imaging

Perioperative OCT images were obtained with either the Cirrus SD-OCT device (Carl Zeiss Meditec) or the Spectralis OCT+SLO device (Heidelberg Engineering, Heidelberg, Germany). Cirrus OCT images were captured as 6×6 mm volume scans, with 350 B-scans and 350 A-scans per B-scan, with two images averaged per scan. Spectralis OCT images were captured as $20^\circ \times 20^\circ$ (approximately 6×6 mm) volume scans with 25 B-scans and 512 A-scans per B-scan, with automated real-time tracking setting of 10. CMT was automatically measured from the central 1 mm area using the OCT devices' native segmentation algorithm for retinal thickness measurements. All preoperative and postoperative images were acquired longitudinally on the same OCT system, with image registration enabled, and image segmentation verified for accuracy. Images with errors in foveal centration or inaccurate segmentation were manually corrected.

Surgical Technique

All patients underwent standard three-port 23- or 25-gauge pars plana vitrectomy using the Constellation vitrectomy system (Alcon, Fort Worth, TX, USA) by one of four retinal surgeons with assistance by a vitreoretinal fellow. After performing core vitrectomy and inducing a posterior vitreous detachment as needed, the ERM was peeled using end-gripping forceps, using triamcinolone acetonide to assist with visualization. Additional indocyanine green staining and internal limiting membrane (ILM) peeling were conducted at the discretion of the surgeon. The intraocular pressure was maintained at the same level using the Constellation system's intraocular pressure compensation feature at each time point of iOCT image capture. Subconjunctival dexamethasone and cefazolin were given at the conclusion of all cases.¹⁷

The iOCT Imaging and Analysis

The iOCT images of the macula were captured after initiation of the infusion, but before performing vitrectomy or membrane peeling, and immediately after removal of the ERM and ILM. The iOCT images were captured using the Rescan 700 iOCT device (Carl Zeiss Meditec) as 6×6 mm volume scans, with 128 B-scans and 512 A-scans per B-scan using the 128D lens of the Resight 700 noncontact fundus viewing system. A-scan depth was 2 mm (1024 pixels) for 24 of the 27 eyes, and 2.9 mm (1024 pixels) for the remaining three eyes after a software update. The iOCT images were captured as 512×1024 pixel bitmap files, with 128 bitmap

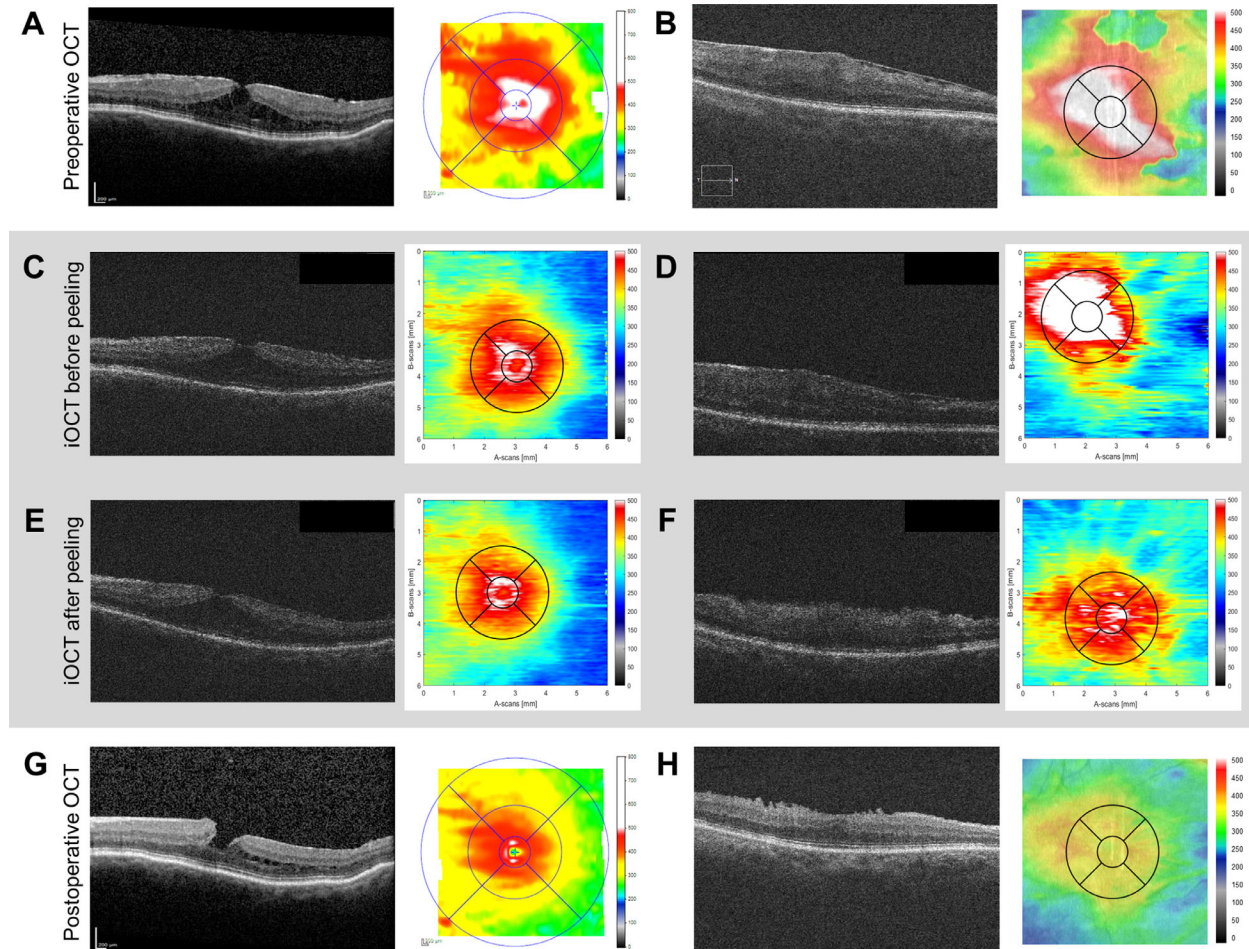


Figure 1. Preoperative OCT (**A, B**), iOCT (*gray*) before (**C, D**) and after membrane peeling (**E, F**), and postoperative OCT at month 3 (**G, H**) of two patients exhibiting minimal (**A, C, E, G**) or prominent (**B, D, F, H**) iCMT change on iOCT after ERM peeling surgery.

images per volume stack. The iOCT images were imported into the Duke Optical Coherence Tomography Retinal Analysis Program software¹⁸ for semiautomated segmentation of the internal limiting membrane and the outer border of the retinal pigment epithelium–Bruchs membrane complex,^{19,20} with manual adjustments of the segmentation performed where necessary. The fovea was manually identified by a masked grader based on the location of greatest outer segment elongation, and the intraoperative CMT (iCMT) was measured from the central 1 mm diameter circle to correspond with the preoperative and postoperative OCT images and the central circle of the Early Treatment Diabetic Retinopathy Study grid (Fig. 1). Thickness measurements were determined using the Duke Optical Coherence Tomography Retinal Analysis Program after calibration with scan density and resolution parameters provided by the manufacturer based on model eyes. The calibration and measurements were validated by correlating CMT measure-

ments from preoperative conventional OCT scans with iCMT measurements before membrane peeling on iOCT scans. In addition, average retinal thickness across the central 3 mm–diameter region corresponding to the central circle and inner ring of the Early Treatment Diabetic Retinopathy Study grid was also measured. Eyes with missing iOCT images or iOCT image quality that was insufficient for semiautomated segmentation were excluded from the study.

Statistical Analyses

Statistical analyses were performed using SPSS software (version 22.0; IBM, Chicago, IL, USA). We evaluated the correlation between iCMT before membrane peeling and preoperative CMT using linear regression analysis. The relationship between BCVA and CMT was also assessed by linear regression. Intraoperative changes in iCMT before and after peeling and changes in BCVA and CMT before and after ERM

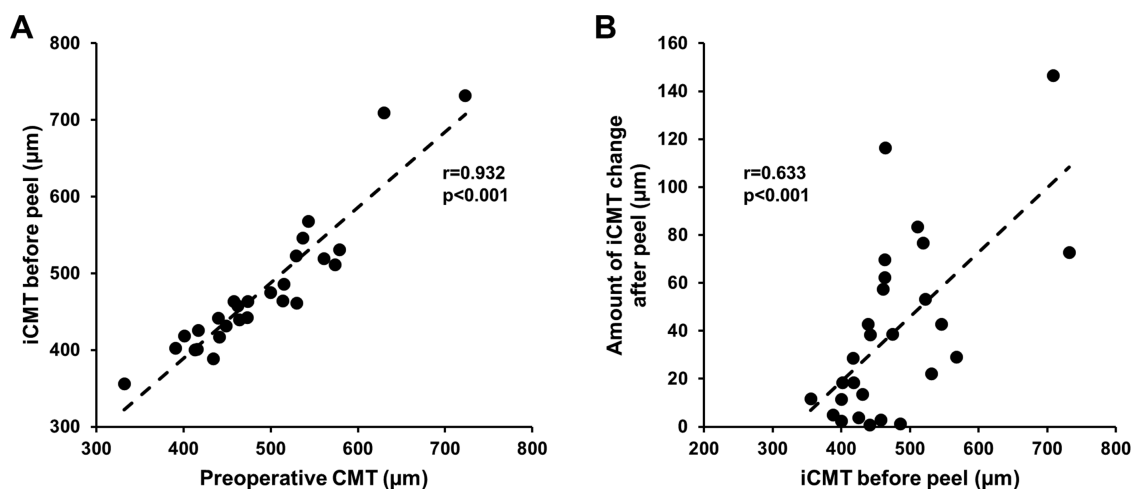


Figure 2. Scatterplots comparing preoperative CMT with iCMT before membrane peeling (A), and iCMT before membrane peeling with iCMT change after membrane peeling (B).

surgery were compared using paired-samples *t*-tests. Any association between iCMT change during surgery and postoperative visual (BCVA change) or anatomic (CMT change) outcomes at one and three months were determined using univariate and multivariate linear regression analyses. The iCMT change was analyzed as either amount of iCMT change (absolute value of iCMT change) or actual iCMT change, which takes the direction of change into account. Variables included in multivariate linear regression models include age, gender, laterality, presence of a posterior vitreous detachment, lens status, and amount or actual iCMT change. *P* values <0.05 were considered statistically significant.

Results

Baseline Characteristics

We identified 48 eyes from 48 patients that underwent iOCT-assisted ERM peeling surgery that met inclusion criteria during the study period. Seven eyes were excluded because of poor-quality images, and 12 were excluded because of lack of complete image acquisition. Two additional patients were lost to follow-up after surgery. Therefore 27 patients (27 eyes) met inclusion criteria for this analysis. The mean age of patients was 68 years (range 48–81), with 12 female and 15 male subjects, and 14 right and 13 left eyes. Nineteen patients were phakic, and eight were pseudophakic. Mean preoperative BCVA was logMAR 0.50 ± 0.36 (Snellen 20/63) and mean baseline CMT was

$489 \pm 82 \mu\text{m}$, with no clear association between visual acuity and anatomy before surgery.

Among the 19 phakic patients, six underwent combined phacovitrectomy with cataract extraction and intraocular lens placement before membrane peeling. A posterior vitreous detachment (PVD) was already present in 13 of 27 eyes and was surgically induced in the remaining 14 eyes, of which nine eyes had an additional iOCT image captured after PVD induction and before ERM peeling. All eyes underwent ERM peeling with triamcinolone acetate, and almost all eyes (26 of 27 eyes) had indocyanine green staining and ILM peeling.

Intraoperative Thickness Changes

Before membrane peeling, mean iCMT was $477 \pm 87 \mu\text{m}$, which correlated well with mean preoperative CMT measurements of $489 \pm 82 \mu\text{m}$ ($r = 0.932$, $P < 0.001$, Fig. 2A) and validates the accuracy of iCMT measurements using our segmentation methods. After membrane peeling, the mean iCMT was $454 \pm 78 \mu\text{m}$, which was significantly different from iCMT before peeling ($P = 0.028$). Some eyes had decreased macular thickness after ERM removal while others showed no change or even increased thickness (range $-116 \mu\text{m}$ to $77 \mu\text{m}$). The mean amount of iCMT change after membrane peeling was $39.6 \pm 37.0 \mu\text{m}$. Retinas that were thicker before peeling tended to show a greater amount of iCMT change after membrane removal ($r = 0.633$, $P < 0.001$, Fig. 2B). When intraoperative macular thicknesses were averaged across the central 3 mm diameter circle, a similar trend was noted, although the degree of retinal thickness change was less

pronounced (mean change $36.5 \pm 44 \mu\text{m}$). In a subset of eyes in which a PVD was surgically induced and iOCT was performed before and after PVD induction, we noted no significant change in iCMT after PVD induction ($500 \pm 58 \mu\text{m}$ vs. $496 \pm 40 \mu\text{m}$, $P = 0.82$).

Surgical Outcomes and Intraoperative Predictors

Overall, subjects showed improved visual acuity and decreased CMT after iOCT-assisted ERM peeling surgery. Mean BCVA improved from logMAR 0.50 ± 0.36 (Snellen 20/63) to logMAR 0.40 ± 0.38 (Snellen 20/50) at month 1 ($P = 0.007$) and logMAR 0.27 ± 0.23 (Snellen 20/37) at month 3 ($P < 0.001$), after exclusion of two eyes that developed visually significant cataracts. There were no significant differences in BCVA improvements between phakic versus pseudophakic eyes at one month ($P = 0.860$) or three months ($P = 0.646$), and between combined phacovitrectomies versus vitrectomy alone among phakic patients at postoperative month 1 ($P = 0.260$) or month 3 ($P = 0.786$), consistent with published reports.²¹ Mean CMT decreased from $489 \pm 82 \mu\text{m}$ before surgery, to $397 \pm 44 \mu\text{m}$ at month 1 ($P < 0.001$) and $396 \pm 59 \mu\text{m}$ at month 3 ($P < 0.001$) after surgery. There were no ERM recurrences detected during the follow-up period.

Interestingly, the amount of iCMT change after membrane peeling was associated with anatomic outcomes at 1 month ($r = 0.658$, $P = 0.001$, Fig. 3A) and 3 months ($r = 0.553$, $P = 0.003$, Fig. 3B), with eyes that demonstrated greater iCMT changes showing greater CMT improvements after surgery. Multivariate regression accounting for age, sex, laterality, PVD status, and lens status confirms that the amount of iCMT change is independently associated with anatomic outcomes at one and three months ($P < 0.001$ and $P = 0.010$, Table). By contrast, actual iCMT change, which accounts for the direction of iCMT change (i.e., whether retinal thickening or thinning occurred after membrane peeling), did not impact anatomic improvements at one and three months in both univariate and multivariate regression models (Fig. 3C and Fig. 3D, Table).

With respect to visual outcomes, the amount of iCMT change showed a possible relationship with visual outcomes at one month ($r = 0.453$, $P = 0.030$, Fig. 4A) but not at three months ($r = 0.334$, $P = 0.120$, Fig. 4B), even after excluding the two eyes that developed significant cataracts after surgery, but was not confirmed on multivariate regression ($P = 0.124$) (Table). However, the actual iCMT change

appeared to be associated with visual outcomes at one month ($r = 0.487$, $P = 0.018$, Fig. 4C) and three months ($r = 0.530$, $P = 0.009$, Fig. 4D), with eyes that demonstrated intraoperative retinal thinning exhibiting greater improvement in vision, and was confirmed on multivariate regression at three months ($P = 0.036$, Table) and possibly at one month ($P = 0.054$, Table). Together, our results suggest that intraoperative changes in retinal thickness may predict surgical outcomes, with the amount of intraoperative CMT change associated with anatomic improvement and actual iCMT change associated with visual recovery.

Discussion

The advent of commercial iOCT systems has broadened the availability of this technology for intraoperative visualization of retinal anatomy during vitreoretinal surgery. In the DISCOVER study, both anterior and posterior segment surgeons found iOCT technology useful, with many indicating that iOCT data impacted surgical decision making and altered the procedure.²² Intraoperative OCT can also detect microanatomic retinal changes during macular surgery. In a study of 12 eyes that underwent ERM surgery with a microscope-mounted iOCT system, central retinal thickness was found to increase by less than 2% after ILM peeling, although a majority showed a subretinal hyporeflectance suggesting a shallow macular detachment after membrane removal.²³ In another study of 10 eyes, retinal thickness measured using a handheld iOCT decreased after membrane removal but returned to baseline after additional ILM peeling.²⁴ An analysis of subjects from the PIONEER study also revealed an increased separation between the retinal pigment epithelium and the ellipsoid and interdigitation zones following membrane peeling, as identified on a single foveal scan.¹⁵ Another analysis from the PIONEER study revealed a probable link between intraoperative subretinal fluid under PFO tamponade in patients undergoing surgery for macula-involving retinal detachment and visual outcomes.²⁵ A more recent analysis of eyes that underwent full-thickness macular hole repair from the PIONEER study revealed several characteristics measured by iOCT may be able to predict macular hole closure speed.²⁶ These studies provide insight into retinal changes during macular surgery, and the impact of these changes on postoperative outcomes remain an active area of research.

In our study, we demonstrated variable changes in intraoperative retinal thickness after ERM removal

Table. Association Between Intraoperative Retinal Changes and Postoperative Anatomic and Visual Outcomes

	POM1 CMT Change			POM3 CMT Change			POM1 VA Change			POM3 VA Change		
	Estm	SE	P Value	Estm	SE	P Value	Estm	SE	P Value	Estm	SE	P Value
Univariate Regression												
Amount of iCMT Change	-1.13	0.30	0.001	-0.78	0.24	0.003	-0.002	0.001	0.03	-0.003	0.002	0.12
Actual iCMT Change	0.43	0.26	0.113	0.09	0.21	0.660	0.002	0.001	0.018	0.003	0.001	0.009
Multivariate Regression: Age, Gender, Eye, PVD, Lens Status, and Amount of iCMT Change												
Amount of iCMT Change	-1.175	0.246	<0.001	-0.694	0.246	0.010	-0.001	0.001	0.124	-0.003	0.002	0.181
Multivariate Regression: Age, Gender, Eye, PVD, Lens Status, and Actual iCMT Change												
Actual iCMT Change	0.352	0.264	0.203	0.032	0.211	0.880	0.002	0.001	0.054	0.003	0.001	0.036

Values shown demonstrate relationships between iCMT change and CMT or VA change at follow-up. Amount of iCMT change is calculated as the absolute value of the actual iCMT change.

POM, postoperative month; Estm, estimate; SE, standard error.

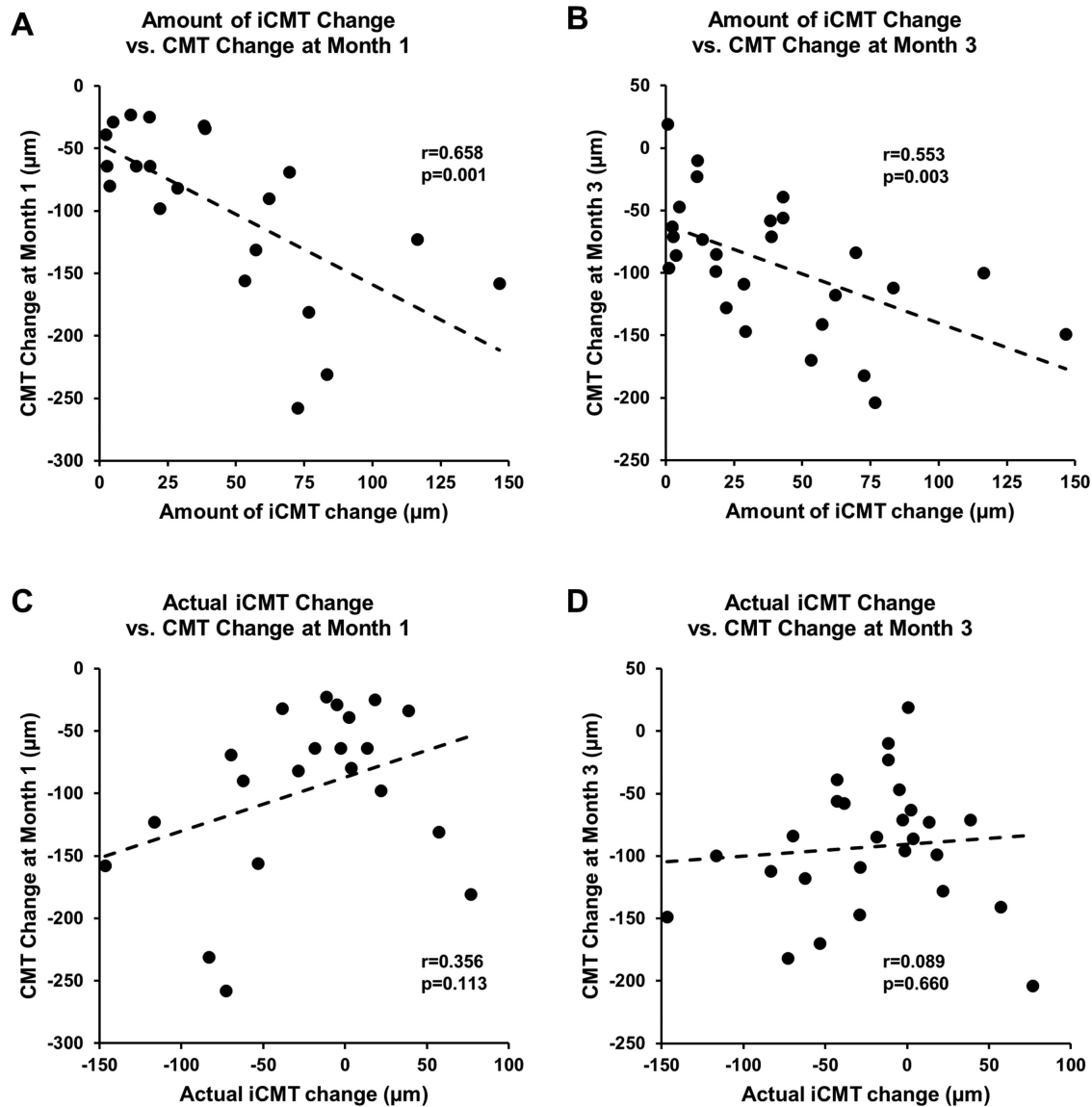


Figure 3. Scatterplots comparing the amount of iCMT change with postoperative change in CMT at month 1 (A) and month 3 (B) after surgery, and actual iCMT change with postoperative change in CMT at month 1 (C) and month 3 (D) after surgery.

and found that the amount of iCMT change may be associated with anatomic improvements up to three months after surgery. We hypothesize that the amount of iCMT change reflects retinal tissue elasticity—a “stiffer” retina that does not exhibit as much intraoperative change will less likely undergo significant anatomic restoration postoperatively. In addition, differences in the amount of ERM tractional force across the macula released after ERM peeling may play a role in iCMT change. Thus four different mechanistic combinations could be theorized: low elasticity/low traction could cause a minimal iCMT change, low elasticity/high traction or high elasticity/low traction could cause an intermediate iCMT change, and a

high elasticity/high traction could cause a large iCMT change.

We also found that the actual iCMT change may be associated with visual outcomes up to three months after surgery. Unlike the amount of iCMT change that reflects retinal elasticity or ERM traction, the actual iCMT change incorporates directionality. We hypothesize that iCMT decrease may signify preservation or restoration of retinal and photoreceptor integrity, whereas iCMT increase may suggest stretching and possible cellular damage that could lead to eventual function loss. Although the iOCT techniques used in this study did not provide consistently adequate image quality to enable accurate segmentation of individual

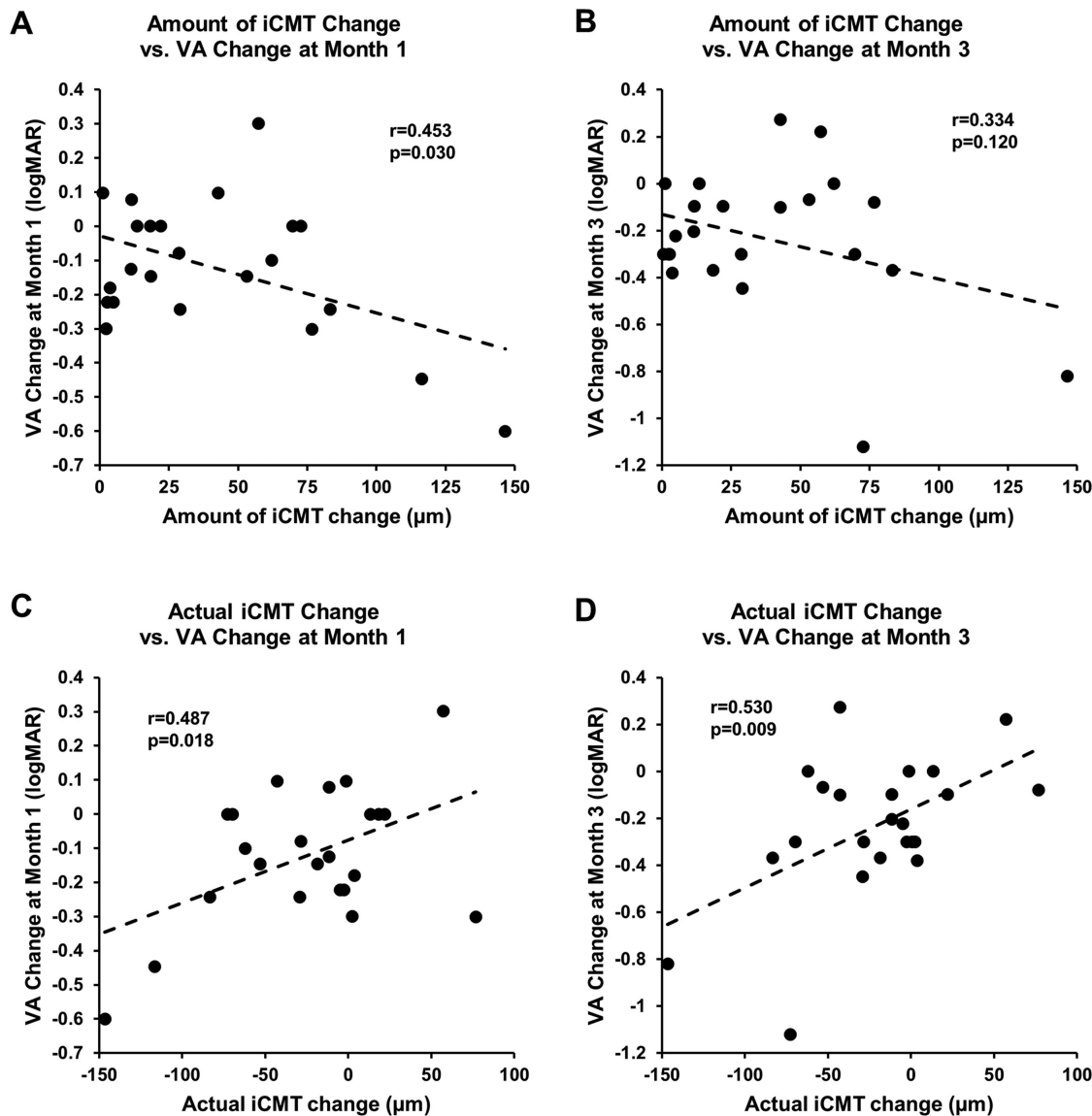


Figure 4. Scatterplots comparing the amount of iCMT change with postoperative VA improvement at month 1 (A) and month 3 (B) after surgery, and actual iCMT change with postoperative VA improvement at month 1 (C) and month 3 (D) after surgery.

retinal layers, future studies measuring the thickness of these individual layers using a contact flat lens or other iOCT systems with higher resolution could provide greater insight into the structural integrity of the photoreceptor layer following ERM peeling. Few prior studies demonstrated a strong, consistent correlation between anatomic and functional improvements after ERM surgery. A study of 21 eyes that underwent vitrectomy for idiopathic ERM showed significant retinal thinning at three months after surgery, but significant visual acuity improvements did not occur until nine months after surgery.²⁷ Although overall visual acuity improved in our cohort within three months after surgery, cataract progression limited visual gains in two

eyes. Perhaps a larger cohort with more pseudophakic eyes, higher resolution imaging, and longer duration of follow-up may overcome these limitations and reveal a clearer relationship between intraoperative retinal changes and visual outcomes.

Although qualitative features have been shown to correlate well between intraoperative and preoperative OCT,²⁸ the reproducibility of quantitative measurements between the two modalities has not been fully validated. In our analysis, we demonstrated high correlation between the intraoperative CMT (iCMT) measured from the central 1 mm-diameter circle and preoperative CMT measured using conventional OCT devices, although we did not perform

axial length measurements to more precisely calibrate iCMT and CMT measurements. Instead of relying on single-location measurements, we used semiautomated segmentation of the iOCT images, with averaged retinal thickness measured up to a 3 mm-diameter circle. This method reduces the variability of manual caliper markings and image registration of the foveal center. Also, the commercial microscope-integrated iOCT device used in our study reduces the microscope adjustments that are necessary when using handheld or microscope-mounted units. Nevertheless, discrepancies between these studies may still arise from differences in membrane peeling technique and variable timing of iOCT capture after ERM removal. Future studies using video capture to provide more dynamic and precisely timed retinal changes, or with X-Y tracking to maintain foveal registration, may improve the reproducibility of iOCT studies. Finally, our findings were limited by the retrospective nature of the study. The presence of a PVD was based on surgeon documentation on the operative report, and the method for how this was assessed was not clearly documented, although PVD status did not impact our findings. Also, although we reviewed clinical charts to exclude patients with diabetic retinopathy or other retinal vascular conditions, retinal tear or detachments, or ocular inflammatory conditions that would suggest a secondary ERM, we cannot exclude the possibility that some of the cases were not truly idiopathic. Last, not all surgeons consistently obtained high-quality iOCT images before and after ERM peeling, so a large number of subjects had to be excluded because of missing or poor-quality images.

Intraoperative OCT helps with surgical decision-making and reveals detailed anatomic retinal changes that occur during vitreoretinal surgery. Our study suggests that intraoperative retinal tissue response to ERM peeling may predict the restoration of retinal architecture and visual acuity outcomes following surgery. Future prospective studies may help elucidate the prognostic implications of iOCT information obtained during macular surgeries.

Acknowledgments

Presented as a poster at the annual meeting for Association of Vision and Research in Ophthalmology (ARVO) on April 29, 2018, in Honolulu, HI.

Supported by Grants from NIH R01 EY032238, NIH R21 EY031108, the BrightFocus Foundation, the Macula Society, NIH K08 EY027463, NIH P30 EY005722, Google Faculty Research Award, and the

2018 Unrestricted Grant from Research to Prevent Blindness.

Disclosure: **L.K. Mukkamala**, None; **J. Avaylon**, None; **R.J. Welch**, None; **A. Yazdanyar**, None; **P. Emami-Naeini**, None; **S. Wong**, None; **J. Storkersen**, None; **J. Loo**, None; **D. Cunefare**, None; **S. Farsiu**, US Patent 8,811,745; 9,299,155; 9,589,346; 10,366,492 (P); **A. Moshiri**, None; **S.S. Park**, conducts contracted research via employer Roche/Novartis; **G. Yiu**, received research support from Clearside Biomedical, Genentech, and Iridex, and personal fees for consultancy from Alimera, Allergan, Carl Zeiss Meditec, Clearside Biomedical, Genentech, Intergalactic Therapeutics, Iridex, Regeneron, Topcon, and Verily

* LKM and JA contributed equally to this work.

References

1. Moisseiev E, Davidovitch Z, Kinori M, Loewenstein A, Moisseiev J, Barak A. Vitrectomy for idiopathic epiretinal membrane in elderly patients: surgical outcomes and visual prognosis. *Curr Eye Res.* 2012;37(1):50–54.
2. Luu KY, Koenigsaecker T, Yazdanyar A, et al. Long-term natural history of idiopathic epiretinal membranes with good visual acuity. *Eye (Lond).* 2019;33(5):714–723.
3. Batman C, Citirik M. The impact of macular surgery in different grades of epiretinal membrane. *Int J Ophthalmol.* 2017;10(12):1877–1882.
4. Pichi F, Alkabes M, Nucci P, Ciardella AP. Intraoperative SD-OCT in macular surgery. *Ophthalmic Surg Lasers Imaging.* 2012;43(6 Suppl):S54–S60.
5. Kim JH, Kim YM, Chung EJ, Lee SY, Koh HJ. Structural and functional predictors of visual outcome of epiretinal membrane surgery. *Am J Ophthalmol.* 2012;153(1):103–110.e1.
6. Ehlers JP, Goshe J, Dupps WJ, Kaiser PK, Singh RP, Gans R, et al. Determination of feasibility and utility of microscope-integrated optical coherence tomography during ophthalmic surgery. *JAMA Ophthalmol.* 2015;133(10):1124–1132.
7. Binder S, Falkner-Radler CI, Hauger C, Matz H, Glittenberg C. Feasibility of intrasurgical spectral-domain optical coherence tomography. *Retina.* 2011;31(7):1332–1336.
8. Dayani PN, Maldonado R, Farsiu S, Toth CA. Intraoperative use of handheld spectral domain optical coherence tomography imaging in macular surgery. *Retina.* 2009;29(10):1457–1468.

9. Ehlers JP, Kaiser PK, Srivastava SK. Intraoperative optical coherence tomography using the RESCAN 700: preliminary results from the DISCOVER study. *Br J Ophthalmol.* 2014;98:1329–1332.
10. Ehlers JP, Dupps WJ, Kaiser PK, et al. The Prospective Intraoperative and Perioperative Ophthalmic Imaging with Optical Coherence Tomography (PIONEER) Study: 2-year results. *Am J Ophthalmol.* 2014;158(5):999–1007.
11. Ehlers JP, Tao YK, Farsiu S, Maldonado R, Izatt JA, Toth CA. Integration of a spectral domain optical coherence tomography system into a surgical microscope for intraoperative imaging. *Invest Ophthalmol Vis Sci.* 2011;52(6):3153–3159.
12. Carrasco-Zevallos OM, Keller B, Viehland C, et al. Live volumetric (4D) visualization and guidance of in vivo human ophthalmic surgery with intraoperative optical coherence tomography. *Sci Rep.* 2016;6:31689.
13. Song Z, Xu L, Wang J, et al. Lightweight learning-based automatic segmentation of subretinal blebs on microscope-integrated optical coherence tomography images. *Am J Ophthalmol.* 2021;221:154–168.
14. Moisseiev E, Yiu G. Role of Tractional Forces and Internal Limiting Membrane in Macular Hole Formation: Insights from Intraoperative Optical Coherence Tomography. *Case Rep Ophthalmol.* 2016;7(2):372–376.
15. Ehlers JP, Khan M, Petkovsek D, Stiegel L, Kaiser PK, Singh RP, et al. Outcomes of intraoperative OCT-assisted epiretinal membrane surgery from the PIONEER study. *Ophthalmol Retina.* 2017;2017:1–5.
16. Ehlers JP, Han J, Petkovsek D, Kaiser PK, Singh RP, Srivastava SK. Membrane peeling-induced retinal alterations on intraoperative OCT in vitreomacular interface disorders from the PIONEER Study. *Invest Ophthalmol Vis Sci.* 2015;56(12):7324–7330.
17. Yiu G, Young L, Gilmore M, Chodosh J. Prophylaxis against postoperative endophthalmitis in cataract surgery. *Int Ophthalmol Clin.* 2011;51(4):67–83.
18. Lee JY, SJ C, Srinivasan PP, et al. Fully automatic software for retinal thickness in eyes with diabetic macular edema from images acquired by Cirrus and Spectralis systems. *Invest Ophthalmol Vis Sci.* 2013;2013(54):7595–7602.
19. Vuong VS, Moisseiev E, Cunefare D, Farsiu S, Moshiri A, Yiu G. Repeatability of choroidal thickness measurements on enhanced depth imaging optical coherence tomography using different posterior boundaries. *Am J Ophthalmol.* 2016;169:104–112.
20. Wong SS, Vuong VS, Cunefare D, Farsiu S, Moshiri A, Yiu G. Macular fluid reduces reproducibility of choroidal thickness measurements on enhanced depth optical coherence tomography. *Am J Ophthalmol.* 2017;184:108–114.
21. Yiu G, Marra KV, Wagley S, et al. Surgical outcomes after epiretinal membrane peeling combined with cataract surgery. *Br J Ophthalmol.* 2013;97(9):1197–1201.
22. Ehlers JP, Modi YS, Pecan PE, et al. The DISCOVER Study 3-year results: feasibility and usefulness of microscope-integrated intraoperative OCT during ophthalmic surgery. *Ophthalmology.* 2018;125(7):1014–1027.
23. Ray R, Baranano DE, Fortun JA, et al. Intraoperative microscope-mounted spectral domain optical coherence tomography for evaluation of retinal anatomy during macular surgery. *Ophthalmology.* 2011;118:2212–2217.
24. Riazi-Esfahani M, Khademi MR, Mazloumi M, Khodabandeh A, Riazi-Esfahani H. Macular surgery using intraoperative spectral domain optical coherence tomography. *J Ophthalmic Vis Res.* 2015;10(3):309–315.
25. Abraham JR, Srivastava SK, Reese JL, Ehlers JP. Intraoperative OCT features and postoperative ellipsoid mapping in primary macula-involving retinal detachments from the PIONEER Study. *Ophthalmol Retina.* 2019;3(3):252–257.
26. Ehlers JP, Uchida A, Srivastava SK, Hu M. Predictive model for macular hole closure speed: insights from intraoperative optical coherence tomography. *Transl Vis Sci Technol.* 2019;8(1):18.
27. Cekic O, Cakir M, Alagoz N, Yilmaz OF. Retinal thickness change in relation to visual acuity improvement after 23-gauge vitrectomy for idiopathic epimacular membrane. *Eye (London, England).* 2011;25(2):180–184.
28. Leisser C, Hirschschall N, Hackl C, Doller B, Varsits R, Findl O. Diagnostic precision of a microscope-integrated intraoperative OCT device in patients with epiretinal membranes. *Eur J Ophthalmol.* 2018;28(3):329–332.