

# Clinico-Etiological Factors, Neuroimaging Characteristics and Outcome in Pediatric Cerebral Venous Sinus Thrombosis

Leema P. Cornelius, Neeraj Elango, Venkateswaran Kuttava Jeyaram

Department of Paediatric Neurology, Institute of Child Health and Hospital for Children, Madras Medical College, Chennai, Tamil Nadu, India

## Abstract

**Background:** Cerebral venous sinus thrombosis (CVST) is rare in children, increasingly being recognized of late due to advances in neuroimaging. The aim of the study was to describe the clinical, etiological, and imaging characteristics of CVST and its outcome in children. **Study Design:** A retrospective chart review of children with CVST in a tertiary hospital from January 2011 to December 2020. **Results:** Of the 35 patients enrolled, 26 (74.3%) patients were males. The mean age was 5.03 years with a range of 0.17–12 years. The common presenting symptoms were seizures in 18 (51.4%) followed by headache in 17 (48.6%), fever in 16 (45.7%), and vomiting in 15 (42.9%) children. Superior sagittal sinus was the commonest site of thrombus occlusion in 20 (57%), followed by transverse sinus in 18 (51.4%) patients. Multiple sinus involvement was noticed in one-half of the patients. The risk factors associated with CVST were head and neck infections in 15 (42.9%) children, inherited thrombophilia in 4 (11.6%), head trauma, iron deficiency anemia, leukemia with l-asparaginase therapy, acquired thrombophilia in 3 (8.6%) each, dehydration in 2 (5.7%), and dural arteriovenous fistula in one child. Two children (5.7%) died and one-third of the cohort had a poor outcome. **Conclusions:** Head and neck infections continue to be the common cause of CVST in children. Though mortality is low, CVST is associated with significant morbidity in children.

**Keywords:** Cerebral venous sinus thrombosis, children, neuroimaging findings, outcome

## INTRODUCTION

Cerebral venous sinus thrombosis (CVST) is rare in the pediatric age group, with an estimated incidence of 0.67 per 1,00,000 children per year.<sup>[1]</sup> The signs and symptoms of CVST in children are quite nonspecific, and hence diagnosis can be delayed, at times missed altogether.<sup>[2]</sup> CVST may manifest with a wide range of symptoms and signs including headache, vomiting, seizures, lack of consciousness or lethargy, papilledema, and focal neurological deficits. The risk factors associated with childhood CVST are diverse and differ from those observed in adults.<sup>[1]</sup> Local and systemic infections, dehydration, cardiac defects, hematological malignancies, anemia, prothrombotic disorders both genetic and acquired have been described as predisposing factors.<sup>[3]</sup> Though there exists a lot of literature on CVST in adults from our country, there is a significant lack of information in the pediatric age group. To understand the disease better in terms of clinical presentation, risk factors, and outcome in our population, we retrospectively analyzed the clinical data of pediatric cases of CVST admitted to our hospital in the past 10 years. In the present communication, we report the clinical features, neuroimaging findings, etiology, short-term outcome, and predictors of poor outcome of pediatric CVST from a tertiary care center in South India.

## MATERIALS AND METHODS

A retrospective chart review of patients with a diagnosis of CVST aged 1 month to 12 years admitted to our hospital between January 2011 and December 2020 was performed.

Neonates were excluded as neonatal CVST has a different etiology and outcome. The diagnosis of CVST was based on Magnetic Resonance (MR) venography findings with evidence of thrombosis in the cerebral venous sinuses or veins. We collected the following type of data from the medical records—demographic data, presenting symptoms, time from the onset of symptoms to the presentation defined as acute (<2 days), subacute (3 days to 30 days), and chronic (>30 days), clinical signs, neuroimaging findings including the location of parenchymal lesions, location of thrombus, cortical vein involvement, investigations done, treatment given, and outcome at 3 months.

The laboratory investigations included complete blood count, erythrocyte sedimentation rate (ESR), blood urea, sugar, serum creatinine, peripheral smear for sickling, collagen vascular disorder work up including antinuclear antibody (ANA),

**Address for correspondence:** Dr. Leema Pauline,  
Department of Paediatric Neurology, Institute of Child Health and Hospital for  
Children, Egmore, Chennai, Tamil Nadu, India.  
E-mail: leema\_pauline@rediffmail.com

**Submitted:** 15-Mar-2021 **Revised:** 24-Apr-2021 **Accepted:** 11-May-2021

**Published:** 17-Dec-2021

This is an open access journal, and articles are distributed under the terms of the Creative Commons Attribution-NonCommercial-ShareAlike 4.0 License, which allows others to remix, tweak, and build upon the work non-commercially, as long as appropriate credit is given and the new creations are licensed under the identical terms.

**For reprints contact:** WKHLRPMedknow\_reprints@wolterskluwer.com

**DOI:** 10.4103/aian.AIAN\_221\_21

antiphospholipid antibodies, prothrombin time, activated partial thromboplastin time, protein C, protein S, antithrombin III levels, serum homocysteine, serum iron, total iron-binding capacity, and serum ferritin with an aim to detect the underlying etiology.

The outcome was assessed from the follow-up notes in the charts. Follow-up data extracted from the records included—disability (according to modified Rankin Scale [mRS]), death, recurrent symptomatic sinus thrombosis (new symptoms with new thrombus on repeated venogram or Magnetic Resonance Imaging (MRI)), and seizures. Imaging findings in MRI brain and magnetic resonance venography (MRV) repeated at 3 months such as complete or partial recanalization of the involved sinuses, organization of thrombus, resolution of infarct, and gliotic changes were also noted. Outcome was classified as complete recovery (mRS 0–1); partial recovery, independent (mRS 2); dependent (mRS 3–5); and death (mRS 6). The mRS from 0 to 2 was graded as good outcomes and scores above 2 were considered poor outcomes.

### Statistical analysis

Numeric values were shown as mean  $\pm$  standard deviation. Chi-square and/or Fisher's exact test were used to study the association between categorical variables. *P* value  $<0.05$  was considered statistically significant. The analysis was performed using Epi Info™ 7 statistical software (developed by Centers for Disease Control and Prevention [CDC] in Atlanta, GA, US).

## RESULTS

The study included a total of 35 patients with CVST. The mean age at presentation was 5.03 years with a range of 0.17–12 years. There were 26 (74.3%) males and 9 (25.7%) females. Nine (25.7%) were infants, 11 (31.4%) belonged to the 1–5-year age group, and 15 (42.9%) were in more than 5-year age group.

### Clinical presentation

A majority of the patients had a subacute presentation ( $n = 23$ , 65.7%), while 11 (31.4%) had an acute onset. The presenting symptoms were seizures in 18 (51.4%) children followed by headache in 17 (48.6%), fever in 16 (45.7%), vomiting in 15 (42.9%), and altered sensorium in 12 (34.3%). The neurological signs noted were cranial nerve palsies in 9 (25.7%), motor deficits in 8 (22.9%), meningeal signs in 6 (17.1%), papilledema in 5 (14.3%), and bulging anterior fontanel in 4 (11.6%) patients. Neurological examination was normal in four (11.6%) children. The demographic and clinical features are depicted in Table 1.

### Clinical syndromes of CVST

The syndrome of focal neurologic deficit with or without increased intracranial pressure (ICP) was the most common syndrome found in 23 (65.7%) cases, followed by the syndrome of increased ICP in 7 (20%). Four (11.4%) cases were diagnosed as having the syndrome of cavernous sinus thrombosis. One presented with subacute encephalopathy.

**Table 1: Demographic and clinical features of children with CVST**

Parameters	Number of cases ( $n=35$ )
Age	
<1 year	9 (25.7%)
1-5 years	11 (31.4%)
>5 years	15 (42.9%)
Mean age in years	5.03
Range in years	0.17-12
Gender	
Male	26 (74.3%)
Female	9 (25.7%)
Onset	
Acute	11 (31.4%)
Subacute	23 (65.7%)
Chronic	1 (2.9%)
Symptoms and signs	
Seizures	18 (51.4%)
Generalized seizures	13 (37.1%)
Focal seizures	3 (8.6%)
Status epilepticus	2 (5.7%)
Headache	17 (48.6%)
Fever	16 (45.7%)
Vomiting	15 (42.9%)
Altered sensorium	12 (34.3%)
Motor deficit	
Hemiparesis	6 (17.1%)
Paraparesis	1 (2.9%)
Quadriparesis	1 (2.9%)
Cranial nerve palsy	9 (25.7%)
Ataxia	3 (8.6%)
Bulging anterior fontanel	4 (11.6%)
Papilledema	5 (14.3%)
Meningeal signs	6 (17.1%)

### Neuroimaging findings

Computed Tomography (CT) brain was done in 29 (82.9%) patients, and it revealed hemorrhagic infarct in 4 (13.8%), non-hemorrhagic infarct, parenchymal hemorrhage, intraventricular hemorrhage in 3 (10.3%) each, and abscess in 2 (6.9%) patients. CT brain was normal in the remaining 14 (48.3%) patients. Dense triangle sign, hyperdense transverse sinus were visualized in one child each. CT angiography done in a child with intraventricular bleed did not reveal any abnormality. CT venography was not done in any child.

MRI brain including MRV had been done in all the patients. Eighteen (51.4%) patients showed parenchymal lesions. Hemorrhagic infarct was the commonest brain parenchymal lesion observed in nine (25.7%), followed by a bland infarct in six (17.1%), and parenchymal bleed in three (8.6%) children. Intracerebral bleed was isolated in two children, along with hemorrhagic infarct and subarachnoid bleed in one. The anatomical regions involved were cortex of the frontal ( $n = 3$ ), temporal ( $n = 3$ ), parietal ( $n = 9$ ) and occipital ( $n = 1$ ) regions, thalamus ( $n = 1$ ) and cerebellum ( $n = 1$ ). Three (8.6%) children

presented with intraventricular bleed, isolated in one, along with hemorrhagic infarct in one, with subarachnoid bleed and hemorrhagic infarcts in another. Four children (13.8%) developed hydrocephalus during the course of the illness. The underlying conditions which led to hydrocephalus were tuberculous meningitis in two patients, bacterial meningitis in one, and intraventricular hemorrhage in one. Two (5.7%) patients had cerebellar abscess in association with mastoiditis. Subdural effusion was noted in one child with pyogenic meningitis.

### Sinuses involved

Superior sagittal sinus was the most common site of thrombus occlusion seen in 20 (57%) children, followed by transverse sinus in 18 (51.4%), and sigmoid sinuses in 11 (31.4%) [Figures 1 and 2]. Superficial cortical veins were involved in 4 (11.4%) children. Cavernous sinus thrombosis was observed in 4 (11.4%) patients. Three children (8.6%) showed thrombosis within the internal jugular vein. One child (2.9%) showed thrombosis involving both superficial and deep system of veins. Nineteen (54.3%) had involvement of more than one sinus. Both arterial and venous sinus thrombosis were observed in two (5.7%) children. Another two children developed thrombosis in peripheral veins in addition to CVST. The site of thrombus occlusion is detailed in Table 2.

### Risk factors

The various predisposing factors identified in this cohort were head and neck infections in 15 (42.9%), inherited thrombophilia in 4 (11.6%), head trauma, iron deficiency anemia, leukemia with l-asparaginase therapy, acquired thrombophilia in 3 (8.6%) each, dehydration in 2 (5.7%) children, and dural arteriovenous fistula in 1. No risk factor could be identified in one child (2.9%). The acquired prothrombotic conditions that led to CVST were elevated antiphospholipid antibody associated with varicella infection in two (5.7%) and nephrotic syndrome in one [Table 3].

### Treatment given

Thirty patients (85.7%) received low molecular weight heparin overlapped by oral acenocoumarin which was continued for a minimum period of 3 months. Patients with infective etiology received appropriate antibiotics as well. Four children who developed hydrocephalus underwent ventriculoperitoneal shunt surgery. Two patients who had peripheral vein

thrombosis in addition to CVST developed gangrene which required amputation of the affected limb.

### Outcome

Two (5.7%) children died, one of them had tubercular meningitis with Isoniazid resistance who went on to develop hydrocephalus, arterial stroke, and CVST. The other was a case of acute myeloid leukemia with secondaries in multiple organs, meningeal secondaries, and cavernous sinus thrombosis. Two patients lost their follow-up.

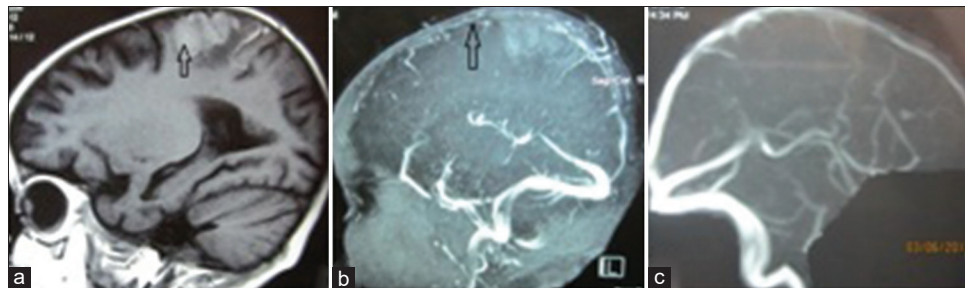
At 90 days of follow-up, 17 (54.8%) patients were normal (mRS: 0–1), 3 (9.7%) became functionally independent (mRS: 2), and 11 (35.5%) remained dependent (mRS: 3–5).

The predictors of poor outcome were age less than 1 year, seizures, altered sensorium, motor deficit, parenchymal lesions in neuroimaging, presence of hydrocephalus, superior sagittal sinus involvement, meningitis as the etiologic factor, and focal syndrome presentation [Table 4].

**Table 2: Neuroimaging findings and sinus involved in CVST**

Parameters	Number of patients (n=35)
Hemorrhagic infarct	9 (25.7%)
Non-hemorrhagic infarct	6 (17.1%)
Intracranial hemorrhage	6 (17.1%)
Hydrocephalus	4 (11.4%)
Abscess	2 (5.7%)
Normal	13 (37.1%)
Midline shift	2 (5.7%)
Sinuses involved	
SSS with/without other sinuses	20 (57.1%)
Right TS with/without other sinuses	13 (37.1%)
Left TS with/without other sinuses	5 (14.3%)
Sigmoid sinuses with/without other sinuses	11 (31.4%)
Isolated SSS	8 (22.9%)
Isolated TS	3 (8.6%)
Isolated sigmoid sinus	1 (2.9%)
Deep venous thrombosis	1 (2.9%)
Cortical vein thrombosis	4 (11.4%)
Cavernous sinus thrombosis	4 (11.4%)

SSS: Superior sagittal sinus. TS: Transverse sinus



**Figure 1:** (a) MRI brain T1W image sagittal view showing hemorrhagic infarct in the right parietal region in a child with pyogenic meningitis. (b) Magnetic resonance venography (MRV) showing thrombosis in the superior sagittal sinus. (c) Partial recanalization after 3 months



Repeat MR imaging showed an area of gliosis in nine (29%), resolution of infarction in 5 (16.1%), and diffuse atrophy in 1 (3.2%). Repeat MR venography showed complete recanalization of sinuses in 16 (51.6%), partial recanalization in 12 (38.7%), and organized thrombus with collaterals in 3 (9.7%). The mean follow-up period was 11 months with a range from 3 months to 8 years. The complications noted include residual motor deficits such as spastic quadriplegia in six (19.4%), hemiparesis in five (16.1%), cognitive disturbances in five (16.1%), and seizure disorder in four (12.9%) children. No recurrence was noted in any child.

## DISCUSSION

Cerebral vein and sinus thrombosis (CVST) is rare in children compared to arterial stroke. We report a cohort of 35 children with CVST over a period of 10 years managed in our institution.

A total of 574 children were diagnosed and treated as stroke during this period, out of which 289 (50.3%) were arterial

ischemic strokes, 250 (43.6%) were hemorrhagic strokes, and 35 (6.1%) were due to CVST. It constituted 10.8% (35 out of 324) of ischemic strokes in our institution. Kalita *et al.*<sup>[4]</sup> have quoted a similar proportion, 7 children with CVST out of 69 ischemic strokes (10.1%) in their study on pediatric stroke from North India.

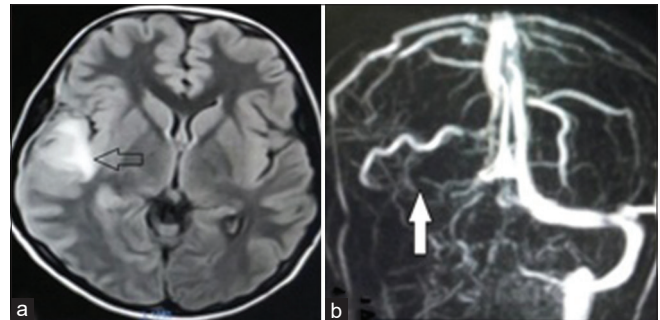
Males (74%) predominated the study, concordant with previous reports.<sup>[1,5,6]</sup> A majority of reported literature speaks about the delay and difficulty in the diagnosis of CVST in children as the symptoms and signs are highly nonspecific.<sup>[2]</sup> Our study reiterates the same as two-thirds of our children with CVST had a subacute presentation. This could be explained by the fact that the growth of thrombus is usually slow, and venous collateralization is extensive. The symptoms typically evolve over days or weeks, though the onset may be acute. Lack of awareness about CVST among primary care physicians is another factor to be considered.<sup>[7,8]</sup>

The clinical manifestations of CVST are nonspecific—may be subtle and may overlap with predisposing conditions such as infection and dehydration. Seizures, altered levels of consciousness, focal neurologic deficits (cranial nerve palsies, hemiparesis, hemisensory loss), and diffuse neurologic symptoms (headache, nausea, emesis) may result. While most of the symptoms can occur at any age, seizures are more common in neonates and focal and diffuse neurologic signs

**Table 3: Risk factors associated with CVST**

Risk factors	Number of patients (n=35)
Head and neck infections	15 (42.9%)
Mastoiditis	5 (14.3%)
Bacterial meningitis	4 (11.6%)
Tuberculous meningitis	2 (5.7%)
Orbital cellulitis	3 (8.6%)
Nephrotic syndrome with bacterial meningitis	1 (2.9%)
Head trauma	3 (8.6%)
Protein C deficiency	2 (5.7%)
Protein S deficiency	2 (5.7%)
Iron deficiency anemia	3 (8.6%)
Malignancy (leukemia)	3 (8.6%)
Dehydration	2 (5.7%)
Varicella infection with elevated APLA	2 (5.7%)
Nephrotic syndrome	1 (2.9%)
Dural AV fistula	1 (2.9%)
Idiopathic	1 (2.9%)

APLA; Antiphospholipid antibody. AV: Arterio venous



**Figure 2:** (a) MRI brain Fluid Attenuated Inversion Recovery Sequence (FLAIR) sequence axial view showing hemorrhagic infarct in the right temporoparietal region in a child with primary varicella infection. (b) MRV showing thrombosis in the right transverse, sigmoid sinuses, and internal jugular vein

**Table 4: Differences between good and poor outcomes with risk factors at follow-up**

Parameter	Good outcome (n=20)	Poor outcome (n=13)	P
Infants	2 (10%)	7 (53.9%)	0.009
Seizures	6 (30%)	11 (84.6%)	0.003
Altered sensorium	3 (15%)	8 (61.5%)	0.008
Motor deficit	2 (10%)	6 (46.2%)	0.03
Parenchymal lesions in imaging	9 (45%)	12 (92.3%)	0.007
Intracranial hemorrhage	1 (5%)	5 (38.5%)	0.02
Hydrocephalus	0	4 (30.8%)	0.02
SSS involvement	7 (35%)	12 (92.3%)	0.001
Meningitis	1 (5%)	6 (46.2%)	0.008
Focal syndrome presentation	10 (50%)	12 (92.3%)	0.01
Multiple sinuses involvement	13 (65%)	6 (46.2%)	0.24
Partial/non-recanalization	8 (40%)	7 (53.9%)	0.34

are more common in older infants and children.<sup>[1]</sup> We found seizures and headache were the common presenting symptoms noticed in 51 and 49% of our children, respectively. Similar observations had been made by Heller *et al.*<sup>[9]</sup> Baddouh *et al.*,<sup>[10]</sup> and Fernandez *et al.*<sup>[11]</sup> while others have described a higher incidence of headache and a lower incidence of seizures in their studies.<sup>[12,13]</sup> Higher incidence of seizures in our study can be explained by the parenchymal involvement in the majority and one fourth of our cohort were infants who have a higher seizure risk among children.

Adult studies often quote the syndromic approach to CVST, which is not commonly described in pediatric studies. The syndrome of the focal neurologic deficit with or without increased ICP was the most common syndrome found in two-thirds of the patients in our study. Similar results have been reported by Mishra *et al.*<sup>[8]</sup> and another study in adults.<sup>[14]</sup>

Neuroimaging is the principal basis for the diagnosis of CVST. Non-contrast CT scans may detect venous thrombosis as linear densities in the sinuses and cortical veins—the dense triangle sign (high attenuation in the superior sagittal sinus in a triangle shape) or the cord sign (high attenuation due to thrombus in the cortical vein). As the thrombus becomes less dense, contrast may demonstrate the empty delta sign, a filling defect in the posterior part of the superior sagittal sinus. CT can also detect ischemia (typically not respecting arterial boundaries, often with some hemorrhagic transformation), parenchymal or subarachnoid hemorrhages, or signs of cerebral edema. However, CT brain may be normal and miss the diagnosis of CVST in up to 30–40% of the patients.<sup>[15,16]</sup> Most children (83%) of our cohort underwent an initial CT brain, which was normal in nearly half of them (48%). Similar views have been echoed by Wang *et al.*<sup>[12]</sup> confirming that it is difficult to rule out CVST with CT brain alone.

All the children in our cohort underwent MRI brain with MRV which is the gold standard for diagnosing CVST.<sup>[16]</sup> Focal parenchymal changes were noted in one-half of the patients, and hemorrhagic infarct was the commonest brain parenchymal lesion observed in one-fourth, which is in accordance with previous studies.<sup>[7,17]</sup>

Isolated intracranial hemorrhage was noticed in three children, intraparenchymal in two, and intraventricular in one. Intracerebral hemorrhage may be due to increased venous pressure resulting in diapedesis of red blood corpuscles (RBC) and subsequent rupture of small vessels. The rapidity of venous thrombosis and lack of fibrinolysis may contribute to the occurrence of intracerebral hemorrhage as well.<sup>[18]</sup>

Three children presented with intraventricular hemorrhage, isolated in one, associated with hemorrhagic infarct, and subarachnoid hemorrhage (SAH) in the other two. All three had the involvement of multiple sinuses in the superficial system namely superior sagittal, transverse, and sigmoid sinuses. Two of them were near neonates aged between 45 and 60 days of life. CSVT is a recognized cause of symptomatic

intraventricular hemorrhage in neonates due to the deficiency of the protective mechanisms because of immaturity.<sup>[19]</sup> The other one was a 4-year-old female child with isolated intraventricular hemorrhage (IVH) for whom coagulation profile was normal, CT angiography and MR angiography were normal, and MRV picked up thrombosis of venous sinuses. Deep venous thrombosis can be accompanied by hemorrhage into the ventricles as a result of blockage and hypertension in the deep venous system.<sup>[20]</sup> But our patient showed involvement of superficial venous system. We presume that poor drainage can result in increased pressure in the veins of the ventricular surface, causing the rupture of the small blood vessels leading to IVH.<sup>[21]</sup>

Two children had a subarachnoid hemorrhage in addition to other findings. The exact mechanism of cortical CVST-induced SAH is unknown. The possible explanations include rupture of venous parenchymal hemorrhagic infarcts into the subarachnoid space and rupture of dilated thin-walled bridging subarachnoid cortical veins due to venous hypertension.<sup>[22]</sup>

The literature is divided among the commonest sinus involvement in pediatric CVST, some reporting transverse sinus<sup>[8,23,24]</sup> and others quoting superior sagittal sinus as the commonest sinus involved. Wang *et al.*<sup>[12]</sup> have reported 18 out of 30 children (60%) with CVST had superior sagittal sinus involvement. Huisman *et al.*<sup>[25]</sup> found superficial sagittal sinus involvement in 47.5% of their cases. We found superior sagittal sinus is the most common site of thrombus occlusion (57%) in our study. The involvement of sinuses might be different according to different geographic regions. Wasay *et al.*<sup>[7]</sup> have reported that multiple sinuses were involved in more than 70% of their patients. Nearly 60% of our cohort had involvement of multiple sinuses which is in accordance with the earlier studies as well.<sup>[9,10]</sup> Concurrent involvement of arterial and venous sinus thrombosis was observed in two children which has not been reported so far in literature—underlying etiology being drug-resistant tuberculous meningitis in one, and iron deficiency anemia in the other. Various theories put forward to explain the association between iron deficiency and thrombosis include reactive thrombocytosis, hypercoagulable state due to microcytosis, and anemic hypoxia during periods of stress.<sup>[26]</sup>

The causes of CVST are diverse in children. Acute infections of the head and neck are the most common cause followed by chronic underlying diseases like nephrotic syndrome, cancer, and inflammatory bowel disease.<sup>[3]</sup> We also found that head and neck infection (43%) was the commonest underlying cause of CVST with mastoiditis, pyogenic meningitis in 14% each, orbital cellulitis in 9%, and tubercular meningitis in 6%. Similar observations have been made by other authors (Wasay *et al.*<sup>[7]</sup> 28/70 [40%], Heller *et al.*<sup>[9]</sup> 54/149 [36%], and Vieira *et al.*<sup>[24]</sup> 30/56 [56.6%]) as well. Prothrombotic conditions accounted for 11% of the risk factors in our study which included protein C deficiency and protein S deficiency in two children each. Similar findings were reported by Karakas *et al.*<sup>[27]</sup> in their cohort of 148 patients. Risk factors could not be identified in one of our patients. Similar results have been

reported by a few authors.<sup>[1,2]</sup> However, a higher proportion of idiopathic cases have been reported by Mishra *et al.*<sup>[8]</sup> and Wang *et al.*<sup>[12]</sup> An extensive search for prothrombotic factors in patients without an underlying disease may be the reason for the lower incidence of idiopathic cases in our study. More than 80% of the patients in our cohort received anticoagulation which is in accordance with reported literature.<sup>[12,23,27]</sup>

CSVT-specific mortality is less than 10%, but motor and cognitive deficits may be present in 17–79% of the survivors who require long-term rehabilitation.<sup>[1,2,28]</sup> Two of our children died, one with drug-resistant tubercular meningitis with complications and the other with acute myeloid leukemia with secondaries. We feel that they succumbed to the underlying disease and its complications rather than by CVST. Fernandez *et al.*<sup>[11]</sup> and Bonduel *et al.*<sup>[29]</sup> had expressed similar views in their studies.

Nearly two-thirds had a complete recovery which is in accordance with the other studies.<sup>[7,15,24]</sup> The factors associated with poor prognosis included age less than 1 year ( $P = 0.009$ ), seizures at the onset ( $P = 0.003$ ), decreased level of consciousness ( $P = 0.008$ ), parenchymal lesions in neuroimaging ( $P = 0.007$ ), superior sagittal sinus involvement ( $P = 0.001$ ), and presentation as a focal syndrome ( $P = 0.01$ ). Though factors such as the presence of motor deficit, hydrocephalus, intracranial hemorrhage, meningitis as risk factor were associated with poor outcomes, they could not be considered significant because of the small numbers. Fernandez *et al.*<sup>[11]</sup> reported that the presence of infarcts, hydrocephalus, and seizures at onset predicted a worse neurologic outcome. Similar findings have been noted by others as well.<sup>[1,2]</sup> Involvement of straight sinus, multiple sinuses were found to be associated with a higher risk of sequelae by different authors.<sup>[23,24]</sup> However, we found no such correlation. On the contrary, we found that superior sagittal sinus thrombosis was significantly correlated with a poor outcome which is in accordance with the study by Vieira *et al.*<sup>[24]</sup> The same author had expressed that the prognosis was dependent significantly in some cases on the etiologic factor for thrombosis. In four of their patients, the sequelae were more likely due to bacterial meningitis, and in another, the residual neurologic deficits were of multifactorial origin. We also had a similar experience with six of our patients (four with bacterial meningitis and two with tuberculous meningitis).

Partial recanalization of the thrombosed sinuses was seen in nearly 40% and non-recanalization in about 10% at the end of 3 months which is in confirmation with the other studies.<sup>[9,30]</sup> Vieira *et al.* had reported that recanalization is not a significant factor for long-term outcomes.<sup>[24]</sup> We also found no correlation between recanalization and prognosis.

### Limitations

Genetic tests identifying Factor V Leiden mutation and prothrombin gene mutation were not done due to non-availability in our institution. Hence, we are unable to comment upon their role as risk factors in our study.

## CONCLUSIONS

There should be a high index of suspicion to diagnose CVST especially in patients with an underlying risk factor for venous sinus thrombosis because of its comparative rarity. As the symptoms are highly nonspecific, there should be a lower threshold to perform neuroimaging for early diagnosis. Intracranial hemorrhage may be a rare presentation of CVST and this possibility should be considered in an appropriate clinical setting. Though mortality is low, CVST is associated with high morbidity in children. Age less than 1 year, seizures, altered sensorium, parenchymal lesions in neuroimaging, superior sagittal sinus involvement, and presentation as focal syndrome were the predictors of adverse outcome.

### Financial support and sponsorship

Nil.

### Conflicts of interest

There are no conflicts of interest.

## REFERENCES

- de Veber G, Andrew M, Adams C, Bjornson B, Booth F, Buckley DJ, *et al.* Cerebral sinovenous thrombosis in children. *N Engl J Med* 2001;345:417-23.
- Sébire G, Tabarki B, Saunders DE, Leroy I, Liesner R, Saint-Martin C, *et al.* Cerebral venous sinus thrombosis in children: Risk factors, presentation, diagnosis and outcome. *Brain* 2005;128:477-89.
- Hashmi M, Wasay M. Caring for cerebral venous sinus thrombosis in children. *J Emerg Trauma Shock* 2011;4:389-94.
- Kalita J, Goyal G, Misra UK. Experience of pediatric stroke from a tertiary medical center in North India. *J Neurol Sci* 2013;325:67-73.
- Holzhauser S, Heller C, Ralf K, Karim K, Anne K, Karin K. Cerebral venous thrombosis in neonates, children and adolescents; Results from the German pediatric surveillance unit for rare pediatric diseases (ESPED). *Blood* 2016;128:420.
- Bektaş Ö, Teber S, Akar N, Uysal LZ, Arsan S, Atasay B, *et al.* Cerebral sinovenous thrombosis in children and neonates: Clinical experience, laboratory, treatment, and outcome. *Clin Appl Thromb Hemost* 2015;21:777-82.
- Wasay M, Dai AI, Ansari M, Shaikh Z, Roach ES. Cerebral venous sinus thrombosis in children: A multicenter cohort from the United States. *J Child Neurol* 2008;23:26-31.
- Mishra S, Mallick AK, Mohanty G, Nayak P. Cerebral venous sinus thrombosis in children: A study from a tertiary care hospital of Eastern India. *J Pediatr Neurosci* 2020;15:370-4.
- Heller C, Heinecke A, Junker R, Knofler R, Kosch A, Kurnik K, *et al.* Childhood stroke study group. Cerebral venous thrombosis in children: A multifactorial origin. *Circulation* 2003;108:1362-7.
- Baddouh N, Elbakri S, Draiss G, Mouaffak Y, Rada N, Younous S, *et al.* [Cerebral venous thrombosis in children: About a series of 12 cases]. *Pan Afr Med J* 2019;32:22.
- Fernandez JME, Garcia-Carpintero AS, Delgado I, Conangla MP, Carballés MG, Vives MAR. Cerebral sinovenous thrombosis in paediatric age. DOI 10.26044/ecr2019/C-1382. Available from: <https://dx.doi.org/10.26044/ecr2019/C-1382>. [Last accessed on 2021 Aug 03].
- Wang ZH, Zhang LM, Chai YM, Wang J, Yu LF, Zhou SZ. Clinical characteristics and outcomes of pediatric cerebral venous sinus thrombosis: An analysis of 30 cases in China. *Front Pediatr* 2019;7:364.
- Ünver O, Ekinci G, Kutlubay BI, Gülten T, Güneş S, Hacifazlıoğlu NE, *et al.* Evaluation of cases with cerebral thrombosis in children. *Turk Pediatri Ars* 2016;51:87-93.
- Nagaraja D, Wassy M, Christopher M, Santosh V. Cerebral venous sinus thrombosis. In: Chopra JS, Sawhney IMS, editors. *Neurology in Tropics*. 2<sup>nd</sup> ed. Chennai, India: Elsevier; 2016. p. 669-79.

15. de Veber G, Andrew M. The Canadian pediatric ischemic stroke study group. The epidemiology and outcome of sinovenous thrombosis in pediatric patients. *N Engl J Med* 2001;345:417-23.
16. Bousser MG, Ferro JM. Cerebral venous thrombosis: An update. *Lancet Neurol* 2007;6:162-70.
17. Tsai FY, Wang AM, Matovich VB, Lavin M, Berberian B, Simonson TM, *et al.* MR staging of acute dural sinus thrombosis: Correlation with venous pressure measurements and implications for treatment and prognosis. *AJNR Am J Neuroradiol* 1995;16:1021-9.
18. Villringer A, Mehraein S, Einhupl KM. Pathophysiological aspects of cerebral sinus venous thrombosis. *J Neuroradiol* 1994;21:72-80.
19. Wu YW, Hamrick SE, Miller SP. Intraventricular hemorrhage in term neonates caused by sinovenous thrombosis. *Ann Neurol* 2003;54:123-6.
20. Dlamini N, Billingham L, Kirkham FJ. Cerebral venous sinus (Sinovenous) thrombosis in children. *Neurosurg Clin N Am* 2010;21:511-27.
21. Zhang H, Song S, Ouyang Z. Intraventricular hemorrhage caused by intracranial venous sinus thrombosis. *Medicine (Baltimore)* 2016;95:e3907.
22. Kato Y, Takeda H, Furuya D, Nagoya H, Deguchi I, Fukuoka T, *et al.* Subarachnoid hemorrhage as the initial presentation of cerebral venous thrombosis. *Intern Med* 2010;49:467-70.
23. Javed I, Sultan T, Rehman ZU, Yaseen MR. Clinical spectrum and outcome of cerebral venous sinus thrombosis in children. *J Coll Physicians Surg Pak* 2018;28:390-3.
24. Vieira JP, Luis C, Monteiro JP, Temudo T, Campos MM, Quintas S, *et al.* Cerebral sinovenous thrombosis in children: Clinical presentation and extension, localization and recanalization of thrombosis. *Eur J Paediatr Neurol* 2010;14:80-5.
25. Huisman TA, Holzmann D, Martin E, Willi UV. Cerebral venous thrombosis in childhood. *Eur Radiol* 2001;11:1760-5.
26. Hartfield DS, Lowry NJ, Keene DL, Yager JY. Iron deficiency: A cause of stroke in infants and children. *Pediatr Neurol* 1997;16:50-3.
27. Karakas C, Takacs D, Edmondson E, Fisher K, Shukla N, Clark G, *et al.* Clinical Presentation, Neuroimaging Characteristics and Long-term Outcome in Pediatric Cerebral Venous Sinus Thrombosis: A Retrospective Study. *Neurology*.2019; 92 (15 Supplement) P2.3-052.
28. Ichord RN, Benedict SL, Chan AK, Kirkham FJ, Nowak-Gottl U. Paediatric cerebral sinovenous thrombosis: Findings of the International paediatric stroke study. *Arch Dis Child* 2014;100:174-9.
29. Bonduel M, Sciuccati G, Hepner M, Pieroni G, Torres AF, Frontrouth JP, *et al.* Arterial ischemic stroke and cerebral venous thrombosis in children: A 12-year Argentinean registry. *Acta Haematol* 2006;115:180-5.
30. Kenet G, Kirkham F, Niederstadt T, Heinecke A, Saunders D, Stoll M, *et al.* Risk factors for recurrent venous thromboembolism in the European collaborative paediatric database on cerebral venous thrombosis: A multicentre cohort study. *Lancet Neurol* 2007;6:595-603.