

Successful sequential drug eluting balloon angioplasty to chronic total occluded popliteal artery in a patient with thromboangitis obliterans by PCR

Fehmi Kaçmaz, Adnan Kaya¹, Aysel Yazıcı²
 Department of Cardiology, OSM Ortadoğu Hospital, Şanlıurfa-Turkey
¹Department of Cardiology, Suruç State Hospital, Şanlıurfa-Turkey
²Department of Cardiology, Liv Hospital, Ankara-Turkey

Introduction

Thromboangitis obliterans (TAO), also known as Buerger's disease (BD), is a non-atherosclerotic, segmental, inflammatory, episodic, non-destructive, thrombotic, and occlusive disease of unknown origin compromising small to medium-sized distal arteries, veins, and nerves (1). Intravenous iloprost (2), intermittent pneumatic compression (3), bosentan (4), and cilostazol (5) are used or experimental medical therapies for TAO, for all that smoking cessation is the sole definitive therapy.

Surgical revascularization is usually not preferred because of high involvement of distal segments of vessels. Endovascular revascularization could be an option for patients with bad distal vasculature.

Case Report

A 42-year-old man diagnosed with Buerger's disease 10 years ago was presented to our clinic with right foot rest pain and ulceration of right toe. His second and third right foot digits have already been amputated because of subsequent ulceration, infection, and necrosis. He had pale, cold legs with ulceration of right toe. Periphery pulses of both legs were absent. He was a heavy cigarette smoker using 2 packs a year for 30 years. Color Doppler ultrasound showed occlusion of both popliteal arteries. Diagnostic angiography revealed occlusion of both popliteal arteries. There were typical "corkscrew" collaterals around knees at the level of occlusions (Fig. 1a–c, Video 1).

Percutaneous transluminal angioplasty was planned and a 6F vascular sheath (Medtronic Corp, Minneapolis, MN) was inserted to right femoral artery via antegrade femoral puncture and 10000 IU unfractionated heparin was administered and added according to the result of activated clotting time during procedure. The occluded part of the popliteal artery was successfully passed with 0.014 guidewire (Abbott Laboratories, Abbott Park, Illinois) via the support catheter (Quick-Cross, The Spectranetics Corporation Colorado Springs) (Fig. 1d) demonstrated by micro-injection via support catheter (Video 2). The first angioplasty was performed with 2.5x80 mm balloon (Medtronic Corp, Minneapolis, MN) to the popliteal artery

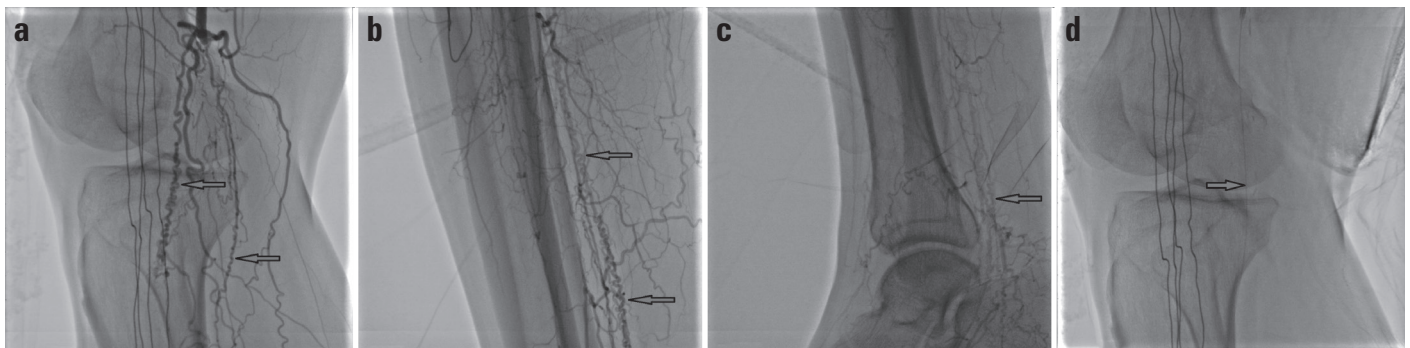


Figure 1. (a–d) Baseline periphery angiography shows typical corkscrew (arrows) collateral arteries of right lower extremity. There is no visible trace of popliteal artery in a; anterior tibial artery, posterior tibial artery, and peroneal artery in b; and foot arteries in (c, d) shows the 0.014 guidewire that passed through the popliteal artery

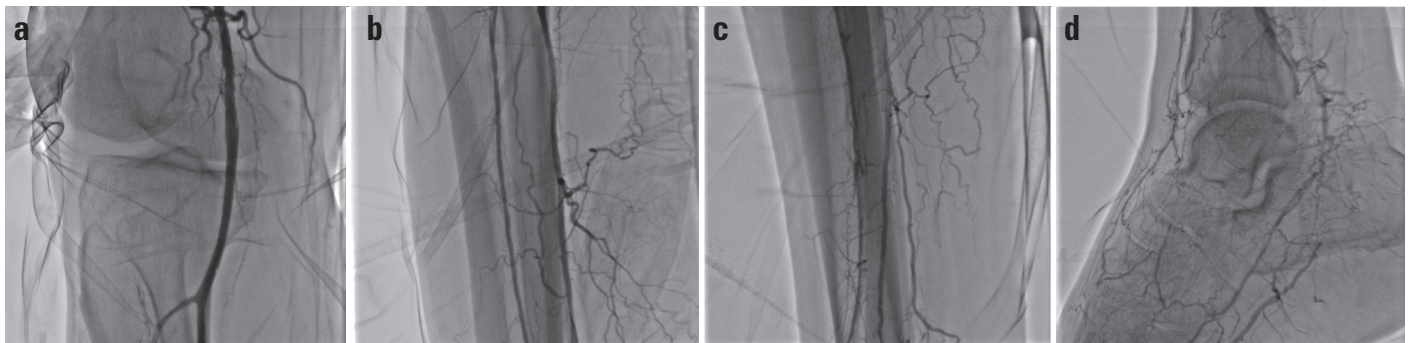


Figure 2. (a–d) Direct blood flow of popliteal artery (a), anterior tibial artery and posterior tibial arteries (b, c), and foot arteries (d) was restored after angioplasty

(Video 3). The sequential drug coated balloon angioplasties were then performed on the posterior tibial artery (Video 4), anterior tibial artery (Video 5), and dorsalis pedis artery (Video 6). Final angioplasty was performed to popliteal artery with 4.0x100 mm balloon (Video 7) and complete blood flow of the foot was restored (Fig. 2a–d, Video 8–10). The pain resolved and the patient was mobile the following morning. The ulcer healed within the following three weeks. The patient was recommended to quit smoking cigarette. A daily dose of 100 mg acetylsalicylic acid and 75 mg clopidogrel was recommended for the following 12 months although there is no consensus regarding treatment duration. The fifth month visit was uneventful with an increased capacity of ambulation.

Discussion

Endovascular revascularization gained preference over surgical revascularization in treatment of lower extremity occlusive disease. Besides improvement in success rate of endovascular revascularization, it preserves the surgical option in case of failure. An endovascular specialist and a vascular surgeon could determine the most appropriate revascularization strategy for patients in close cooperation according to anatomical suitability, comorbidities, local availability, expertise, and the patient's preference (6).

Successful endovascular revascularization of patient with TAO was first described by Lang EV et al. (7) in a 47 year-old male with a left cold blue hand in 1989. After this first step of angioplasty in patients with TAO, there have been several successful cases reported in literature. In 2012, Grazini et al. (8) showed an incredible technical success rate in a case series of 17 patients with TAO with 20 critical limb ischemia lesions. In total, 47 vessels were treated, of which 36 were below-the-knee foot arteries. No complications were reported during the interventions. No mortality or morbidity was recorded during a mean follow-up period of 23 months. In addition, a study aimed angioplasty over the knee arteries; in the study, Yuan et al. (9). showed the efficacy and safety of angioplasty over 9 patients with TAO. In total, 13 lesions were treated, and there were no complications. Angioplasty was performed in all patients with a technical success rate of 100%. No need for amputation was observed in a mean follow-up period of 20.9 months.

In our case the patient did not have appropriate distal vasculature and there were no surgical intervention chance. Sequential and extended balloon angioplasty is performed to obtain a through blood flow in this case. Another aspect of our report is about the technique. Subintimal angioplasty, a previously described technique by Kawarada et al. (10) in a femorotibial occlusion of a patient with TAO, is successfully applied in this patient.

Conclusion

Extended angioplasty could be a beneficial revascularization option in patients with TAO.

Video 1. Total occlusion of popliteal artery with typical “corkscrew” collaterals around knees at the level of occlusion.

Video 2. The occluded part of the popliteal artery was successfully passed with 0.014 guidewire via the support catheter demonstrated by microinjection via support catheter.

Video 3. Balloon dilatation with 2.5x80 mm.

Video 4. Drug coated balloon angioplasty of posterior tibial artery.

Video 5. Drug coated balloon angioplasty of anterior tibial artery.

Video 6. Drug coated balloon angioplasty of pedal artery.

Video 7. Final angioplasty was performed to popliteal artery with 4.0x100 mm balloon

Video 8–10. Restored blood flow of popliteal, anterior tibial, posterior tibial and pedal artery.

References

1. Fazeli B, Rezaee SA. A review on thromboangiitis obliterans pathophysiology: thrombosis and anxieties, which is to blame? *Vascular* 2011; 19: 141-53.
2. Fiessinger JN, Schäfer M. Trial of iloprost versus aspirin treatment for critical limb ischaemia of thromboangiitis obliterans. *The TAO Study. Lancet* 1990; 335: 555-7.
3. Labropoulos N, Watson WC, Mansour MA, Kang SS, Littooy FN, Baker WH. Acute effects of intermittent pneumatic compression on popliteal artery blood flow. *Arch Surg* 1998; 133: 1072-5.
4. De Haro J, Acin F, Bleda S, Varela C, Esparza L. Treatment of thromboangiitis obliterans (Buerger's disease) with bosentan. *BMC Cardiovasc Disord* 2012; 12:5.
5. Reilly MP, Mohler ER 3rd. Cilostazol: treatment of intermittent claudication. *Ann Pharmacother* 2001; 35: 48-56.
6. European Stroke Organisation, Tenders M, Aboyans V, Bartelink ML, Baumgartner I, Clément D, et al. ESC Guidelines on the diagnosis and treatment of peripheral artery diseases: Document covering atherosclerotic disease of extracranial carotid and vertebral, mesenteric, renal, upper and lower extremity arteries: the Task Force on the Diagnosis and Treatment of Peripheral Artery Diseases of the European Society of Cardiology (ESC). *Eur Heart J* 2011; 32: 2851-906.
7. Lang EV, Bookstein JJ. Accelerated thrombolysis and angioplasty for hand ischemia in Buerger's disease. *Cardiovasc Intervent Radiol* 1989; 12: 95-7.
8. Graziani L, Morelli L, Parini F, Franceschini L, Spano P, Calza S, et al. Clinical outcome after extended endovascular recanalization in Buerger's disease in 20 consecutive cases. *Ann Vasc Surg* 2012; 26: 387-95.
9. Yuan L, Bao J, Zhao Z, Lu Q, Feng X, Jing Z. Clinical results of percutaneous transluminal angioplasty for thromboangiitis obliterans in arteries above the knee. *Atherosclerosis* 2014; 235: 110-5.
10. Kawarada O, Ayabe S, Yotsukura H, Nakaya T, Kanayama J, Harada K. Subintimal angioplasty of lengthy femorotibial total occlusion in Buerger's disease. *J Endovasc Ther* 2013; 20: 578-81.

Address for Correspondence: Dr. Fehmi Kaçmaz

Ortadoğu Sağlık Merkezi, Şanlıurfa-Türkiye

E-mail: kacmazfehmi@superonline.com

©Copyright 2016 by Turkish Society of Cardiology - Available online at www.anatoljcardiol.com

DOI:10.14744/AnatolJCardiol.2016.6979

