

Arthroscopic Modified Bosworth Procedure for Refractory Lateral Elbow Pain With Radiocapitellar Joint Snapping

In-Ho Jeon,* MD, PhD, Jae-Man Kwak,* MD, Bin Zhu,[†] MD, Yucheng Sun,[‡] MD, PhD, Hyojune Kim,* MD, Kyoung-Hwan Koh,* MD, PhD, and Erica Kholinne,*^{§||} MD, PhD

Investigation performed at Asan Medical Center, Seoul, Republic of Korea

Background: Radiocapitellar joint snapping due to the presence of synovial plica has been described as a contributory intra-articular pathology of lateral epicondylitis (LE).

Hypothesis: The arthroscopic modified Bosworth technique can provide a safe and favorable outcome for refractory LE with radiocapitellar snapping.

Study Design: Case series; Level of evidence, 4.

Methods: Patients treated with the arthroscopic modified Bosworth procedure for refractory LE with radiocapitellar joint snapping were included in this study. The sequential surgical procedures included excision of the upper portion of the anterolateral annular ligament, removal of the synovial plicae, and release of the extensor carpi radialis brevis for all patients. Clinical outcomes were measured at a minimum 1-year follow-up.

Results: A total of 22 patients with a mean \pm SD age of 51.2 ± 10.4 years were included in this study. The mean follow-up was 29.4 ± 7.7 months (range, 21-42 months). The overall visual analog scale score (from preoperative to final follow-up) was 7.5 ± 1.2 vs 2.5 ± 1.8 ($P < .001$); flexion-extension motion arc was $133.8^\circ \pm 11.2^\circ$ vs $146.4^\circ \pm 7.1^\circ$ ($P = .001$); pronation-supination motion arc was $101.8^\circ \pm 9.2^\circ$ vs $141.7^\circ \pm 10.2^\circ$ ($P = .001$); Disabilities of the Arm, Shoulder and Hand score was 54.5 ± 13.2 vs 3.6 ± 4.1 ($P < .001$); and Mayo Elbow Performance Score was 51.9 ± 12.2 vs 84.3 ± 10.3 ($P < .001$).

Conclusion: Radiocapitellar joint snapping may coexist with LE as a disease spectrum. The arthroscopic modified Bosworth technique provides safe and favorable outcomes for patients with refractory LE associated with radiocapitellar joint snapping.

Keywords: lateral epicondylitis; refractory; snapping radiocapitellar; elbow; arthroscopy

Lateral epicondylitis (LE) affects the origin of the extensor carpi radialis brevis (ECRB) and is thought to be related to repetitive injuries that lead to microtrauma and nonhealing of immature reparative tissue.³¹ Regardless of the exact cause of this disorder, the symptoms of LE generally will resolve or improve within a year.⁹ Nonoperative treatment remains the first-line approach to this condition; however, 25% of the patients remain symptomatic.¹¹ A previous study reported that severe forms of tendinopathy may not benefit from nonoperative measures.⁸ Several surgical procedure types have been described to treat refractory symptoms. More than half a century ago, Bosworth¹⁰ reported a successful approach to the treatment of refractory LE and described the importance of resection of the annular ligament, which he identified as the focal abnormality in refractory LE. Traditional surgical measures involve resection of pathologic degenerative tissue through an open

incision and the release, repair, and denervation of the common extensor origin.^{6,7,10,31} More recently, arthroscopic surgery, as a minimally invasive technique, has gained popularity. The clinical outcomes of arthroscopic surgery in the treatment of LE have been shown to be comparable with those achieved via the open technique.^{4,26,34} Approximately 18% to 58% of LE cases are associated with other intra-articular abnormalities. Arthroscopic intervention is able to address intra-articular pathologies; nevertheless, some patients remain symptomatic after surgery, which is probably due to inadequate treatment of the intra-articular pathologies.^{4,18,27,39}

Radiocapitellar joint snapping may be misdiagnosed as LE because of the similar location as the source of the symptoms.¹ Radiocapitellar joint snapping due to the presence of synovial plicae has been described as a contributory intra-articular pathology in LE.^{5,14,15,30} Nevertheless, little is known about the treatment of LE associated with radiocapitellar joint snapping. The purpose of this study was to assess the clinical outcome of an arthroscopic modified Bosworth technique as a treatment for refractory LE with

The Orthopaedic Journal of Sports Medicine, 8(6), 2325967120929929

DOI: 10.1177/2325967120929929

© The Author(s) 2020

This open-access article is published and distributed under the Creative Commons Attribution - NonCommercial - No Derivatives License (<https://creativecommons.org/licenses/by-nc-nd/4.0/>), which permits the noncommercial use, distribution, and reproduction of the article in any medium, provided the original author and source are credited. You may not alter, transform, or build upon this article without the permission of the Author(s). For article reuse guidelines, please visit SAGE's website at <http://www.sagepub.com/journals-permissions>.

TABLE 1
Study Criteria for Diagnosis, Inclusion, and Exclusion^a

Diagnostic Criteria	Inclusion Criteria	Exclusion Criteria
Lateral epicondylitis ^{21,39}	(1) Patient fulfilled the diagnostic criteria for lateral epicondylitis and radiocapitellar snapping	(1) Less than 1 year of follow-up (n = 17)
(1) Tenderness on deep palpation of the lateral epicondyle over the extensor origin	(2) Patient underwent nonoperative measures that included rest, activity modification, counterforce bracing, nonsteroidal anti-inflammatory medication, and steroid injections	(2) Previous surgery of the affected elbow (n = 8)
(2) Aggravated pain during resisted wrist extension in elbow extension	(3) Patient was without improvement after nonoperative treatment for at least 6 months	(3) History of infection of the affected elbow (n = 3)
Radiocapitellar snapping ^{1,28}	(4) Patient was available for follow-up at a minimum of 1 year	(4) History of musculoskeletal trauma of the affected elbow (n = 8)
(1) Tenderness on the lateral side of the elbow joint over the radiocapitellar joint		(5) Receiving workers' compensation (n = 12)
(2) Presence of painful lateral elbow joint snapping, observed and felt with palpation during elbow movement ¹		(6) Deceased (n = 5)
		(7) Refused MRI (n = 6)
		(8) Refused study consent (n = 3)
		(9) Developed cervical pathologies (n = 4)
		(10) Developed Parkinson disease (n = 1)

^aMRI, magnetic resonance imaging.

radiocapitellar joint snapping. Our hypothesis was that the arthroscopic modified Bosworth technique could provide a safe and favorable outcome for this condition.

METHODS

Institutional board review approval was obtained for this study. The study began with 89 patients who underwent arthroscopic surgery for refractory LE by 1 surgeon (I.-H.J.) between 2012 and 2016 in a tertiary university hospital. The inclusion and exclusion criteria are described in Table 1.

Elbow joint instability was routinely assessed (via the varus instability test and lateral pivot-shift test) in the outpatient clinic before the surgical procedure. If the outpatient clinic test finding was inconclusive, assessment was repeated in the operating room with the patient under general anesthesia. All patients underwent standard

anterior-posterior and lateral radiographs and contrast-enhanced magnetic resonance imaging (MRI). Although MRI is not part of our routine diagnostic imaging, MRI was performed in all patients because of elbow joint snapping. MRI was used to evaluate the presence of a high signal or torn ECRB and to confirm the synovial plicae that interpose between the radial head and capitellum. MRI has been used widely and is appreciated for its high sensitivity, specificity, and accuracy in the diagnosis of LE.¹³ Nevertheless, despite the ability of MRI to reveal a synovial plicae structure, no definitive findings have been described for distinguishing a pathologic plicae from a physiologic plicae.²⁸

Operative Procedures

The surgery was performed by a single senior surgeon (I.-H.J.) on an outpatient basis in the manner described by Baker et al.⁵ Prophylactic antibiotics were administered preoperatively. The patient was placed in a lateral

^{||}Address correspondence to Erica Kholinne, MD, PhD, Department of Orthopedic Surgery, St. Carolus Hospital. Jl. Salemba Raya No. 41, Jakarta Pusat, Jakarta, Indonesia (email: erica_kholinne@yahoo.com).

^{*}Department of Orthopedic Surgery, Asan Medical Center, University of Ulsan, Seoul, Republic of Korea.

[†]Department of Hand Surgery, Ningbo No. 6 Hospital, Ningbo, Zhejiang, China.

[‡]Department of Hand Surgery, Affiliated Hospital of Nantong University, Nantong, China.

[§]Department of Orthopedic Surgery, St. Carolus Hospital, Jakarta, Indonesia.

Parts of this study were presented at the ISAKOS Congress, Cancun, Mexico, May 2019.

Final revision submitted February 10, 2020; accepted February 27, 2020.

One or more of the authors has declared the following potential conflict of interest or source of funding: This research was supported by the convergence technology development program for the bionic arm through the National Research Foundation of Korea funded by the Ministry of Science & ICT (No. 2014M3C1B2048422). AOSSM checks author disclosures against the Open Payments Database (OPD). AOSSM has not conducted an independent investigation on the OPD and disclaims any liability or responsibility relating thereto.

Ethical approval for this study was obtained from Asan Medical Center (No. 2019-0784).

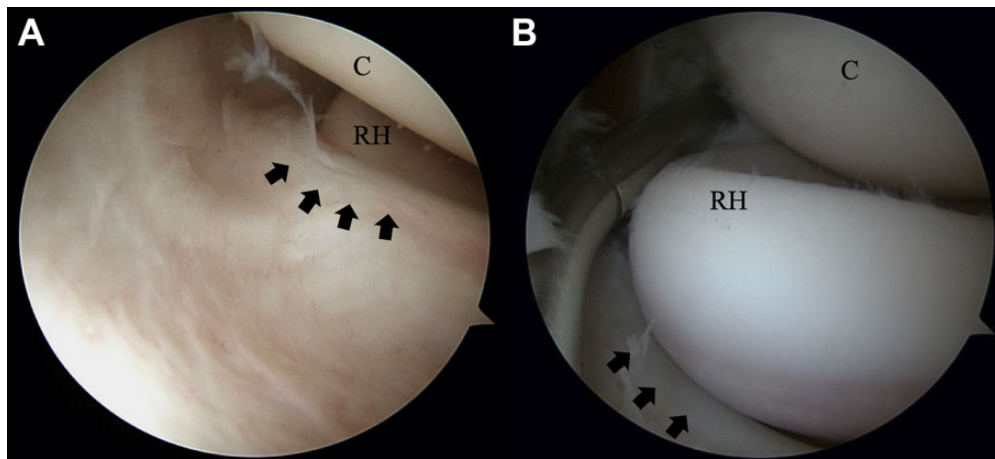


Figure 1. Arthroscopic images from the proximal anteromedial portal of the right elbow showing (A) meniscocapsular complex type III (black arrows) with radiocapitellar joint snapping and (B) resection of the upper portion of the annular ligament resulting from type I meniscocapsular complex with annular ligament remnant (black arrows). C, capitellum; RH, radial head.

decubitus position under general anesthesia. A tourniquet was applied, and the joint was distended with 20 mL of saline through an 18-gauge needle introduced through a lateral soft spot. A standard 4.0-mm, 30°-angled arthroscope with a pump was used. Diagnostic arthroscopy was performed through the anteromedial portal as a standard viewing portal. Careful examination was conducted for the type of capsular lesion based on the classification system by Baker et al⁵ (type I, smooth capsule; type II, torn capsule; type III, retracted capsule) and on the existence and arrangement of the meniscocapsular complex based on the criteria described by Mullet et al³⁰ (type I, no impingement or coverage of the radial head; type II, partial coverage of the radial head during elbow extension; type III, subluxation of the capsular edge into the radiocapitellar joint; type IV, complete obscuration of the radial head in all elbow flexion and extension positions). The meniscocapsular complex was assessed under flexion-extension and pronation-supination of the elbow. The conditions of the annular ligament as well as the cartilage of the radial head and capitellum were evaluated.

Modified Bosworth Technique

A direct lateral portal was established as the working portal. The Bosworth¹⁰ technique was used as the standard and modified with our protocol. It was originally described as an open technique with 4 types of procedures; type 1 involved dividing the common extensor origin, followed by synovial fringe removal in type 2, orbicular (annular) ligament removal in type 3, and resuturing of the common extensor origin over the radial head in type 4. The original Bosworth procedure was adapted in this study to include only procedure types 1 through 3 under arthroscopy. The capsule underneath the ECRB tendon was debrided through use of a 3.5-mm shaver (Dyonics 3.5-mm Arthroscopic Surgical Blade; Smith & Nephew) until the extensor carpi radialis longus muscle insertion was visualized. The arthroscope was then proximally advanced, tracing the

ECRB origin to the lateral epicondyle. The ECRB origin was then removed by use of a 2.4-mm radiofrequency ablator (ArthroCare). ECRB release was limited to the anterior half of the radial head equator so as not to violate the lateral collateral ligament. A shaver was used to remove any remaining tendinosis found in the retracted ECRB tendon. The lateral epicondyle was not decorticated. The synovial plica was then debrided with an ablator if the plica was hypertrophic and measured 3 mm or more in thickness at the preoperative MRI investigation corresponding to the intraoperative finding.³⁸ The radiocapitellar joint was checked for visible snapping by performance of flexion-extension and pronation-supination. If snapping occurred, the annular ligament was partially removed at the upper portion of the anterolateral part to the distal edge of the radial neck (Figure 1). Careful partial resection of the annular ligament was performed with an L-hook tip radiofrequency ablator (Saber 30; ArthroCare). The skin was closed with interrupted suture with 3.0 Nylon suture. At the final follow-up session in the outpatient clinic, elbow joint stability was assessed due to the concern for iatrogenic injury of the lateral ulnar collateral ligament during debridement of the ECRB origin.

Postoperative Protocol

Active-assisted range of motion exercise was encouraged on the first day following surgery or as pain was tolerated. A light dressing was applied 3 days postoperatively. All sutures were removed 2 weeks postoperatively. Strenuous activities were allowed if pain was tolerable.

Outcome Assessment

Pre- and postoperative clinical assessments were conducted by a single independent blinded examiner (E.K.). The functional outcome assessment included the motion arc in flexion-extension and pronation-supination and an evaluation for pain with a visual analog scale (VAS). The

Disabilities of the Arm, Shoulder and Hand (DASH) score and Mayo Elbow Performance Score (MEPS) served as the outcome measurement tools.¹⁷ The DASH score is a general outcome measure of upper extremity conditions, and the MEPS is used specifically to assess the elbow joint. The patients were surveyed for their satisfaction with the procedure (much better, better, same, or worse compared with preoperative levels). The time to return to unrestricted work and any complications of the procedures were also recorded.

Statistical Analysis

The estimated sample size needed was calculated based on paired *t* tests. A sample size of 40 patients was needed to achieve a large effect size with a power of 0.8 and a .05 type I error. The Kolmogorov-Smirnov test was used for normality distribution. The data set for the DASH score was normally distributed; therefore, the paired *t* test was used to compare pre- and postoperative mean values. Data sets for VAS, motion arc, and MEPS had skewed distribution; therefore, the Wilcoxon signed-rank test was used to compare pre- and postoperative means. The significance level was set at $P < .05$. All descriptive and analytic analyses were conducted using SPSS (Version 15.0; SPSS Inc).

RESULTS

During the study period, a total of 22 patients with refractory LE and radiocapitellar joint snapping underwent the arthroscopic modified Bosworth procedure. The patients included 15 women and 7 men with a mean \pm SD age of 51.2 ± 10.4 years. A total of 14 (63.6%) patients were involved in manual labor, 7 (31.9%) performed office-type work, and 1 (4.5%) was unemployed at the time of surgery. There were no professional athletes in the study. A total of 15 (68.2%) elbows involved the dominant arm. The mean duration of nonoperative treatment was 16.2 ± 11.9 months.

Capsular lesions were evaluated with the classification system described by Baker et al⁵; we identified 1 (4%) type I lesion, 12 (55%) type II lesions, and 9 (41%) type III lesions. Synovial plicae existed in all cases, with a posterior site for 16 patients (72.7%), anterior site for 2 patients (9%), and anteroposterior site for 4 patients (18.3%). The meniscocapsular complex was assessed with the classification system described by Mullet et al,³⁰ revealing 9 (41%) cases of type II and 13 (59%) cases of type III meniscocapsular complex. No type I or IV meniscocapsular complex was observed. Synovitis was observed at the anterior part of the radiocapitellar joint in 16 (80%) patients, the posterior part in 1 (5%) patient, and both anterior and posterior parts in 3 (15%) patients. Other surgical findings included a focal radial head cartilage lesion in 2 patients. None of the patients had osteoarthritis, loose bodies, or instability. Further, none of the patients experienced snapping or needed further annular ligament resection after the procedure.

The mean follow-up was 29.4 ± 7.7 months (range, 21-42 months). At the final follow-up, the VAS, motion arc,

TABLE 2
Comparison of Functional Outcomes of VAS, Motion Arc, DASH, and MEPS^a

Functional Outcome Measurement	Preoperative	Final Follow-up	P Value
VAS	7.5 ± 1.2	2.5 ± 1.8	$<.001^b$
Motion arc			
Extension-flexion	133.8 ± 11.2	146.4 ± 7.1	$.001^b$
Pronation-supination	101.8 ± 9.2	141.7 ± 10.2	$.001^b$
DASH	54.5 ± 13.2	3.6 ± 4.1	$<.001^c$
MEPS	51.9 ± 12.2	84.3 ± 10.3	$<.001^b$

^aValues are expressed as mean \pm SD. DASH, Disabilities of the Arm, Shoulder and Hand score; MEPS, Mayo Elbow Performance Score; VAS, visual analog scale.

^bWilcoxon signed-rank test.

^cPaired *t* test.

DASH, and MEPS scores were remarkably improved (Table 2). The overall satisfaction was “much better” in 18 patients (82%) and “better” in 4 patients (18%), and none reported feeling “the same” or “worse.” The mean time to return to work without restriction was 10 days (range, 7-14 days). The mean time to return to work was longer for patients involved in manual labor (11.2 days) than for patients whose work did not involve manual labor (9.1 days) ($P = .02$). No complications were recorded.

DISCUSSION

This study found that the arthroscopic modified Bosworth technique provided a safe and favorable outcome in refractory LE. The study also revealed the associated intra-articular pathology in refractory LE, which includes the meniscocapsular complex lesion, synovitis, and focal radial head cartilage lesion. This finding implies that it is perhaps important to look for the presence of other pathologies, such as the meniscocapsular complex lesion that resulted in radiocapitellar snapping.

As an alternative to open surgical procedures, arthroscopic intervention for LE has gained in popularity since described by Baker et al.⁵ Some studies described favorable outcomes of arthroscopic intervention^{4,30,39}; however, 10% of patients experienced residual pain.⁴ Associated intra-articular pathology has been proposed as the cause of this refractory state.^{8,30} The additional benefit of the arthroscopic technique is the ability to address the associated intra-articular pathology without disturbing the common extensor tendon. This study highlights the importance of addressing the associated intra-articular pathology in the treatment of refractory LE, which includes capsular debridement, meniscocapsular complex lesion resection, and partial resection of the annular ligament. Any meniscocapsular complex lesions were mostly type III, which partially covers the radiocapitellar joint (59%). A focal radial head cartilage lesion was found in only 2 cases, and we postulated that it was due to the abrading effect from the mirroring meniscocapsular complex lesion. The existence of

the meniscocapsular complex suggests the possibility that this is an important pathology in refractory LE. In contrast to our intra-articular pathology assessment, recent studies highlighted subtle elbow instability as a cause of refractory LE without joint snapping.^{3,25} The subtle instability of the elbow joint was demonstrated by varus stress testing with the patient under anesthesia²⁵ or by the sign of lateral ligamentous patholaxity during arthroscopic examination.³ Arthroscopic plication of the lateral ligament complex was performed in a series of 27 patients with LE who had an incompetent lateral ligament complex, resulting in favorable outcomes.³ Therefore, in patients without radiocapitellar joint snapping, the clinician should consider the incompetence of the lateral ligament complex as another cause of refractory LEs.

The synovial plica is a consistent structural remnant of normal embryonic development during the cavitation stage.^{20,29} It has been found to cover 28% of the radiocapitellar joint of the adult radial head.²⁴ A cadaveric study revealed nearly 100% existence of synovial plica with an absence of the lateral fold in the embryonic elbow. The lateral fold was observed in only adult specimens, which appeared as an excessive hyalinized lateral extension caused by the alteration of the radial head movement.²⁰ Furthermore, an anatomic study revealed that the synovial plica protruded as a distinct structure from the proximal edge of the inner surface of the annular ligament, which merged with the common extensor tendon to form a composite structure together with capsule and bone.²⁰ Therefore, the pathology of LE may involve 1 or more of these elements. Elbow extension increases the tension in the capsule, and forearm pronation produces tension in the ECRB. Moreover, repeated, piston-like radial head movements will cause considerable compression stress, which later results in hypertrophy of the fold, similar to skin folds found in highly mobile sites.²⁰ Repetitive tension of the ECRB, as seen in overuse injuries, may thrust the pathologic fold into the radiocapitellar joint and cause refractory lateral elbow pain with or without mechanical symptoms, such as snapping, clicking, or catching (Figure 2).^{16,19,30,35,38}

In a study of 30 patients who had recalcitrant LE for at least 9 months, Mullet et al³⁰ found that all patients had a collar-like band as an extension of the radiocapitellar capsule impinging the radial head at the time of arthroscopy. In comparison, similar impingement was found in only 15 of 34 cadaveric elbow specimens.³⁰ Therefore, LE may be a spectrum disease that appears to be consistent with the following superimposed structures: (1) degenerated ECRB tendon, (2) radiocapitellar capsular lesions, (3) pathologic synovial plicae, and (4) hypertrophic annular ligament. This postulation is supported by several histology studies that revealed the existence of free nerve endings in the capsule and synovial plica.^{22,36} The annular ligament may also have nociceptive receptors.²³ Failure to address all structures may lead to painful and refractory conditions.

Our modified Bosworth procedure has several advantages in the management of refractory LE with snapping radiocapitellar joint. First, in this study, the ECRB origin, typically affected in LE, was consistently released, which may lead to distal migration of the capsulotendinous complex, thereby

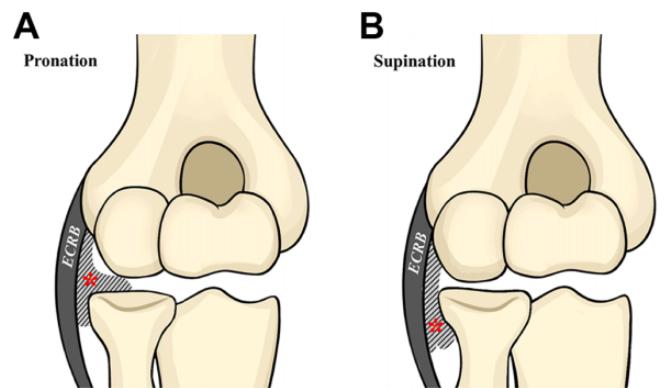


Figure 2. Illustration of the pathology of symptomatic plica. An articular capsule tear changes the normal tension of the annular ligament, resulting in piston-like movement that leads to a hypermobile plica (*) that (A) occupies the radiocapitellar joint in the pronation position and (B) is released from the radiocapitellar joint in the supination position. ECRB, extensor carpi radialis brevis.

creating the decompression effect.³⁰ Second, consistent debridement of the capsular lesions is necessary to eliminate pain source structures and increase the decompression effect. Third, dynamic assessment of synovial plica is necessary in every case. An inflamed and hypertrophic plica will impinge the radial head in extension and flexion movements. Therefore, we routinely debride this pathologic plica rather than perform a simple division. Simple division to reduce the bow-string effect of this structure should be avoided because it can lead to fibrosis and possible recurrence of symptoms.³⁷ Fourth, the main feature of our technique is that it addresses the stenotic annular ligament, which Bosworth described as a characteristic of this condition.¹⁰

Complete annular ligament resection has been described in previous studies^{2,10}; nevertheless, we do not recommend this procedure. Biomechanical studies have revealed the contribution of the annular and lateral collateral ligaments to elbow joint stability.^{32,33} Furthermore, additional studies have reported that annular ligament reconstruction is mandatory when dealing with congenital radial head dislocation.^{40,41} Therefore, in this study, only the upper portion of the anterolateral annular ligament was removed. Overzealous resection of the annular ligament is not advocated because it will render the collateral ligament ineffective, leading to elbow instability. Partial annular ligament resection has also been reported to result in favorable outcomes.¹²

The arthroscopic modified Bosworth technique resulted in favorable outcomes at the final follow-up assessments, with no patients experiencing complications. Thus, pathologic plica and hypertrophic annular ligament should not be underestimated. Radiocapitellar joint snapping may coexist as a disease spectrum with LE.

Limitations

This study has some limitations. First, the study was a retrospective case series from a single surgeon and did not

include a control arm, such as patients who were treated for only LE (nonplica) or patients who underwent treatment for only the plicae. Therefore, this may lead to the possibility of limited external validity. Nevertheless, given the rarity of this disease, a comparative study was difficult to perform. Second, the small sample size may lead to inadequate power. Third, there was a lack of long-term follow-up to track the possibility of lateral elbow instability complication, which was not found during the study period. Fourth, a large number of patients were excluded because they had less than 1 year of follow-up, were deceased, or refused to participate, leading to the possibility of selection bias among the patients who were included.

CONCLUSION

Radiocapitellar joint snapping may coexist with LE as a disease spectrum. Awareness of this condition may prevent delays and underdiagnosis. An arthroscopic modified Bosworth technique results in safe and favorable outcomes for patients with refractory LE associated with radiocapitellar joint snapping.

ACKNOWLEDGMENT

We thank Jessica Kholinne for her assistance in providing illustrations as well as Jong Hwee Park, CNS, for her assistance in collecting medical information.

REFERENCES

1. Antuna SA, O'Driscoll SW. Snapping plicae associated with radiocapitellar chondromalacia. *Arthroscopy*. 2001;17(5):491-495.
2. Aoki M, Okamura K, Yamashita T. Snapping annular ligament of the elbow joint in the throwing arms of young brothers. *Arthroscopy*. 2003;19(8):e4-e7.
3. Arrigoni P, Cucchi D, D'Ambrosi R, Menon A, Aliprandi A, Randelli P. Arthroscopic R-LCL plication for symptomatic minor instability of the lateral elbow (SMILE). *Knee Surg Sports Traumatol Arthrosc*. 2017; 25(7):2264-2270.
4. Baker CL Jr, Baker CL III. Long-term follow-up of arthroscopic treatment of lateral epicondylitis. *Am J Sports Med*. 2008;36(2): 254-260.
5. Baker CL Jr, Murphy KP, Gottlob CA, Curd DT. Arthroscopic classification and treatment of lateral epicondylitis: two-year clinical results. *J Shoulder Elbow Surg*. 2000;9(6):475-482.
6. Barnes DE, Beckley JM, Smith J. Percutaneous ultrasonic tenotomy for chronic elbow tendinosis: a prospective study. *J Shoulder Elbow Surg*. 2015;24(1):67-73.
7. Baumgard SH, Schwartz DR. Percutaneous release of the epicondylar muscles for humeral epicondylitis. *Am J Sports Med*. 1982;10(4): 233-236.
8. Bhabra G, Wang A, Ebert JR, Edwards P, Zheng M, Zheng MH. Lateral elbow tendinopathy: development of a pathophysiology-based treatment algorithm. *Orthop J Sports Med*. 2016;4(11):2325967 116670635.
9. Binder AI, Hazleman BL. Lateral humeral epicondylitis—a study of natural history and the effect of conservative therapy. *Br J Rheumatol*. 1983;22(2):73-76.
10. Bosworth DM. The role of the orbicular ligament in tennis elbow. *J Bone Joint Surg Am*. 1955;37-A(3):527-533.
11. Bowen RE, Dorey FJ, Shapiro MS. Efficacy of nonoperative treatment for lateral epicondylitis. *Am J Orthop (Belle Mead NJ)*. 2001;30(8): 642-646.
12. Bozentka DJ. Subluxation of the annular ligament as a cause of elbow clicking. *J Shoulder Elbow Surg*. 2000;9(1):67-69.
13. Cha YK, Kim SJ, Park NH, Kim JY, Kim JH, Park JY. Magnetic resonance imaging of patients with lateral epicondylitis: relationship between pain and severity of imaging features in elbow joints. *Acta Orthop Traumatol Turc*. 2019;53(5):366-371.
14. Clarke RP. Symptomatic, lateral synovial fringe (plica) of the elbow joint. *Arthroscopy*. 1988;4(2):112-116.
15. Cummins CA. Lateral epicondylitis: in vivo assessment of arthroscopic debridement and correlation with patient outcomes. *Am J Sports Med*. 2006;34(9):1486-1491.
16. Duparc F, Putz R, Michot C, Muller JM, Freger P. The synovial fold of the humeroradial joint: anatomical and histological features, and clinical relevance in lateral epicondylalgia of the elbow. *Surg Radiol Anat*. 2002;24(5):302-307.
17. Evans JP, Porter I, Gangannagaripalli JB, et al. Assessing patient-centred outcomes in lateral elbow tendinopathy: a systematic review and standardised comparison of English language clinical rating systems. *Sports Med Open*. 2019;5(1):10.
18. Grewal R, MacDermid JC, Shah P, King GJ. Functional outcome of arthroscopic extensor carpi radialis brevis tendon release in chronic lateral epicondylitis. *J Hand Surg Am*. 2009;34(5):849-857.
19. Huang GS, Lee CH, Lee HS, Chen CY. MRI, arthroscopy, and histologic observations of an annular ligament causing painful snapping of the elbow joint. *AJR Am J Roentgenol*. 2005;185(2): 397-399.
20. Isogai S, Murakami G, Wada T, Ishii S. Which morphologies of synovial folds result from degeneration and/or aging of the radiohumeral joint: an anatomic study with cadavers and embryos. *J Shoulder Elbow Surg*. 2001;10(2):169-181.
21. Jerosch J, Schunck J. Arthroscopic treatment of lateral epicondylitis: indication, technique and early results. *Knee Surg Sports Traumatol Arthrosc*. 2006;14(4):379-382.
22. Kholinne E, Lee HJ, Deslivia MF, et al. Neuroanatomical distribution of sensory receptors in the human elbow joint capsule. *Shoulder Elbow*. 2019;11(4):300-304.
23. Kholinne E, Lee HJ, Lee YM, et al. Mechanoreceptor profile of the lateral collateral ligament complex in the human elbow. *Asia Pac J Sports Med Arthrosc Rehabil Technol*. 2018;14:17-21.
24. Koh S, Morris RP, Andersen CL, Jones EA, Viegas SF. Ultrasonographic examination of the synovial fold of the radiohumeral joint. *J Shoulder Elbow Surg*. 2007;16(5):609-615.
25. Kwak SH, Lee SJ, Jeong HS, Do MU, Suh KT. Subtle elbow instability associated with lateral epicondylitis. *BMC Musculoskelet Disord*. 2018;19(1):136.
26. Kwon BC, Kim JY, Park KT. The Nirschl procedure versus arthroscopic extensor carpi radialis brevis debridement for lateral epicondylitis. *J Shoulder Elbow Surg*. 2017;26(1):118-124.
27. Lattermann C, Romeo AA, Anbari A, et al. Arthroscopic debridement of the extensor carpi radialis brevis for recalcitrant lateral epicondylitis. *J Shoulder Elbow Surg*. 2010;19(5):651-656.
28. Lee HI, Koh KH, Kim JP, Jaegal M, Kim Y, Park MJ. Prominent synovial plicae in radiocapitellar joints as a potential cause of lateral elbow pain: clinico-radiologic correlation. *J Shoulder Elbow Surg*. 2018; 27(8):1349-1356.
29. Merida-Velasco JA, Sanchez-Montesinos I, Espin-Ferra J, Merida-Velasco JR, Rodriguez-Vazquez JF, Jimenez-Collado J. Development of the human elbow joint. *Anat Rec*. 2000;258(2):166-175.
30. Mullett H, Sprague M, Brown G, Hausman M. Arthroscopic treatment of lateral epicondylitis: clinical and cadaveric studies. *Clin Orthop Relat Res*. 2005;439:123-128.
31. Nirschl RP, Pettrone FA. Tennis elbow: the surgical treatment of lateral epicondylitis. *J Bone Joint Surg Am*. 1979;61(6A):832-839.
32. Olsen BS, Sojbjerg JO, Dalstra M, Sneppen O. Kinematics of the lateral ligamentous constraints of the elbow joint. *J Shoulder Elbow Surg*. 1996;5(5):333-341.

33. Olsen BS, Sojbjerg JO, Nielsen KK, Vaesel MT, Dalstra M, Sneppen O. Posterolateral elbow joint instability: the basic kinematics. *J Shoulder Elbow Surg.* 1998;7(1):19-29.
34. Peart RE, Strickler SS, Schweitzer KM Jr. Lateral epicondylitis: a comparative study of open and arthroscopic lateral release. *Am J Orthop (Belle Mead NJ).* 2004;33(11):565-567.
35. Ruch DS, Papadonikolakis A, Campolattaro RM. The posterolateral plica: a cause of refractory lateral elbow pain. *J Shoulder Elbow Surg.* 2006;15(3):367-370.
36. Sasaki K, Ohki G, Iba K, Kokai Y, Yamashita T, Wada T. Innervation pattern at the undersurface of the extensor carpi radialis brevis tendon in recalcitrant tennis elbow. *J Orthop Sci.* 2013;18(4):528-535.
37. Schindler OS. "The sneaky plica" revisited: morphology, pathophysiology and treatment of synovial plicae of the knee. *Knee Surg Sports Traumatol Arthrosc.* 2014;22(2):247-262.
38. Steinert AF, Goebel S, Rucker A, Barthel T. Snapping elbow caused by hypertrophic synovial plica in the radiohumeral joint: a report of three cases and review of literature. *Arch Orthop Trauma Surg.* 2010;130(3):347-351.
39. Szabo SJ, Savoie FH III, Field LD, Ramsey JR, Hosemann CD. Tendinosis of the extensor carpi radialis brevis: an evaluation of three methods of operative treatment. *J Shoulder Elbow Surg.* 2006;15(6):721-727.
40. Thompson JD, Lipscomb AB. Recurrent radial head subluxation treated with annular ligament reconstruction: a case report and follow-up study. *Clin Orthop Relat Res.* 1989;246:131-135.
41. Yamazaki H, Kato H. Open reduction of the radial head with ulnar osteotomy and annular ligament reconstruction for bilateral congenital radial head dislocation: a case with long-term follow-up. *J Hand Surg Eur Vol.* 2007;32(1):93-97.