

# Quantitative Analysis of Microvascular Network with Optical Coherence Tomography Angiography and its Correlation with Visual Acuity in Retinal Vein Occlusion

Meriem Ouederni<sup>1,2</sup>, Mohamed Ben Hadj Khalifa<sup>1,2</sup>, Hela Sassi<sup>1,2</sup>, Fehmy Nefaa<sup>1,2</sup>, Oumaima Ayed<sup>2,3</sup>, Monia Cheour<sup>1,2</sup>

<sup>1</sup>Department of Ophthalmology, Habib Thameur Hospital, Tunis, Tunisia, <sup>2</sup>University of Tunis El Manar, Faculty of Medicine of Tunis, Tunisia, <sup>3</sup>Department of Medical Epidemiology, Pasteur Institute of Tunis, Tunisia

## Abstract

**Purpose:** To analyze the macular microvascular network and the correlations between visual acuity and quantitative parameters using optical coherence tomography angiography (OCTA) in eyes with retinal vein occlusion (RVO).

**Methods:** We conducted a prospective cross-sectional study including patients with unilateral RVO. We performed 4.5 mm × 4.5 mm macular OCTA angiograms for assessment of quantitative parameters in both superficial and deep capillary plexuses (SCP, DCP). Area of foveal avascular zone (FAZ), vascular density (VD), skeleton density (SD), fractal dimension (FD), vessel diameter index (VDI), and lacunarity (LAC) were analyzed.

**Results:** Seventy eyes of 35 patients were enrolled. As compared to fellow eyes, OCTA analysis in eyes with RVO showed larger FAZ, lower VD, lower SD, lower FD, higher VDI, and increased LAC in both plexuses (All  $P < 0.05$ ). The enlargement of FAZ in the SCP was associated with visual loss ( $P = 0.025$ ,  $r = 0.378$ ). In the DCP, visual acuity was negatively correlated with parafoveal VD, SD, and FD ( $P = 0.004$ ,  $r = -0.472$ ;  $P = 0.003$ ,  $r = -0.482$  and  $P = 0.036$ ,  $r = -0.308$ , respectively). Stepwise multivariate regression analysis showed that lower SD and lower FD in the DCP remained correlated with poorer visual acuity ( $P = 0.04$ ,  $r = -0.261$  and  $P = 0.032$ ,  $r = -0.264$ , respectively).

**Conclusions:** OCTA provides quantitative parameters to analyze retinal microvasculature in eyes with RVO. These OCTA biomarkers could be used to predict the impact of macular ischemia and capillary dropout on visual acuity in RVO.

**Keywords:** Microvascular network, Optical coherence tomography angiography, Retinal vein occlusion, Vascular density

**Address for correspondence:** Meriem Ouederni, 3, Road A, Ben Ayed Montfleury, 1089 Tunis, Tunisia.

E-mail: meriem.oued@hotmail.com

**Submitted:** 22-May-2021; **Revised:** 01-Oct-2021; **Accepted:** 01-Oct-2021; **Published:** 06-Jan-2022

## INTRODUCTION

Retinal vein occlusion (RVO) is the second most common retinal vasculopathy that can lead to visual impairment after diabetic retinopathy.<sup>1</sup> Its prognosis depends on two main complications: macular edema and retinal nonperfusion.<sup>2,3</sup> Fluorescein angiography (FA) and optical coherence tomography (OCT) have been the gold standard to examine the retinal vasculature and macular structure in eyes with RVO in order to identify these complications.<sup>4</sup>

Recently introduced into clinical practice, optical coherence tomography angiography (OCTA) is a recent noninvasive technique, which provides high-resolution and three-dimensional retinal vasculature analysis. Unlike FA, this new imaging tool can visualize the superficial and deep retinal capillary networks separately and without dye injection.<sup>5</sup> Several studies<sup>6-8</sup> have reported qualitative microvascular abnormalities using OCTA imaging in eyes

This is an open access journal, and articles are distributed under the terms of the Creative Commons Attribution-NonCommercial-ShareAlike 4.0 License, which allows others to remix, tweak, and build upon the work non-commercially, as long as appropriate credit is given and the new creations are licensed under the identical terms.

**For reprints contact:** WKHLRPMedknow\_reprints@wolterskluwer.com

**How to cite this article:** Ouederni M, Khalifa MB, Sassi H, Nefaa F, Ayed O, Cheour M. Quantitative analysis of microvascular network with optical coherence tomography angiography and its correlation with visual acuity in retinal vein occlusion. *J Curr Ophthalmol* 2021;33:453-60.

### Access this article online

Quick Response Code:



**Website:**  
www.jcurrophthalmol.org

**DOI:**  
10.4103/joco.joco\_163\_21

with RVO including vascular tortuosity, microaneurysms, nonperfusion areas, collateral vessel formation, cystoid spaces, and disruption of the perifoveal capillary plexus, especially in the deep retinal network.

More recent works<sup>9,10</sup> have measured OCTA quantitative parameters such as foveal avascular zone (FAZ) area and vascular density (VD) to assess microvascular changes in the macular region in these eyes and their correlation with visual acuity. These OCTA indices remain uninformative about capillary morphology. Other objective and reproducible quantitative parameters are needed to help assess RVO severity and prognosis.

The purpose of this study was to analyze the macular microvascular network using OCTA in eyes with RVO and to assess the correlation between quantitative parameters and visual acuity.

## METHODS

A prospective, observational cross-sectional single-center study was conducted between March 2017 and March 2019. The study adhered to the tenets of the 1964 Declaration of Helsinki. All patients provided written informed consent.

The inclusion criteria were the presence of unilateral central RVO (CRVO), or branch RVO (BRVO) or hemicentral RVO (HCRVO), either naïve or already treated (3 months after the last anti-vascular endothelial growth factor [anti-VEGF] injection). The exclusion criteria were the presence of any other retinal disorders (diabetic retinopathy, epiretinal membrane, retinal arterial occlusion, or age-related macular degeneration), a history of retinal surgery, pathologic myopia, high hyperopia (more than -6 diopters), and previous ocular trauma. Eyes with poor-quality images on OCTA (signal strength index lower than 50) due to media opacities, eye movements, or significant motion artifact were excluded.

Thirty-five patients with unilateral RVO who presented to our department between March 2017 and March 2019 met our eligibility criteria.

All patients underwent a complete ophthalmic examination including: best corrected visual acuity (BCVA) measurement, FA (TRC 50 DX, Topcon Corporation, Tokyo, Japan), swept-source OCT (SS-OCT) and OCTA 4.5 × 4.5 mm scans centered on the fovea (DRI OCT Triton machine, Topcon Corporation, Tokyo, Japan).

The SS-OCT scans were performed to spot the presence of cystoid macular edema (CME). The central retinal thickness (CRT) was recorded on the B-scan maps from a 1-mm diameter circle on the Early Treatment Diabetic Retinopathy Study (ETDRS) grid. The presence of ellipsoid zone (EZ) disruption was defined as any loss of the continuity of the EZ within the 1-mm diameter centered on the fovea.

The swept-source DRI OCT Triton machine (Topcon Corporation, Tokyo, Japan) was used for OCTA imaging.

This device uses an integrated blood flow detection algorithm: Optical Coherence Tomography Angiography Ratio Analysis (OCTARA) and operates at 100,000 A-scans per second to acquire OCTA volumes.<sup>11</sup> Automated segmentation was conducted using integrated Triton software (IMAGEnet 6) to delineate the superficial capillary plexus (SCP) (between 15.6 μm below the inner border of the inner plexiform layer [IPL] and 2.6 μm below the top of the internal limiting membrane) and the deep capillary plexus (DCP) (between 15.6 and 70.2 μm below the inner border of the IPL).<sup>12</sup>

In case of significant disorganization of retinal layers due to a significant subretinal fluid or a CME, manual adjustment of the segmentation slab was performed.

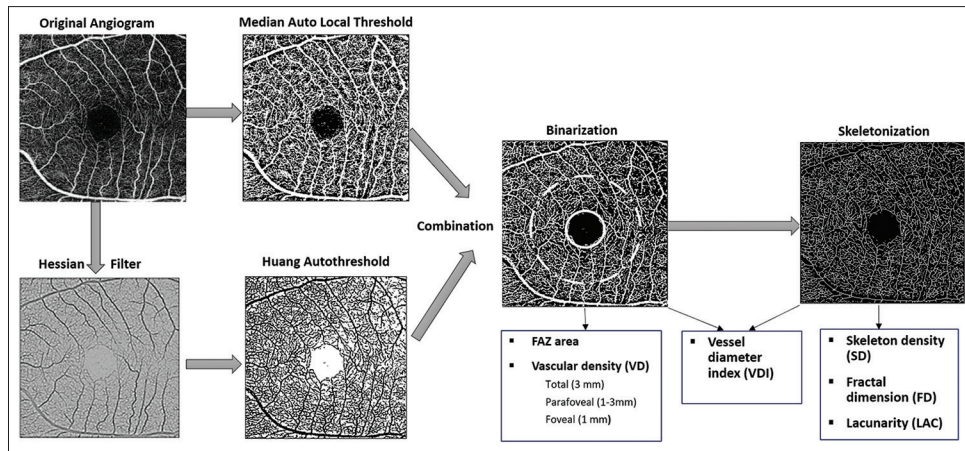
ImageJ software version 1.50 (National Institutes of Health, Bethesda, MD, USA) was used to convert the en face angiograms of the SCP and DCP into binarized and skeletonized images. The 4.5 mm × 4.5 mm en face angiograms were used to get two binarized images, one after being processed with a Hessian filter, then a Huang auto threshold, and the other was processed with the median auto local threshold. These images were compared to create the final binarized image, only positive pixels with both methods were counted as vessels. The binarization method was previously described.<sup>13,14</sup> The skeletonized image was then created by reducing the width of each vessel segment to one pixel [Figure 1].

Through the analysis of these images, we calculated retinal vascular perfusion parameters (VD, skeleton density [SD]) and retinal vascular morphology parameters (fractal dimension [FD], vessel diameter index [VDI], and lacunarity [LAC]).

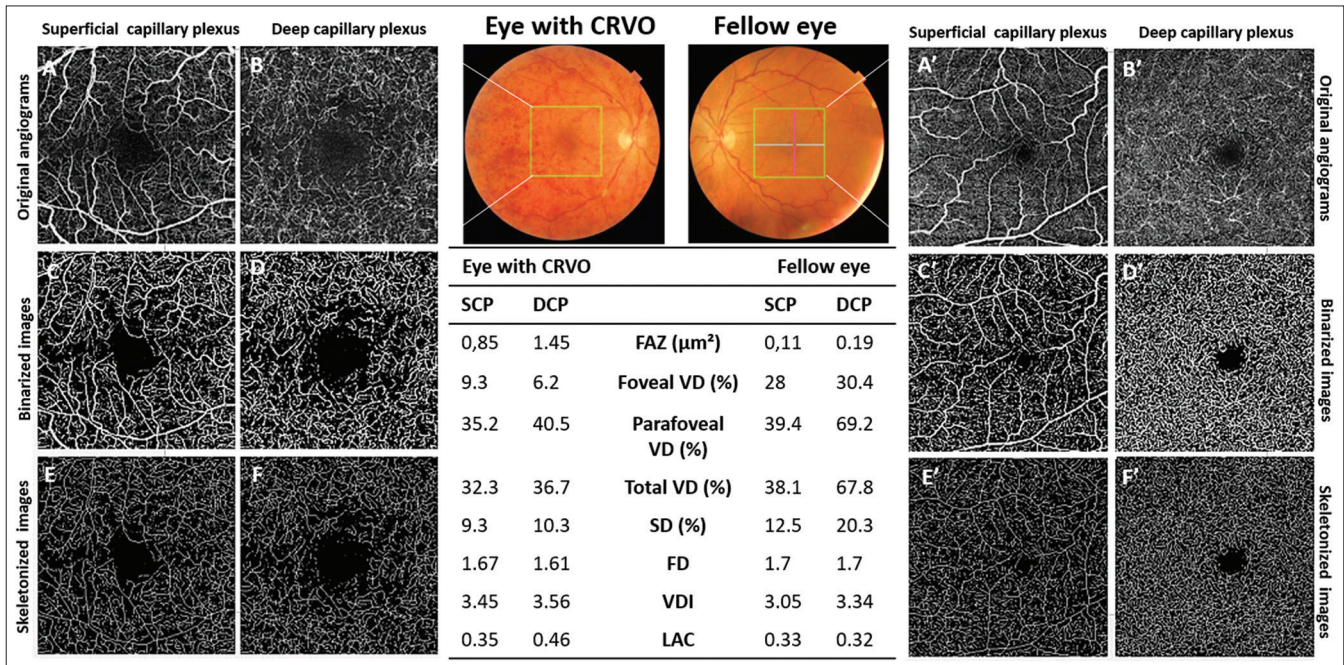
Two experienced graders (C.M and O.M) independently reviewed the images. Areas of the FAZ in the full slab, the superficial, and the deep retinal layers were manually measured using the plotter tool offered by the IMAGEnet software. The VD was derived from the binarized OCTA scan and was calculated as the ratio of pixels occupied by blood vessels to all pixels in the binarized image.<sup>15</sup> The areas used for VD quantification in our study were the foveal area (within 1-mm diameter centered on the fovea), the parafoveal area (macular ring measured between 1 mm and 3 mm from the center of the fovea), and total foveal area (within 3-mm diameter centered on the fovea).

The SD was derived from the skeletonized OCTA image to represent the length of the entire macular vascular network independently of vessel caliber. The FD and LAC were deduced from the skeletonized image using the box-counting method in ImageJ Fiji software, as previously described.<sup>14,16</sup> FD quantifies vessel complexity. It has a value between 0 and 2, with lower values indicating decreased pattern complexity.<sup>17</sup> LAC characterizes structural nonuniformity where lower values reflect a homogenous vascular structure and higher values reflect heterogeneity.<sup>18</sup> VDI was derived from both skeletonized and binarized images to quantify the average vascular caliber.





**Figure 1:** Imaging processing with Image J software. The 4.5 mm × 4.5 mm en face angiograms were converted to 8-bit 320 × 320 pixel images, and global thresholding was done by subtracting the mean signal of a fixed central selection area (50 pixels) to decrease the background noise. Then the image was duplicated. One copy was processed with a Hessian filter and binarized using a Huang auto threshold, and the other one underwent binarization through the median auto local threshold. Lastly, the two binarized images were compared, and only positive pixels with both methods were counted as vessels. The skeletonized image was then created by reducing the width of each vessel segment to one pixel. The binarized optical coherence tomography angiography scan was used to calculate foveal avascular zone area and vascular density. From the skeletonized image, we determined skeleton density, fractal dimension, and lacunarity. Vessel diameter index was derived from both the binarized and the skeletonized images



**Figure 2:** Analyzed 4.5 × 4.5 angiograms in a 55-year-old patient with central retinal vein occlusion (CRVO) in the right eye. As compared to the left unaffected eye, binarized optical coherence tomography angiography images in the CRVO eye show a larger foveal avascular zone and lower foveal, parafoveal, and total vascular density in the superficial capillary plexus and the deep capillary plexus. Skeletonized images show a decreased fractal dimension and an increased lacunarity in both networks of the eye with CRVO. Results are summarized in the table.

**Statistical analysis**

All statistical analyses were performed using IBM SPSS Statistics version 24.0 (Chicago, IL, USA).

The BCVA was converted to the logMAR for statistical analysis. All values were presented as a mean ± standard deviation. *P* < 0.05 was considered statistically significant.

Eyes with RVO were compared to the unaffected fellow eyes. Paired *t*-test was used to compare the quantitative data of the two eyes. Student’s *t*-test was used to compare CRVO and BRVO eyes. Pearson correlation coefficient was used to evaluate the association between BCVA (logMAR) and OCTA parameters. Univariate linear regression analysis and stepwise multivariate linear regression analyses were

performed to identify the most associated parameters to BCVA.

## RESULTS

A total of 70 eyes of 35 patients with unilateral RVO were examined. Nine patients presented with a CRVO, 2 with an HCRVO, and 24 with a BRVO. For statistical purposes, CRVO and HCRVO eyes were analyzed together in the CRVO subgroup. The mean age was  $62.5 \pm 9.3$  years (range, 44–79 years), and twenty patients (57%) were male. Eighteen eyes (51%) were treatment naïve, and 17 eyes had previously been treated with anti-VEGF injections and/or laser photocoagulation. The median period between the onset of RVO and inclusion in the study was 4 months (range, 0.5–24 months). The mean BCVA was  $0.8 \pm 0.45$  logMAR (Snellen, 20/125) in eyes with RVO and was  $0.1 \pm 0.08$  logMAR (Snellen, 20/25) in fellow eyes.

Demographic and clinical data of our study patients are summarized in Table 1.

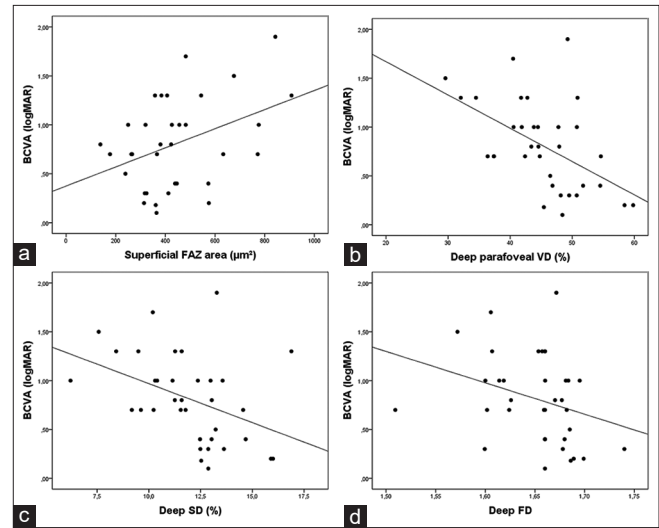
Central macular edema was noted in 21 eyes with RVO (71%). The mean CRT was  $411 \pm 190$   $\mu$ m (range, 160–829  $\mu$ m) in eyes with RVO and  $247 \pm 26$   $\mu$ m (range, 197–285  $\mu$ m) in fellow eyes. Twenty-two (63%) of the 35 RVO eyes had EZ disruption at the fovea.

The mean area of full slab, superficial, and deep FAZ in eyes with RVO was significantly larger than in fellow eyes ( $P < 0.001$ ,  $P = 0.007$ , and  $P = 0.006$ , respectively).

In both networks, RVO eyes demonstrated lower mean foveal VD, parafoveal VD, total VD, SD, and FD compared to the unaffected fellow eyes ( $P < 0.002$ ). VDI and LAC were significantly higher ( $P < 0.003$ ) in eyes with RVO than in contralateral eyes [Table 2 and Figure 2].

Eyes with BRVO demonstrated higher mean parafoveal VD, total VD, and SD compared to eyes with CRVO in the SCP ( $P = 0.013$ ,  $P = 0.013$ , and  $P = 0.004$ , respectively), and DCP ( $P = 0.002$ ,  $P = 0.003$ , and  $P = 0.005$ , respectively). None of the other microvascular parameters were significantly different between these two subgroups [Table 2].

An increased CRT and an EZ disruption at the fovea were significantly correlated with a poor BCVA in the univariate ( $P = 0.035$ ,  $r = 0.357$  and  $P < 0.001$ ,  $r = 0.634$ ,



**Figure 3:** Correlation between best corrected visual acuity (logMAR) and optical coherence tomography angiography parameters in eyes with retinal vein occlusion. Scatterplots show a significant correlation between visual acuity (logMAR) and superficial foveal avascular zone area (a) and a significant inverse correlations between visual acuity (logMAR) and parafoveal vascular density (b), skeleton density (c), and fractal dimension (d) in the deep capillary plexus

**Table 1: Demographic and clinical characteristics of patients with retinal vein occlusion**

	All RVO (n=35)	Subgroups	
		CRVO (n=11)	BRVO (n=24)
Mean age (years±SD)	62.5±9.3	63.3±10.6	62.5±9.2
Male/female (n)	20/15	7/4	13/11
Comorbidities (%)			
Hypertension	77	54	88
Diabetes	46	46	46
Dyslipidemia	29	27	29
Glaucoma	40	37	42
Follow-up period, months (range)	4 (0.5-8)	4 (0.5-12)	6 (0.5-24)
Prior treatments (%)			
Treatment naïve	18 (51)	4 (36)	14 (58)
Anti-VEGF injection	5 (14)	1 (9)	4 (17)
Laser	3 (9)	1 (9)	2 (8)
Anti-VEGF + laser	9 (26)	5 (46)	4 (17)
BCVA, logMAR	0.8	0.97	0.74
Snellen visual acuity	20/125	20/160	20/100

RVO: Retinal vein occlusion, BRVO: Branch RVO, CRVO: Central RVO, VEGF: Vascular endothelial growth factor, BCVA: Best corrected visual acuity, SD: Standard deviation



**Table 2: Comparison of visual acuity and optical coherence tomography angiography parameters between eyes with retinal vein occlusion and unaffected fellow eyes and between eyes with central retinal vein occlusion and eyes with branch retinal vein occlusion**

	RVO versus fellow eyes			CRVO versus BRVO		
	RVO	Fellow eyes	P	CRVO	BRVO	P
BCVA, logMAR	0.8±0.45	0.1±0.08	<0.001*	0.97±0.4	0.74±0.47	0.134
Snellen visual acuity	20/125	20/25		20/160	20/100	
Full slab FAZ area (mm <sup>2</sup> )	0.53±0.24	0.32±0.12	<0.001*	0.55±0.35	0.51±0.18	0.65
Superficial capillary plexus						
Area of the FAZ (mm <sup>2</sup> )	0.56±0.41	0.32±0.11	0.007*	0.61±0.6	0.46±0.18	0.57
Foveal vascular density (%)	17.69±7.32	22.53±6.04	0.001*	15.07±7.05	18.09±7.26	0.17
Parafoveal vascular density (%)	37.67±7.97	42.8±5.97	0.001*	32.33±8.83	40.11±6.32	0.013*
Total vascular density (%)	35.36±7.38	40.28±5.73	0.001*	30.41±8.47	37.62±5.67	0.013*
SD (%)	10.61±2.26	12.71±1.68	<0.001*	8.96±2.5	11.36±1.72	0.004*
Fractal dimension	1.67±0.03	1.69±0.01	<0.001*	1.65±0.04	1.68±0.02	0.088
Vessel density index	3.34±0.16	3.17±0.12	<0.001*	3.39±0.12	3.32±0.18	0.219
Lacunarity	0.37±0.05	0.34±0.01	<0.001*	0.38±0.48	0.37±0.05	0.5
Deep capillary plexus						
Area of the FAZ (mm <sup>2</sup> )	0.89±0.62	0.43±0.14	0.006*	0.97±1.1	0.76±0.33	0.42
Foveal vascular density (%)	13.09±8.08	18.59±9.74	0.002*	15.54±8.53	11.98±6.67	0.42
Parafoveal vascular density (%)	44.5±8.09	63.01±11.65	<0.001*	39.21±7.59	46.98±7.21	0.002*
Total vascular density (%)	40.97±7.35	59.5±4.8	<0.001*	36.38±6.78	43.08±6.72	0.003*
SD (%)	11.95±2.32	17.81±1.52	<0.001*	10.46±1.91	12.63±2.20	0.005*
Fractal dimension	1.65±0.03	1.70±0.02	<0.001*	1.63±0.05	1.66±0.04	0.063
Vessel density index	3.44±0.17	3.34±0.06	0.003*	3.47±0.15	3.43±0.18	0.36
Lacunarity	0.48±0.1	0.34±0.02	<0.001*	0.49±0.08	0.47±0.11	0.5

\*Statistically significant value. Data are expressed as mean±SD. RVO: Retinal vein occlusion, BRVO: Branch RVO, CRVO: Central RVO, BCVA: Best corrected visual acuity, SD: Skeleton density, FAZ: Foveal avascular zone, SD: Standard deviation

respectively) and multivariate ( $P = 0.019$ ,  $r = 0.292$  and  $P < 0.001$ ,  $r = 0.637$ , respectively) analysis [Table 3].

The univariate linear regression analysis showed that in the SCP, the area of FAZ remained positively correlated with BCVA logMAR ( $P = 0.025$ ,  $r = 0.378$ ) but not in the full slab ( $P = 0.791$ ). In the DCP, the BCVA (logMAR) was negatively correlated with parafoveal VD ( $P = 0.004$ ,  $r = -0.472$ ), total VD ( $P = 0.015$ ,  $r = -0.407$ ), SD ( $P = 0.003$ ,  $r = -0.482$ ), and FD ( $P = 0.036$ ,  $r = -0.308$ ).

Stepwise multivariate linear regression analysis was performed using the significant factors obtained from the univariate analysis. The correlations between BCVA and deep SD ( $P = 0.04$ ,  $r = -0.261$ ) and deep FD [ $P = 0.032$ ,  $r = -0.264$ , Figure 3] remained significant [Table 3].

## DISCUSSION

In this study, we aimed to provide objective and reliable OCTA parameters that quantify FAZ area, capillary density (VD, SD), and vessel morphology (FD, VDI, LAC) and to identify their correlations with BCVA. We showed a significantly larger FAZ, lower VD, lower SD, lower FD, higher VDI, and higher LAC in both superficial and deep vascular networks in eyes with RVO compared to fellow eyes. The FAZ area in the SCP and VD, SD, and FD in the DCP were significantly correlated to BCVA. We demonstrated,

for the first time, that deep SD and deep FD were the most important predictor of visual acuity.

Several studies have already demonstrated that OCTA is a very effective imaging tool that allows a segmented evaluation of the FAZ and the parafoveal capillary networks in eyes with RVO.<sup>7,19</sup> Using this technology, we found a significant superficial and deep FAZ enlargement in eyes with RVO compared with fellow eyes with a more pronounced enlargement in the DCP. These results are in agreement with previous papers where a FAZ enlargement was reported in both networks.<sup>7,19,20</sup> Other authors stated that only the area of deep FAZ in eyes with RVO was significantly larger compared to contralateral eyes.<sup>10,21</sup> This may be explained by the DCP vulnerability to ischemic changes compared to the SCP, as suggested by Coscas *et al.*<sup>6</sup>

This FAZ enlargement in eyes with RVO reflects macular ischemia and could be a reliable biomarker of visual impairment. We found that a larger FAZ area was significantly correlated with a poorer BCVA in the SCP, which is consistent with Casselholmde *et al.*<sup>20</sup> and Kang *et al.*<sup>21</sup> findings. Some studies reported this correlation only in the DCP,<sup>10</sup> or in both the SCP and the DCP.<sup>22</sup> This controversy must be interpreted with caution because OCTA images are subject to numerous artifacts, including segmentation errors projection artifacts from inner retinal vessels onto deeper vascular network and presence of blood in different retinal layers in RVO patients, which could distort results.<sup>23</sup>

**Table 3: Univariate and stepwise multivariate regression analysis of the correlation between best corrected visual acuity and optical coherence tomography angiography parameters in eyes with retinal vein occlusion**

	Univariate linear regression			Multivariate linear regression	
	R <sup>2</sup>	Regression coefficient	P	Regression coefficient	P
OCT findings					
Ellipsoid zone disruption	0.402	0.634	<0.001*	0.637	<0.001*
CRT	0.127	0.357	0.035*	0.292	0.019*
Superficial capillary plexus					
Area of the FAZ	0.143	0.378	0.025*	0.136	0.304
Parafoveal VD	0.045	-0.213	0.22	-0.074	0.574
Total VD	0.063	-0.251	0.15	-0.08	0.545
SD	0.08	-0.283	0.1	-0.137	0.29
Fractal dimension	0.108	-0.329	0.054	-0.152	0.254
Vessel diameter index	0.039	0.199	0.25	0.22	0.071
Lacunarity	0.104	0.305	0.057	0.173	0.181
Deep capillary plexus					
Area of the FAZ	0.062	0.25	0.191	0.126	0.375
Parafoveal VD	0.223	-0.472	0.004*	-0.247	0.058
Total VD	0.166	-0.407	0.015*	-0.207	0.107
SD	0.233	-0.482	0.003*	-0.261	0.04*
Fractal dimension	0.095	-0.308	0.036*	-0.264	0.032*
Vessel diameter index	0.007	-0.086	0.622	-0.059	0.69
Lacunarity	0.084	0.289	0.092	0.233	0.087

\*Statistically significant value. OCT: Optical coherence tomography, FAZ: Foveal avascular zone, VD: Vascular density, CRT: Central retinal thickness, SD: Skeleton density

To quantify capillary perfusion, we measured VD, which represents the proportion of area occupied by vessels, and SD, which represents the length of the entire retinal vascular network independently of vessel caliber. Our results showed significantly decreased vascular and skeleton densities in SCP and DCP of eyes with RVO compared to fellow eyes except the VD in the avascular foveal region. These findings have been reported by previous studies when comparing eyes with RVO to fellow eyes or to healthy controls.<sup>21,24,25</sup>

On the other hand, we found a significantly lower VD and SD in eyes with CRVO compared to eyes with BRVO, as reported by Koullis *et al.*<sup>25</sup> in a retrospective cross-sectional study including 14 patients with CRVO and 20 patients with BRVO. These results might be related to the higher intraocular VEGF levels in eyes with CRVO than in eyes with BRVO.<sup>8</sup> It has been demonstrated that VEGF released by hypoxic retinal tissue plays a major role in damaging the retinal vessel wall and inducing capillary occlusions.<sup>26</sup>

As previously described, superficial and deep capillary networks in eyes with RVO are the site of microvascular changes including irregular nonperfusion areas, vascular congestion, and capillary abnormalities.<sup>23,27</sup> In our study, we translated these qualitative abnormalities into quantitative parameters: decreased FD (vessel complexity), increased LAC (structure nonuniformity), and increased VDI (vessel diameter) in both the superficial and deep networks. Our results are in agreement with a recent research by Cabral *et al.*<sup>28</sup> who analyzed FD and LAC in 48 eyes with RVO. The authors also reported a positive linear association

between LAC and peripheral nonperfusion areas on FA. They suggested that OCTA may help in identifying RVO eyes with increased LAC which are at high risk of neovascular complications.

As found by Koullis *et al.*,<sup>25</sup> we demonstrated that the vasculature branching complexity (FD) was lower in eyes with CRVO compared to eyes with BRVO without significant difference. These results suggest that capillary morphology measured in the macular region could be useful in quantifying disease severity in RVO and therefore require greater attention in future clinical studies.

By studying the relationship between visual acuity and OCTA parameters, we demonstrated that macular ischemia was involved in visual impairment in eyes with RVO. We found a highly negative correlation between BCVA and deep VD, deep SD, and deep FD. After stepwise multivariate linear regression, only low SD and low FD in the DCP remained significantly associated with poor visual acuity.

It is easily understandable that these OCTA parameters, which theoretically reflect the degree of macular nonperfusion, would be associated with visual function.

In fact, decreased VD may result from either low perfusion flow or capillary rarefaction, while decreased SD and decreased FD are due to capillary dropout.

In eyes with RVO, capillary dropout can be associated with compensatory vessel dilatation, which will lead to a more pronounced decrease in SD and FD than VD. This explains

that SD and FD in the DCP could be the best predictive factors for BCVA in eyes with RVO.

To the best of our knowledge, this is the first research that identified SD and FD as new OCTA biomarkers to predict visual function in eyes with RVO. The preservation of capillary perfusion and morphology in the DCP seems to be primordial for better visual acuity in RVO. Further research with larger sample size is needed to confirm and explain these correlations.

We did not find a correlation between visual acuity and these microvascular parameters in the SCP. This can be explained by the more vulnerability of the DCP to retinal ischemia.<sup>6</sup> Some authors reported these correlations in both superficial and deep networks.<sup>9,10,24,29</sup> This discrepancy may be related to the different segmentation and measurement methods and to the different inclusion criteria between these studies.

Our study has several limitations. First, our sample was heterogeneous including treated and naïve RVO patients, with and without associated CME. The presence of CME may affect the OCTA metrics. Second, it was a cross-sectional design so that longitudinal vascular changes and visual acuity progression could not be assessed. Third, we included patients with systemic comorbidities such as hypertension and atherosclerosis, which might affect the capillary networks interfering with our results. Although we excluded poor-quality scans, many projected artifacts and segmentation errors could distort the OCTA measurements. Finally, the exclusion of patients with poor fixation during OCTA acquisition due to poor visual acuity may have biased our study.

In conclusion, our study described quantified OCTA parameters in order to characterize macular microvasculature in eyes with RVO and to evaluate its impact on visual acuity. Compared to fellow eyes, eyes with RVO showed larger FAZ, decreased VD and SD, decreased branching complexity (FD), and increased VDI and LAC. We suggest that SD and FD in the DCP could be new OCTA biomarkers to predict visual function in eyes with RVO. Future longitudinal studies are necessary before making any definite conclusions.

### Financial support and sponsorship

Nil.

### Conflicts of interest

There are no conflicts of interest.

## REFERENCES

- Rogers S, McIntosh RL, Cheung N, Lim L, Wang JJ, Mitchell P, *et al.* The prevalence of retinal vein occlusion: Pooled data from population studies from the United States, Europe, Asia, and Australia. *Ophthalmology* 2010;117:313-9.e1.
- Murakami T, Tsujikawa A, Miyamoto K, Sakamoto A, Ota M, Ogino K, *et al.* Relationship between perifoveal capillaries and pathomorphology in macular oedema associated with branch retinal vein occlusion. *Eye (Lond)* 2012;26:771-80.
- Noma H, Funatsu H, Harino S, Nagaoka T, Mimura T, Hori S. Influence of macular microcirculation and retinal thickness on visual acuity in patients with branch retinal vein occlusion and macular edema. *Jpn J Ophthalmol* 2010;54:430-4.
- Coscas G, Loewenstein A, Augustin A, Bandello F, Battaglia Parodi M, Lanzetta P, *et al.* Management of retinal vein occlusion – Consensus document. *Ophthalmologica* 2011;226:4-28.
- Kashani AH, Lee SY, Moshfeghi A, Durbin MK, Puliafito CA. Optical coherence tomography angiography of retinal venous occlusion. *Retina* 2015;35:2323-31.
- Coscas F, Glacet-Bernard A, Miere A, Caillaux V, Uzzan J, Lupidi M, *et al.* Optical coherence tomography angiography in retinal vein occlusion: Evaluation of superficial and deep capillary plexa. *Am J Ophthalmol* 2016;161:160-71.e1.
- Rispoli M, Savastano MC, Lumbroso B. Capillary network anomalies in branch retinal vein occlusion on optical coherence tomography angiography. *Retina* 2015;35:2332-8.
- Suzuki N, Hirano Y, Yoshida M, Tomiyasu T, Uemura A, Yasukawa T, *et al.* Microvascular abnormalities on optical coherence tomography angiography in macular edema associated with branch retinal vein occlusion. *Am J Ophthalmol* 2016;161:126-32.e1.
- Seknazi D, Coscas F, Sellam A, Rouimi F, Coscas G, Souied EH, *et al.* Optical coherence tomography angiography in retinal vein occlusion: Correlations between macular vascular density, visual acuity, and peripheral nonperfusion area on fluorescein angiography. *Retina* 2018;38:1562-70.
- Samara WA, Shahlace A, Sridhar J, Khan MA, Ho AC, Hsu J. Quantitative optical coherence tomography angiography features and visual function in eyes with branch retinal vein occlusion. *Am J Ophthalmol* 2016;166:76-83.
- Stanga PE, Tsamis E, Papayannis A, Stringa F, Cole T, Jalil A. Swept-source optical coherence tomography Angio™ (Topcon Corp, Japan): Technology review. *Dev Ophthalmol* 2016;56:13-7.
- Spaide RF, Curcio CA. Evaluation of segmentation of the superficial and deep vascular layers of the retina by optical coherence tomography angiography instruments in normal eyes. *JAMA Ophthalmol* 2017;135:259-62.
- Uji A, Balasubramanian S, Lei J, Baghdasaryan E, Al-Sheikh M, Satta SR. Impact of multiple en face image averaging on quantitative assessment from optical coherence tomography angiography images. *Ophthalmology* 2017;124:944-52.
- Reif R, Qin J, An L, Zhi Z, Dziennis S, Wang R. Quantifying optical microangiography images obtained from a spectral domain optical coherence tomography system. *Int J Biomed Imaging* 2012;2012:509783.
- Gadde SG, Anegondi N, Bhanushali D, Chidambara L, Yadav NK, Khurana A, *et al.* Quantification of vessel density in retinal optical coherence tomography angiography images using local fractal dimension. *Invest Ophthalmol Vis Sci* 2016;57:24652.
- Kim AY, Chu Z, Shahidzadeh A, Wang RK, Puliafito CA, Kashani AH. Quantifying microvascular density and morphology in diabetic retinopathy using spectral-domain optical coherence tomography angiography. *Invest Ophthalmol Vis Sci* 2016;57:T362-70.
- Lopes R, Betrouni N. Fractal and multifractal analysis: A review. *Med Image Anal* 2009;13:634-49.
- Smith TG, Lange GD, Marks WB. Fractal methods and results in cellular morphology – Dimensions, lacunarity and multifractals. *J Neurosci Methods* 1996;69:123-36.
- Wons J, Pfau M, Wirth MA, Freiberg FJ, Becker MD, Michels S. Optical coherence tomography angiography of the foveal avascular zone in retinal vein occlusion. *Ophthalmologica* 2016;235:195-202.
- Casselholmde Salles M, Kvanta A, Amrén U, Epstein D. Optical coherence tomography angiography in central retinal vein occlusion: Correlation between the foveal avascular zone and visual acuity. *Invest Ophthalmol Vis Sci* 2016;57:T242-6.
- Kang JW, Yoo R, Jo YH, Kim HC. Correlation of microvascular structures on optical coherence tomography angiography with visual acuity in retinal vein occlusion. *Retina* 2017;37:1700-9.
- Wakabayashi T, Sato T, Hara-Ueno C, Fukushima Y, Sayanagi K, Shiraki N, *et al.* Retinal microvasculature and visual acuity in eyes with branch retinal vein occlusion: Imaging analysis by optical coherence tomography angiography. *Invest Ophthalmol Vis Sci* 2017;58:2087-94.
- Spaide RF, Fujimoto JG, Waheed NK. Image artifacts in optical coherence tomography angiography. *Retina* 2015;35:2163-80.

24. Wang Q, Chan SY, Yan Y, Yang J, Zhou W, Jonas JB, *et al.* Optical coherence tomography angiography in retinal vein occlusions. *Graefes Arch Clin Exp Ophthalmol* 2018;256:1615-22.
25. Koullis N, Kim AY, Chu Z, Shahidzadeh A, Burkemper B, Olmos de Koo LC, *et al.* Quantitative microvascular analysis of retinal venous occlusions by spectral domain optical coherence tomography angiography. *PLoS One* 2017;12:e0176404.
26. Campochiaro PA, Bhisitkul RB, Shapiro H, Rubio RG. Vascular endothelial growth factor promotes progressive retinal nonperfusion in patients with retinal vein occlusion. *Ophthalmology* 2013;120:795-802.
27. Adhi M, Filho MA, Louzada RN, Kuehlewein L, de Carlo TE, Bauml CR, *et al.* Retinal capillary network and foveal avascular zone in eyes with vein occlusion and fellow eyes analyzed with optical coherence tomography angiography. *Invest Ophthalmol Vis Sci* 2016;57:T486-94.
28. Cabral D, Coscas F, Glacet-Bernard A, Pereira T, Geraldes C, Cachado F, *et al.* Biomarkers of peripheral nonperfusion in retinal venous occlusions using optical coherence tomography angiography. *Transl Vis Sci Technol* 2019;8:7.
29. Sellam A, Glacet-Bernard A, Coscas F, Miere A, Coscas G, Souied EH. Qualitative and quantitative follow-up using optical coherence tomography angiography of retinal vein occlusion treated with anti-VEGF: Optical Coherence Tomography Angiography Follow-up of Retinal Vein Occlusion. *Retina*. 2017;37:1176-1184.