

# Limits of Surgical Resection for Bile Duct Cancer

Fabian Bartsch Stefan Heinrich Hauke Lang

General, Visceral and Transplant Surgery, Johannes Gutenberg-University Hospital of Mainz, Mainz, Germany

## Keywords

Perihilar cholangiocarcinoma · Bile duct cancer · Klatskin tumor · Resectability · Surgery · Limits

## Summary

**Introduction:** Perihilar cholangiocarcinoma is the most frequent cholangiocarcinoma and poses difficulties in preoperative evaluation. For its therapy, often major hepatic resections as well as resection and reconstruction of the hepatic artery or the portal vein are necessary. In the last decades, great advances were made in both the surgical procedures and the perioperative anesthetic management. In this article, we describe from our point of view which facts represent the limits for curative (R0) resection in perihilar cholangiocarcinoma. **Methods:** Retrospective data of a 6-year period (2008–2014) was collected in an SPSS 22 database and further analyzed with focus on the surgical approach and the postoperative as well as histological results. **Results:** Out of 96 patients in total we were able to intend a curative resection in 73 patients (76%). In 58/73 (79.5%) resections an R0 situation could be reached (R1 n = 14; R2 n = 1). 23 patients were irresectable because of peritoneal carcinosis (n = 8), broad infiltration of major blood vessels (n = 8), bilateral advanced tumor growth to the intrahepatic bile ducts (n = 3), infiltration of the complete liver hilum (n = 2), infiltration of the gallbladder (n = 1), and liver cirrhosis (n = 1). Patients with a T4 stadium were treated with curative intention twice, and in each case an R1 resection was achieved. Most patients with irresectable tumors can be suspected to have a T4 stadium as well. In a T3 situation (n = 6) we could establish five R0 resections and one R1 resection. **Conclusion:** The limit of surgical resection for bile duct cancer is the advanced tumor stage (T stadium). While in a T3 stadium an R0 resection is possible in most cases, we were not able to perform an R0 resection in a T4 stadium. From our point of view, early T stadium cannot usually be estimated through expanded diagnostics but only through surgical exploration.

## Introduction

The perihilar cholangiocarcinoma (Klatskin tumor) is the most common type of cholangiocarcinomas. The attending physician is confronted with difficulties in clinical diagnosis, preoperative staging, and surgical therapy due to the location of this kind of tumor in the liver hilum within striking distance to the portal vein and the hepatic artery. It is a rare entity which was deemed as irresectable for a long time. After its first description by Altmeier et al. [1] in 1957 the name ‘Klatskin tumor’ appeared because of a publication of Gerald Klatskin in 1965 [2]. Bismuth and Corlette created the famous classification of the localization of perihilar cholangiocarcinomas (type I–IV) and gave insights in resection strategies [3, 4]. With further developments in the perioperative management as well as in (liver) surgery, perihilar cholangiocarcinomas were also treated with a curative intention. Starting with the resection of the perihilar bile ducts, the dimension of resections developed from an extension through partial liver resections and (extended) hemihepatectomy to mesohepatectomy and further to liver transplantation [5–9]. These surgical procedures are connected with a high level of complications such as bile leakage, septic constellations, and, rarely, liver failure or mortality.

Irresectability is present if the tumor spreads bilaterally to the segmental bile ducts or if the blood vessels are infiltrated bilaterally. Further small-for-size situations with tumor affection of the segmental bile ducts or blood vessels of the necessarily spared bigger liver remnant can be problematic regarding a curative resection [8]. Many different procedures such as endoscopic retrograde cholangiography (ERC), magnetic resonance tomography (MRT) with cholangiography (MRC), computed tomography (CT), positron emission tomography-computed tomography (PET-CT), or percutaneous transhepatic cholangiography (PTC) are used for the preoperative definition of tumor extension in terms of resection planning. However, even in patients who underwent nearly all of these procedures, the tumor is overvalued in up to 30% and still difficult to be estimated correctly. DeOliveira et al. [10] developed a new staging system by means of a categorization of the tumor spread to the portal vein, the liver artery, and the bile duct (similar to the

**Table 1.** Overview of the performed resections and the connected T, N, and R stadium (TNM classification of the Union for International Cancer Control (UICC), ed 7, 2010). No extensions of resection had to be performed. Resections and/or reconstructions of blood vessels are listed as well

Resection	n	T stadium					N stadium				R stadium			Extension of resection	Resection/Reconstruction blood vessels
		T1	T2a	T2b	T3	T4	N0	N1	N2	Nx	R0	R1	R2		
Right hepatectomy	16	1	3	11	1	–	13	3	–	–	10	6	–	no	VC 1 - MHV 0 - PV 5 - HA 1
Extended right hepatectomy	15	2	3	9	1	–	11	4	–	–	15	–	–	no	VC 1 - MHV 0 - PV 7 - HA 0
Left hepatectomy	23	2	1	16	3	1	15	5	–	3	19	3	1	no	VC 0 - MHV 5 - PV 7 - HA 2
Extended left hepatectomy	6	–	–	5	1	–	2	4	–	–	3	2	1	no	VC 0 - MHV 0 - PV 1 - HA 1
Mesohepatectomy	1	–	–	1	–	–	–	1	–	–	1	–	–	no	VC 0 - MHV 0 - PV 0 - HA 0
Bisegmentectomy	3 <sup>a</sup>	–	–	1	–	1	1	–	–	1	2	1	–	no	–
Monosegmentectomy	2 <sup>a</sup>	–	1	1	–	–	1	1	–	–	2	–	–	no	–
Resection of extrahepatic bile duct	6	–	5	1	–	–	6	–	–	–	5	1	–	no	–

<sup>a</sup>Once a resection of tumor recurrence is included with neither Bismuth-Corlette type nor T or N status.

VC = Vena cava; MHV = major hepatic vein; PV = portal vein; HA = hepatic artery.

Bismuth and Corlette classification) based on MRT, CT, PET-CT, ERC, and PTC imaging for an earlier ascertainment of irresectability and established a registry. In most cases an exploration has to be performed for a precise estimation of the tumor expansion. Laparoscopy as a first step can help to exclude peritoneal carcinosis or superficial liver metastasis.

In this article we present our data and results of 96 patients who underwent a surgical exploration (and often also resection) in order to outline which facts are the limit for curative surgical (R0) resection in perihilar cholangiocarcinoma from our point of view.

### Bile Duct Cancer in 96 Patients: Surgical Exploration and Resection

Retrospective data of a 6-year period (2008–2014) from patients who underwent at least a surgical exploration was collected in an SPSS 22 database and further analyzed with special emphasis on the surgical approach as well as the postoperative course and histological results. We focused on the kind of resection, reasons for irresectability, extensions of resection (e.g. partial resection and reconstruction of the portal vein or hepatic artery), the Bismuth-Corlette classification, and especially the postoperative TNM (tumor – node – metastasis) classification. Patients who did not undergo surgery were excluded. Liver transplantations were not performed at our center because of restrictions of Eurotransplant and the country of Germany. Tumor recurrence operations with intended liver resection (4 cases) as well as one case with extrahepatic manifestation of metastasis were also included in our database. In 4/5 cases a right hemihepatectomy had been performed before, while a bile duct resection with biliodigestive anastomosis had been carried out once.

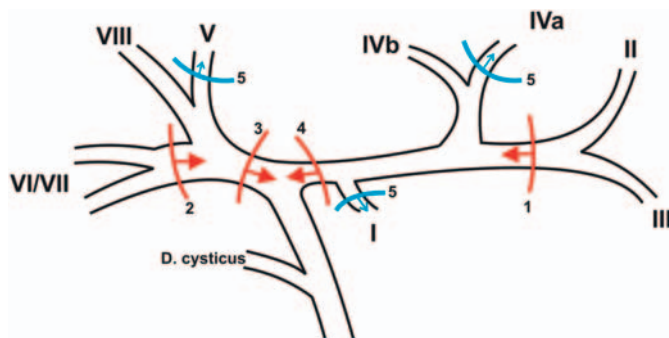
Resections were performed by different surgeons using different techniques for tissue dissection. All resections included dissection

of the regional lymph nodes in the Ligamentum hepatis and the upper edge of the pancreas. High serum bilirubin because of cholestasis was lowered through preoperative stenting (ERC) or percutaneous transhepatic cholangio-drainage (PTCD). In case peritoneal carcinosis or a very advanced tumor stage was detected, a palliative biliary bypass was considered if technically possible. In one patient, an extension of resection was necessary due to an infiltration of the diaphragm and pericardium in a recurrence situation.

### Results

From 2008 to 2014 we indicated 96 patients for exploration because of a perihilar cholangiocarcinoma. In our preoperative evaluation either a CT scan or an MRT was necessary. We would like to point out that we did not include patients in our database which were not indicated for a surgical exploration. Thus, we are not able to provide a precise percentage or total number of patients who were in a palliative situation at initial diagnosis for our center. From our point of view, it is very important that all patients are discussed in an interdisciplinary tumor conference of a specialized center and should generally be presented to an experienced hepatobiliary surgeon for evaluation of a surgical intervention even if irresectability is suspected. In most of the cases a surgical exploration should be performed since it presents the only way of evaluating for sure if resection is possible.

Out of the 96 patients, 61 (63.5%) were male and 35 (36.5%) were female. In our database we also recorded 5 patients with recurrence of perihilar cholangiocarcinoma. In 6 cases, a clear classification according to Bismuth and Corlette was not possible pre- and postoperatively. Twice we found a perihilar cholangiocarcinoma as a double tumor, i.e. once with an extrahepatic cholangiocarcinoma of the cystic duct and once with a carcinoma of the gallbladder. Most of our patients were classified as type IV (n = 54).



**Fig. 1.** Presentation of the intrahepatic and partial extrahepatic bile ducts with their subdivision into the segmental bile ducts. The red lines are representing the resection sites (1–4) for major hepatectomies. The arrows indicate the resected parts of the liver. 1) Extended right hemihepatectomy – remaining liver segments II + III; 2) extended left hemihepatectomy – remaining liver segments VI + VII; 3) left hemihepatectomy – remaining liver segments I + II + III + IV; 4) right hemihepatectomy – remaining liver segments V + VI + VII + VIII. The blue lines (5) are showing the Taj Mahal technique with resection along the root of the middle hepatic vein including the segments IVa + V (often also Sg. I) – remaining liver segments II + III + IVb + VI + VII + VIII. The arrows indicate the resected liver parts.

In 7 cases we dealt with type IIIa and 13 times with type IIIb. 5 patients were classified as type II, 4 as type I. The classifications were based on the pathological findings. Extensions of resections like additional pancreaticoduodenectomy were not performed in our patients. Only in one case of tumor recurrence we had to resect and partially reconstruct the diaphragm and pericardium due to infiltration.

Table 1 gives an overview regarding the total numbers of our resections with the T, N, and R status as well as the extensions of the resection and also resection or reconstruction of the blood vessels of the liver hilum. In the following, we will focus on the major hepatic resections.

*Left hemihepatectomy* was our most often performed resection in 23 patients. We were able to achieve an R0 resection in 19 cases as well as three R1 resections (2 × type IIb, 1 × type IV (classification according to Bismuth and Corlette)) and one R2 resection (type IIb (classification according to Bismuth and Corlette)). The nodal status was 15 times N0 (N1 n = 5; Nx n = 3). In 10 patients, a resection with reconstruction of major blood vessels had to be performed (5 × major hepatic vein and/or 7 × portal vein and/or 2 × hepatic artery). *Right hemihepatectomy* was performed 16 times – with ten R0 and six R1 resections (5 × type IIb, 1 × type IIa (classification according to Bismuth and Corlette)). A positive nodal status was found three times with 13 N0 resections. The portal vein was reconstructed in 5 patients, the Vena cava as well as the hepatic artery once.

An *extended right hemihepatectomy* was performed 15 times; all resections were R0. A negative nodal status was established in 11 patients, while 4 patients were N1. Figure 1 provides an overview of the resected as well as of the remaining bile ducts for the different (major) liver resections. Due to the length of the left hepatic bile duct it is obvious why the highest amount of R0 resections was achieved with extended right hemihepatectomy. However, we have

**Table 2.** T and N stadium of the TNM classification of the Union for International Cancer Control (UICC), ed 7, 2010

<b>Primary tumor (T)</b>
Tis – carcinoma in situ
T1 – tumor confined to the bile duct, with extension up to the muscle layer or fibrous tissue
T2a – tumor invades beyond the wall of the bile duct to surrounding adipose tissue
T2b – tumor invades adjacent hepatic parenchyma
T3 – tumor invades unilateral branches of the portal vein or hepatic artery
T4 – tumor invades main portal vein or its branches bilaterally; or the common hepatic artery; or the second-order biliary radicals bilaterally; or unilateral second-order biliary radicals with contralateral portal vein or hepatic artery involvement
<b>Regional lymph nodes (N)</b>
N0 – no regional lymph node metastasis
N1 – regional lymph node metastasis (including nodes along the cystic duct, common bile duct, hepatic artery, and portal vein)
N2 – metastasis to periaortic, pericaval, superior mesenteric artery, and/or celiac artery lymph nodes

to keep in mind that this only applies to the bile ducts. In 8 patients, a reconstruction of the major blood vessels had to be performed as well (1 × Vena cava, 7 × portal vein). In 6 patients, we conducted an *extended left hemihepatectomy*. R0 resections were achieved in 3 patients as well as three R1 resections (2 × type IIb, 1 × type III (classification according to Bismuth and Corlette)). The nodal status was only twice N0, while it was N1 four times. The portal vein as well as the hepatic artery had to be reconstructed once. Additionally, one *mesohepatectomy* was performed and an N1R0 status was achieved. No major blood vessels had to be reconstructed.

Further resections such as bi- or monosegmentectomies or resections of the extrahepatic bile duct can be found in table 1.

In 23 patients, we were not able to perform a curative resection. Seven times we decided to perform a high biliary bypass (e.g. segment III hepatojejunostomy) because of the advanced stage of the tumor in order to prevent the patient from complications due to permanent bile duct stenting or to be able to remove a preoperatively placed PTCd and/or a gastroenterostomy because of foreseeable problems in digestion. In the remaining 15 cases only an exploration was performed. The most frequent reason for irresectability was a peritoneal carcinosis (n = 8) followed by infiltration of the Arteria hepatica (n = 5) or infiltration of the portal vein (n = 3) with no possibility of resection or reconstruction, advanced bilateral intrahepatic spread to the bile ducts (n = 3), and wide tumor infiltration of the complete liver hilum (n = 2). Furthermore, we found an infiltration of the gallbladder and a liver cirrhosis once which made a liver resection impossible.

Table 2 shows the tumor classification (T) of the TNM classification of the Union for International Cancer Control (UICC) [11]. While the T1 stadium is limited to the bile duct, the T2 stadium already infiltrates adipose tissue (T2a) or adjacent hepatic tissue (T2b). In a T3 stadium, the hepatic artery or the portal vein are in-

**Table 3.** Overview of the T stadium versus the achieved R and N stadium (TNM classification, ed 7, 2010); at the bottom, the frequencies of types of the Bismuth-Corlette classification are mentioned as well

	T1	T2a	T2b	T3	T4	Tx
N	5	13	45 <sup>a</sup>	6	2	2 <sup>b</sup>
R0	5	11	35	5	–	1
R1	–	2	9	1	2	–
R2	–	–	1	–	–	–
Rx	–	–	–	–	–	1
N0	4	10	28	5	1	–
N1	1	3	13	1	1	–
Nx	–	–	4	–	–	–
Type I	–	1	2	–	–	–
Type II	2	1	2	–	–	–
Type IIIa	–	2	3	2	–	–
Type IIIb	1	1	9	1	–	–
Type IV	2	8	26	3	2	–

<sup>a</sup>Twice double tumor; once tumor recurrence.  
<sup>b</sup>Twice tumor recurrence.

filtrated unilaterally. The T4 stadium is an advanced form with different possibilities (table 2); hence, it becomes obvious why a curative resection is very difficult in these cases. In table 3 we provide an overview of the T stadium and offer a better look into its relation to the R and N stadium as well as the Bismuth-Corlette classification. Most patients were in a T2b stadium (n = 45). Regarding the Bismuth-Corlette classification, 41 patients had a type IV situation.

Since there are interesting differences to be found in the results published in other articles, we will now discuss our data in comparison to the literature. Nagino et al. [12], for example, reviewed 574 patients who underwent resections of perihilar cholangiocarcinomas over a 34-year period. Out of these 574 resections, 300 patients with a T4 stadium are mentioned. In total, 439 R0 resections could be performed; i.e., a lot of patients with a T4 stadium had to be resected curatively. This differs a lot from our experience. Independently, the authors could show that N0R0 resections were associated with a good and any N1 stadium with a poor survival. DeOliveira et al. [13] reviewed resections of cholangiocarcinomas in general over a 31-year period. 281 out of 564 patients dealt with a perihilar cholangiocarcinoma and 174 (62%) were resected. An R0 resection could be achieved in 81%, which is comparable to our series. Unfortunately, the T stadium is not further mentioned as the authors especially focused on survival; however, in 2007, the 7th edition of the UICC TNM classification had not yet been published and so the data would be difficult to compare. They were also able to show that an R0 or N0 resection as well as a smaller tumor size or better differentiation are correlated with a better survival. De Jong et al. [14] reported on 305 cases that underwent resection with a curative intention. The number of T3 and T4 sta-

dium combined was 155, whereas T4 stadium alone was not mentioned. Overall they were able to achieve an R0 resection in 197 of 305 cases (64.6%). Neuhaus et al. [15] published very interesting results in a comparison of the 'hilar en bloc resection', which is an extended right hepatectomy with obligatory resection and reconstruction of the bifurcation of the portal vein to gain a no-touch technique of the tumor, versus conventional hepatectomy [15]. In total, 100 patients were included (50 in each group), and a requirement for inclusion was an R0 resection. Similar to our results, Neuhaus et al. [15] reported about only 3 patients in both groups with a T4 stadium (3%), while 68 were T3, 27 were T2, and 2 were T1. These results are comparable to ours and show that a curative resection in a T4 stadium is rarely achievable. Due to patient selection and study design no statement can be made regarding irresectability and how many patients with a T4 stadium were resected in a curative intention without achieving an R0 resection. Juntermanns et al. [16] compared the 6th and the 7th edition of the TNM classification as well as the associated survival in 195 patients who underwent resections because of perihilar cholangiocarcinomas. They report on 52 patients with a T4 stadium (7th edition) with only a short median survival of 7.8 months; however, the R status is not mentioned at all.

## Conclusion

Our data shows that the limit of surgical resection for bile duct cancer is the advanced stage of the tumor (T stadium). While in a T3 stadium a R0 resection was possible in most cases, we were not able to perform an R0 resection in a T4 stadium. Compared to other articles, the data is not completely conclusive. While Neuhaus et al. [15] reported on comparable results in 2012, the data of Nagino et al. [12] from 2013 differs from our findings. Other analyses with many cases focus on survival and often do not mention the number of R0 resections of patients with T4 stadium. Further observation and comparison is necessary to confirm our data. Because of its definition in the UICC TNM classification (7th edition) [11], a T4 stadium is present even if the tumor invades the main portal vein. An R0 resection can sometimes be achieved by means of a resection and reconstruction of the portal vein, even in a T4 stadium. From our point of view, the T stadium cannot be estimated through expanded preoperative diagnostics but only through surgical exploration. In consequence, patients suffering from perihilar cholangiocarcinoma should generally be presented to the surgical department for evaluation of a surgical intervention even if irresectability is suspected.

## Disclosure Statement

There are no conflicts to declare or financial relationships to disclose.

## References

- 1 Altemeier WA, Gall EA, Zininger MM, Hoxworth PI: Sclerosing carcinoma of the major intrahepatic bile ducts. *AMA Arch Surg* 1957;75:450–460; discussion 460–461.
- 2 Klatskin G: Adenocarcinoma of the hepatic duct at its bifurcation within the porta hepatis. An unusual tumor with distinctive clinical and pathological features. *Am J Med* 1965;38:241–256.
- 3 Bismuth H, Corlette MB: Intrahepatic cholangioenteric anastomosis in carcinoma of the hilus of the liver. *Surg Gynecol Obstet* 1975;140:170–178.
- 4 Bismuth H, Nakache R, Diamond T: Management strategies in resection for hilar cholangiocarcinoma. *Ann Surg* 1992;215:31–38.
- 5 Iwatsuki S, Todo S, Marsh JW, Madariaga JR, Lee RG, Dvorchik I, Fung JJ, Starzl TE: Treatment of hilar cholangiocarcinoma (Klatskin tumors) with hepatic resection or transplantation. *J Am Coll Surg* 1998;187:358–364.
- 6 Lang H, Sotiropoulos GC, Malagó M, Broelsch CE: Mesohepatectomy, caudate lobectomy and resection of hilar bifurcation with biliary reconstruction by 6 hepaticojunostomies for Klatskin tumor. *Hepatogastroenterology* 2003;50:1327–1329.
- 7 Lang H, Sotiropoulos GC, Kaiser GM, Molmenti EP, Malagó M, Broelsch CE: The role of liver transplantation in the treatment of hilar cholangiocarcinoma. *HPB (Oxford)* 2005;7:268–272.
- 8 Lang H, Kaiser GM, Zöpf T, Sotiropoulos GC, Frilling A, Malagó M, Broelsch CE: Surgical therapy of hilar cholangiocarcinoma (Article in German). *Chirurg* 2006;77:325–334.
- 9 Neuhaus P, Jonas S, Bechstein WO, Lohmann R, Radke C, Kling N, Wex C, Lobeck H, Hintze R: Extended resections for hilar cholangiocarcinoma. *Ann Surg* 1999;230:808–818; discussion 819.
- 10 DeOliveira ML, Schulick RD, Nimura Y, Rosen C, Gores G, Neuhaus P, Clavien PA: New staging system and a registry for perihilar cholangiocarcinoma. *Hepatology* 2011;53:1363–1371.
- 11 Union for International Cancer Control (UICC): *TNM Classification of Malignant Tumors*, ed 7. New York, Wiley-Liss, 2009.
- 12 Nagino M, Ebata T, Yokoyama Y, Igami T, Sugawara G, Takahashi Y, Nimura Y: Evolution of surgical treatment for perihilar cholangiocarcinoma: a single-center 34-year review of 574 consecutive resections. *Ann Surg* 2013;258:129–140.
- 13 DeOliveira ML, Cunningham SC, Cameron JL, Kamangar F, Winter JM, Lillemoe KD, Choti MA, Yeo CJ, Schulick RD: Cholangiocarcinoma: thirty-one-year experience with 564 patients at a single institution. *Ann Surg* 2007;245:755–762.
- 14 de Jong MC, Marques H, Clary BM, Bauer TW, Marsh JW, Ribero D, Majno P, Hatzaras I, Walters DM, Barbas AS, Mega R, Schulick RD, Choti MA, Geller DA, Barroso E, Mentha G, Capussotti L, Pawlik TM: The impact of portal vein resection on outcomes for hilar cholangiocarcinoma: a multi-institutional analysis of 305 cases. *Cancer* 2012;118:4737–4747.
- 15 Neuhaus P, Thelen A, Jonas S, Puhl G, Denecke T, Veltke-Schlieker W, Seehofer D: Oncological superiority of hilar en bloc resection for the treatment of hilar cholangiocarcinoma. *Ann Surg Oncol* 2012;19:1602–1608.
- 16 Juntermanns B, Sotiropoulos GC, Radunz S, Reis H, Heuer M, Baba HA, Canbay A, Schuler M, Gerken G, Paul A, Kaiser GM: Comparison of the sixth and the seventh editions of the UICC classification for perihilar cholangiocarcinoma. *Ann Surg Oncol* 2013;20:277–284.