



An innovative method of reconstructed penis reduction: a case report

Shin Hyuk Kang^{1^}, Seung Hyun Kang^{1^}, Woo Seob Kim^{1^}, Han Koo Kim^{1^}, Woo Ju Kim^{2^}, Hyeon Seok Kim^{1^}, Tae Hui Bae^{2^}

¹Department of Plastic and Reconstructive Surgery, Chung-Ang University Hospital, Seoul, Korea; ²Department of Plastic and Reconstructive Surgery, Chung-Ang University Gwangmyeong Hospital, Gwangmyeong-si, Korea

Contributions: (I) Conception and design: All authors; (II) Administrative support: Seung Hyun Kang, WS Kim; (III) Provision of study materials or patients: HK Kim, WJ Kim; (IV) Collection and assembly of data: HS Kim; (V) Data analysis and interpretation: Shin Hyuk Kang, TH Bae; (VI) Manuscript writing: All authors; (VII) Final approval of manuscript: All authors.

Correspondence to: Tae Hui Bae, MD, PhD. Department of Plastic and Reconstructive Surgery, Chung-Ang University Gwangmyeong Hospital, 110, Deokan-ro, Gwangmyeong-si, Gyeonggi-do, 14353, Korea. Email: psbth@cau.ac.kr.

Background: Surgery to reduce the size of the reconstructed penis is uncommon. Patients who have undergone total penis reconstruction may want to reduce the size of their reconstructed penis due to convenience issues. To reduce reconstructed penis size, surgical treatment is essential. However, no research has thus far reported on this methodology.

Case Description: A 50-year-old Asian man experienced a nearly total loss of his penis due to trauma 30 years ago. He underwent nearly total penis reconstruction using a tubed abdominal flap. The patient's reconstructed penis showed hypospadias, which caused discomfort during urination. The length of the penis was 17 cm. The patient felt that the reconstructed penis was too large, and a reduction surgery was planned for corrective action. Y-shape incision lines were applied on both lateral sides of the reconstructed penis to reduce the circumference, and curved incision lines were applied on the front and back of the penis to construct the neomeatus and glans of the penis. The incision was made, and the remnant tissue was dissected, with attention paid to avoid damage to the neourethra. After the tissue resection, the neourethra was isolated and resected to fit the height of the penis to construct the neomeatus and correct the hypospadias. An approximation was performed after the reconstructed penis reduction.

Conclusions: Two years after the surgery, there were no complications, such as urethral stricture or fistula, and the patient was satisfied with the shape and size of the reduced penis (9 cm). The surgical reconstructed penis reduction procedure introduced in this case report achieved satisfactory aesthetic and functional results.

Keywords: Penis; phalloplasty; abdominal flap; debulking surgical procedure; case report

Submitted Jul 21, 2022. Accepted for publication Nov 12, 2022.

doi: 10.21037/tau-22-488

View this article at: <https://dx.doi.org/10.21037/tau-22-488>

[^] ORCID: Shin Hyuk Kang, 0000-0001-9868-2019; Seung Hyun Kang, 0000-0002-3039-208X; Woo Seob Kim, 0000-0002-4104-3926; Han Koo Kim, 0000-0002-2849-3973; Woo Ju Kim, 0000-0002-7817-0443; Hyeon Seok Kim, 0000-0002-0142-9314; Tae Hui Bae, 0000-0002-0342-1439.

Introduction

Through total penis reconstruction, patients with penile loss can experience functional, aesthetic, and mental satisfaction (1). Plastic and reconstructive surgeons and urology surgeons have several new challenges in improving phalloplasty. As a result of surgeons' efforts, microsurgical and various surgical techniques have improved, and the range of surgical approaches available has been augmented (2).

Surgery to reduce the size of a reconstructed penis is uncommon. Patients who have undergone nearly total penis reconstruction may want to reduce the size of their reconstructed penis due to convenience issues. To reduce the reconstructed penis size, surgical treatment is essential. However, no research thus far has reported on this methodology.

In this case presentation, we introduce a first-time described method for reducing reconstructed penis size. We present the following article in accordance with the CARE reporting checklist (available at <https://tau.amegroups.com/article/view/10.21037/tau-22-488/rc>).

Case presentation

The patient was a 50-year-old Korean man with no specific medical or family history who visited our clinic with the chief complaint of a large reconstructed penis. He experienced a total loss of his penis due to trauma 30 years ago and underwent nearly total penis reconstruction using a tubed abdominal flap. A penis prosthesis was not implanted during reconstruction (*Figure 1*).

The patient and his sexual partner felt that the reconstructed penis, 17 cm in length, was too large. The patient especially wanted to shorten the length during the reduction. Additionally, the patient's reconstructed penis showed hypospadias, which caused discomfort during urination.

The patient had a sensation in the undamaged proximal area of the penis, which enabled sexual intercourse. Therefore, he wanted to reduce the length rather than improve erectile function.

First, we determined the patient's desired penis length. Considering the average length of Koreans, we had planned to reduce it to 11 cm, but the patient wanted to shorten it to 9 cm instead. Y-shape incision lines were applied on both lateral sides of the penis to reduce its circumference, and curved incision lines were applied on the front and back of

the penis to alter the neomeatus and glans of the penis, as shown in *Figure 2*.

Since the reconstructed part of the penis had no sensation, surgery was performed without local infiltration, such as lidocaine or epinephrine saline. The incision was applied using a number 15 blade after the foley catheter was inserted. By checking the path of the neourethra through the inserted foley catheter, the remnant tissue was dissected carefully not to damage the neourethra. After the tissue resection, the neourethra was isolated and resected to fit the height of the resected penis (*Figure 3*) in a manner that constructed the neomeatus and corrected the hypospadias. After reduction, we performed an approximation using 4-0 vicryl and 5-0 nylon according to the designed incision line (*Figure 4A*).

To prevent infection, foley catheter insertion and antibiotics were maintained 3 weeks after surgery until a total stitch-off was performed (2). Shortly after the surgery, there were no complications other than the raw surface around the opening of the urethra (*Figure 4B*). Two years after the surgery, there were no complications, such as urethral stricture or fistula, and the patient was satisfied with the shape and size of the reduced penis (9 cm) (*Figure 4C,4D*).

All procedures performed in this study were in accordance with the ethical standards of the institutional and/or national research committee(s) and with the Declaration of Helsinki (as revised in 2013). The Institutional Review Board of Chung-Ang University Hospital approved this retrospective study (IRB No. 2131-001-455). Written informed consent was obtained from the patient for publication of this case report and accompanying images. A copy of the written consent is available for review by the editorial office of this journal.

Discussion

In the event of penile loss, a flap-based penis reconstruction surgery resolves functional and cosmetic problems. A variety of penis reconstruction methods using flaps have been introduced (2,3). In our case, the patient used a random pattern type of tubed abdominal flaps by Bogoraz and Gillies for *de novo* fabrication of the penis (3).

After penis reconstruction, neourethra-related side effects of the urethra stricture or fistula may occur. The patient developed a urethra fistula after the penis reconstruction, resulting in hypospadias. Hypospadias can be corrected simultaneously with penis reduction. Before the penis

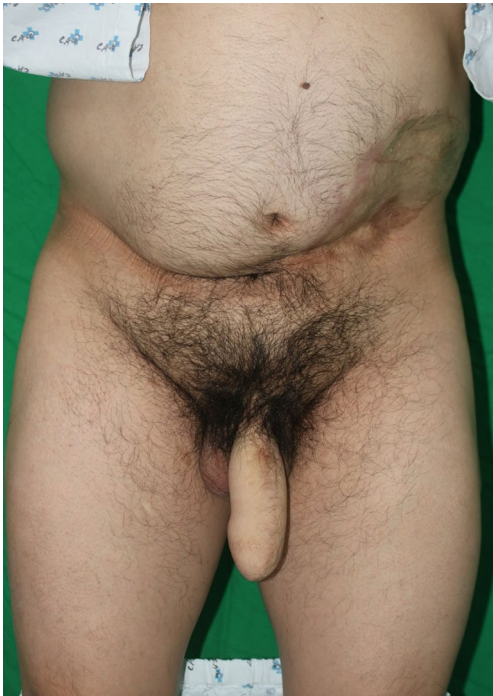

Figure 1 Preoperative finding.

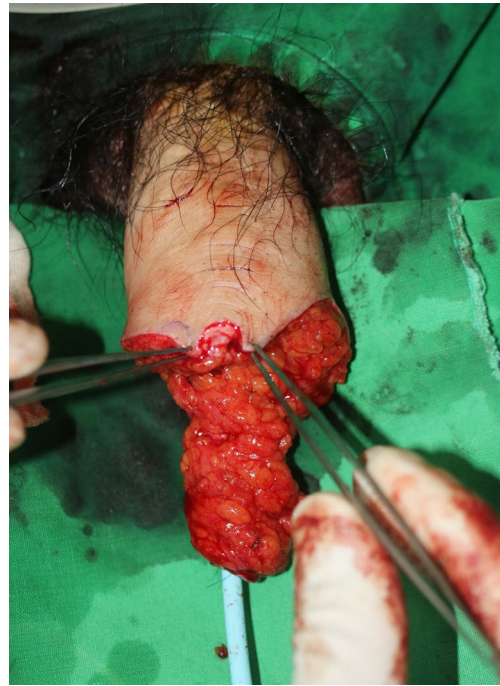

Figure 3 The status of the unresected and isolated neourethra after the penile tissue resection.

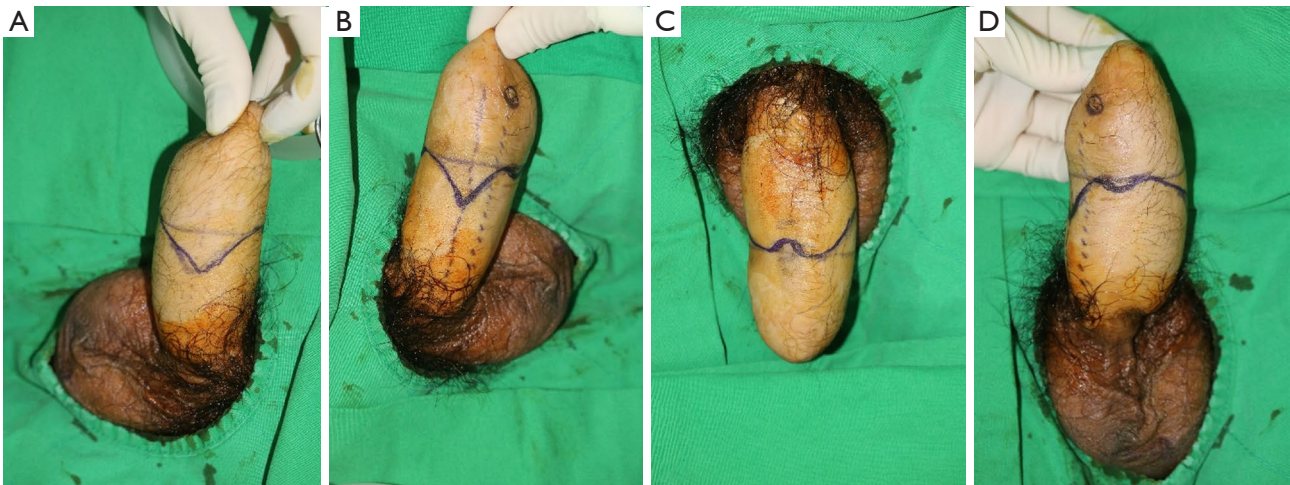


Figure 2 Preoperative design. (A) Lateral view (patient's left side); (B) lateral view (patient's right side); (C) anterior view; (D) posterior view.

reduction, the neourethra must be isolated to prevent damage during penile dissection. (Figure 3) Isolating the neourethra before resection can determine if the urethra is intact and if it is long enough to make a new neomeatus.

When resecting a normal penis, the anatomical position of the arteries, veins, and cavernous bodies must first be

estimated and the arteries and veins stitched. The penis can then be resected while creating a new neomeatus (4). Unlike a normal penis, in a reconstructed penis made using a random type of tubed abdominal flap, it is difficult to know the exact anatomical structure, including vessels or the neourethra. For this reason, attention must be paid to avoid

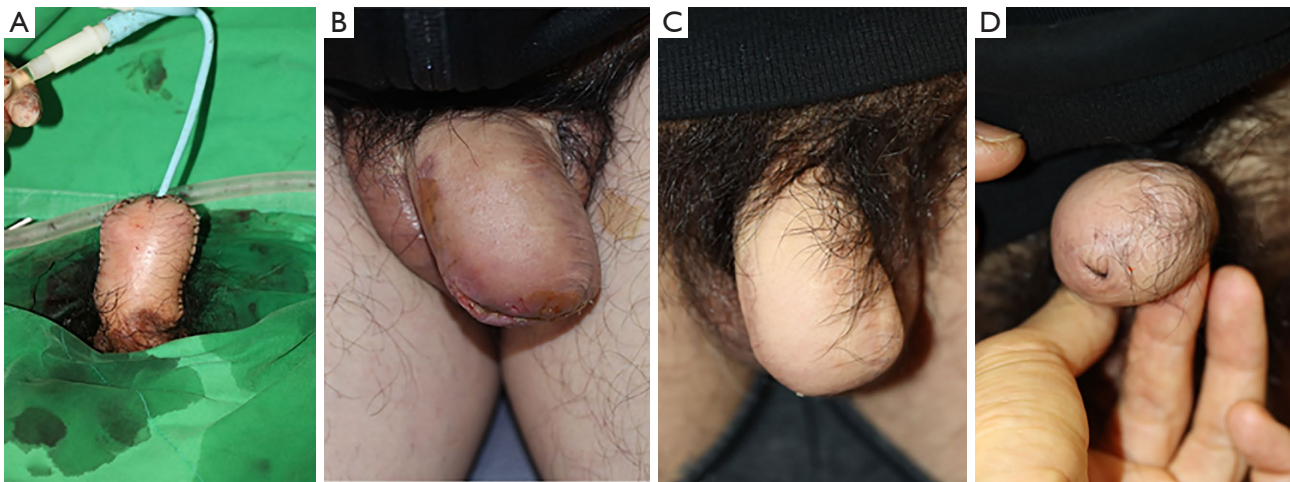


Figure 4 Postoperative findings. (A) Immediate postoperative finding; (B) 3 weeks after surgery; (C) 2 years after surgery (anterior view); (D) 2 years after surgery (apical view).

damage to major anatomical structures, and careful resection and dissection are required during the reconstructed penis resection. By checking the intraoperative doppler sound, damage to the main pedicle can be reduced. In particular, it is expected to be more helpful in cases of random flap surgery, where it is difficult to predict the location of the pedicle (5).

In addition to direct excision, liposuction, tissue shaving with an arthroscopic cartilage shaver, cryolipolysis, and skin grafting are methods of debulking flaps (6,7). Direct excision is the first method of consideration for flap debulking. Similar to the surgical procedure introduced in this case presentation, it can be used when the flap volume is large. Note that vascular pedicles may be damaged during direct excision.

Liposuction can reduce the amount of subcutaneous tissue in the flap. It is less invasive than direct excision. However, it is not suitable for debulking a large volume or debulking fibrotic tissues (6). In addition to direct excision and liposuction, methods such as drawback and skin grafting using a shaver can correct the flap contour or the color match (8). In this case, a large volume had to be reduced, so the direct excision reduction method was appropriate. However, liposuction or skin grafting can be used for a simple contour of the reconstructed penis, correcting a color match, or if the debulking volume is small.

Many methods of total penis reconstruction have been published. However, there are no published reports on a method of reconstructed penis reduction. Although this procedure is unlikely to be done frequently as a reduction

phalloplasty is unusual, the new surgical reduction procedure introduced in this case may be helpful to surgeons planning a reconstructed penis reduction.

Acknowledgments

Funding: None.

Footnote

Reporting Checklist: The authors have completed the CARE reporting checklist. Available at <https://tau.amegroups.com/article/view/10.21037/tau-22-488/rc>

Peer Review File: Available at <https://tau.amegroups.com/article/view/10.21037/tau-22-488/prf>

Conflicts of Interest: All authors have completed the ICMJE uniform disclosure form (available at <https://tau.amegroups.com/article/view/10.21037/tau-22-488/coif>). The authors have no conflicts of interest to declare.

Ethical Statement: The authors are accountable for all aspects of the work in ensuring that questions related to the accuracy or integrity of any part of the work are appropriately investigated and resolved. All procedures performed in this study were in accordance with the ethical standards of the institutional and/or national research committee(s) and with the Declaration of Helsinki (as revised in 2013). The Institutional Review Board of Chung-

Ang university hospital approved this retrospective study (IRB No. 2131-001-455). Written informed consent was obtained from the patient for publication of this case report and accompanying images. A copy of the written consent is available for review by the editorial office of this journal.

Open Access Statement: This is an Open Access article distributed in accordance with the Creative Commons Attribution-NonCommercial-NoDerivs 4.0 International License (CC BY-NC-ND 4.0), which permits the non-commercial replication and distribution of the article with the strict proviso that no changes or edits are made and the original work is properly cited (including links to both the formal publication through the relevant DOI and the license). See: <https://creativecommons.org/licenses/by-nc-nd/4.0/>.

References

1. Perović S. Phalloplasty in children and adolescents using the extended pedicle island groin flap. *J Urol* 1995;154:848-53.
2. Yao A, Ingargiola MJ, Lopez CD, et al. Total penile reconstruction: A systematic review. *J Plast Reconstr Aesthet Surg* 2018;71:788-806.
3. Rashid M, Tamimy MS. Phalloplasty: The dream and the reality. *Indian J Plast Surg* 2013;46:283-93.
4. Burnett AL. Penile preserving and reconstructive surgery in the management of penile cancer. *Nat Rev Urol* 2016;13:249-57.
5. Sonda R, Pandis L, Bassetto F, et al. Deep inferior epigastric perforator flap preoperative planning: A comparative analysis between dynamic infrared thermography, computerized tomography angiography, and hand-held Doppler. *Microsurg* 2022;42:649-58.
6. Kim TG, Choi MK. Secondary contouring of flaps. *Arch Plast Surg* 2018;45:319-24.
7. Nagel SS, Rauh A, Siegwart LC, et al. From Esthetic Medicine to Optimizing Reconstructive Outcome: A Feasibility Trial on Secondary Refinement of Fasciocutaneous Anterolateral Thigh Flaps with Cryolipolysis. *J Reconstr Microsurg* 2022. [Epub ahead of print]. doi: 10.1055/s-0042-1755259.
8. Lin TS, Jeng SF. Full-thickness skin graft as a one-stage debulking procedure after free flap reconstruction for the lower leg. *Plast Reconstr Surg* 2006;118:408-12.

Cite this article as: Kang SH, Kang SH, Kim WS, Kim HK, Kim WJ, Kim HS, Bae TH. An innovative method of reconstructed penis reduction: a case report. *Transl Androl Urol* 2022;11(12):1798-1802. doi: 10.21037/tau-22-488