

Effects of topical Kiwifruit on healing of neuropathic diabetic foot ulcer

Gholamreza Mohajeri, Masumeh Safaee, Mohamad Hossein Sanei¹

Departments of Thoracic Surgery and ¹Pathology, Isfahan University of Medical Sciences, Isfahan, Iran

Background: Kiwifruit (*Actindia Deliciosa*) is demonstrated to have antibacterial and pro-angiogenic effects. It also contains proteolytic enzymes (actinidin) and ascorbic acid. In this study, the effects of Kiwifruit on neuropathic diabetic foot ulcer healing in clinical settings were evaluated. **Materials and Methods:** In this randomized clinical trial of 37 patients (17 in experimental and 20 in control groups) with neuropathic diabetic foot ulcer were studied in Isfahan-Iran. Patients of the control group received just the standard treatments. In the experimental group, in addition to the standard treatments, ulcers were dressed with pure extract of kiwifruit twice daily for 21 days. The ulcers were examined and evaluated based on macroscopic, microscopic and microbiological status. Pre- and post-interventions, biopsies were taken from the ulcers to perform microbiological and histological studies. **Results:** Mean reduction in surface area of foot ulcer in the experimental group was significantly higher than the control group (168.11 ± 22.31 vs. 88.80 ± 12.04 mm² respectively, $P < 0.0001$). The amount of collagen and granulation tissues was significantly higher in the experimental groups than the control group (P value < 0.0001). Significantly higher levels of angiogenesis and vascularization were found in the kiwifruit treated patients (P value < 0.0001). No significant antibacterial effect was observed for kiwifruit. **Conclusion:** Natural compounds in the kiwifruit including protein-dissolving enzymes (Actinidin) improved different aspects of the wound healing process. Based on these benefits and safety aspects, we conclude that using kiwifruit is a simple, applicable and effective way for treatment of neuropathic diabetic foot ulcer.

Key words: Diabetic foot, diabetic foot ulcer, fruit, kiwifruit, wound healing

How to cite this article: Mohajeri G, Safaee M, Sanei MH. Effects of topical Kiwifruit on healing of neuropathic diabetic foot ulcer. *J Res Med Sci* 2014;19:520-4.

INTRODUCTION

During the past decade, the incidence of diabetes mellitus has increased and led to a threatening epidemic.^[1,2] This increased incidence is associated with higher rate of complications including foot problems and ulcer healing difficulties, which are clinically significant and challenging.^[3-5] Diabetes is considered as the major cause of non-traumatic lower extremity amputation that reduces the survival of patients, and causes an enormous burden to the society.^[6,7]

To improve the diabetic foot ulcer healing process, many biomedical studies have been carried out, and different preparations have been studied.^[8] Over the previous century, different herbal compounds have been developed in Africa and Asia for ulcer healing.

The kiwifruit is originated from China, and it has been known there since 700 years ago. Later, it was introduced to New Zealand and America. It is believed that this fruit contains potent protein-dissolving enzymes (actinidin),

ascorbic acid (a scavenger agent) and antibacterial agents; therefore, it can play an important role in ulcer healing process.^[9-16]

Several *in vitro* and animal studies reported that the kiwifruit has proven effects in ulcer debridement, angiogenesis and disinfection.^[11,17-19]

Given the above evidence, this study was purposed to evaluate the effect of kiwifruit on healing of neuropathic diabetic foot ulcers.

MATERIALS AND METHODS

Study design and patients

In this randomized clinical trial patients with neuropathic diabetic foot ulcer referred to Al-Zahra hospital clinic, affiliated to Isfahan University of Medical Sciences, from 2009 to 2010 were enrolled.

Sixty-four patients were initially evaluated. Twenty patients were excluded for not meeting the study criteria and 4 were excluded because of declining participation. Finally, 40 patients were randomly allocated to the

Address for correspondence: Dr. Masumeh Safaee, Department of Surgery, Alzahra Hospital, Isfahan University of Medical Sciences, Soffeh st., Isfahan, Iran. E-mail: safaee.masumeh@yahoo.com

Received: 19-11-2012; **Revised:** 11-06-2013; **Accepted:** 15-01-2014

experimental or control groups using an online application (<http://www.randomizer.org>) [Figure 1].

Inclusion criteria of the patients for the study were based on clinical diagnosis of neuropathic diabetic foot ulcer and the signing informed consent. Diagnosis of neuropathy was confirmed using a 5.07/10 gram monofilament. In addition, all patients underwent palpation of the foot pulses and Doppler sonography to assess foot blood supply, and those with ischemic ulcers were excluded from the study. Patients who had received any treatment for diabetic foot ulcer within 6 months of the study were also excluded.

The ethics committee of Isfahan University of Medical Sciences approves this study (Research project number; 390023), and the informed consent was obtained from all patients included in this study.

Procedure

All patients were initially admitted to the hospital. To make a pre-intervention histological assessment, a tissue sample was taken from the ulcer site under local anesthesia. Moreover, to determine the initial size of the lesion, a baseline photo of the lesion was taken.

Then, all the patients received standard treatments including surgical debridement, oral antibiotic — ciprofloxacin 500 mg (Chemidarou-Iran) every 12 hours and clindamycin 600 mg (Chemidarou-Iran) every 8 hours, blood sugar control was monitored and the regular sterile ulcer dressing was done,

after washing the ulcer with sterile normal saline. When the ulcers showed no signs of infection based on the culture results, patients were discharged from the hospital, but a daily visit was arranged to assess the ulcer and to perform debridement on a regular basis.

Patients of the control group received only the standard treatment, and the ulcer dressing was changed thrice a day. Patients in the experimental group received the standard treatment and an additional treatment, which is as follows; the ulcers of the experimental group were covered with a 3-mm-thick layer of a mixture of pulped fresh kiwifruit and pure-normal concentration-kiwifruit extract, using a 50 cc gavage syringe. Both the mixture and the extract were provided from the natural fruit (without any additive).

The ulcers of the experimental group were washed with sterile normal saline every 12 hours. Then, they were covered again with kiwifruit, and were dressed with sterile gauze and latex-free tape.

All wound dressings were performed by trained and experienced nurses during hospitalization, and thereafter.

All macroscopic, histopathologic and microbiologic changes of the ulcers in both groups were observed and recorded during the study. Regarding the macroscopic properties, any change in the ulcer size, degree of edema, hyperemia, and epithelialization status were assessed every other day. Furthermore, on each visit, a digital photo of the lesion was taken to record the ulcer size and check the healing progress. Photos were analyzed by SigmaScan pro software, version 5.0, to determine the ulcer size.

After 21 days, a post-intervention biopsy was taken, and an ulcer culture was obtained to check the histopathological and microbiological statuses, respectively. The ulcer cultures were studied based on the presence of *Pseudomonas-aeruginosa*, *Staphylococcus aureus*, coagulase-negative *Staphylococcus*, *Streptococcus* and other gram-negative bacteria (such as *Enterobacter* and *Klebsiella*).

Both pre- and post-intervention biopsies were studied by the same pathologist who was not aware of the samples' group. Samples were assessed regarding the degree of epithelialization, degree of angiogenesis, degree of tissue granulation, collagen deposition status and acute or chronic inflammatory cell count. Epithelialization, inflammation, granulation, and vascularization were investigated based on the scoring system presented in Table 1.^[20,21]

Statistical analysis

Data were analyzed by the Statistical Package for the Social Sciences (SPSS) 20.0 (SPSS Inc., Chicago, IL, USA) software and Wilcoxon, Mann-Whitney, independent-*t* test and

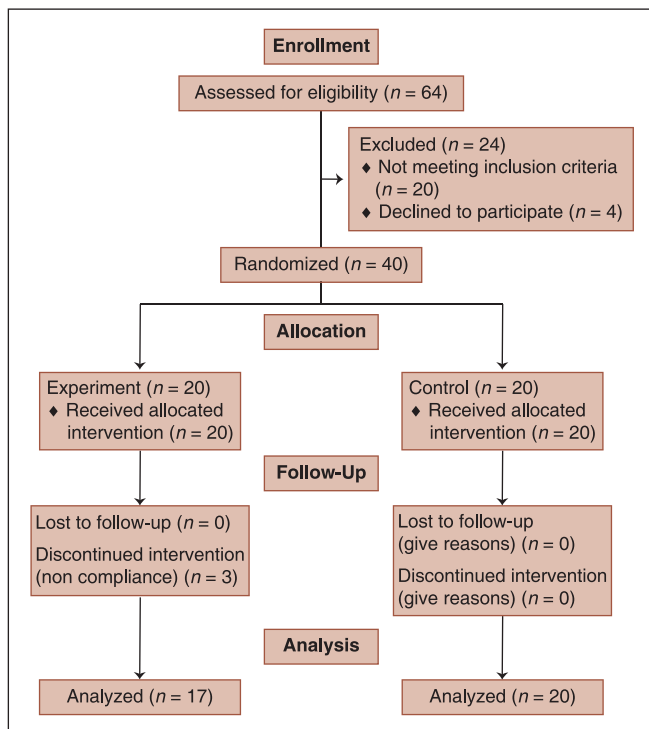


Figure 1: Study flow diagram

Chi-square tests. *P* values less than 0.05 were considered as the level of significance.

RESULTS

After exclusion of 3 patients from the experimental group due to non-compliance in blood sugar control, data of the other 17 patients in this group was compared with 20 patients of the control group. There were no significant differences in the baseline characteristics of two studied groups [Table 2].

The ulcers were assessed regarding changes in macroscopic, histopathological and microbiological properties.

Macroscopic findings

Ulcer size

A more significant reduction in the ulcer size was found in the experimental group compared with the control group (168.11 ± 22.31 vs. 88.80 ± 12.04 mm² respectively, *P* < 0.0001).

Macroscopic hyperemia and edema

Although the experimental group showed macroscopically more hyperemia on the day 3 and 5 (25.33 ± 8.06 vs.

22.40 ± 6.09 arbitrary units (AU), *p*: 0.08); after the 11th day, hyperemia was more evident in the control group (32.08 ± 4.99 vs. 27.31 ± 5.78, *p*: 0.02).

Wound closure

Applying kiwifruit accelerated wound closure. Wound closure occurred 11.24 ± 3.66 days after starting the intervention in the experimental group, which was significantly sooner than the control group (17.76 ± 4.88 days) (*P* < 0.0001).

Microscopic findings

Pre- and post-interventions, histopathological properties of the ulcers are compared in Table 3.

Microbiological findings

The rate of positive bacterial culture at the beginning of the study was 72% and 83% in experimental and control groups, respectively. After intervention, reduction in positive bacterial cultures was not different in two studied groups (44% in experimental group vs. 67% in control group, *P* = 0.18).

No major side effect was found or reported during the study.

DISCUSSION

Diabetic foot ulcer is a common, expensive and debilitating problem among diabetic patients that may lead to lower limb amputation. Therefore, several different methods have been studied to achieve better results in the treatment of this sort of ulcers.^[6,7] Herbal products have been widely used in treatment of different types of wound for centuries.^[22] For instance, these preparations were used for chemical wound debridement during World War II.^[23] Similarly, different herbal compounds have been reported to be effective in the treatment of diabetic foot ulcers.^[24-29] Although there is no study regarding the effectiveness of kiwifruit on diabetic foot ulcers, the previous animal study states that reported kiwifruit is a safe and effective method for wound healing in animal models.^[18] We carried out a pilot study on patients with neuropathic diabetic foot ulcers for the first time, and found it to be beneficial.

Patients treated with kiwifruit had significantly sooner scar tissue detachment. This effect may be related to some

Table 1: Histopathological wound healing scale

Score	Epithelialization	Inflammatory cell response	Granulation tissue	Vascularization
0	None	None	None	None
1	Focal	Minimal	Minimal	Minimal
2	Thin, complete surface	Mild	Mild	Mild
3	Thick, complete surface	Evident	Evident	Severe

Table 2: Baseline characteristics of experimental and control groups

	Experimental group n = 17	Control group n = 20	<i>P</i> value
Age (year)	58.27±11.39	60.38±11.88	0.59
Sex (Male/Female)	14/4	16/2	0.32
Duration of diabetes (years)	18.72±4.8	10.83±3.4	0.11
HbA1c (%)	6.94±0.18	6.98±0.33	0.83
Fasting blood sugar (mg/dl)	198.06±27.96	196.44±18.34	0.62
Pre-intervention ulcer size (mm ²)	424.89±85.81	398.22±73.37	0.21

Data are presents as mean ± SD except sex distribution

Table 3: Pre- and post-intervention histopathological characteristics of experimental and control groups

Histopathological characteristics	Experimental group		<i>P</i> value	Control group		<i>P</i> value
	Before intervention	After intervention		Before intervention	After intervention	
Epithelialization score	0.72±0.22	0.72±0.17	0.81	0	0	0.47
Vascularization score	0.22±0.09	1.8±0.7*	0.03	0	0.75±0.62*	0.08
Collagen formation	0.42±0.09	2.1±0.7*	0.0001	0.33±0.14	0.17±0.6*	0.02
Inflammation score	2.27±0.75	1.12±0.58	0.001	0.92±0.51	1.75±1.1	0.07
Granulation score	0.11±0.06	1.83±0.98*	0.03	0	0.5±0.11*	0.09

**P* < 0.05 between experimental and control groups after intervention

of the ingredients of kiwifruit including ascorbic acid, which works as a scavenger agent, and actinidin, which is a strong protein dissolving enzyme.^[19,30] Actinidin is a sort of cysteine proteases (CPs) found in kiwifruit. This enzyme is responsible for well-known proteolytic and meat-tenderizing effect of kiwi, and makes this fruit a good option for herbal debridement.^[18,31] This finding confirms the suggested role for kiwifruit in the previous study as a herbal debridement agent.^[30]

Better vascularization that was found in the experimental group is similar to animal findings.^[32] Although several plants such as aloe vera are reported to have angiogenic compounds, there is no report about angiogenic properties of kiwifruit.^[18] Hence, it is assumed that kiwifruit may be a rich source of some sorts of angiogenesis modulators that are necessary for healing process.^[32]

The combination of scar tissue detachment and angiogenesis effects of kiwifruit could explain its effect on hyperemia. These effects lead to more hyperemia during the first half when the scavenger and debridement effects are dominant; however, in the second part, hyperemia is less evident in the experimental group probably due to better progress of the healing process.

In addition to macroscopic improvement, histological evaluation of foot ulcers showed that kiwifruit dressing significantly increases granulation score, epithelialization score and collagen formation. It decreases inflammation of the ulcer site. These microscopic changes need further biochemical investigations to confirm the definite mechanisms involved in these processes.

Given the above evidence, it is not surprising to find a significant reduction in the size of the foot ulcers treated with kiwifruit.

Because wound infection is a common problem in patients with diabetic foot ulcer, infection control is a very important issue in these patients. Previous studies reported significant antibacterial properties for kiwifruit.^[19,32] It may be attributed to the composing ingredients of kiwifruit. High concentration of CPs in different fruits like kiwi may be responsible for their antibacterial, antifungal and even anti-insect effects.^[19,31] *In vitro* studies reported that the kiwifruit extract have antibacterial effects against Gram-positive and Gram-negative bacteria.^[19,33] In contrast to the previous studies, we did not find any difference between the two groups that confirm antimicrobial effects of kiwifruit. This contradiction may be due to administration of oral antibiotics to all patients as a part of standard treatment. Antibiotics can hide the antibacterial effects of kiwifruit.

A major concern during the treatment with herbal medications is the unpredicted side effects such as allergic reactions. Fortunately, similar to the previous study on rats,^[32] no major side effects were observed in patients treated with kiwifruit.

Based on the useful properties of kiwifruit including debridement of devitalized tissue and detachment of the scar tissue — without detrimental effects on the healing process; improvement of angiogenesis, epithelialization, and granulation; and its effect on reducing the ulcer size, this pilot study suggests that applying kiwifruit on neuropathic diabetic foot ulcers could be a promising way to achieve better outcomes.

REFERENCES

1. Wild S, Roglic G, Green A, Sicree R, King H. Global prevalence of diabetes: Estimates for the year 2000 and projections for 2030. *Diabetes Care* 2004;27:1047-53.
2. Coliaguri S, Borch-Johnsen K, Glümer C, Vistisen D. There really is an epidemic of type 2 diabetes. *Diabetologia* 2005;48:1459-63.
3. Powlson AS, Coll AP. The treatment of diabetic foot infections. *J Antimicrob Chemother* 2010;65:iii3-9.
4. Iraj B, Khorvash F, Ebnehashidi A, Askari G. Prevention of diabetic foot ulcer. *Int J Prev Med* 2013;4:373-6.
5. Nilforoushzadeh MA, Jaffary F, Ansari N, Siadat AH, Heidari A, Adibi N. Treatment of recalcitrant diabetic foot ulcers using trichloroacetic acid. *J Res Med Sci* 2012; 17(Spec 2): S286-S290.
6. Tentolouris N, Al-Sabbagh S, Walker MG, Boulton AJ, Jude EB. Mortality in diabetic and nondiabetic patients after amputations performed from 1990 to 1995: A 5-year follow-up study. *Diabetes Care* 2004;27:1598-604.
7. Boulton AJ, Vileikyte L, Ragnarson-Tennvall G, Apelqvist J. The global burden of diabetic foot disease. *Lancet* 2005;366:1719-24.
8. Madibally SV, Solomon V, Mitchell RN, Van De Water L, Yarmush ML, Toner M. Influence of insulin therapy on burn wound healing in rats. *J Surg Res* 2003;109:92-100.
9. Nanney LB, Fortney DZ, Durham DR. Effect of vibriolysin, an enzymatic debriding agent, on healing of partial-thickness burn wounds. *Wound Repair Regen* 1995;3:442-8.
10. Houck JC, Chang CM, Klein G. Isolation of an effective debriding agent from the stems of pineapple plants. *Int J Tissue React* 1983;5:125-34.
11. Tiras U, Erdeve O, Karabulut AA, Dallar Y, Eksioglu HM. Debridement via collagenase application in two neonates. *Pediatr Dermatol* 2005;22:472-5.
12. Marazzi M, Stefani A, Chiaratti A, Ordanini MN, Falcone L, Rapisarda V. Effect of enzymatic debridement with collagenase on acute and chronic hard-to-heal wounds. *J Wound Care* 2006;15:222-7.
13. Rosenberg L, Lapid O, Bogdanov-Berezovsky A, Glesinger R, Krieger Y, Silberstein E, *et al.* Safety and efficacy of a proteolytic enzyme for enzymatic burn debridement: A preliminary report. *Burns* 2004;30:843-50.
14. Ramundo J, Gray M. Enzymatic wound debridement. *J Wound Ostomy Continence Nurs* 2008;35:273-80.
15. Krieger Y, Rosenberg L, Lapid O, Glesinger R, Bogdanov-Berezovsky A, Silberstein E, *et al.* Escharotomy using an enzymatic debridement agent for treating experimental burn-induced compartment syndrome in an animal model. *J Trauma* 2005;58:1259-64.

16. Ozcan C, Ergun O, Celik A, Corduk N, Ozok G. Enzymatic debridement of burn wound with collagenase in children with partial-thickness burns. *Burns* 2002;28:791-4.
17. Masoudpour H, Mohajeri G, Khademi EF, Adibi S. Comparison between dressing with kiwifruit and silver sulfadiazine ointment in treatment of *Pseudomonas* infections in third-degree burns. *JACS* 2009;209:S80-1.
18. Mohajeri G, Masoudpour H, Heidarpour M, Khademi EF, Ghafghazi S, Adibi S, *et al.* The effect of dressing with fresh kiwifruit on burn wound healing. *Surgery* 2010;148:963-8.
19. Basile A, Vuotto ML, Violante U, Sorbo S, Martone G, Castaldo-Cobianchi R. Antibacterial activity in *Actinidia chinensis*, *Feijoa sellowiana* and *Aberia caffra*. *Int J Antimicrob Agents* 1997;8:199-203.
20. Schlager A, Kronberger P, Petschke F, Ulmer H. Low-power laser light in the healing of burns: A comparison between two different wavelengths (635 nm and 690 nm) and a placebo group. *Lasers Surg Med* 2000;27:39-42.
21. Schlager A, Oehler K, Huebner KU, Schmutz M, Spoetl L. Healing of burns after treatment with 670-nanometer low-power laser light. *Plast Reconstr Surg* 2000;105:1635-9.
22. Maenthaisong R, Chaiyakunapruk N, Niruntraporn S, Kongkaew C. The efficacy of aloe vera used for burn wound healing: A systematic review. *Burns* 2007;33:713-8.
23. Klasen HJ. A review on the nonoperative removal of necrotic tissue from burn wounds. *Burns* 2000;26:207-22.
24. Cai Y, Chen J, Jiang J, Cao W, He L. Zhen-wu-tang, a blended traditional Chinese herbal medicine, ameliorates proteinuria and renal damage of streptozotocin-induced diabetic nephropathy in rats. *J Ethnopharmacol* 2010;131:88-94.
25. Chan CM, Chan YW, Lau CH, Lau TW, Lau KM, Lam FC, *et al.* Influence of an anti-diabetic foot ulcer formula and its component herbs on tissue and systemic glucose homeostasis. *J Ethnopharmacol* 2007;109:10-20.
26. Lau KM, Lai KK, Liu CL, Tam JC, To MH, Kwok HF, *et al.* Synergistic interaction between *Astragalus Radix* and *Rehmannia Radix* in a Chinese herbal formula to promote diabetic wound healing. *J Ethnopharmacol* 2012;141:250-6.
27. Lau TW, Chan YW, Lau CP, Chan CM, Lau CB, Fung KP, *et al.* Investigation of the effects of Chinese medicine on fibroblast viability: Implications in wound healing. *Phytother Res* 2007;21:938-47.
28. Leung PC, Wong MW, Wong WC. Limb salvage in extensive diabetic foot ulceration: An extended study using a herbal supplement. *Hong Kong Med J* 2008;14:29-33.
29. Tam JC, Lau KM, Liu CL, To MH, Kwok HF, Lai KK, *et al.* The *in vivo* and *in vitro* diabetic wound healing effects of a 2-herb formula and its mechanisms of action. *J Ethnopharmacol* 2011;134:831-8.
30. Low C, Webb C, Thomas L, Ramos E, Panarese A, Clarke R, *et al.* The efficacy of fruit juices in disimpacting meat bolus obstruction. *Otolaryngol Head Neck Surg* 2004;131:166.
31. Nieuwenhuizen NJ, Maddumage R, Tsang GK, Fraser LG, Cooney JM, De Silva HN, *et al.* Mapping, complementation, and targets of the cysteine protease actinidin in kiwifruit. *Plant Physiol* 2012;158:376-88.
32. Fan TP, Yeh JC, Leung KW, Yue PY, Wong RN. Angiogenesis: From plants to blood vessels. *Trends Pharmacol Sci* 2006;27:297-309.
33. Motohashi N, Shirataki Y, Kawase M, Tani S, Sakagami H, Satoh K, *et al.* Cancer prevention and therapy with kiwifruit in Chinese folklore medicine: A study of kiwifruit extracts. *J Ethnopharmacol* 2002;81:357-64.

Source of Support: Nil, **Conflict of Interest:** None declared.