

Clinical Study

Abdominoperineal Resection for Rectal Cancer: Is the Pelvic Drain Externalization Site an Independent Risk Factor for Perineal Wound Healing?

M. G. Pramateftakis,¹ D. Raptis,¹ D. Kanellos,² E. Christoforidis,¹
G. Tsoulfas,² I. Kanellos,^{1,2} and Ch. Lazaridis¹

¹4th Surgical Department, Aristotle University of Thessaloniki, G. Papanikolaou General Hospital, Exochi, 57010 Thessaloniki, Greece

²Surgical Department, European Medical Center, Pilea, 55236 Thessaloniki, Greece

Correspondence should be addressed to D. Raptis, dimitrios.raptis@uk-erlangen.de

Received 19 December 2011; Accepted 14 February 2012

Academic Editor: Nikolaos Touroutoglou

Copyright © 2012 M. G. Pramateftakis et al. This is an open access article distributed under the Creative Commons Attribution License, which permits unrestricted use, distribution, and reproduction in any medium, provided the original work is properly cited.

Aim. The aim of this paper is to investigate if the insertion of the pelvic drainage tube *via* the perineal wound could be considered as an independent risk factor for perineal healing disorders, after abdominoperineal resection for rectal malignancy. **Patients and Methods.** The last two decades, 75 patients underwent elective abdominoperineal resection for malignancy. In 42 patients (56%), the pelvic drain catheter was inserted through the perineal wound (PW group), while in the remaining 33 (44%) through a puncture skin wound of the perineum (SW group). Patients' data with respect to age ($P = 0.136$), stage ($P > 0.05$), sex ($P = 0.188$) and comorbidity ($P = 0.128$) were similar in both groups. 25 patients (PW versus SW: 8 versus 17, $P = 0.0026$) underwent neoadjuvant radio/chemotherapy. **Results.** The overall morbidity rate was 36%, but a significant increase was revealed in PW group (52.4% versus 9%, $P = 0.0007$). In 33.3% of the patients in the PW group, perineal healing was delayed, while in the SW group, no delay was noted. Perineal healing disorders were revealed as the main source of increased morbidity in this group. **Conclusion.** The insertion of the pelvic drain tube through the perineal wound should be considered as an independent risk factor predisposing to perineal healing disorders.

1. Introduction

The abdominoperineal resection (APR) was first described by Miles in 1908, but early clinical trials reported operative morbidity rates as high as 40% [1–4]. Nissan et al. [5] reported an overall morbidity rate of 50–60% in patients undergoing APR for carcinoma. After the rectum is excised, the sacral cavity forms a large wound area that cannot be efficiently reduced. That area is prone to retention and infection. Besides, it is well documented that postoperative complications of the perineal wound and their long-term residuals comprise the major morbidity factor, especially when combined with neoadjuvant radio/chemotherapy [6–8].

According to published data, some authors recommend the pelvic drain externalization through an abdominal stab incision, while others bring out the tubes directly through

the perineum—either *via* a separate skin incision or *via* the perineal wound [9–11]. With regards to our technique, we believe that a perineal externalization site produces better results due to the gravity. To our knowledge, there are no studies up to date concerning the effects of the pelvic drain externalization site on the morbidity rates.

The aim of this study is to investigate whether the insertion of the pelvic drainage tube *via* the perineal wound could be considered as an independent risk factor for perineal healing disorders, following APR for rectal malignancy.

2. Patients and Methods

Between 1991 and 2010, elective abdominoperineal resection for rectal carcinoma was performed in 75 patients (47 males

and 28 females) with a mean age of 69 years (range, 22–82 years). The preoperative assessment for all patients included blood tests, chest X-ray, colonoscopy, and abdominal computed tomography. Since 1995, pelvic MRI was also routinely used for staging purposes. The mean distance of the tumors from the dentate line was 3.1 cm (max: 4 cm, min: 0.5 cm).

Preoperative bowel preparation with polyethylene glycol was routinely performed. Antibiotic prophylaxis consisted of intravenous 2nd generation cephalosporin and metronidazole, given at induction. During procedures lasting more than 2 hours, another dose was administered. No further postoperative antibiotics were used, unless a postoperative complication had arisen that needed treatment. All procedures were performed by one senior colorectal surgeon. Before the beginning of the procedure, randomization of the patient to either one of the two groups found place using a computer-generated ballot.

With regards to the technique used, we performed both abdominal and perineal approaches with the patient in modified lithotomy position. The abdomen was entered through a midline incision, extending from the pubis cephalad to just above the umbilicus. This approach allows adequate visualization of the abdomen, as well as the extension of the incision cephalad, should the splenic flexure need mobilization. A total mesorectal excision with high ligation of the inferior mesenteric vessels and preservation of the pelvic plexuses was performed.

Ninety-two percent of the interventions (69 patients; 38 of the *Perineal Wound* and 31 of the *Skin Wound* group) were performed with curative intent, whereas in 6 patients (8%), 4 of the PW and 2 of the SW group, the procedure was palliative. In one patient of the *Perineal Wound* group, the posterior vaginal wall was also resected *en bloc* with the rectum. In a further *Perineal Wound* group patient, two metastases of the right hepatic lobe were enucleated using radiofrequency ablation. With regards to the *Skin Wound* group, one patient underwent total hysterectomy and resection of the posterior vaginal wall, one underwent resection of the posterior bladder wall, and a third patient underwent resection of the posterior vaginal wall.

A 30-Fr passive drainage was inserted and the peritoneal pelvic floor was reconstructed. This device, also known as gravity drainage system, consisted of a plain tube and a 350 mL volumetric bag (Figure 1). The perineal wound was primarily closed in a two-layer fashion. In 42 patients (56%), the pelvic drain was inserted through the perineal wound, whereas in the remaining 33 patients (44%), the drain was inserted *via* a puncture skin wound to the left lateral portion of the perineum. The puncture site used was due to surgeon's preference. Dermatological anomalies that would not allow the positioning of the puncture wound at this point were not observed in any patient. The pelvic drain was left *in situ* until either the daily fluid amount was less than 50 mL, or the drain had been *in situ* for 5–7 days and the patient was ready for discharge. In the latter case, the drain was removed irrespective of the daily output amount of the drain.

Twenty-five patients, 8 of the *Perineal Wound* and 17 of the *Skin Wound* group ($P = 0.0026$), underwent neoadjuvant chemoradiation. Surgery was performed six to eight weeks

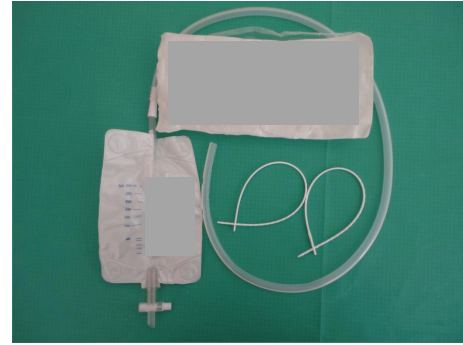


FIGURE 1: Type of a 30-Fr passive drainage system.

after preoperative radio/chemotherapy (Table 1). Patients' data with respect to age, sex, and comorbidity were similar in both groups (Table 2).

3. Statistical Analysis

Fisher's exact test was used for the comparisons between proportions. All the statistical analyses were performed using the SPSS v.15.0 statistical package (SPSS Inc, Chicago, IL, USA), enhanced with the modules exact tests.

4. Results

All patients were followed-up in our clinic on a weekly basis following their discharge for the first month and monthly thereafter. During follow-up, all patients had their baseline observations taken and a thorough examination of the perineal wound was performed by the operating surgeon and one assistant surgeon. Signs of localized infection, cellulitis, or delayed healing (such as redness, discoloration, swelling, warmth, etc.) were noted and recorded.

Most tumors in both groups were classified as BII according to Duke's classification and most of them were moderately differentiated. The detailed classification and differentiation of all tumors in the two groups is presented in Table 3.

Postoperative complications were observed in 22 patients of the *Perineal Wound* as well as in 5 patients of the *Skin Wound* group. With regards to surgery-specific complications, 20 were noted in patients of the *Perineal Wound* group, as well as 3 in patients of the *Skin Wound* group (PW versus SW: 47.6% versus 9%, $P = 0.0002$). The incidence of perineal wound healing disorders was significantly higher in the *Perineal Wound* group (PW versus SW: 33.3% versus 0, $P < 0.001$). In detail, 14 patients of the *Perineal Wound* showed a delay in perineal wound healing; in 11 of these patients, the perineal wound healing process was completed in 25–40 days (mean 31.2 days), while in three patients a permanent fistula was formed. In the *Skin Wound* group the mean time until complete perineal wound healing was 10 days and no case of healing disorder was noted. On the other hand, the number of patients who underwent neoadjuvant radio/chemotherapy was significantly higher in

TABLE 1: Patients treated by APR for a low rectal cancer ($n = 75$).

Group	PW ($n = 42$)	SW ($n = 33$)	<i>P</i> value	Significance level
Age*	67.2 (22–81)	71.3 (41–80)	0.157	NS
Sex ♂/♀	26/16	21/12	0.1878	NS
Tumor loc.**	3.1 (0.5–4)			
Indication				
Curative	38 (90%)	31 (94%)	0.2935	NS
Palliative	4 (10%)	2 (6%)	0.2935	NS
Neo-adjuvant RT/CT	8	17	0.0026	Sig.
Adjuvant RT/CT	21	8	0.0147	Sig.

* yrs: value I median (range).

** cm from the dentate line: value is mean (range).

(NS: non-significant; *P* value >0.05; Sig.: significant, *P* value <0.05).

TABLE 2: Risk factors associated with increased morbidity after APR; comparison of the study groups.

Group	PW ($n = 42$)	SW ($n = 33$)	<i>P</i> value	Significance level
Age (>55 yrs)	29	26	0.136	NS
Comorbidity	30	27	0.128	NS
Diabetes	11	7	0.191	NS
Cardiopulmonary dis.	4	5	0.212	NS
Vascular dis.	8	9	0.153	NS
Obesity (B.M.I. >30 kg/m ²)	12	9	0.203	NS
Neo-adjuvant RT/CT	8	17	0.0026	Sig.

NS: non-significant, *P* value >0.05; Sig.: significant, *P* value <0.05.

the *Skin Wound* group (SW versus PW: 51.5% versus 19%, $P = 0.0026$), and it is widely known that the incidence of wound healing abnormalities is reported to be higher in these patients. The rate of nonspecific, postoperative complications was exactly the same in both groups (Table 4).

The overall morbidity rate was 36%, but the statistical analysis revealed a significant increase in the *Perineal Wound* group (PW versus SW: 52.4% versus 9%, $P = 0.0007$). 5-year follow-up was completed for 49 patients, with a nonsignificant comparison between the study groups (SW versus PW: 26 versus 23, $P = 0.1336$). With regards to the survival rates, no significance was revealed after the pairwise comparison (SW versus PW: 73.07% versus 73.9%, $P = 0.253$), while the overall rate was 73.4% (Table 5).

5. Discussion

The abdominoperineal resection of the rectum is one of the most demanding procedures in gastrointestinal surgery and has undergone only slight technical modifications since its first description [12–15].

In patients undergoing APR and especially for carcinoma, multiple specific complications may arise either in the short or long term. According to published data, the overall morbidity ranges from 50 to 60% after an APR [16]. Murrell et al. [17] reported that the most common immediate postoperative complication, with a frequency of 32%, is the formation of an intra-abdominal or pelvic abscess. In

our study the incidence of this complication was extremely low, as only one case of abscess in the presacral space was noted, which was treated successfully with computed tomography-guided drainage and intravenous antibiotics. Other known complications include nerve injury, ureteric injury, complications from the colostomy site, as well as perineal wound complications [18, 19].

In the past, when blunt dissection was used with little appreciation to the fine pelvic anatomy, sexual dysfunction was seen in up to 75% of men and 40% of women, while bladder dysfunction was seen up to 80% of cases. Nowadays, following the introduction of TME, these rates—even though influenced by age, tumor location, and comorbidity—are reported to be 10–30% for sexual dysfunction and less than 5% for bladder dysfunction [20, 21]. Moreover, postoperative radiation tends to exacerbate male sexual dysfunction [22]. In our study, 2 cases (2.7%) of urinary but no case of sexual dysfunction was noted, as sharp dissection in the proper planes helped avoiding injury to the nerve plexuses.

The perineal wound poses a unique risk, predisposing to major postoperative complications. Despite improved surgical techniques, the rates of perineal wound dehiscence are reported to be higher than 10%, as it was also shown in our data. Furthermore, it is observed in 30–40% of patients who undergo neoadjuvant radiation [23–26]. The anatomy of the pelvic floor and the inherent potential risk of infection secondary to rectal surgery are associated with a high rate

TABLE 3: Staging and differentiation.

Group	PW (<i>n</i> = 42)	SW (<i>n</i> = 33)	<i>P</i> value	Significance level
Staging (Duke's)				
In situ	2	—	0.310	NS
A	3	3	0.311	NS
BI	6	5	0.254	NS
BII	14	13	0.165	NS
CI	3	3	0.311	NS
CII	11	7	0.191	NS
D	3	2	0.351	NS
Differentiation				
Well	10	4	0.107	NS
Moderate	28	23	0.189	NS
Poor	4	6	0.149	NS

NS: non-significant, *P* value >0.05.

TABLE 4: Complications, morbidity, and mortality.

Group	PW (<i>n</i> = 42)	SW (<i>n</i> = 33)	<i>P</i> value	Significance level
Complications	22	5	0.0007	Sig.
Surgical (specific)	20	3	0.0002	Sig.
Abdominal wound dehiscence	2	2		
Pelvic abscess*	1	—		
Ostomy necrosis**	—	1		
Evisceration/reoperation	1	—		
Perineal healing disorders	16	—	<0.001	Sig.
Delay in perineal healing	14	—		
Perineal wound dehiscence	2	—		
Medical (nonspecific)	2	2	0.374	NS
Pneumonia	1	—		
Urinary dysfunction	1	1		
Atrial fibrillation	—	1		
Morbidity	52.4%	15.2%	0.0007	Sig.
Mortality			0	
Overall morbidity			36%	

* In the presacral space, treated with CT-guided drainage.

**treated with primary relocation.

(NS: non-significant, *P* value >0.05; Sig.: significant, *P* value <0.05).

of perineal healing abnormalities following an APR. Besides, perioperative chemoprophylaxis fails to provide sufficient protection, because vessel ligation and electrocoagulation result in reduced perfusion and consequent disorders in microcirculation of the sacral cavity [27].

A confounding issue is the different opinions as to what risk factors impair the perineal wound healing. According to Christian et al. [28], higher rates of major wound complications were associated with increased body mass index, diabetes, and stage, while preoperative radiation and primary closure were not associated with increased complications. On the other hand, Luna-Pérez et al. [29] demonstrated that the main cause of morbidity was perineal

wound infection, influenced by postoperative radio +/- chemotherapy administration and patient age over 55 years.

In our patient group, the overall morbidity rate was 36%, while perineal healing disorder was noted to be the most common postoperative complication (59.3% of all case complications). Primary healing of the perineal wound, meaning no formation of seroma or hematoma and no signs of inflammation, was seen in 78.7% of patients. In the *Perineal Wound* group, the morbidity was significantly higher compared to the *Skin Wound* group (52.4%; 22/42 of patients, *P* = 0.0007). Perineal wound healing abnormalities were the main source of increased morbidity in this group (72.8%; 16/22 of complicated cases, *P* = 0.001). There were

TABLE 5: Local recurrence and survival.

Patients (n)	SW	PW	Overall	P value*	Significance level
Compl. 5-year follow-up	26	23	49	0.1336	NS
Deaths	7	6	13	0.2831	NS
<i>Cause of death</i>					
					<i>Time after APR (months)</i>
LR**	1	1	2		12, 24
LR** + hepatic metastases	—	1	1		6
Hepatic metastases	3	2	5		12, 12, 14, 18,38
Brain metastases	1	—	1		24
Lung + hepatic metastases	1	1	2		18, 24
Hepatic + brain metastases	1	—	1		24
Stroke	—	1	1		36
Survival (%)	73.07	73.9	73.4	0.253	NS
Local Recurrence (%)	3.8	8.7	6.1	0.357	NS

* SW versus PW.

** LR: local recurrence.

NS: non-significant, P value >0.05 ; Sig.: significant, P value <0.05 .

14 cases (33.3%) of delayed perineal healing, as well as 2 cases (4.8%) of perineal wound infection/dehiscence, which were treated conservatively.

Apart from the pelvic drain externalization site, patients in both groups showed no statistically significant differences with regards to population data, comorbidities, disease stage, and intraoperative conditions. As mentioned before, these parameters have been reported to affect perineal wound healing in many publications [30, 31]. Moreover, it is shown that even though the number of patients who underwent neoadjuvant radiation was significantly higher in the *Skin Wound* group, the rate of perineal wound healing abnormalities was significantly lower in these patients compared to those of the *Perineal Wound* group. This fact correlates with recently published studies suggesting the lack of any relation between pelvic irradiation and perineal healing abnormalities [26]. According to these findings, it is clearly demonstrated that the insertion of the pelvic drain tube through the perineal wound constitutes an independent risk factor affecting perineal wound healing, which results in increased postoperative morbidity rates in patients undergoing APR for rectal cancer.

6. Conclusion

The insertion of the pelvic drain tube through the perineal wound should be considered as an independent risk factor following an APR, predisposing to perineal healing disorders.

References

- [1] W. Ernest Miles, "A method of performing abdominoperineal excision for carcinoma of the rectum and of the terminal portion of the pelvic colon," *The Lancet*, vol. 172, no. 4451, pp. 1812–1813, 1908.
- [2] S. T. Martin, H. M. Heneghan, and D. C. Winter, "Systematic review of outcomes after intersphincteric resection for low rectal cancer," *British Journal of Surgery*, vol. 99, no. 5, pp. 603–612, 2012.
- [3] P. Mroczkowski, S. Hać, M. Mik et al., "Preliminary results of the first quality assurance project in rectal cancer in Poland," *Polski Przegląd Chirurgiczny*, vol. 83, no. 3, pp. 144–149, 2011.
- [4] I. S. Martijnse, F. Holman, G. A.P. Nieuwenhuijzen, H. J.T. Rutten, and S. W. Nienhuijs, "Perineal hernia repair after abdominoperineal rectal excision," *Diseases of the Colon and Rectum*, vol. 55, no. 1, pp. 90–95, 2012.
- [5] A. Nissan, J. G. Guillem, P. B. Paty et al., "Abdominoperineal resection for rectal cancer at a specialty center," *Diseases of the Colon and Rectum*, vol. 44, no. 1, pp. 27–36, 2001.
- [6] L. Smeets, B. Hendrickx, and T. C. Teo, "The propeller flap concept used in vaginal wall reconstruction," *Journal of Plastic, Reconstructive and Aesthetic Surgery*. In press.
- [7] T. L. Sagebiel, S. C. Faria, A. Balachandran, J. M. Sacks, Y. N. You, and P. R. Bhosale, "Pelvic reconstruction with omental and VRAM flaps: anatomy, surgical technique, normal post-operative findings, and complications," *Radiographics*, vol. 31, no. 7, pp. 2005–2020, 2011.
- [8] K. L. Mathis, D. W. Larson, E. J. Dozois et al., "Outcomes following surgery without radiotherapy for rectal cancer," *British Journal of Surgery*, vol. 99, no. 1, pp. 137–143, 2012.
- [9] L. Do, N. Syed, A. Puthawala, S. Azawi, I. Shbeeb, and I. -Y. Gong, "Low-lying rectal cancer with anal canal involvement: abdominoperineal or low anterior resection after neoadjuvant chemoradiotherapy," *Gastrointestinal Cancer Research*, vol. 4, no. 3, pp. 90–95, 2011.
- [10] W. B. Perry and J. C. Connaughton, "Abdominoperineal resection: how is it done and what are the results?" *Clinics in Colon and Rectal Surgery*, vol. 20, no. 3, pp. 213–220, 2007.
- [11] A. P. Zbar, R. K. Shenoy, and A. Chiappa, "Extended abdominoperineal resection in women: the barbadian experience," *International Seminars in Surgical Oncology*, vol. 4, article 1, 2007.
- [12] C. L. Simmang, "Abdominoperineal resection," *Operative Techniques in General Surgery*, vol. 5, no. 4, pp. 240–256, 2003.
- [13] F. Köckerling, H. Scheidbach, C. Schneider et al., "Laparoscopic abdominoperineal resection: early postoperative results of a prospective study involving 116 patients," *Diseases of the Colon and Rectum*, vol. 43, no. 11, pp. 1503–1511, 2000.

- [14] R. J. Heald, E. M. Husband, and R. D. H. Ryall, "The mesorectum in rectal cancer surgery—The clue to pelvic recurrence?" *British Journal of Surgery*, vol. 69, no. 10, pp. 613–616, 1982.
- [15] R. J. Heald, R. K. Smedh, A. Kald, R. Sexton, and B. J. Moran, "Abdominoperineal excision of the rectum—an endangered operation," *Diseases of the Colon and Rectum*, vol. 40, no. 7, pp. 747–751, 1997.
- [16] H. Farid and T. X. O'Connell, "Methods to decrease the morbidity of abdominoperineal resection," *American Surgeon*, vol. 61, no. 12, pp. 1061–1064, 1995.
- [17] Z. A. Murrell, M. R. Dixon, H. Vargas, T. D. Arnell, R. Kumar, and M. J. Stamos, "Contemporary indications for and early outcomes of abdominoperineal resection," *American Surgeon*, vol. 71, no. 10, pp. 837–840, 2005.
- [18] I. Kellokumpu, J. Vironen, M. Kairaluoma, I. Jantunen, H. Kautiainen, and K. Nuorva, "Quality of surgical care, local recurrence, and survival in patients with low- and midrectal cancers following multimodal therapy," *International Journal of Colorectal Disease*, vol. 27, pp. 111–120, 2011.
- [19] A. Simorov, J. F. Reynoso, O. Dolghi, J. S. Thompson, and D. Oleynikov, "Comparison of perioperative outcomes in patients undergoing laparoscopic versus open abdominoperineal resection," *American Journal of Surgery*, vol. 202, no. 6, pp. 666–672, 2011.
- [20] R. J. Heald, "The "Holy Plane" of rectal surgery," *Journal of the Royal Society of Medicine*, vol. 81, no. 9, pp. 503–508, 1988.
- [21] L. Ruo, J. Pfitzenmaier, and J. G. Guillem, "Autonomic nerve preservation during pelvic dissection for rectal cancer," *Clinics in Colon and Rectal Surgery*, vol. 15, no. 1, pp. 35–41, 2002.
- [22] M. I. Chorost, T. K. Weber, R. J. Lee, M. A. Rodriguez-Bigas, and N. J. Petrelli, "Sexual dysfunction, informed consent and multimodality therapy for rectal cancer," *American Journal of Surgery*, vol. 179, no. 4, pp. 271–274, 2000.
- [23] L. Xu, Y. Xiao, B. Wu et al., "Impact of neoadjuvant chemoradiation on perineal wound healing after abdominoperineal resection for lower rectal cancer," *Zhonghua Wei Chang Wai Ke Za Zhi*, vol. 14, pp. 775–777, 2011.
- [24] S. Anwar, "Short-course preoperative radiotherapy prior to abdominoperineal resection for Stage I low rectal cancer; evidence based or defensive medicine?" *Colorectal Disease*, vol. 14, no. 3, pp. 387–389, 2012.
- [25] O. Peacock, H. Pandya, T. Sharp et al., "Biological mesh reconstruction of perineal wounds following enhanced abdominoperineal excision of rectum (APER)," *International Journal of Colorectal Disease*, vol. 27, no. 4, pp. 475–482, 2012.
- [26] G. El-Gazzaz, R. P. Kiran, and I. Lavery, "Wound complications in rectal cancer patients undergoing primary closure of the perineal wound after abdominoperineal resection," *Diseases of the Colon and Rectum*, vol. 52, no. 12, pp. 1962–1966, 2009.
- [27] U. Gruessner, M. Clemens, P. V. Pahlplatz, P. Sperling, J. Witte, and H. R. Rosen, "Improvement of perineal wound healing by local administration of gentamicin-impregnated collagen fleeces after abdominoperineal excision of rectal cancer," *American Journal of Surgery*, vol. 182, no. 5, pp. 502–509, 2001.
- [28] C. K. Christian, M. R. Kwaan, R. A. Betensky, E. M. Breen, M. J. Zinner, and R. Bleday, "Risk factors for perineal wound complications following abdominoperineal resection," *Diseases of the Colon and Rectum*, vol. 48, no. 1, pp. 43–48, 2005.
- [29] P. Luna-Pérez, S. Rodríguez-Ramírez, J. Vega, E. Sandoval, and S. Labastida, "Morbidity and mortality following abdominoperineal resection for low rectal adenocarcinoma," *Revista de Investigacion Clinica*, vol. 53, no. 5, pp. 388–395, 2001.
- [30] S. E. Regenbogen, T. E. Read, P. L. Roberts, P. W. Marcello, D. J. Schoetz, and R. Ricciardi, "Urinary tract infection after colon and rectal resections: more common than predicted by risk-adjustment models," *Journal of the American College of Surgeons*, vol. 213, no. 6, pp. 784–792, 2011.
- [31] H. K. Christensen, P. Nerström, T. Tei, and S. Laurberg, "Perineal repair after extralevator abdominoperineal excision for low rectal cancer," *Diseases of the Colon and Rectum*, vol. 54, no. 6, pp. 711–717, 2011.