

Pediatric chylous ascites treatment with combined ultrasound and fluoroscopy-guided intranodal lymphangiography

Zainab A Vora, Devasenathipathy Kandasamy, Priyanka Naranje, Rohan Malik¹

Departments of Radiodiagnosis and ¹Pediatrics, All India Institute of Medical Sciences, New Delhi, India

Correspondence: Dr. Devasenathipathy Kandasamy, Room No. 82, Department of Radiodiagnosis, Ground Floor, AIIMS, New Delhi, India.
E-mail: devammc@gmail.com

Abstract

Chylous ascites is a form of ascites resulting from the leakage of lymph into the peritoneal cavity, which is particularly rare in children, most common etiology being an iatrogenic injury to lymphatics during surgery. Initial conservative management options include medium-chain triglycerides-based diet, somatostatin analogs, and total parenteral nutrition. If these fail, then interventions such as paracentesis with sclerotherapy, surgical ligation, or peritoneal shunts have been described. This study reports a case of a 7-year-old child with refractory chylous ascites to demonstrate a minimally invasive technique of intranodal lymphangiography with lipiodol as a viable treatment option for chylous ascites in children, particularly in cases of minor and undetectable leaks.

Key words: Chylous ascites; intranodal lymphangiography; therapeutic

Introduction

Chylous ascites (CA) is a rare type of ascites, rich in triglycerides and low-density lipoproteins (LDL), occurring because of lymphatic leakage into the peritoneal cavity. This is particularly rare in the pediatric population, with only ~100 reported cases,^[1] iatrogenic injury to the lymphatic vessels being the most common cause. Most of the cases which have been reported are those of post-retroperitoneal lymph node dissection for germ cell tumors of testis or neuroblastoma. In our case, CA followed resection of an intra-abdominal lymphangioma, which is particularly rare. Recently, there has been increased interest in the diagnostic as well as the therapeutic utility of ultrasound-guided

intranodal lymphangiography with ethiodized oil (lipiodol; Guerbet Japan, Tokyo, Japan).^[2-4] However, there are scarce reports on their utility in the pediatric population.^[5]

We herein present a child with refractory postoperative CA who was treated by combined ultrasound and fluoroscopy-guided intranodal lymphangiography with lipiodol.

Case Report

A 7-year-old male child presented to our tertiary care center with progressive abdominal distention since birth. The child was antenatally diagnosed with a large cystic abdominal

This is an open access journal, and articles are distributed under the terms of the Creative Commons Attribution-NonCommercial-ShareAlike 4.0 License, which allows others to remix, tweak, and build upon the work non-commercially, as long as appropriate credit is given and the new creations are licensed under the identical terms.

For reprints contact: reprints@medknow.com

Cite this article as: Vora ZA, Kandasamy D, Naranje P, Malik R. Pediatric chylous ascites treatment with combined ultrasound and fluoroscopy-guided intranodal lymphangiography. *Indian J Radiol Imaging* 2019;29:226-8.

Access this article online

Quick Response Code:



Website:
www.ijri.org

DOI:
10.4103/ijri.IJRI_424_18

lesion at 28 weeks of gestation, which was excised at 4 months of age. Histopathology confirmed a diagnosis of lymphangioma. After a brief period of relief, there was a recurrence of the lesion followed by re-excision at 3 years of age. This was followed by progressively increasing abdominal distension with nonspecific abdominal pain. Abdominal examination showed marked distention with mild tenderness. Abdominal ultrasound revealed marked ascites. Paracentesis to study the nature of ascites showed a milky and cloudy appearance of fluid with markedly raised triglyceride (1842 mg/dL), LDL (435 IU/L), and cholesterol (86 mg/dL) levels suggestive of chylous nature of the ascites.

Medical treatment with medium-chain triglyceride (MCT)-based, low-fat diet and inj. octreotide 50 µg TDS followed by paracentesis with sclerotherapy was performed, which failed to show any improvement. Dynamic magnetic resonance (MR) lymphangiography (dMRL) was performed, wherein bilateral inguinal lymph nodes were punctured using 25-gauge spinal needle under ultrasound guidance, which was secured and fixed. Injection of 5 mL diluted (1:1) gadobenate dimeglumine (MultiHance; Bracco International B.V.) at 1 mL/min into bilateral inguinal lymph nodes simultaneously was performed followed by careful positioning of the patient in the MR suite (Philips Ingenia, Best, the Netherlands). A T1-weighted 3D gradient sequence was acquired which was repeated sequentially until the contrast leak was identified. The study revealed gross ascites with left inguinal and abdominal wall lymphangiomas, with extravasation of contrast on the left side of the pelvic cavity and rectovesical pouch, providing indirect evidence of leak; however, the exact site of leakage could not be delineated [Figure 1A].

In order to detect the site of the leak, intranodal lymphangiography was performed. Under ultrasound guidance, the largest left inguinal lymph node was punctured with a 25-gauge spinal needle. In order to reduce the needle movement after lymph node puncture, the stylet of the spinal needle was removed and was attached to a connecting tube, flushed with lipiodol. The needle tip was carefully positioned between the cortex and fatty hilum of the lymph node. The rate of lipiodol administration was kept extremely slow to prevent perinodal extravasation. A total volume of 5 mL of lipiodol was slowly injected over a period of 10 min under serial fluoroscopic guidance. Inguinal lymphatic vessels were visualized along with a globular area medial to Inferior iliac spine suggesting filling up of the lymphangioma itself [Figure 1B and C]. There was no passage of lipiodol proximally into the pelvic lymphatics or the cisterna chyli. There was persistence of lipiodol in the inguinal lymphatics in the follow-up CT obtained 48 h later [Figure 1D and E]. The patient was followed-up after 7 days when there was a dramatic decrease in the abdominal distension and ultrasound showed minimal residual ascites.

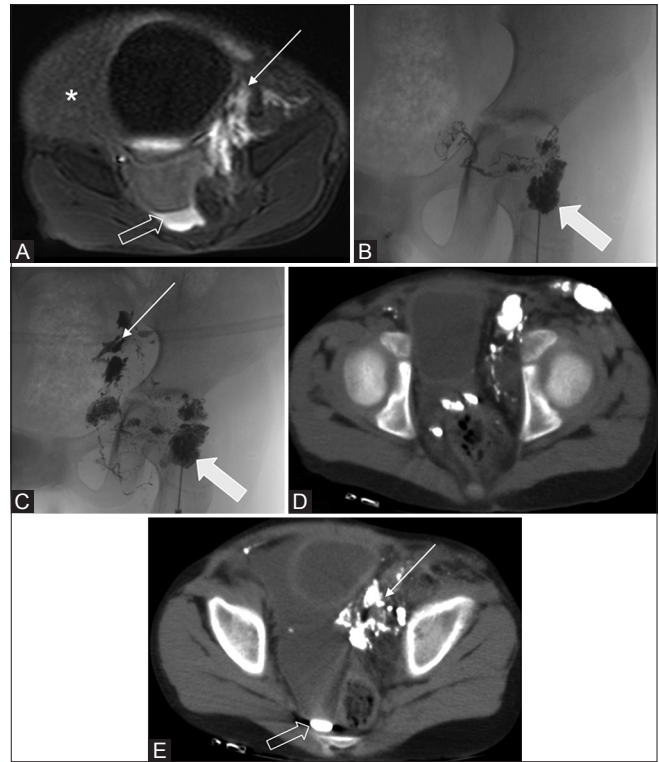


Figure 1 (A-E): Intranodal MR lymphangiography image (A) showing pooling of contrast (thin arrow) in the cystic spaces of residual lymphangioma in the left lateral pelvic wall and ascites (asterisk). There is layering of contrast in the dependent part of the rectovesical pouch (outlined arrow) suggesting contrast leak. Images (B and C) showing an intranodal injection of lipiodol (thick arrow) which is seen to opacify the lymph nodes, lymphatics, and the cystic spaces of lymphangioma. The post-procedure CT scan (D and E) showing the distribution of lipiodol as well as leakage into the rectovesical pouch (CT: Computed tomography, MR: Magnetic resonance)

There was sustained remission of disease at 6 months after the procedure and the child has been kept on follow-up.

Discussion

CA in the pediatric population is a rare type of ascites that develops most commonly as a result of surgical disruption of the lymphatic system. It leads to local complications, such as infection and delayed wound healing, as well as more grave systemic complications like malnutrition and immune dysfunction because of the loss of triglyceride, lymphocytes as well as immunoglobulins in the ascitic fluid.^[6]

The therapeutic options include a trial of conservative therapy with (1) diet control with low-fat, MCT diet; (2) total parenteral nutrition; (3) medical treatment with somatostatin analogs like octreotide, and (4) large volume paracentesis with the addition of sclerosing agents. It has been reported that 66% to 77% of patients can be successfully treated by conservative methods.^[7] On the other hand, a few authors describe that if drainage volume is >1000 – 1500 mL/day for >5 days, surgical repair of large lymphatic leaks or peritoneovenous shunt placement should

be attempted.^[4] However, these procedures cause high morbidity and are often unsuccessful in cases where there is leakage from small retroperitoneal and pelvic lymphatics.

Lymphangiography is a promising minimally invasive technique for the diagnosis as well as the treatment of chyle leakage. Intranodal lymphangiography in contrast to the conventional, more invasive pedal lymphangiography involves ultrasound-guided access to the inguinal lymph nodes for direct puncture, requiring no incision and bypassing the lymphatics of the lower limb, markedly reducing the procedural time, contrast volume, and radiation exposure, proving to be that much more valuable in the pediatric population.

The therapeutic effect of lipiodol in lymphangiography has previously been described in adults; two articles describe a success rate of 65–89% in their 14 and 9 patients series of refractory CA,^[2,4] respectively. The proposed mechanism for this effect is that lipiodol accumulates near the point of leakage and induces a local inflammatory reaction, which is followed by fibrosis.^[7,8] An interesting observation by Kawasaki *et al.*^[4] was that higher success rate (100%) could be achieved in the minor leak groups as compared with major leaks, as also seen in our case. This denotes a particularly valuable role to lymphangiography in the niche group with minor and undetectable lymphatic leaks, not responding to conservative therapy, as these leaks would be easily missed and would not be amenable to surgical repair.

In conclusion, intranodal lymphangiography with lipiodol may play a valuable role in the treatment of refractory postoperative CA in children, particularly in cases of minor and undetectable leaks. MRL, being radiation-free modality, can be particularly useful to distinguish major leaks from the minor ones in the pediatric population, as in our case, and dictate the difference in management from surgical repair of lymphatic leaks to lymphangiography using lipiodol.

Declaration of patient consent

The authors certify that they have obtained all appropriate patient consent forms. In the form the patient(s) has/have given his/her/their consent for his/her/their images and other clinical information to be reported in the journal. The patients understand that their names and initials will not be published and due efforts will be made to conceal their identity, but anonymity cannot be guaranteed.

Financial support and sponsorship

Nil.

Conflicts of interest

There are no conflicts of interest.

References

1. Leibovitch I, Mor Y, Golomb J, Ramon J. The diagnosis and management of postoperative chylous ascites. *J Urol* 2002;167:449-57.
2. Matsumoto T, Yamagami T, Kato T, Hirota T, Yoshimatsu R, Masunami T, *et al.* The effectiveness of lymphangiography as a treatment method for various chyle leakages. *Br J Radiol* 2009;82:286-90.
3. Yamagami T, Masunami T, Kato T, Tanaka O, Hirota T, Nomoto T, *et al.* Spontaneous healing of chyle leakage after lymphangiography. *Br J Radiol* 2005;78:854-7.
4. Kawasaki R, Sugimoto K, Fujii M, Miyamoto N, Okada T, Yamaguchi M, *et al.* Therapeutic effectiveness of diagnostic lymphangiography for refractory postoperative chylothorax and chylous ascites: Correlation with radiologic findings and preceding medical treatment. *AJR Am J Roentgenol* 2013;201:659-66.
5. Rajebi MR, Chaudry G, Padua HM, Dillon B, Yilmaz S, Arnold RW, *et al.* Intranodal lymphangiography: Feasibility and preliminary experience in children. *J Vasc Interv Radiol* 201;22:1300-5.
6. Kitagawa S, Sakai W, Hasegawa T. Ultrasound-guided intranodal lymphangiography with ethiodized oil to treat chylous ascites. *ACG Case Rep J* 2016;3:e95.
7. Lv S, Wang Q, Zhao W, Han L, Wang Q, Batchu N, *et al.* A review of the postoperative lymphatic leakage. *Oncotarget* 2017;8:69062-75.
8. Lee EW, Shin JH, Ko HK, Park J, Kim SH, Sung KB. Lymphangiography to treat postoperative lymphatic leakage: A technical review. *Korean J Radiol* 2014;15:724-32.