

# A sustained ventricular tachycardia overlooked by subcutaneous implantable cardioverter-defibrillator but recognized by co-implanted transvenous implantable cardioverter defibrillator



Kentaro Goto, MD,\* Yuichi Ono, MD,\* Yuki Osaka, MD,\* Ken Kurihara, MD,\*  
Kenichiro Otomo, MD,\* Tetsuo Sasano, MD<sup>†</sup>

From the \*Division of Cardiology, Ome Municipal General Hospital, Tokyo, Japan, and <sup>†</sup>Department of Cardiovascular Medicine, Tokyo Medical and Dental University, Tokyo, Japan.

## Introduction

The subcutaneous implantable cardioverter-defibrillator (S-ICD) system is an established therapy for the primary and secondary prevention for sudden cardiac death. This system is clinically advantageous, as it does not require endovascular leads that cause many of the complications associated with transvenous ICDs.<sup>1</sup> In the absence of intracardiac electrocardiograms, the S-ICD discriminates arrhythmias based on electrocardiograms sensed by subcutaneous electrodes. The device program designates 2 therapeutic zones: the shock zone, in which arrhythmias are discriminated only by heart rate; and the conditional shock zone, wherein a morphology-based discrimination algorithm is used to classify rhythms as either shockable or nonshockable. This optional conditional shock zone has led to a similar prevalence of inappropriate shocks with S-ICD and transvenous (TV) ICD.<sup>2</sup>

The clinical limitations of the discrimination algorithm based on subcutaneous lead electrocardiograms (ECGs) should be determined. Here, we describe a case in which the S-ICD overlooked a hemodynamically instable sustained ventricular tachycardia (VT), although the VT cycle length was covered by the conditional shock zone. Although the sustained VT within this zone was detected by an inpatient ECG monitor and co-implanted transvenous dual-chamber ICD leads, the S-ICD did not leave any records or deliver any shocks during the arrhythmia episode.

**KEYWORDS** Congestive heart failure; Old myocardial infarction; S-ICD; Subcutaneous implantable cardioverter-defibrillator; Transvenous ICD; TV-ICD; Ventricular tachycardia; VT  
(Heart Rhythm Case Reports 2020;6:334-337)

**Address reprint requests and correspondence:** Dr Kentaro Goto, Division of Cardiology, Ome Municipal General Hospital, 4-16-5 East Ome, Ome City, 198-0042, Tokyo, Japan. E-mail address: [ken-goto@umin.ac.jp](mailto:ken-goto@umin.ac.jp).

## Case report

A 68-year-old man with a medical history of broad anteroseptal myocardial infarction was transferred to our hospital with exercise-induced sustained VTs and symptomatic chest discomfort in December 2006. He presented with ischemic cardiomyopathy and underwent a percutaneous coronary intervention for residual ischemia in the proximal-to-middle portion of the left anterior descending coronary artery using a Sirolimus eluting stent (Cypher 3.5 \* 23 mm, Cypher 3.5 \* 18 mm), and the proximal portion of the right coronary artery using a bare metal stent (Driver 4.0 \* 30 mm) in January 2007. Subsequently, 2 sessions of catheter ablation for the sustained VTs were performed in January 2007 and August 2008. He received implantation of a TV dual-chamber ICD (Evera XT DR, atrial lead: CapSure Fix NOVUS 5076-52, ventricular lead: Sprint Quattro Secure 6947-58, Medtronic, Minneapolis, MN) for secondary prevention in August 2008. After this series of interventional treatments, he remained free from sustained VT episodes for 10 years.

In May 2018, he was readmitted to our hospital with a TV-ICD electrical lead failure of the right ventricular coil, which produced a high lead impedance and electrical noise that were detected by a home monitoring system. Although the TV-ICD had not recorded any sustained VT episodes, the patient exhibited heart failure with a severely reduced left ventricular ejection fraction (20%) on echocardiography and sporadic nonsustained VT episodes on TV-ICD recordings. At that time, he also exhibited paroxysmal atrial fibrillation and sick sinus syndrome. He had potential indications for cardiac resynchronization therapy – defibrillator upgrade; however, given his general condition and the adhesion of noninfectious shock coil leads, we discussed his therapeutic options and finally decided to utilize the residual atrial lead of the TV-ICD as an AAI pacemaker for bradycardia, as well as the ventricular lead as a tachycardia monitor with the therapy function turned off. We also implanted another

## KEY TEACHING POINTS

- It is important to understand the limitations of the electrocardiogram morphology–based discrimination algorithm for the subcutaneous implantable cardioverter-defibrillator (S-ICD) conditional shock zone.
- It is important to understand the need for sensing vector checks of the S-ICD, especially in patients with an unstable clinical status.
- Further studies are needed to determine the adequate timing and frequency of a sensing vector check of the S-ICD in unstable patients.

S-ICD for dual device management, although this practice was not fully supported by the 2017 AHA/ACC/HRS Guideline.<sup>3</sup> Results of automatic screening test for S-ICD sensing vectors were all suitable in both standing and spine position. The S-ICD (EMBLEM MRI S-ICD system, Boston Scientific, Marlborough, MA) implantation was completed without any adverse events in June 2018 (Supplemental Figure). A defibrillation test also succeeded just after the device implantation. We obtained the ECG template for the conditional shock zone in the sitting position before discharge and set the conditional shock zone as 180–220 beats per minute (bpm), which covered the documented VT cycle length and shock zone as over 220 bpm with SMART-Pass filter turned on. Max sensing range/gain setting was 1x. We also programmed the TV-ICD as follows to utilize as tachycardia monitor: VT-zone 420–350 ms/VF-zone 350 ms/therapy off/tachycardia monitoring on/discrimination algorithms: PR logic/Wavelet on.

After device implantation, the patient visited our device clinic every 4 months for follow-ups, during which the QRS morphologies of the S-ICD sensing vectors (eg, primary, secondary, alternate) did not change in the sitting position. All were deemed adequate for sensing according to the S-ICD vector tests until at least 6 months after implantation.

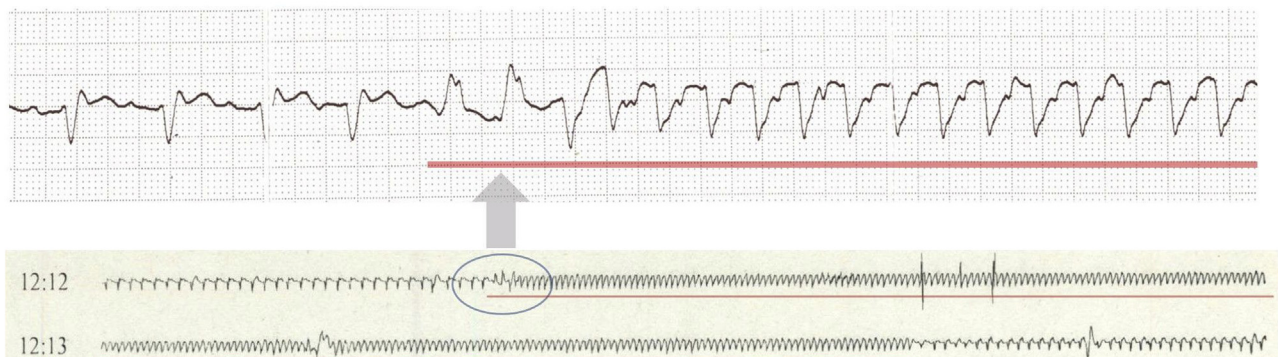
Seven months after implantation, he was readmitted for an exacerbation of congestive heart failure. Upon admission, his 12-lead ECG revealed a decreasing R-wave amplitude in the precordial leads, and a chest radiograph did not reveal any S-ICD migration. His respiratory condition improved after an injection of diuretics. However, 14 days after admission, the inpatient ECG monitor revealed a wide QRS tachycardia (cycle length: 300 ms, 200 bpm) that was sustained for approximately 1 minute 20 seconds with near-syncope symptoms, and it stopped spontaneously (Figure 1). This tachycardia was diagnosed as a sustained VT by the TV-ICD (Figure 2), and the S-ICD covered its cycle length in the conditional shock zone (180–220 bpm). The tachycardia was sustained long enough to be discriminated by the S-ICD. Nevertheless, the S-ICD did not deliver any shocks or record the sustained VT.

We checked the S-ICD program and observed a decline in the R-wave amplitude from 3.2 to 1.5 mV in the secondary vector, which was the most optimal sensing vector immediately after S-ICD implantation (Figure 3). The secondary sensing vector remained adequate, although the primary vector morphology became more appropriate for the S-ICD at that time. We changed the sensing vector from the secondary to the primary and increased the daily dosage of oral amiodarone from 100 to 200 mg. After medical treatment, no further VT was observed before discharge.

## Discussion

S-ICDs lack intracardiac ECGs and discriminate arrhythmias based on ECGs sensed by subcutaneous electrodes. However, some cases cannot be distinguished even within the programmed conditional shock zone, which may lead to inappropriate shocks.

Prior studies of therapeutic efficacy of S-ICD analyzed arrhythmia event data obtained via device checks or home monitoring systems. However, the lack of records for an overlooked VT episode in the conditional shock zone of the S-ICD suggests that such episodes could not be confirmed in real clinical scenarios in the absence of ECG recording devices such as co-implanted ICDs. Gold and colleagues<sup>4</sup>



**Figure 1** A wide QRS tachycardia (cycle length: 300 ms) sustained for approximately 1 minute, 20 seconds with near-syncope symptoms that stopped spontaneously, as revealed by an inpatient electrocardiogram monitor.



template, the S-ICD treats the event; if it is narrower or the same, the S-ICD does not deliver shocks. Referring to the QRS duration of the VT that is longer than that of the NSR in the inpatient monitor (Figure 2) in this case, it appears unlikely that the VT was missed in the final stage that compares the QRS durations.

Regarding the accuracy of ventricular tachycardia discrimination by S-ICDs, prior studies demonstrated that a morphology-based discrimination algorithm in the conditional shock zone could very effectively prevent inappropriate shocks.<sup>2</sup> However, we did not identify any other studies that discussed the prevalence of overlooked VT in the conditional shock zone. The START study revealed the highly sensitive ability of the S-ICD to detect ventricular tachyarrhythmias induced by programmed stimuli.<sup>5</sup> Almost all ventricular episodes analyzed in that study were tachycardias >240 bpm in the shock zone, whereas the number of tachycardias below 220 bpm in the conditional shock zone were limited. In addition, by contrast to TV-ICD that discriminates arrhythmias even in the VF zone utilizing a multiple discrimination algorithm such as PR Logic or Wavelet discrimination algorithm (Medtronic),<sup>6,7</sup> the S-ICD discriminates arrhythmias only by heart rate in the shock zone. This raises the possibility of inappropriate shocks for unexpected high rates of supraventricular tachycardias in the shock zone of the S-ICD.

In our case, the R-wave amplitude of the secondary sensing vector decreased significantly. VT under-sensing appears unlikely, even for the decreased R-wave amplitude, given the very low S-ICD detection floor that can detect even a small f wave of ventricular fibrillation. However, the lower R-wave amplitude might decrease the accuracy of tachycardia discrimination. Bettin and colleagues<sup>8</sup> reported changes in the sensing vectors in 216 patients who underwent S-ICD implantation during a follow-up of 27.3 months. In that study, a change in the initial vector was observed in 77 patients (35.7%), and a postoperative setup in the supine and erect position was the most frequent reason cited for a vector change (54 patients, 70.1%). The authors also mentioned a position change of the generator owing to an acute body weight gain or loss as a possible cause of a change in the initial vector. In our case, the position of the device on a chest radiograph did not appear to have changed notably from before to after the implantation. Therefore, the ECG change in our patient might be attributable to the accumulation of chest fluid or cardiomegaly consequent to congestive heart failure. In other words, the optimal sensing vector of the S-ICD might change in response to the patient's condition. In our case, we should have updated the QRS

template of the S-ICD when the patient was admitted to our hospital for worsening heart failure.

The 2017 AHA/ACC/HRS Guideline<sup>3</sup> advises that physicians should confirm a match between the sensed QRS and templates during follow-up. However, the template was not automatically updated in the S-ICD; ECG template checks at every routine follow-up for every patient with an S-ICD would take too much time. The basis on which follow-up S-ICD vector checks are deemed adequate is to be clarified.

A sensing vector check and reset timing of the S-ICD should be considered, especially in a patient whose condition has changed dramatically. Checking 12-lead ECG morphology could be an effective screening option; nevertheless, it is also important to understand the limitations of the ECG morphology-based discrimination algorithm.

## Conclusions

It is necessary to understand the limitations of the ECG morphology-based discrimination algorithm for the S-ICD, especially regarding VT discrimination. Further studies are needed to determine the necessity of a routine sensing vector check of the S-ICD in unstable patients.

## Supplementary data

Supplementary data to this article can be found online at <https://doi.org/10.1016/j.hrcr.2020.02.012>.

## References

1. Boersma L, Barr C, Knops R, et al. Implant and midterm outcomes of the subcutaneous implantable cardioverter-defibrillator registry: The EFFORTLESS Study. *J Am Coll Cardiol* 2017;70:830–841.
2. Theuns DAMJ, Brouwer TF, Jones PW, et al. Prospective blinded evaluation of a novel sensing methodology designed to reduce inappropriate shocks by the subcutaneous implantable cardioverter-defibrillator. *Heart Rhythm* 2018;15:1515–1522.
3. Al-Khatib SM, Stevenson WG, Ackerman MJ, et al. 2017 AHA/ACC/HRS Guideline for Management of Patients With Ventricular Arrhythmias and the Prevention of Sudden Cardiac Death: Executive Summary. *Circulation* 2018;138:e210–e271.
4. Gold MR, Weiss R, Theuns DA, et al. Use of a discrimination algorithm to reduce inappropriate shocks with a subcutaneous implantable cardioverter-defibrillator. *Heart Rhythm* 2014;11:1352–1358.
5. Gold MR, Theuns DA, Knight BP, et al. Head-to-head comparison of arrhythmia discrimination performance of subcutaneous and transvenous ICD arrhythmia detection algorithms: the START study. *J Cardiovasc Electrophysiol* 2012; 23:359–366.
6. Koneru JN, Swerdlow CD, Wood MA, Ellenbogen KA. Minimizing inappropriate or "unnecessary" implantable cardioverter-defibrillator shocks: appropriate programming. *Circ Arrhythm Electrophysiol* 2011;4:778–790.
7. Gold MR, Ahmad S, Browne K, Berg KC, Thackeray L, Berger RD. Prospective comparison of discrimination algorithms to prevent inappropriate ICD therapy: primary results of the Rhythm ID Going Head to Head Trial. *Heart Rhythm* 2012; 9:370–377.
8. Bettin M, Rath B, Ellermann C, et al. Change of sensing vector in the subcutaneous ICD during follow-up and after device replacement. *J Cardiovasc Electrophysiol* 2018;29:1241–1247.