

Available online at www.sciencedirect.com
ScienceDirect
journal homepage: www.elsevier.com/locate/radcr

Case Report

Calcific tendinitis of the longus colli: An uncommon cause of neck pain ☆,☆☆

Hind Guerroum, MD^{a,b,*}, Ines Koubaa, MD^a, Aldjia Benissad, MD^a

^aGH Nord Essonne: Groupement Hospitalier Nord Essonne Longjumeau, FRANCE

^bDepartment of Radiology, Faculty of Medicine, Mohammed VI University of Health Sciences/Cheikh Khalifa International University Hospital, Casablanca, Morocco

ARTICLE INFO

Article history:

Received 3 November 2021

Accepted 13 January 2022

Available online 4 February 2022

Keywords:

Inflammatory neck pain

Longus colli tendinitis

Retropharyngeal calcific tendonitis

ABSTRACT

Calcific tendinitis of the longus colli is an uncommon disease with unknown incidence, caused by the deposit of calcium hydroxyapatite in the superior oblique tendon of the longus colli. We report a case of a 57-year-old woman with a history of a thyroglossal cyst, presented in the emergency department with severe neck pain, odynophagia, and a biological inflammatory syndrome. The CT scan showed calcifications in the longus colli muscle (LCM) in front of the C1-C2 level with poorly defined margins, a thickening of the prevertebral soft tissue measured at 15 mm, with no evidence of abscess formation. The diagnosis of resorbed calcific tendinitis of the longus colli muscle was established. The patient was treated with nonsteroidal anti-inflammatory drugs with a complete resolution of symptoms after. Radiologists should be aware of the pathognomonic imaging feature of Calcific tendinitis of the longus colli to guide physicians and to avoid invasive treatment and over-prescription of antibiotics, after excluding life-threatening diseases.

© 2022 The Authors. Published by Elsevier Inc. on behalf of University of Washington.

This is an open access article under the CC BY-NC-ND license

(<http://creativecommons.org/licenses/by-nc-nd/4.0/>)

Introduction

Calcific tendinitis of the longus colli is a rare entity [1], commonly misdiagnosed and ignored [2,3], with unknown incidence [4]. Also known as Retropharyngeal Calcific Tendinitis [1,5], it consists of a foreign-body inflammatory response to deposited crystals of hydroxyapatite in the superior oblique tendon of the longus colli [1,6].

Clinically, it can be misdiagnosed as retropharyngeal abscess, meningitis traumatic injury, or infectious spondylitis [3,5]. CT-scan plays a key role to establish the correct diagnosis of Calcific Tendinitis of the Longus Colli as it shows the calcifications in the insertion of an edematous tendon of the longus colli muscle [6].

We aim to increase the awareness of radiologists and spine surgeons to easily establish the correct diagnosis and to avoid unnecessary interventions.

☆ The name and street address of the institution from which the work originated: 159 Rue du Président François Mitterrand, 91160 Longjumeau

☆☆ Competing Interests: The authors declare that they have no competing interest.

* Corresponding author.

E-mail address: guerroumhind@gmail.com (H. Guerroum).

<https://doi.org/10.1016/j.radcr.2022.01.023>

1930-0433/© 2022 The Authors. Published by Elsevier Inc. on behalf of University of Washington. This is an open access article under the CC BY-NC-ND license (<http://creativecommons.org/licenses/by-nc-nd/4.0/>)

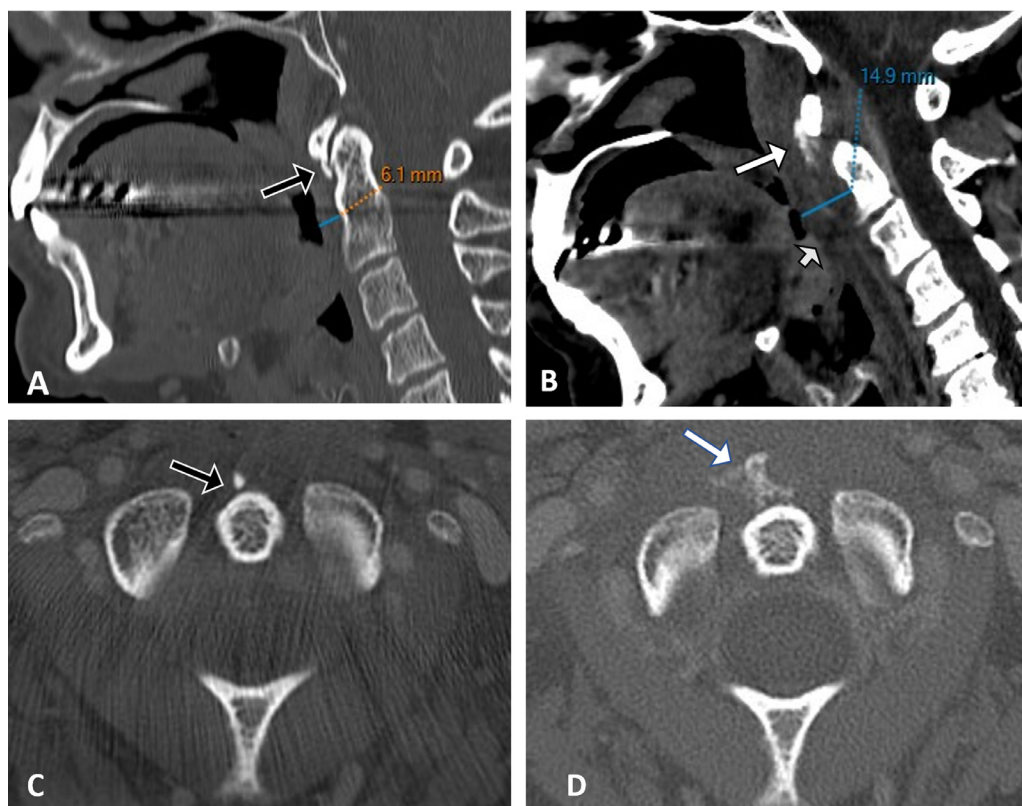


Fig. 1 – (B) Sagittal, (D) Axial CT computed tomography shows calcifications (White arrow) in the longus colli muscle (LCM) in front of the C1-C2 level with poorly defined margins, a thickening (15 mm) (→) of the prevertebral soft tissue. (A) sagittal, (C) axial of former CT scan performed 3 years ago showed that the calcification (Black arrow) in the LCM was smaller with well-defined margins, and no thickening of the prevertebral soft tissue.

Case presentation

A 57-year-old woman with a history of a thyroglossal cyst, presented in the emergency department with severe neck pain, and odynophagia. Laboratory tests showed C-reactive protein of 58 mg/L and leucocytosis $14730/\text{mm}^3$, which were suggestive of acute inflammation.

The CT-scan (Fig 1B and D) showed calcifications in the longus colli muscle (LCM) in front of the C1-C2 level with poorly defined margins, a thickening measured at 15 mm of the prevertebral soft tissue with no evidence of abscess formation. The diagnosis of resorbed calcific tendinitis of the longus colli muscle was established.

Compared to a former CT-scan (Fig 1A and C) performed 3 years ago to assess the diagnosis of the thyroglossal cyst, the calcification in the LCM was smaller with well-defined margins, and no thickening of the prevertebral soft tissue.

The patient was treated with nonsteroidal anti-inflammatory drugs with a complete resolution of symptoms after.

Discussion

Calcific tendinitis of the longus colli is a relatively rare aseptic inflammatory disease [3] localized in the superior oblique

tendon of longus colli, which is a muscle that extends anterior to the spine from its origin along the first three thoracic, and last three cervical vertebrae in three groups; the lower groups insert into the bodies and transverse process of the cervical vertebrae, and the superolateral group inserts by a tendon into the anterior tubercle [7].

To the best of our knowledge, Hartley [9] reported in 1964 the first case of Calcific tendinitis of the longus colli.

Frequently misdiagnosed, the incidence of Calcific tendinitis of the longus colli remains unknown [4], however, J. Boardman [10] reported in 2017, in his study a frequency of 1.1 per 1000 examinations. The Risk factors consist of repetitive trauma, recent injury degenerative cervical disorders, osteoarthritis, tissue necrosis, renal failure [3], ischemia, and vascular disease [4,8].

The clinical features of calcific tendinitis of LCM are variable, the typical symptoms encompass severe neck pain with limited neck movement that is accompanied by dysphagia or odynophagia, and headache [3,8]. The duration of symptoms before presentation ranges from one day to three months [1].

CT-scan is the modality of choice to establish the diagnosis as it has a good sensitivity to show small amorphous calcifications [1] and to eliminate life-threatening differential diagnoses such as retropharyngeal abscess [3].

Pathognomonic imaging findings on CT-scan include amorphous calcifications in the longus colli muscle with

retropharyngeal edema [3,8]. The calcifications feature may vary considerably from subtle to quite obvious [3].

MRI may be useful to show features related to edema and inflammatory reaction and non-enhancing retropharyngeal effusion [3,8].

A CT-guided biopsy of the prevertebral soft tissue may be recommended in cases where the differentiation from a retropharyngeal abscess is difficult [1].

Calcific tendinitis of the longus colli is a self-limiting condition [1,10]. A complete resolution of the acute symptoms is reported after the administration of nonsteroidal anti-inflammatory drugs. Sometimes a soft cervical collar is prescribed [1].

Learning points

- Calcific tendinitis of the longus colli is a rare condition revealed mostly by neck pain and odynophagia.
- CT-scan is the modality of choice to establish the diagnosis as it has a good sensitivity to show small amorphous calcifications and to eliminate retropharyngeal abscess. MRI may be useful to show features related to edema and inflammatory reaction.
- Radiologists should be aware of Calcific tendinitis of the longus colli to guide physicians and to avoid invasive treatment and over-prescription of antibiotics, after excluding life-threatening diseases.

Patient consent

I confirm that written, informed consent for publication of their case was obtained from the patient.

REFERENCES

- [1] Shawky A, Elnady B, El-Morshidy E, Gad W, Ezzati A. Longus colli tendinitis. A review of literature and case series. *SICOT J* 2017;3:48 Epub 2017 Jun 28. PMID: 28664844; PMCID: PMC5492790. doi:10.1051/sicotj/2017032.
- [2] Suh B, Eoh J, Shin J. Clinical and imaging features of longus colli calcific tendinitis: an analysis of ten cases. *Clin Orthop Surg* 2018;10(2):204–9 Epub 2018 May 18. PMID: 29854344; PMCID: PMC5964269. doi:10.4055/cios.2018.10.2.204.
- [3] Kessler B, Leyva JD, Schmitt C, Murtagh R. Acute longus colli tendinitis: case report of a rare cause of neck pain. *Radiol Case Rep* 2020;15(9):1433–6 PMID: 32642012; PMCID: PMC7334548. doi:10.1016/j.radcr.2020.05.058.
- [4] Kang T, Park SY, Lee SH, Park JH. Acute calcific tendinitis of the longus colli. *Pain Medicine* 2020;21:1706–8. doi:10.1093/pm/pnaa055.
- [5] Chung T, Rebello R, Gooden EA. Retropharyngeal calcific tendinitis: case report and review of literature. *Emerg Radiol* 2005;11:375–80 Epub 2005 Jul 15. PMID: 16344978. doi:10.1007/s10140-005-0427-y.
- [6] Ring D, Vaccaro AR, Scuderi G, Pathria MN, Garfin SR. Acute calcific retropharyngeal tendinitis. Clinical presentation and pathological characterization. *J Bone Joint Surg Am* 1994;76:1636–42 PMID: 7962023. doi:10.2106/00004623-199411000-00006.
- [7] Haun CL. Retropharyngeal tendinitis. *AJR Am J Roentgenol* 1978;130(6):1137–40 PMID: 418653. doi:10.2214/ajr.130.6.1137.
- [8] Langford B, Kleinman Sween J, Penn DM, Hooten WM. Severe neck pain and odynophagia secondary to acute calcific longus colli tendinitis: a case report. *J Med Case Rep* 2020;14(1):148 PMID: 32891177; PMCID: PMC7487496. doi:10.1186/s13256-020-02480-z.
- [9] HARTLEY J. Acute cervical pain associated with retropharyngeal calcium deposit. A case report. *J Bone Joint Surg Am* 1964;46:1753–4 PMID: 14239862.
- [10] Boardman J, Kanal E, Aldred P, Boonsiri J, Nworgu C, Zhang F. Frequency of acute longus colli tendinitis on CT examinations. *Emerg Radiol* 2017;24(6):645–51 Epub 2017 Jul 25. PMID: 28744692; PMCID: PMC5681978. doi:10.1007/s10140-017-1537-z.