

Percutaneous treatments of acute myocardial infarction and major stroke: Two parallel roads



Giampiero Vizzari^{1,2} , Francesco Versaci^{3,4} and Antonino Nicosia¹

Abstract

Neurological and cardiovascular ischemic diseases represent the main causes of morbidity and mortality in the world. Physiopathological mechanisms present several similarities, based on “thromboembolic” events, as well as the pharmacological and percutaneous treatment options. We report a case of contemporary presentation of acute coronary and cerebral syndromes, successfully managed with a combined percutaneous intervention driven by the emergency setting. Whereas invasive revascularization represents nowadays the “gold standard” therapy for acute coronary syndromes, catheter-based treatment of acute stroke is not yet widespread and still under debate.

Keywords

Acute stroke, acute myocardial infarction, primary PCI, carotid angioplasty, endovascular thrombectomy

Received 31 January 2019; Revised received 26 June 2019; accepted 18 July 2019

Introduction

More than 15 million strokes occur worldwide every year and the importance of the timing of treatment for acute events is nowadays well known. Evidence showed poor efficacy of current pharmacological treatment of acute stroke (AS), with low rate of recanalization, especially in case of major vessel occlusions.

On the other hand, percutaneous treatments of AS and acute myocardial infarction (the last routinely performed) present several similarities, and the importance of an invasive management for acute neurological events is currently debated.

Case report

A 74-year-old male, smoker, diabetic with previous acute coronary syndrome and stent implantation in the right coronary artery (RCA), was admitted to our Cath-lab for non-ST-elevation myocardial infarction. Despite detailed information about the life-threatening risk and the importance to immediately undergo percutaneous coronary intervention (PCI), the patient refused the procedure and self-discharged.

Two weeks later, he presented to the emergency department for major stroke, unconscious, aphasic with right hemiplegia (NIHSS 27). Furthermore, his

electrocardiogram showed massive ST-segment elevation in inferior-lateral leads, with specular anterior ST depression, signs of a concomitant inferior-posterior-lateral STEMI. Blood pressure was 170/80 mmHg, Killip class 1 and time-from-onset of stroke symptoms was established to be within 2 h. CT angiogram of supra-aortic vessels confirmed the occlusion of the left internal carotid artery (ICA) excluding hemorrhagic cerebral infarction (Figure 1(a)).

We decided to perform a complete percutaneous treatment for both the cerebral and myocardial acute ischemic events. Coronary angiography confirmed a proximal occlusion of the RCA, whereas carotid angiogram showed the occlusion at the origin of the left ICA (Figure 1(b)). After providing double proximal and

¹Cardiology Unit, “Giovanni Paolo II” Hospital of Ragusa, Ragusa, Italy

²Department of Clinical and Experimental Medicine, University of Messina, Messina, Italy

³Cardiology Unit, “Santa Maria Goretti” Hospital, Latina, Italy

⁴Dipartimento di Scienze Mediche, Tor Vergata University of Rome, Rome, Italy

Corresponding author:

Giampiero Vizzari, University of Messina, Via Montesanto, MESSINA DUE, Pal. 10, 98124 Messina, Italy.

Email: giampierovizzari@hotmail.it



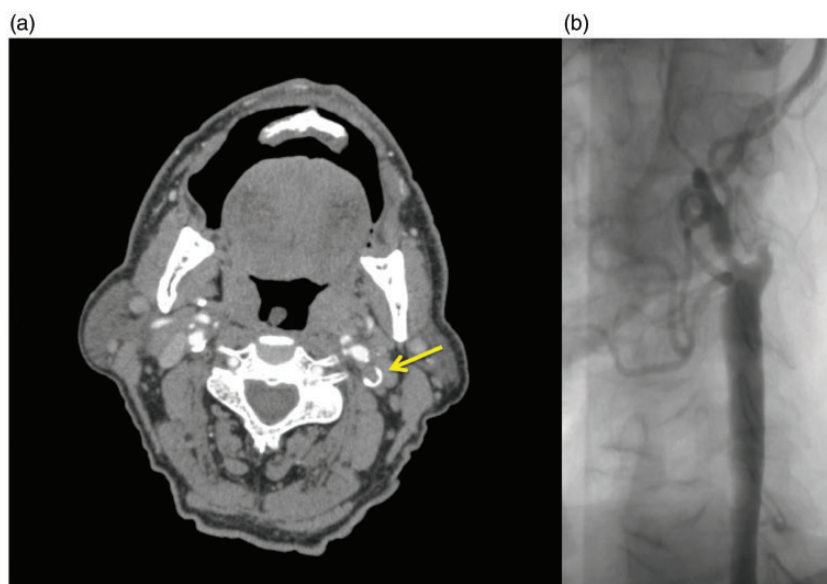


Figure 1. CT angiography of supra-aortic vessels showing the occlusion of the left internal carotid artery (a, arrow). Carotid angiogram showing the occlusion at the origin of the left internal carotid artery (b).

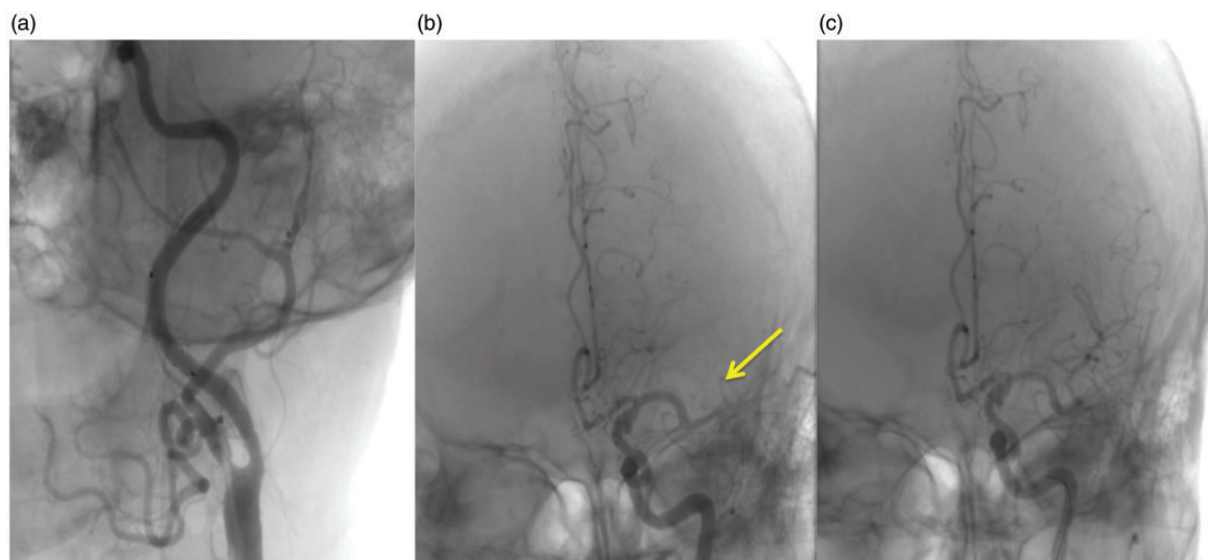


Figure 2. Carotid angiogram performed through the MOMA proximal protection system, showing flow restoration after stent implantation in the internal carotid artery (a). Cerebral angiogram of intracranial vessels, showing clot embolization in the middle cerebral artery (b). Middle cerebral artery after revascularization by balloon PTA (c).

distal cerebral protection with both filter-wire and MOMA system, we first performed thrombus aspiration and then proceeded with stent implantation in the ICA (Figure 2 (a)). A cerebral angiogram, performed to check the status of intracranial vessels, highlighted clot embolization in the middle cerebral artery (Figure 2(b)) requiring immediate revascularization with 2.0/15 mm balloon angioplasty (Figure 2(c)). Finally, we completed the revascularization with PCI

and bare metal stent positioning in the RCA, with flow restoration and resolution of ST elevation. Patient's clinical conditions improved significantly in the following hours; however, pharmacological sedation for psychomotor agitation was required for 48 h. Dual antiplatelet therapy based on acetylsalicylic acid (100 mg) and clopidogrel (75 mg) was immediately started with loading dose administration. Low-molecular weight heparin was also continued during

hospitalization and for the following two weeks. On day 5, functional recovery of the right arm occurred, and on day 7, he achieved complete movement restoration with residual aphasia (NIHSS 13).

Discussion and review of the literature

Current standard treatment of AS is represented by administration of tissue plasminogen activator (tPA), with several limitations in terms of short therapeutic time window (within 4.5 h of symptom onset) and exclusion criteria such as evidence or history of intracranial hemorrhage, severe uncontrolled hypertension, recent surgery, head trauma or stroke in the previous three months, and coagulopathy.¹ Moreover, some evidence showed poor efficacy of this treatment in AS due to big-size proximal vessels occlusions (i.e. middle cerebral artery), with low rate of recanalization, depending on high thrombus length (>8 mm).

Percutaneous treatment of AS, as shown in our case report, has several similarities to the “primary” treatment of acute myocardial infarction, and its importance has been much debated in the past years. It includes both local infusion of tPA for clot dissolution and mechanical recanalization by thrombus aspiration or retrieval with dedicated devices.

Due to the infrequency of contemporary onset of AS and STEMI, a specific antithrombotic regimen is not recognized for this setting. As always preferable it should be tailored on individual patients’ ischemic and hemorrhagic risks. In our case, the choice to administer clopidogrel instead of newer P2Y12 inhibitors was based on the presence of acute stroke (ruling out Prasugrel) with rapid evolution of the clinical setting and high risk of hemorrhagic progression (ruling out ticagrelor).²

Recently, several studies evaluated the effects of endovascular strategy vs. thrombolysis on clinical outcomes, and interesting meta-analysis further examined these data.^{3,4} Eight multicenter randomized trials, enrolling more than 2400 patients, have been published between 2013 and 2015; about 1300 patients underwent endovascular treatment and 1100 received standard medical therapy. Mechanical thrombectomy showed improvement in terms of functional outcomes and angiographic revascularization at 24 h, especially in cases of proximal arterial occlusion and using stent-retriever devices; there were no differences about intracranial hemorrhage incidence and mortality at 90 days in the overall population (Table 1).

The three previous trials (SYNTHESIS, MR RESCUE, and IMS III) published in 2013 reported negative data for endovascular intervention, showing no significant benefit over thrombolysis.^{5–7} However, major limitations of these studies were inaccurate randomization (non-imaging guided for low availability of CT angiography), variable use of tPA in the endovascular treatment group, and use of outdated (first-generation) mechanical thrombectomy devices.

The five more recent trials (MR-CLEAN, ESCAPE, EXTEND-IA, SWIFT-PRIME, and REVASCAT) published in 2015 have overcome these limitations showing a relative benefit of endovascular interventions further increased by the association of tPA, over thrombolysis alone.^{8–11} Routine use of newer stent-retriever devices for thrombectomy, as well as the time to treatment, significantly influenced the efficacy of this treatment in recent trials. Current guidelines recommend performing endovascular treatment, for all patients with AS caused by a major artery occlusion, possibly within 6 h from symptom onset. A recent meta-analysis from the HERMES group identified a significant benefit of treatment, in terms of lower

Table 1. Results from the most important randomized trials comparing endovascular vs medical treatment of acute stroke.

RCTs	Functional independence (mRS: 0–2) at 90 days				Revascularization at 24 h				Symptomatic intracranial hemorrhage within 90 days			
	Endovasc. therapy (events)	Standard therapy (events)	Odds ratio (95% CI)	P	Endovasc. therapy (events)	Standard therapy (events)	Odds ratio (95% CI)	P	Endovasc. therapy (events)	Standard therapy (events)	Odds ratio (95% CI)	P
2013 Negative Trials												
SYNTHESIS	76/181	84/181	0.84 (0.55–1.27)	.40	–	–	–	–	10/181	10/181	1.00 (0.41–2.46)	>.99
MR RESCUE	12/64	11/54	0.90 (0.36–2.25)	.82	–	–	–	–	3/64	2/54	1.28 (0.21–7.95)	.79
IMS III	177/415	86/214	1.11 (0.79–1.55)	.55	–	–	–	–	27/434	13/222	1.07 (0.54–2.11)	.85
2015 Positive Trials												
MR CLEAN	76/233	51/267	2.05 (1.36–3.09)	.001	141/187	68/207	6.27 (4.03–9.74)	<.001	18/233	17/267	1.23 (0.62–2.45)	.55
ESCAPE	87/164	43/147	2.73 (1.71–4.37)	<.001	113/156	43/138	5.81 (3.51–9.60)	<.001	6/165	4/150	1.38 (0.38–4.98)	.63
EXTEND-IA	25/35	14/35	3.75 (1.38–10.17)	.009	33/35	15/35	22.00 (4.55–106.43)	<.001	0/35	2/35	0.19 (0.01–4.08)	.29
SWIFT-PRIME	59/98	33/93	2.75 (1.53–4.94)	.001	53/64	21/52	7.11 (3.03–16.7)	<.001	1/98	3/97	0.32 (0.03–3.16)	.33
REVASCAT	45/103	29/103	1.98 (1.11–3.53)	.02	–	–	–	–	5/103	2/103	2.58 (0.49–13.59)	.27
Overall	557/1293	351/1094	1.71 (1.18–2.49)	.005	340/442	147/432	6.49 (4.79–8.79)	<.001	70/1313	53/1109	1.12 (0.77–1.63)	.56

mRS: modified Rankin Scale; RCT: randomized controlled trial.

degrees of disability at three months (modified Rankin Scale, mRS score of 0–2), for procedures started within 7.3 h after symptom onset.¹²

The importance of the “timing” for treatment of AS is nowadays common knowledge, so that the principle “time is muscle” has been translated to “time is brain,” and interventional cardiologists could play a crucial role to effectively respond to this healthcare challenge.

The recently published PRAGUE-16 Registry evaluated the feasibility and safety of direct endovascular thrombectomy, not preceded by tPA, performed by cardiologists in Interventional Cardiology department, in cooperation with neurologists and radiologists.¹³ It was a prospective, observational pilot registry, including 103 patients with less than 6 h onset of AS and CT scan evidence of major artery occlusion without large cerebral ischemia; patients were treated by direct catheter-based thrombectomy (73 patients) vs. double treatment with tPA plus endovascular intervention (30 patients), based on clinical picture and CT scan. Similar results have been achieved in both groups, with good functional recovery (mRS score of 0–2 at 90 days) in about 40% of patients, interesting if compared with only 30% recovery in patients who received medical treatment alone (tPA) in previous trials.

Conclusions

Direct catheter-based thrombectomy, if performed within the appropriate window of time in selected patients, represents a valid and faster alternative to thrombolysis (alone or bridging to the intervention). Because of the lack of an organized Interventional Neuroradiology service in many countries, dedicated to 24 h treatment of AS, interventional cardiologists with their consolidated experience in endovascular procedures could be involved in this network, in a multidisciplinary effort targeted to the setting up of a stroke management system.


Declaration of conflicting interests

The author(s) declared no potential conflicts of interest with respect to the research, authorship, and/or publication of this article.

Funding

The author(s) received no financial support for the research, authorship, and/or publication of this article.

ORCID iD

Giampiero Vizzari  <https://orcid.org/0000-0002-7672-2291>

References

1. Emberson J, Lees KR, Lyden P, et al. Effect of treatment delay, age, and stroke severity on the effects of intravenous thrombolysis with alteplase for acute ischaemic stroke: a meta-analysis of individual patient data from randomised trials. *Lancet* 2014; 384: 1929–1935.
2. Valgimigli M, Bueno H, Byrne RA, et al. 2017 ESC focused update on dual antiplatelet therapy in coronary artery disease developed in collaboration with EACTS: The Task Force for dual antiplatelet therapy in coronary artery disease of the European Society of Cardiology (ESC) and of the European Association for Cardio-Thoracic Surgery (EACTS). *Eur Heart J* 2018; 39: 213–260.
3. Badhiwala JH, Nassiri F, Alhazzani W, et al. Endovascular thrombectomy for acute ischemic stroke: a meta-analysis. *JAMA* 2015; 314: 1832–1843.
4. Ferrante G, Nuzzi NP, Stefanini GG, et al. Endovascular treatment vs. intravenous thrombolysis alone for ischaemic stroke: a meta-analysis of randomised controlled trials. *EuroIntervention* 2016; 12: e271–e281.
5. Ciccone A, Valvassori L, Nichelatti M, et al. Endovascular treatment for acute ischemic stroke. *N Engl J Med* 2013; 368: 904–913.
6. Kidwell CS, Jahan R, Gornbein J, et al. A trial of imaging selection and endovascular treatment for ischemic stroke. *N Engl J Med* 2013; 368: 914–923.
7. Broderick JP, Palesch YY, Demchuk AM, et al. Endovascular therapy after intravenous t-PA versus t-PA alone for stroke. *N Engl J Med* 2013; 368: 893–903.
8. Berkhemer OA, Fransen PS, Beumer D, et al. A randomized trial of intraarterial treatment for acute ischemic stroke. *N Engl J Med* 2015; 372: 11–20.
9. Goyal M, Demchuk AM, Menon BK, et al. Randomized assessment of rapid endovascular treatment of ischemic stroke. *N Engl J Med* 2015; 372: 1019–1030.
10. Saver JL, Goyal M, Bonafe A, et al. Stent-retriever thrombectomy after intravenous t-PA vs. t-PA alone in stroke. *N Engl J Med* 2015; 372: 2285–2295.
11. Jovin TG, Chamorro A, Cobo E, et al. Thrombectomy within 8 hours after symptom onset in ischemic stroke. *N Engl J Med* 2015; 372: 2296–2306.
12. Saver JL, Goyal M, van der Lugt A, et al. Time to treatment with endovascular thrombectomy and outcomes from ischemic stroke: a meta-analysis. *JAMA* 2016; 316: 1279–1288.
13. Widimsky P, Koznar B, Peisker T, et al. Feasibility and safety of direct catheter-based thrombectomy in the treatment of acute ischaemic stroke. Cooperation among cardiologists, neurologists and radiologists. Prospective registry PRAGUE-16. *EuroIntervention* 2017; 13: 131–136.