

# Pregnancy following Unilateral Immediate Breast Reconstruction with Titanized Polypropylene Mesh (TiLOOP(R) Bra) without Compromising the Result

Elke Nolte, PhD\*  
 Evelyn Klein, MD†  
 Stefan Paepke, MD†

**Summary:** Immediate breast reconstruction after mastectomy due to cancer or as a prophylactic treatment is widely preferred to avoid psychosocial distress, poor body image, and diminished sexual well-being. An increasing number of women undergoing breast reconstruction are in childbearing age; however, only limited data are available on the cosmetic outcome of patients undergoing implant-based breast reconstruction with a surgical mesh and subsequent pregnancy. This is a case report of a female patient who underwent unilateral implant-based breast reconstruction with a titanized surgical mesh implant (TiLOOP Bra). Twenty-two months after reconstruction, the woman delivered a healthy child. No adverse events occurred. The patient breastfed with the contralateral breast. The cosmetic result and patient-reported outcome was excellent. Pregnancy after breast reconstruction with a synthetic surgical mesh is not contradictory to an excellent cosmetic outcome. (*Plast Reconstr Surg Glob Open* 2018;6:e1919; doi: 10.1097/GOX.0000000000001919; Published online 14 September 2018.)

With estimated 1.7 million cases worldwide<sup>1</sup> and 70,000 newly diagnosed cases in Germany,<sup>2</sup> breast cancer is the most common cancer in women and leading cause of cancer-related death. Although the median age at diagnosis is 64 years, more than 30% of the women are younger than 55 years.<sup>2</sup> The European Commission identified an increasing age of women having children due to academic, professional, or personal reasons. Thus, the likelihood for women at childbearing age for becoming pregnant during or after breast cancer treatment is increasing. To avoid psychosocial distress, poor body image, and diminished sexual well-being an immediate breast reconstruction (IBR) after mastectomy is preferred.<sup>3</sup> Breast reconstruction (BR) can be performed

either with autologous tissue or implant-based, optionally with further implant coverage by biological or synthetic matrices.<sup>4</sup> Most information concerning pregnancy during or following BR is related to autologous BR.<sup>5-14</sup> To date, only 1 case description of pregnancy after subcutaneous mastectomy and BR using an implant<sup>15</sup> and only 1 case report describing successful BR during pregnancy with tissue expander and biological matrix are available.<sup>16</sup>

Here, we present 1 patient with successful aesthetic result following unilateral implant-based BR with a synthetic mesh and subsequent pregnancy.

## CASE REPORT

In May 2015, a 39-year-old woman (otherwise healthy, nonsmoker, body mass index of 24.3) presented with a ductal carcinoma in situ (Tis, N0, M0) in the right breast. The patient was included in the national, multicenter study "Patient Reported Outcome in Breast Reconstruction Following Mastectomy With TiLOOP(R) Bra," which started in December 2013 after approval by the respective local ethics committees and is conducted in accordance with the Declaration of Helsinki (2013; clinicaltrials.gov, NCT01885572).


From the \*pfm medical ag, Cologne, Germany; and †Department of Obstetrics and Gynecology, Technical University of Munich, Munich, Germany.

Received for publication January 19, 2018; accepted July 11, 2018.

Clinical trial registration: [www.clinicaltrials.gov](http://www.clinicaltrials.gov), NCT01885572. This study was conducted in accordance with the Declaration of Helsinki and approved by the local institutional review board.

Copyright © 2018 The Authors. Published by Wolters Kluwer Health, Inc. on behalf of The American Society of Plastic Surgeons. This is an open-access article distributed under the terms of the Creative Commons Attribution-Non Commercial-No Derivatives License 4.0 (CCBY-NC-ND), where it is permissible to download and share the work provided it is properly cited. The work cannot be changed in any way or used commercially without permission from the journal. DOI: 10.1097/GOX.0000000000001919

**Disclosure:** Dr. Paepke is a member of the advisory board of pfm medical ag and received honoraria, support of travel / travel reimbursement, and support of surgical workshops. Dr. Nolte is a permanent employee of pfm medical ag, Cologne, Germany. Dr. Klein has nothing to disclose. The Article Processing Charge was paid for by the authors.



**Fig. 1.** TiLOOP(R) Bra surgical mesh.

The patient underwent uncomplicated unilateral skin and nipple-sparing mastectomy with immediate BR in the right breast with prepectoral placement of a round implant (Mentor, Hallbergmoos, Germany) supported for complete implant-coverage and -stabilization with 2 non-absorbable titanized polypropylene meshes caudal and cranial (TiLOOP(R) Bra medium extralight, pfm medical ag, Cologne, Germany). The patient did not undergo radio- or chemotherapy before or after mastectomy. During the postoperative period, the woman did not experience any complications.

The mesh implant TiLOOP(R) Bra has been approved for use in breast surgery since 2008 in Europe. It is a large-pore, nonabsorbable mesh made from monofilament polypropylene thread with surrounding titanium containing coating (Fig. 1).<sup>17,18</sup>

Twenty-two months after BR, the woman gave birth to 1 healthy child. The pregnancy was uneventful, and cosmetic result postpartum compared with the cosmetic outcome before pregnancy was still excellent. Before pregnancy, both breasts had same size and shape (Fig. 2). After pregnancy, the left, nonoperated breast showed a bigger size than the right, operated breast (Fig. 2). As a study participant the patient had planned follow-up (FU) visits 6, 12, and 24 months after BR, which also included assessment of patient-reported outcome with the use of the BREAST-Q questionnaire.<sup>19</sup> The 2 years FU

**Table 1. Evaluation of Breast-Q Reconstruction Module**

Domains of Breast-Q Reconstruction Module	Preoperative	FU 6 mo	FU 1 y	FU 2 y
Satisfaction with breasts	100	100	100	100
Psychosocial well being	100	100	100	100
Physical well being: chest	71	63	68	77
Sexual well being	72	90	100	100
Satisfaction with outcome	—	100	100	100
Satisfaction with information	—	100	100	100
Surgeon	—	100	100	100
Medical staff	—	100	100	100
Office staff	—	100	100	100

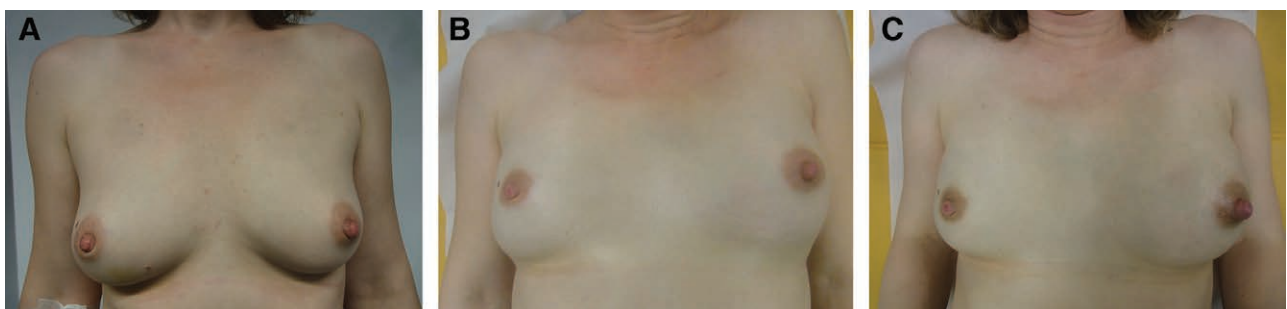
Breast-Q summary scores for 5 domains of the Breast-Q reconstruction module are given for the FU visits at 6 months, 1, and 2 years after BR. Maximum score is 100.

is the first time point after delivery. Concluding from the information provided in the BREAST-Q questionnaire, the patient showed high confidence with the cosmetic result and psychosocial well-being with maximum scores before up to 2 years after BR. Scores for sexual well-being increased from 72 points to maximum (100) from preoperative to 2 years scores (Table 1). Scores for physical well-being chest showed comparable results preoperatively and at 2 years FU (Table 1). The patient breastfed with the contralateral breast, as the glandular tissue was completely removed in the reconstructed breast no breast feeding was possible.

### DISCUSSION

Due to delay of childbearing, an increasing number of women in childbearing age undergo mastectomy with immediate or delayed BR with support of surgical meshes not only due to breast cancer but also prophylactic. Breast cancer patients may benefit from immediate BR as the period of psychosocial distress, poor body image, and diminished sexual well-being are reduced compared with those patients undergoing delayed BR.<sup>3</sup> The rapid and extensive physical changes during pregnancy and postpartum affecting all parts of the body, especially the breasts,<sup>20,21</sup> are a challenge in achieving a promising outcome of BR in women with the desire of having children.

Concerning the outcome of BR before or during pregnancy, most of the literature available is investigating the outcome of autologous BR with focus on the do-



**Fig. 2.** Cosmetic result before and after BR with implant and TiLOOP Bra mesh. A, Preoperative picture before BR and pregnancy. B, Same patient 18 months after BR and before pregnancy. C, Same patient 23 month after BR and 1 month postpartum.

nor site.<sup>7,10–14</sup> Although it was reported that postoperative pregnancy is associated with an increased risk of capsular contracture<sup>22</sup> in most of the articles, breast outcome is not mentioned; thus, it can be concluded that no adverse effects occurred in the breasts.<sup>23</sup>

Two retrospective studies investigated immediate BR with expander during pregnancy in 10 and 12 patients, respectively.<sup>24,25</sup> In the 10 patient cohort, all pregnancies resulted in live births; none of the patients experienced an adverse event related to the BR.<sup>24</sup> Of the 12 patients, 1 patient decided for abortion 2 weeks after surgery; the other 11 patients delivered live children, and no adverse events were reported.<sup>25</sup>

In 1 patient with early pregnancy after implant-based reconstruction at 5 months postmastectomy, a remarkable deformation of both breasts with increased size was observed. An improvement in deformation was observed in the later parts of pregnancy. However, in the end, a major revisional surgery was necessary.<sup>15</sup>

One case of BR is reported with the use of an acellular dermal matrix (Alloderm). Due to a phyllodes tumor, the patient underwent simple mastectomy with immediate BR in the second trimester of pregnancy. The authors conclude that mastectomy with immediate BR using tissue expanders with Alloderm placement can safely be performed during the second trimester of pregnancy.<sup>16</sup> However, to date, no information is available on the cosmetic result of pregnancy subsequent to immediate BR with a nonabsorbable polypropylene mesh. We presented a case report of a woman undergoing immediate, unilateral implant-based BR with TiLOOP(R) Bra. Twenty-two months after BR, the woman delivered a healthy child. The patient showed high confidence with the cosmetic result after reconstruction and also after childbirth. The nonoperated breast presented a greater volume in the nursing period which might, in the future, lead to a more pronounced ptosis, possibly requiring an adapting breast surgery.

## CONCLUSIONS

Our report illustrates the case of pregnancy after BR following skin- and nipple-sparing mastectomy with the support of TiLOOP(R) Bra surgical mesh. This demonstrates that pregnancy after BR with a synthetic surgical mesh is not compromising the aesthetic result. However, women desiring to have children after BR have to be consulted in detail about the possible consequences for the aesthetic outcome.

Stefan Paepke, MD  
 Klinik und Poliklinik für Frauenheilkunde  
 Technical University of Munich  
 Ismaninger Str. 22  
 81675 Munich, Germany  
 E-mail: stefan.paepke@lrz.tum.de

## REFERENCES

1. Torre LA, Bray F, Siegel RL, et al. Global cancer statistics, 2012. *CA Cancer J Clin.* 2015;65:87–108.
2. Robert Koch-Institut und die Gesellschaft der epidemiologischen Krebsregister. In Deutschland e.V., ed. *Krebs in Deutschland*

- 2011/2012. Berlin: Robert Koch-Institut und die Gesellschaft der epidemiologischen Krebsregister in Deutschland e.V.; 2015.
3. Zhong T, Hu J, Bagher S, et al. A comparison of psychological response, body image, sexuality, and quality of life between immediate and delayed autologous tissue breast reconstruction: a prospective long-term outcome study. *Plast Reconstr Surg.* 2016;138:772–780.
4. Logan Ellis H, Asaolu O, Nebo V, et al. Biological and synthetic mesh use in breast reconstructive surgery: a literature review. *World J Surg Oncol.* 2016;14:121.
5. Lawrence WT, McDonald HD. Pregnancy after breast reconstruction with a transverse rectus abdominis musculocutaneous flap. *Ann Plast Surg.* 1986;16:354–355.
6. Arruda EG, Munhoz AM, Montag E, et al. Immediate chest wall reconstruction during pregnancy: surgical management after extended surgical resection due to primary sarcoma of the breast. *J Plast Reconstr Aesthet Surg.* 2014;67:115–118.
7. Parodi PC, Osti M, Longhi P, et al. Pregnancy and tram-flap breast reconstruction after mastectomy: a case report. *Scand J Plast Reconstr Surg Hand Surg.* 2001;35:211–215.
8. Wagner LH, Ruth-Sahd LA. Pregnancy after a TRAM flap procedure: principles of nursing care. *J Obstet Gynecol Neonatal Nurs.* 2000;29:363–368.
9. Ong WC, Lim J, Lim TC. Successful pregnancy after breast reconstruction with the deep inferior epigastric perforator flap. *Plast Reconstr Surg.* 2004;114:1968–1970.
10. Bhat W, Akhtar S, Akali A. Pregnancy in the early stages following DIEP flap breast reconstruction—a review and case report. *J Plast Reconstr Aesthet Surg.* 2010;63:e782–e784.
11. Patel KM, Basci D, Nahabedian MY. Multiple pregnancies following deep inferior epigastric perforator (DIEP) flap breast reconstruction. *J Plast Reconstr Aesthet Surg.* 2013;66:434–436.
12. Collin TW, Coady MS. Is pregnancy contraindicated following free TRAM breast reconstruction? *J Plast Reconstr Aesthet Surg.* 2006;59:556–559.
13. Carramaschi FR, Ramos ML, Pinotti JA, et al. Pregnancy following breast reconstruction with TRAM flaps. *Breast J.* 1998;4:258–260.
14. Chai SC, Umayaal S, Saad AZ. Successful pregnancy “during” pedicled transverse rectus abdominis musculocutaneous flap for breast reconstruction with normal vaginal delivery. *Indian J Plast Surg.* 2015;48:81–84.
15. Gümüş N. Severe influence of early pregnancy on newly reconstructed breast. *Breast.* 2008;17:429–431.
16. Gentile LF, Gaillard WF, Wallace JA, et al. A case of a giant borderline phyllodes tumor early in pregnancy treated with mastectomy and immediate breast reconstruction. *Breast J.* 2016;22:683–687.
17. Casella D, Bernini M, Bencini L, et al. TiLoop® Bra mesh used for immediate breast reconstruction: comparison of retropectoral and subcutaneous implant placement in a prospective single-institution series. *European J Plast Surg.* 2014;37:599–604.
18. Dieterich M, Paepke S, Zwiefel K, et al. Implant-based breast reconstruction using a titanium-coated polypropylene mesh (TiLOOP Bra): a multicenter study of 231 cases. *Plast Reconstr Surg.* 2013;132:8e–19e.
19. Pusic AL, Klassen AF, Scott AM, et al. Development of a new patient-reported outcome measure for breast surgery: the BREAST-Q. *Plast Reconstr Surg.* 2009;124:345–353.
20. Strang VR, Sullivan PL. Body image attitudes during pregnancy and the postpartum period. *J Obstet Gynecol Neonatal Nurs.* 1985;14:332–337.
21. Skouteris H, Carr R, Wertheim EH, et al. A prospective study of factors that lead to body dissatisfaction during pregnancy. *Body Image.* 2005;2:347–361.

22. Dancey A, Nassimizadeh A, Levick P. Capsular contracture—what are the risk factors? A 14 year series of 1400 consecutive augmentations. *J Plast Reconstr Aesthet Surg.* 2012;65:213–218.
23. Alipour S, Eskandari A. Systematic review of effects of pregnancy on breast and abdominal contour after TRAM/DIEP breast reconstruction in breast cancer survivors. *Breast Cancer Res Treat.* 2015;152:9–15.
24. Caragacianu DL, Mayer EL, Chun YS, et al. Immediate breast reconstruction following mastectomy in pregnant women with breast cancer. *J Surg Oncol.* 2016;114:140–143.
25. Lohsiriwat V, Peccatori FA, Martella S, et al. Immediate breast reconstruction with expander in pregnant breast cancer patients. *Breast.* 2013;22:657–660.