

Azacytidine Treatment for VEXAS Syndrome

Marc H. G. P. Raaijmakers¹, Maud Hermans², Anna Aalbers^{1,2}, Melissa Rijken¹, Virgil A. S. H. Dalm^{2,3}, Paul van Daele^{2,3}, Peter J. M. Valk¹

Correspondence: Marc H. G. P. Raaijmakers (m.h.g.raaijmakers@erasmusmc.nl).

Vexas syndrome (vacuoles, E1 enzyme, X-linked, auto-inflammatory, somatic) is a recently identified, treatment-refractory, inflammatory syndrome developing in late adulthood with fevers, cytopenias, characteristic vacuoles in myeloid and erythroid precursor cells, dysplastic bone marrow, neutrophilic cutaneous and pulmonary inflammation, chondritis, vasculitis, and an often fatal outcome.^{1,2} Effective treatments have not yet been established. Here, we report genetic, morphologic, and clinical remissions in 2 of 3 VEXAS syndrome patients treated with the hypomethylating agent azacytidine.

Following the initial report by Beck et al,¹ we identified 6 cases at our institute with a clinical phenotype compatible with VEXAS syndrome. The presence of *UBA1* mutations in the majority of blood cells was confirmed in all patients and we detected concomitant mutations in the DNA (*cytosine-5*)-methyltransferase 3A (*DNMT3A*) gene in 3/6 patients with relatively high VAFs (30%–59%). *UBA1* mutation detection and panel-based sequencing is described in detail in Supplemental Digital Table 1, <http://links.lww.com/HS/A211>.

Three patients were treated with the hypomethylating agent azacytidine, among which two patients with a concomitant *DNMT3A* mutation, and these patients are described in detail in this report (Table 1). Azacytidine was administered at a dose of 75 mg/m² s.c. QD for 7 days in a 4-week schedule, as outlined in the case descriptions. The *DNMT3A* variants found in 2 patients involving the R882 and R688 residues are well known in the context of age-related clonal hematopoiesis (ARCH),^{3,4} and *DNMT3A* R882H and R688C are established as pathogenic variants in hematologic malignancies (respectively, COSV53036153 and COSV99258673). The third patient had a mutation in *TET2* in a small subset (VAF 4%) of hematopoietic cells, as can be observed in the context of ARCH.⁴

Case 1 is a male patient with a previous unnoticeable medical history who presented with a clinical phenotype that was characterized over time by fever, Sweet syndrome, cutaneous small-vessel vasculitis, relapsing polychondritis located in both ears and the nose, and scleritis (Table 1 and Figure 1A–D). Laboratory examination demonstrated an elevation of inflammatory parameters and a transfusion dependent macrocytic anemia with thrombocytopenia (Figure 1I). Bone marrow examination demonstrated hypercellularity, erythroid macrocytosis and a pronounced vacuolization in erythropoiesis and myelopoiesis in the context of mild dysplasia (Figure 1E). Dysplasia scores varied in subsequent aspirates over time (Table 1), while the pronounced vacuolization with toxic granulation of myeloid cells was a consistent finding in multiple bone marrow examinations. No ringsideroblasts were noted and there was no increase in blast frequency. No cytogenetic abnormalities were detected upon repeated testing.

The clinical course was characterized by a remitting relapsing pattern under prednisone maintenance (15 mg/d) with partial, temporary, responses to increasing doses of corticosteroids (10–60 mg) during exacerbation of clinical symptoms, with gradual overall worsening of the clinical condition to a WHO performance status of 4 in 2016 with wheel-chair dependency (due to fatigue) and persisting transfusion-dependency (2–4 units of red blood cells/month) throughout the years. The clinical picture was unresponsive to disease modifying antirheumatic drugs (DMARDs), such as azathioprine (150 mg/d), mycophenolic acid (360 mg twice daily), intravenous immunoglobulins (1 g/kg, every 4 wks for a total of 6 administrations), and erythroid-stimulating agents (darbopoietin 300 µg/wk, by subcutaneous injections).

A variant in the DNA methylase domain of the *DNMT3A* gene (NM_022552.4(DNMT3A):c.2062C>T; p.(Arg688Cys)) was detected at VAFs corresponding to a heterozygous mutation in virtually all mononuclear cells in the bone marrow that, in retrospect, co-occurred with an *UBA1* (NM_003334.3(UBA1):c.122T>C; p.(Met41Thr)) mutation in all available earlier bone marrow and blood samples (Figure 1J). Based on the presence of predominantly clonal hematopoiesis, a provisional diagnosis of “clonal hematopoiesis-associated inflammatory syndrome” was made and the lack of other options in this severely affected, refractory patient, prompted us to start treatment with azacytidine, for which anecdotal responses in MDS with inflammatory symptoms had been reported.⁵

The patient received azacytidine (75 mg/m² s.c. QD for 7 d in a 4-week schedule) from August 2016 for a total of 8 courses until April 2017. Administration of azacytidine was associated with rapid and complete disappearance of disease related inflammatory symptoms (polychondritis and Sweet syndrome), loss of transfusion-dependency with normalization of blood

¹Erasmus MC Cancer Institute, University Medical Center Rotterdam, Department of Hematology, Rotterdam, The Netherlands

²Department of Internal Medicine, Division of Allergy and Clinical Immunology, Erasmus University Medical Center, Rotterdam, The Netherlands

³Department of Immunology, Erasmus University Medical Center, Rotterdam, The Netherlands

Supplemental digital content is available for this article.

Copyright © 2021 the Author(s). Published by Wolters Kluwer Health, Inc.

on behalf of the European Hematology Association. This is an open-access article distributed under the terms of the Creative Commons Attribution-Non Commercial-No Derivatives License 4.0 (CCBY-NC-ND), where it is permissible to download and share the work provided it is properly cited. The work cannot be changed in any way or used commercially without permission from the journal. HemaSphere (2021) 5:12(e661).

<http://dx.doi.org/10.1097/HS9.0000000000000661>.

Received: 2 September 2021 / Accepted: 14 October 2021

Table 1.

Clinical Characteristics of Three Cases of VEXAS Syndrome Treated With Azacytidine.

| | Case 1 | Case 2 | Case 3 |
|--|----------------------------|----------------------------|--------------------------|
| Mutation UBA1^a | c.122T>C ^b | c.121A>G ^c | c.122T>C ^c |
| [first presentation] | (VAF 86%) | (VAF 56%) | (VAF 86%) |
| | p.Met41Thr | p.Met41Val | p.Met41Thr |
| Co-occurring mutations | <i>DNMT3A</i> ^d | <i>DNMT3A</i> ^d | <i>TET2</i> ^e |
| | c.2062C>T | c.2645G>A | c.2290dup |
| | (VAF 59%) ^f | (VAF 30%) | (VAF4%) |
| | Arg688Cys | Arg882His | p.(Gln764Profs*5) |
| Year of first symptoms | 2009 | 2018 | 2011 |
| Follow-up | Alive | Alive | Alive |
| Age at presentation (year) | 61 | 77 | 67 |
| Fever | + | + | + |
| Sweet syndrome | + | - | + |
| Cutaneous small-vessel vasculitis | + | + | + |
| Chondritis | + | - | + |
| Pulmonary infiltrates | - | + | - |
| Venous thromboembolism | - | - | - |
| Scleritis | + | - | + |
| Periorbital inflammation | - | + | - |
| Abducens paralysis | - | - | - |
| Axonal polyneuropathy | - | + | + |
| Macrocytic anemia | + | + | + |
| Thrombocytopenia | + | - | + |
| Leukopenia | - | - | + |
| C-reactive protein (mg/L) ^g | 189 | 160 | 150 |
| median (range) | (62–183) | (58–221) | (182–343) |
| ESR (mm/h) | 119 | 115 | 109 |
| median (range) | (98–150) | (49–150) | (50–119) |
| Bone marrow vacuoles | | | |
| Erythropoiesis | + | - | + |
| Granulopoiesis | + | + | + |
| Bone marrow dysplasia, range dysplasia score | | | |
| Erythropoiesis | <10%–39% | 0%–3% | 10%–26% |
| Granulopoiesis | 2%–14% | 0%–12% | 4%–19% |
| Megakaryopoiesis | 0%–47% | 0%–13% | 22%–23% |
| Bone marrow blast percentage | <2% | <2% | <5% |
| Bone marrow cytogenetics | 46XY | 46XY | 46XY |
| Response to corticosteroids | ± | ± | ± |
| Response to colchicin | - | N/A | N/A |
| Response to DMARDs | - | - | - |
| Response to anti-TNF α | N/A | - | N/A |
| Response to IVIG | - | N/A | N/A |
| Response to ESA | - | N/A | - |
| Response to azacytidine | + | + | - |

^aNM_003334.3 (UBA1).

^bBone marrow.

^cPeripheral blood.

^dNM_022552.4 (DNMT3A).

^eNM_001127208.2 (TET2).

^fSince the DNA for the detection of this *DNMT3A* variant at diagnosis was of limited quantity and quality no conclusion other than that the majority of cells carry a *DNMT3A* mutation can be drawn.

^gValues at flares of disease to avoid bias by treatment or intercurrent infections.

DMARDs = disease modifying antirheumatic drugs; azathioprine, mycophenolate, methotrexate; ESA = erythropoietin stimulating agent; ESR = erythrocyte sedimentation rate; IVIG = intravenous immunoglobulins; N/A = not applicable.

values and inflammatory parameters and eradication of the *UBA1-DNMT3A* mutated clone (VAF 92% (mutant *UBA1*) and 41% (mutant *DNMT3A*) to 1% (mutant *UBA1*) and 1% (mutant *DNMT3A*)) (Figure 1F–J). Improvement of blood values was already apparent after 2 cycles with disappearance of

transfusion dependency. The azacytidine was stopped because of remitting diverticulitis and a diagnosis of local colorectal adenocarcinoma for which a laparoscopic subtotal colectomy was performed in September 2017. The patient has not received azacytidine, or any other disease modulating drug, since, and corticosteroid exposure was weaned.

The clinical course since 2017 is characterized by a persistent complete long-term remission without any VEXAS-related disease symptoms (or any other pathology), an ongoing WHO performance status of 0, normal blood values and continued suppression of the mutant *UBA1* clone in blood and bone marrow for now 4.5 years after the last azacytidin administration (Figure 1).

Case 2 is a male patient who presented with a clinical picture of recurrent episodes of fever, leukocytoclastic vasculitis, periorbital inflammation, relapsing chondritis located in both ears, lung infiltrates, axonal polyneuropathy of the feet, and macrocytic anemia. Laboratory examination demonstrated recurrent elevation of inflammatory parameters during episodes of exacerbation. Bone marrow examination in March 2021 demonstrated normocellularity without signs of dysplasia but pronounced vacuolization of myelopoiesis (Supplemental Digital Figure 1A, <http://links.lww.com/HS/A211>). No cytogenetic abnormalities were detected upon repeated testing. The diagnosis VEXAS syndrome was confirmed by the demonstration of the *UBA1* mutation in the bone marrow (c.121A>G; p.Met41Val; VAF 56%) as well as a mutation in the *DNMT3A* gene (c.2645G>A, Arg882His; VAF 30%). The similar VAFs strongly suggest the co-existence of the *UBA1* and *DNMT3A* mutations in approximately 60% of all bone marrow cells (of note, the *UBA1* gene is X-linked resulting in VAFs twice as high as those of *DNMT3A*). The patient did not fulfill diagnostic WHO 2016 criteria for MDS.

The disease was refractory to azathioprine (150 mg once daily) and anakinra (100 mg once daily) and high-dose corticosteroids (15–40 mg/d) were required to maintain control of inflammation, which he poorly tolerated. Azacytidine (75 mg/m² s.c. QD for 7 d in a 4-week schedule) was started on March 22, 2021 (1.3 y after first presentation) for a total of 3 courses until June 2021. Response evaluation after 3 cycles of azacytidine demonstrated near complete eradication of the *UBA1-DNMT3A* mutated clone (VAF 52% [mutant *UBA1*] and 28% [mutant *DNMT3A*] to <1% [mutant *UBA1*] and 2% [mutant *DNMT3A*] with normalization of bone marrow abnormalities [Supplemental Digital Figure 1A and B, <http://links.lww.com/HS/A211>]). The clinical course was characterized by gradual improvement of periocular complaints without new episodes of systemic inflammation under successful tapering of prednisone dose to 7.5 mg once daily currently.

Case 3 is a male with chondritis, Sweet syndrome, vasculitis, axonal neuropathy, and pancytopenia. The clinical syndrome was unresponsive to mycophenolic acid (360 mg twice daily) and erythroid-stimulating agents and displayed a relapse/remitting pattern under corticosteroid maintenance treatment (7.5–60 mg once daily). Bone marrow examination (February 2021) demonstrated hypercellularity with pronounced vacuolisation of erythropoiesis and myelopoiesis and dysplasia >10% of the erythroid and megakaryocytic lineages. No cytogenetic abnormalities were detected upon repeated testing. The diagnosis VEXAS syndrome was made by the demonstration of the *UBA1* mutation in the bone marrow (c.122T>C, p.Met41Thr; VAF 86% (at the first presentation [Table 1]) in the bone marrow. In addition, a mutation in *TET2* (c.2290dup, p.(Gln764Profs*5); VAF4%) was detected. This low-level *TET2* mutation could either be part of the *UBA1* mutant cells or the result of ARCH. There were no variants detected in the *DNMT3A* gene in this VEXAS patient.

Azacytidine (75 mg/m² s.c. QD for 7 d in a 4-week schedule) was started in March 2021 for a total of 3 courses until May 2021. Azacytidine was discontinued after 3 cycles because of pulmonary

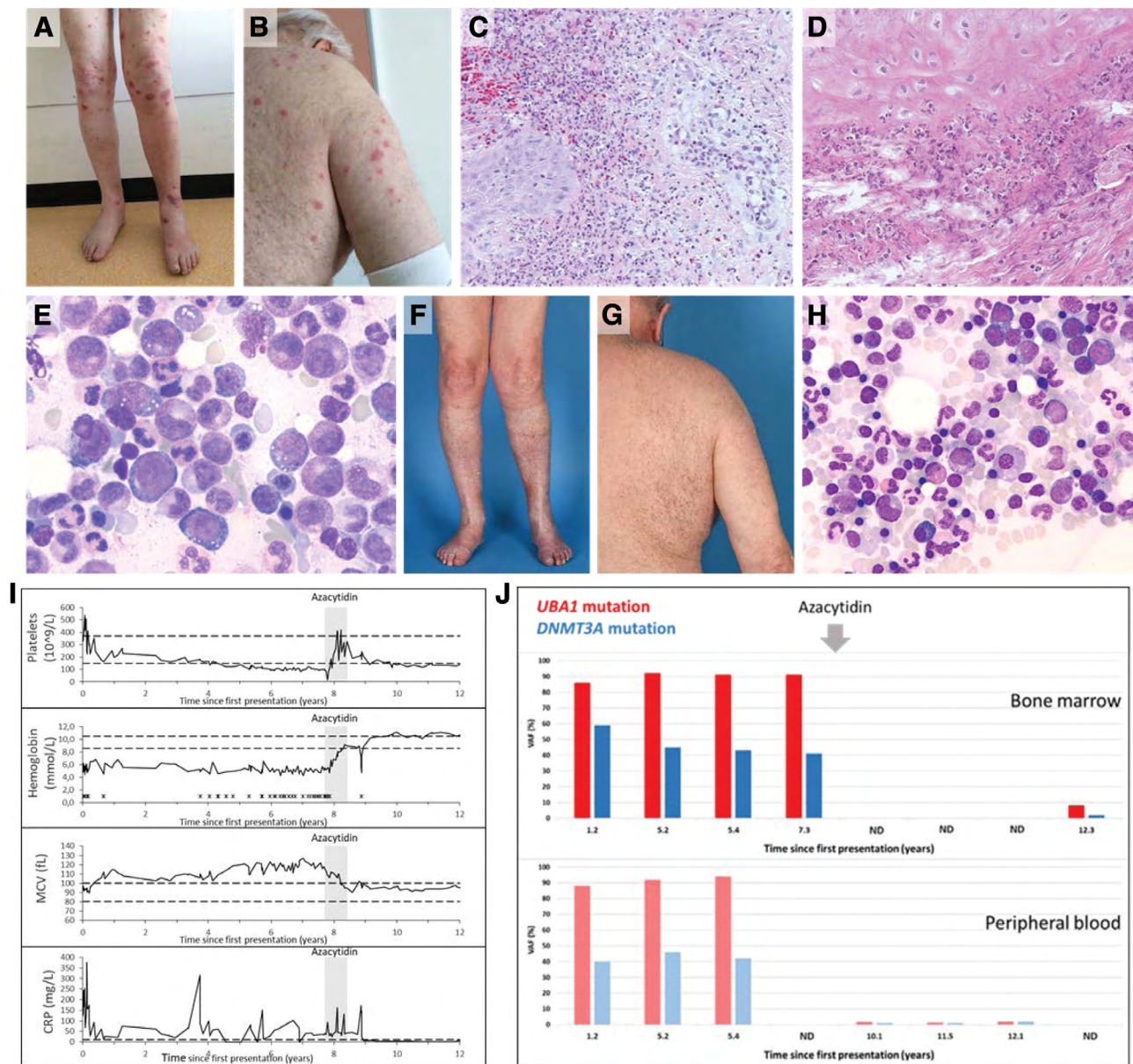


Figure 1. Clinical course and response to azacytidine in VEXAS syndrome (case 1). Skin lesions on extremities and trunk (A and B) and histopathological findings of a leg lesion (C) were consistent with a diagnosis of neutrophilic dermatosis or Sweet syndrome. A clinical picture of relapsing polychondritis corresponded with histopathological findings in an auricular biopsy (D). Bone marrow aspirate showed characteristic vacuolisation of erythroid and myeloid precursor cells (E). Skin lesions disappeared (F and G) and bone marrow cytology normalized (H) after azacytidine treatment (8 cycles). Hematoxylin and eosin staining was used in (C) and (D), and May-Grünwald Giemsa staining in (E) and (H) (magnification 10 × 100 and 10 × 63, respectively). (I) Laboratory parameters from start of first symptoms until last follow-up are shown. During and after azacytidine treatment (indicated by shaded area), laboratory parameters (platelet count, hemoglobin, MCV, and CRP levels) normalized. Horizontal dashed black lines in each graph represent lower and upper limits of the normal range for each variable. X: red blood cell transfusion. (J) Variant allele frequencies (VAFs) of *UBA1* and *DNMT3A* mutations in bone marrow (BM) and peripheral blood (PB) from start of first presentation (years) during and after azacytidine treatment demonstrating near complete eradication of the *UBA1-DNMT3A* mutated clone after azacytidine treatment. ND = no data.

pathology (interstitial pneumonitis, possibly related to azacytidine), which resolved. Response assessment after 3 cycles did not show reduction in disease burden (VAF *UBA1* 45% pretreatment and 43% post treatment) with persistent, unaltered, bone marrow abnormalities (vacuolization) (data not shown). The clinical course was characterized by persistent anemia and fatigue.

These cases demonstrate common co-occurrence of mutant *UBA1* with mutations in *DNMT3A*, substantiating the finding of a *DNMT3A* mutation in 2 of 9 tested VEXAS patients in the original description of the syndrome.¹

The etiology and pathogenetic significance of *DNMT3A* mutations in VEXAS syndrome remains to be elucidated. Both

DNMT3A and *UBA1* occurred at high VAFs in both patients, indicating that the vast majority of hematopoietic cells carried these mutations and that they therefore likely co-occurred in the same cell (in at least a fraction of cells). Loss-of-function mutations in *DNMT3A* may be hypothesized to contribute to the proinflammatory pathology in VEXAS syndrome since *DNMT3A* is thought to function as a repressor of inflammation⁶ and deficiency in *DNMT3A* has been associated with activation of innate immune inflammatory signaling in myeloid cells.⁷⁻⁹ We could not assess the clonal hierarchy because VAFs for *UBA1* and *DNMT3A* were approximately equally high for both mutations. It is, however, conceivable that mutations in *DNMT3A*

provide a competitive advantage to *UBA1* mutated cells because they confer “resistance” to apoptosis caused by inflammatory stress in hematopoietic progenitor cells.¹⁰ Acquisition of a *DNMT3A* mutation may therefore provide *UBA1* mutated cells with a competitive survival advantage in the VEXAS inflammatory micromilieu in the bone marrow.

Another interesting aspect of the reported cases is the distinction between VEXAS syndrome and MDS. Formally, the 3 cases described herein would have met the WHO2016 classification criteria for the diagnosis of MDS¹¹ at some, but, importantly, not all moments of evaluation in their disease course. This is illustrated by case 2, in whom pancytopenia and myelodysplasia in 10%–15% of hematopoietic cells in two lineages was observed at a time of severe systemic inflammatory exacerbation, but no longer later in the course of disease when acute inflammatory symptoms had waned. This illustrates that severe systemic inflammation caused by VEXAS syndrome may cause myelodysplasia and cytopenia which may lead to a presumptive diagnosis of MDS, but this diagnosis requires exclusion of non-malignant causes of dysplasia and, in hindsight, a clinical and genetic diagnosis of VEXAS syndrome could be made in these patients.

Both patients with VEXAS syndrome associated with *DNMT3A* mutations displayed a genetic and clinical response to azacytidine, while another patient, not carrying concurrent *DNMT3A* mutations, was unresponsive to the drug. Future clinical trialing should elucidate whether response to azacytidine is indeed associated with the *DNMT3A* mutational status. Interestingly, *DNMT3A* mutations in MDS are not uniformly related to favorable responses to hypomethylating agents,¹² but recently it was shown that *DNMT3A*^{R882} mutations may sensitize hematopoietic cells to azacytidine.¹³

Our findings bring further the interesting observations in a recent retrospective survey of treatment modalities in VEXAS syndrome in which treatment of azacytidine in four patients was associated with a time-to-next line of treatment of 39.7 months in one patient, suggesting responsiveness to the drug in a subset of VEXAS syndrome patients.¹⁴

Collectively, the data prompt the consideration of treatment with azacytidine on a trial basis in severe cases of VEXAS syndrome, in particular when associated with *DNMT3A* mutations. Future clinical trials will be pivotal to investigate the exact value of azacytidine in subsets of patients with VEXAS syndrome.

Acknowledgments

The authors would like to acknowledge Dr Kirsten Gussinklo (Department of Hematology) and Dr King Lam (Department of

Pathology) for cytologic and histologic evaluation and providing images presented in this article.

Disclosures

The authors have no conflicts of interest to disclose.

References

1. Beck DB, Ferrada MA, Sikora KA, et al. Somatic mutations in *UBA1* and severe adult-onset autoinflammatory disease. *N Engl J Med*. 2020;383:2628–2638.
2. Grayson PC, Patel BA, Young NS. VEXAS syndrome. *Blood*. 2021;137:3591–3594.
3. Genovese G, Kähler AK, Handsaker RE, et al. Clonal hematopoiesis and blood-cancer risk inferred from blood DNA sequence. *N Engl J Med*. 2014;371:2477–2487.
4. Jaiswal S, Fontanillas P, Flannick J, et al. Age-related clonal hematopoiesis associated with adverse outcomes. *N Engl J Med*. 2014;371:2488–2498.
5. Fraison JB, Mekinian A, Grignano E, et al. Efficacy of Azacitidine in autoimmune and inflammatory disorders associated with myelodysplastic syndromes and chronic myelomonocytic leukemia. *Leuk Res*. 2016;43:13–17.
6. Leoni C, Montagner S, Rinaldi A, et al. *Dnmt3a* restrains mast cell inflammatory responses. *Proc Natl Acad Sci U S A*. 2017;114:E1490–E1499.
7. Abplanalp WT, Cremer S, John D, et al. Clonal hematopoiesis-driver *DNMT3A* mutations alter immune cells in heart failure. *Circ Res*. 2021;128:216–228.
8. Li X, Zhang Q, Ding Y, et al. Methyltransferase *Dnmt3a* upregulates HDAC9 to deacetylate the kinase TBK1 for activation of antiviral innate immunity. *Nat Immunol*. 2016;17:806–815.
9. Lim JY, Duttke SH, Baker TS, et al. *DNMT3A* haploinsufficiency causes dichotomous DNA methylation defects at enhancers in mature human immune cells. *J Exp Med*. 2021;218:e20202733.
10. Hormaechea-Agulla D, Matatall KA, Le DT, et al. Chronic infection drives *Dnmt3a*-loss-of-function clonal hematopoiesis via IFN γ signaling. *Cell Stem Cell*. 2021;28:1428–1442.e6.
11. Arber DA, Orazi A, Hasserjian R, et al. The 2016 revision to the World Health Organization classification of myeloid neoplasms and acute leukemia. *Blood*. 2016;127:2391–2405.
12. Falconi G, Fabiani E, Piciocchi A, et al. Somatic mutations as markers of outcome after azacitidine and allogeneic stem cell transplantation in higher-risk myelodysplastic syndromes. *Leukemia*. 2019;33:785–790.
13. Scheller M, Ludwig AK, Göllner S, et al. Hotspot *DNMT3A* mutations in clonal hematopoiesis and acute myeloid leukemia sensitize cells to azacytidine via viral mimicry response. *Nat Cancer*. 2021;2:527–544.
14. Bourbon E, Heiblig M, Gerfaud Valentin M, et al. Therapeutic options in VEXAS syndrome: insights from a retrospective series. *Blood*. 2021;137:3682–3684.