



# Comparison of Ranibizumab Treatment Response of Superior and Inferior Temporal Branch Retinal Vein Occlusion: A Year Follow-Up

Esra Turkseven Kumral,<sup>1</sup> Nursal Melda Yenerel,<sup>1</sup> Nimet Yesim Ercalik,<sup>1</sup> Levent Karabas<sup>2</sup>

<sup>1</sup>Department of Ophthalmology, Haydarpasa Numune Training and Research Hospital, Istanbul, Türkiye

<sup>2</sup>Department of Ophthalmology, Kocaeli University Hospital, Kocaeli, Türkiye

## Abstract

**Objectives:** The aim of the study was to compare ranibizumab treatment response of macular edema secondary to superior and inferior temporal branch retinal vein occlusion.

**Methods:** Sixty-four eyes of 64 patients treated with 0.5 mg/0.05 mL ranibizumab due to macular edema secondary to branch retinal vein occlusion were enrolled in this retrospective study. Thirty-eight eyes with superior temporal branch retinal vein occlusion were classified as Group 1 and 26 eyes with inferior temporal branch retinal vein occlusion as Group 2. Best-corrected visual acuity (BCVA), central macular thickness (CMT), and the number of intravitreal injections were evaluated and compared between the groups.

**Results:** The mean baseline, 3<sup>rd</sup>, 6<sup>th</sup>, 9<sup>th</sup>, and 12<sup>th</sup> month BCVA values in Group 1 were  $0.77 \pm 0.47$ ,  $0.37 \pm 0.20$ ,  $0.37 \pm 0.22$ ,  $0.38 \pm 0.24$ , and  $0.35 \pm 0.18$  logarithm of the minimum angle of resolution (logMAR) and in Group 2 were  $0.75 \pm 0.45$ ,  $0.37 \pm 0.18$ ,  $0.35 \pm 0.19$ ,  $0.32 \pm 0.17$ , and  $0.28 \pm 0.20$  logMAR, respectively. The mean baseline, 3<sup>rd</sup>, 6<sup>th</sup>, 9<sup>th</sup>, and 12<sup>th</sup> month CMT values in Group 1 were  $522.92 \pm 136.01$ ,  $318.03 \pm 66.65$ ,  $287.53 \pm 48.27$ ,  $271.95 \pm 32.47$ , and  $280.47 \pm 91.66$   $\mu\text{m}$  and in Group 2 were  $524.08 \pm 145.51$ ,  $289.85 \pm 53.08$ ,  $268.96 \pm 31.57$ ,  $260.77 \pm 30.22$ , and  $244.04 \pm 44.78$   $\mu\text{m}$ , respectively. BCVA and CMT improved significantly within both groups after the treatment ( $p < 0.05$ ) and there was no statistically significant difference between the groups ( $p > 0.05$ ). However, a significantly higher number of injections was needed for Group 1.

**Conclusion:** Ranibizumab improved the visual and anatomical outcomes similarly in both superior and inferior temporal branch retinal vein occlusion with macular edema. However, more frequent injections were needed to achieve the same efficacy in superior temporal branch retinal vein occlusion.

**Keywords:** Branch retinal vein occlusion, central macular thickness, injection frequency, ranibizumab, visual acuity

## Introduction

Among retinal vascular diseases, retinal vein occlusion is the second most common disorder and classified as a central, branch, and hemicentral according to the site of obstruction (1). About

80% of retinal vein occlusions are constituted of branch retinal vein occlusions (BRVO) (2). Because of the increased number of arteriovenous crossings in the superior temporal quadrant, more than 50% of BRVO occurred in this region (3).

**How to cite this article:** Turkseven Kumral E, Yenerel NM, Ercalik NY, Karabas L. Comparison of Ranibizumab Treatment Response of Superior and Inferior Temporal Branch Retinal Vein Occlusion: A Year Follow-Up. Beyoglu Eye J 2022; 7(3): 207-212.

**Address for correspondence:** Esra Turkseven Kumral, MD. Department of Ophthalmology, Haydarpasa Numune Training and Research Hospital, Istanbul, Türkiye

**Phone:** +90 532 220 37 09 **E-mail:** dresraturkseven@yahoo.com

**Submitted Date:** February 20, 2022 **Accepted Date:** May 06, 2022 **Available Online Date:** August 05, 2022

©Copyright 2022 by Beyoglu Eye Training and Research Hospital - Available online at [www.beyoglu-eye.com](http://www.beyoglu-eye.com)

OPEN ACCESS This work is licensed under a Creative Commons Attribution-NonCommercial-ShareAlike 4.0 International License.



Macular edema is the main factor responsible for visual loss in BRVO (4). According to Starling's law, the hydrostatic and osmotic pressure gradients between blood vessel and tissue regulate the fluid flow between these compartments. In healthy eyes, these gradients are equal and no net movement is observed between vessel and tissue. If either gradient is disrupted by retinovascular diseases macular edema develops (5). Furthermore, vasopermeability factors such as vascular endothelial growth factor (VEGF), interleukin 6 (IL-6), and other inflammatory mediators secreted from a hypoxic retina increase vascular permeability and contribute to the breakdown of the blood-retinal barrier that leads to macular edema formation. VEGF is the major factor that contributes to macular edema (6). Thus, intravitreally administered anti-VEGF agents have become widely used as a primary treatment for macular edema associated with BRVO (7).

Many studies have reported the effectiveness of anti-VEGFs in the treatment of BRVO with macular edema but it has not been investigated if there are any differences between the treatment responses of different occlusion sites. Therefore, the aim of this study was to investigate the anti-VEGF treatment responses of both the superior and inferior temporal BRVO.

## Methods

Sixty-four eyes of 64 patients treated with 0.5 mg/0.05 mL ranibizumab due to BRVO with macular edema were included in this retrospective study. Central macular thickness (CMT) of more than 300  $\mu\text{m}$  or subretinal fluid was accepted as macular edema. Treatment naive eyes received at least three consecutive monthly injections as a loading dose and pro re nata (PRN) injections afterward with a follow-up period of at least 12 months were included in the study. Patients were followed up monthly. Intravitreal dexamethasone implant and anti-VEGF injections other than ranibizumab, intravitreal treatment without a loading dose, irregular visits, follow-up period shorter than 12 months, cataract formation and surgery during the follow-up period, BRVO with other ocular pathologies such as the history of vitreoretinal surgery, uveitis, glaucoma, and diabetic retinopathy were the exclusion criteria. The written consent for treatment according to the tenets of the Declaration of Helsinki was collected from all patients. Institutional Board Review/Ethics Committee has ruled that approval was not required for the study because of its retrospective nature.

Thirty-eight eyes with superior temporal BRVO were classified as Group 1 and 26 eyes with inferior temporal BRVO as Group 2. Ophthalmologic examination was performed at presentation including best-corrected visual acuity (BCVA) measurement by Snellen Chart, anterior and posterior segment examination by slit-lamp biomicroscopy, and

intraocular pressure measurement by Goldmann applanation tonometer. Spectral-domain optical coherence tomography (Heidelberg Engineering, Heidelberg, Germany) was performed for the evaluation of CMT.

## Follow-up and Outcomes

After administration of three monthly intravitreal ranibizumab injections, patients were examined monthly for 12 months. The presence of subretinal fluid or CMT  $>300 \mu\text{m}$  was the reinjection criteria. The BCVA and CMT values were noted at the baseline, 3<sup>rd</sup>, 6<sup>th</sup>, and 12<sup>th</sup> visits. Fundus fluorescein angiography (VISUCAM 500; Carl Zeiss Meditec) was performed in all patients at month 3 after the withdrawal of retinal hemorrhages. Scatter laser photocoagulation was performed if the ischemic area was larger than the 5-disc area. The time between the first symptom to injection, type of macular edema at presentation, presence of retinal ischemia, and laser photocoagulation performed were recorded. The number of injections was calculated at the end of the follow-up period. BCVA and CMT values were compared between the groups at each time point.

## Intravitreal Injection Procedure

All injections were performed in the operating room, under sterile conditions. Eyelids and periocular tissues were cleaned with 10% povidone-iodine (Betadine; Purdue Pharma, Stamford, CT) and then topical 5% povidone-iodine was administered to the conjunctival sac. Intravitreal ranibizumab (0.5 mg/0.5 mL, Lucentis; Novartis, Basel, Switzerland) was injected through the pars plana 4 mm posterior to the limbus with a 30-gauge needle.

## Statistical Analysis

Statistical analysis was performed using SPSS version 22.0. Kolmogorov–Smirnov/Shapiro–Wilk tests were used to determine the normality of the distribution of data. The descriptive data were presented as means, standard deviations, and ordinal variables. The Mann–Whitney U-test was used to evaluate non-parametric statistical significance between the groups. The Friedman test was used for finding the differences in non-parametric repeated measures. Post hoc analysis with Wilcoxon signed-rank test was conducted with a Bonferroni correction applied for the intragroup comparison. The Pearson Chi-square statistic was used for testing relationships between categorical variables. The results were evaluated using the 95% confidence intervals and  $p < 0.05$  was statistically significant.

## Results

Sixty-four eyes treated with intravitreal ranibizumab due to macular edema secondary to BRVO were included in the study. Twenty-one (63.6%) were female and 17 (54.8%) were male in Group 1 and 12 (36.4%) were female and 14 (45.2%)

were male in Group 2. The mean age was 61.00±8.91 and 58.23±8.12 years in Groups 1 and 2, respectively. No significant difference was found in terms of age and sex (p>0.05). Eight eyes (21.05%) in Groups 1 and 2 eyes (7.69%) in Group 2 were pseudofakic. The mean time between the first symptom to injection was 35.26±36.00 days in Group 1 and 32.12±32.62 days in Group 2. The baseline and demographic characteristics of the two groups are summarized in Table 1.

**Visual Outcomes**

Table 2 and Figure 1 provides visual outcomes at baseline, month 3, 6, 9, and 12. The mean BCVA values did not differ between the groups at baseline or during the 3<sup>rd</sup>, 6<sup>th</sup>, 9<sup>th</sup>, and 12<sup>th</sup> month (p>0.05). However, there was a significant difference within both groups (p=0.001) Intragroup comparison of significance was calculated by post hoc analysis conducted with a Bonferroni correction. The BCVAs at the 3<sup>rd</sup>, 6<sup>th</sup>,

**Table 1.** Baseline and demographic characteristics of the two groups

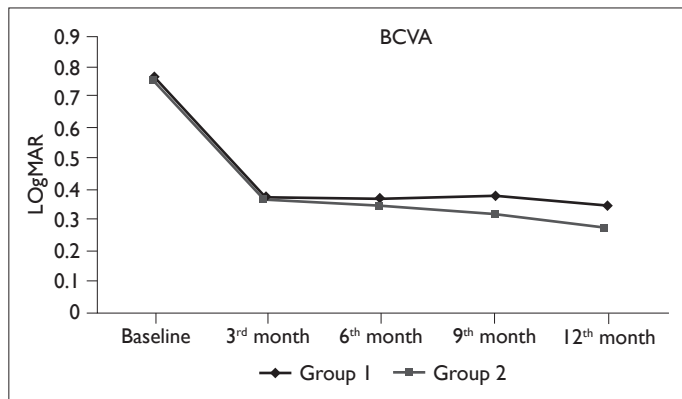
	<b>Group 1 (n=38)</b> <b>(Superior temporal BRVO)</b>	<b>Group 2 (n=26)</b> <b>(Inferior temporal BRVO)</b>	<b>p</b>
Age (year±SD)	61.00±8.91	58.23±8.12	0.292 <sup>1</sup>
Gender (%)			
Female	21 (63.6%)	12 (36.4%)	0.477 <sup>2</sup>
Male	17 (54.8%)	14 (45.2%)	
Hypertension (%)	29/38 (76.3%)	20/26 (76.9%)	0.955 <sup>2</sup>
Diabetes (%)	7/38 (18.4%)	5/26 (19.2%)	0.935 <sup>2</sup>
Hyperlipidemia (%)	4/38 (10.5%)	5/26 (19.2%)	0.325 <sup>2</sup>
Lens Status (%)			
Phakic	30 (55.6%)	24 (44.4%)	0.148 <sup>2</sup>
Pseudophakic	8 (80%)	2 (20%)	
Type of macular edema (%)			
Cystoid	20 (52.6%)	17 (65.4%)	0.310 <sup>2</sup>
Cystoid±serous retinal detachment	18 (47.4%)	9 (34.6%)	
Visual acuity at baseline (logMAR±sd)	0.77±0.47	0.75±0.45	0.945 <sup>1</sup>
CMT at baseline (µm±sd)	522.92±136.01	524.08±145.51	0.779 <sup>1</sup>
The time between the first symptom to injection (days±sd)	35.26±36.00	32.12±32.62	0.967 <sup>1</sup>
Injection number	6.18±2.16	4.26±1.61	0.01 <sup>1</sup>

<sup>1</sup>Mann–Whitney U test. \*P<0.05 BRVO: Branch retinal vein occlusion, <sup>2</sup>Pearson Chi-square test. CMT: Central macular thickness.

**Table 2.** BCVA at each time point and their comparison between the groups

	<b>Group 1 (n=38)</b> <b>(Superior temporal)</b> <b>Mean±SD</b>	<b>Group 2 (n=26)</b> <b>(Inferior temporal)</b> <b>Mean±SD</b>	<b><sup>1</sup>p</b>
BCVA (logMAR)			
Baseline	0.77±0.47	0.75±0.45	0.945
3 <sup>rd</sup> month	0.37±0.20	0.37±0.18	0.895
6 <sup>th</sup> month	0.37±0.22	0.35±0.19	0.749
9 <sup>th</sup> month	0.38±0.24	0.32±0.17	0.331
12 <sup>th</sup> month	0.35±0.18	0.28±0.20	0.074
<sup>2</sup> p	0.001*	0.001*	

<sup>1</sup>Mann–Whitney U test. <sup>2</sup>Friedman test. \*P<0.05 BCVA: Best-corrected visual acuity.



**Figure 1.** The mean Best-corrected visual acuity values at each time points.

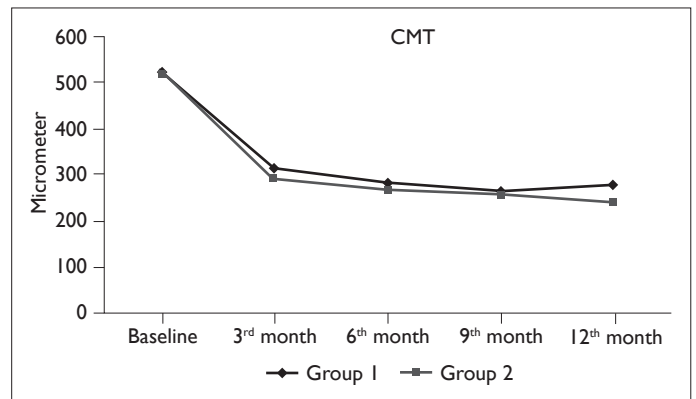
9<sup>th</sup>, and 12<sup>th</sup> month were significantly better than the baseline values after intravitreal ranibizumab injections in both groups ( $p < 0.01$  for all time points for both groups) (Table 2). Furthermore, the changes in BCVA relative to the baseline at the 3<sup>rd</sup>, 6<sup>th</sup>, 9<sup>th</sup>, and 12<sup>th</sup> month did not differ between the groups ( $p > 0.05$ ) (Table 3).

**Anatomical Outcomes**

CMT at each time point was shown in Figure 2. There was no statistically significant difference in CMT measurements between the groups at the baseline, 3<sup>rd</sup>, 6<sup>th</sup>, 9<sup>th</sup>, and 12<sup>th</sup> month ( $p > 0.05$ ). Intragroup comparison of significance was calculated by post hoc analysis conducted with a Bonferroni correction. There was a statistically significant improvement relative to the baseline values in both groups at baseline, 3<sup>rd</sup>, 6<sup>th</sup>, 9<sup>th</sup>, and 12<sup>th</sup> month ( $p < 0.01$  for all time points for both groups) (Table 4). The improvement of CMT did not differ between the groups at any time points ( $p > 0.05$ ) (Table 3).

**Number of Injections**

The mean number of intravitreal injections was  $6.18 \pm 2.16$  and  $4.26 \pm 1.61$  in Groups 1 and 2, respectively. A statistically significant difference was found between the groups ( $p = 0.01$ ) (Table 1). Furthermore, 42.30% of eyes with infe-



**Figure 2.** The mean Central macular thickness values at each time points.

rior BRVO needed no more injections after the first three, whereas this percentage was only 25 % in eyes with superior BRVO.

**Retinal Ischemia and Laser Photocoagulation**

The mean ischemic area was  $4.39 \pm 2.26$  disc area in Group 1

**Table 4.** CMT at each time point and their comparison between the groups

	Group 1 (n=38) (Superior temporal) Mean±SD	Group 2 (n=26) (Inferior temporal) Mean±SD	<sup>1</sup> P
CMT (µm)			
Baseline	522.92±136.01	524.08±145.51	0.779
3 <sup>rd</sup> month	318.03±66.65	289.85±53.08	0.180
6 <sup>th</sup> month	287.53±48.27	268.96±31.57	0.084
9 <sup>th</sup> month	271.95±32.47	260.77±30.22	0.129
12 <sup>th</sup> month	280.47±91.66	244.04±44.78	0.094
<sup>2</sup> P	0.001*	0.001*	

<sup>1</sup>Mann–Whitney U test, <sup>2</sup>Friedman test. \* $p < 0.05$ , CMT: Central macular thickness.

**Table 3.** Changes in mean BCVA and CMT from baseline values and their comparison between the groups

BCVA	3 <sup>rd</sup> month	6 <sup>th</sup> month	9 <sup>th</sup> month	12 <sup>th</sup> month
Group 1 (n=38) (Superior temporal) Mean±SD	-0.39±0.39	-0.39±0.41	-0.39±0.37	-0.42±0.41
Group 2 (n=26) (Inferior temporal) Mean±SD	-0.39±0.38	-0.40±0.39	-0.43±0.41	-0.48±0.42
P	0.793	0.869	0.799	0.563
CMT	3 <sup>rd</sup> month	6 <sup>th</sup> month	9 <sup>th</sup> month	12 <sup>th</sup> month
Group 1 (n=38) (Superior temporal) Mean±SD	-204.89±110.67	-235.40±136.57	-250.97±132.94	-242.45±144.75
Group 2 (n=26) (Inferior temporal) Mean±SD	-234.23±141.60	-255.12±148.10	-263.31±147.55	-280.04±150.74
P	0.477	0.672	0.897	0.315

Mann–Whitney U test  $P < 0.05$ , BCVA: Best-corrected visual acuity, CMT: Central macular thickness.

and  $4.03 \pm 2.19$  disc area in Group 2 and there was no statistically significant difference between the groups ( $p=0.439$ ). Thirteen eyes (34.2%) in Group 1 and 8 (30.8%) eyes in Group 2 received scatter laser photocoagulation for ischemic retinal areas ( $p=0.775$ ).

### Type of Macular Edema and Complications

There was no statistically significant difference between the groups according to the type of macular edema (Table 1). No complications such as cataract formation, endophthalmitis, intraocular hemorrhage, retinal detachment related to intravitreal injection were noted.

## Discussion

In the present study, we evaluated and compared the efficacy of intravitreal ranibizumab injections in the treatment of macular edema secondary to both superior and inferior BRVO. Ranibizumab was effective similarly in both groups. However, an increased number of injections were needed for the treatment of macular edema with superior temporal BRVO.

The previous studies have investigated and demonstrated the effectiveness of intravitreal ranibizumab in the treatment of BRVO with macular edema [8-10]. In the BRAVO and HORIZON studies, a PRN regimen was performed after six consecutive loading doses in the treatment of macular edema secondary to BRVO. BCVA increased and CMT decreased by the 12<sup>th</sup> month of treatment with a mean of 8.5 injections (10,11). In contrast, the mean injection numbers in real-life studies comprising the BRVO patients with macular edema varied from 2.1 to 5 injections during the 12 months of follow-up (12-15). We found similar anatomical and functional improvements as previous studies in both groups over a 1-year follow-up period. The mean number of injections in the superior temporal BRVO was  $6.18 \pm 2.16$  and  $4.26 \pm 1.61$  in the inferior temporal BRVO, which were higher than the real-life studies. The exclusion of patients with irregular visits may have brought our findings closer to the results of prospective, randomized, and controlled trials.

Different from the previous studies, we compared the treatment responses of superior and inferior BRVO. BCVA and CMT improvements were similar in both groups, but to achieve the same efficacy, the eyes with superior temporal BRVO received more intravitreal ranibizumab injections than the eyes with inferior temporal BRVO. Furthermore, 42.30% of eyes with inferior BRVO needed no more injections after the first three, whereas this percentage was only 25 % in eyes with superior BRVO. Age, pre-treatment duration, baseline CMT, retinal ischemia, and type of macular edema were found to be related to the number of injections in the previous studies (16-21). However, there were no significant differences between our groups in terms of these same variables. However, the anatomical and functional variations be-

tween the superior and inferior retina may have led to the difference in injection numbers.

It has been reported that there was an increased risk of developing macular edema in superior BRVOs. The exact mechanism was unknown, but hydrostatic pressure was thought to be responsible for the leakage of fluid in the superior retinal region into the macular zone (22).

Tomita et al. (23) investigated the difference in blood flow of the superior and inferior retina that may be involved in the development and progression of chorioretinal diseases. They evaluated retinal flow volume (RFV) using laser speckle flowgraphy and found that the total RFV, mean vessel diameter, and the blood flow velocity were significantly higher in the superior retina.

There are some theories to explain the differences in blood flow of the superior and inferior retina. First, there may be functional differences between the two retinal regions. Nagatomo et al. (24) demonstrated larger amplitudes of multifocal electroretinograms in the superior retina than in the inferior retina. Miyake et al. (25) found that the a-wave, b-wave amplitudes, and oscillatory potentials of focal electroretinograms were larger in the upper macular area than in the lower macular area. Second, anatomical differences may contribute to the difference in blood flow between the superior and inferior retina. Curcio et al. (26,27) reported a higher number of retinal ganglion cells in the upper macular region than in the lower macular region. In addition, a larger amount of ganglion cells was found in the superior peripheral retina than in the inferior peripheral retina. These anatomical and functional differences may result in a difference in blood flow to the superior and inferior retinal regions. In healthy eyes, autoregulation of blood flow prevents leakage, as in patients with systemic hypertension. However, edema often develops when autoregulation is disrupted by retinal vascular diseases (28). Higher retinal blood flow volume in the superior retina may cause more extravasation of fluid to the macular area that results in a higher number of injections in superior temporal BRVO than in inferior temporal BRVO. Furthermore, gravity may also contribute to the extravasation of more fluid from the superior retinal veins into the macula.

The limitations of this study were its retrospective design, small sample size, and the lack of quantitative measurements of collateral vessel density.

## Conclusion

The efficacy of intravitreal ranibizumab in the treatment of macular edema secondary to both superior and inferior BRVO was similar. However, more frequent injections were needed in the superior temporal BRVO. The site of occlusion may be a predictive factor for the potential need for intravitreal injections and provide information regarding the progression of the disease.

**Disclosures****Ethics Committee Approval:** Retrospective study.**Peer-review:** Externally peer-reviewed.**Conflict of Interest:** None declared.**Authorship Contributions:** Concept – M.Y., L.K.; Design – E.T.K., M.Y.; Supervision – M.Y., L.K.; Materials – E.T.K., M.Y., Y.E.; Data collection and/or processing – E.T.K., M.Y., Y.E.; Analysis and/or interpretation – E.T.K., M.Y.; Literature search – E.T.K.; Writing – E.T.K.; Critical review – E.T.K.**References**

- Parodi MB, Bandello F. Branch retinal vein occlusion: Classification and treatment. *Ophthalmologica* 2009;223:298–305.
- Klein R, Moss SE, Meuer SM, Klein BE. The 15-year cumulative incidence of retinal vein occlusion: The beaver dam eye study. *Arch Ophthalmol* 2008;126:513–8.
- Feist RM, Ticho BH, Shapiro MJ, Farber M. Branch retinal vein occlusion and quadrant variation in arteriovenous crossings. *Am J Ophthalmol* 1992;113:664–8.
- Wong TY, Scott IU. Clinical practice. Retinal vein occlusion. *N Engl J Med* 2010;363:2135–44.
- Stefánsson E. Physiology of vitreous surgery. *Graefes Arch Clin Exp Ophthalmol* 2009;247:147–63.
- Noma H, Minamoto A, Funatsu H, Sukamoto H, Nakano K, Yamashita H, et al. Intravitreal levels of vascular endothelial growth factor and interleukin-6 are correlated with macular edema in branch retinal vein occlusion. *Graefes Arch Clin Exp Ophthalmol* 2006;244:309–15.
- Pielen A, Feltgen N, Isserstedt C, Callizo J, Junker B, Schmucker C. Efficacy and safety of intravitreal therapy in macular edema due to branch and central retinal vein occlusion: A systematic review. *PLoS One* 2013;8:e78538.
- Bandello F, Augustin A, Tufail A, Leback R. A 12-month, multicenter, parallel-group comparison of dexamethasone intravitreal implant versus ranibizumab in branch retinal vein occlusion. *Eur J Ophthalmol* 2018;28:697–705.
- Tadayoni R, Waldstein SM, Boscia F, Gerding H, Gekkieva M, Barnes E, et al. Sustained benefits of ranibizumab with or without laser in branch retinal vein occlusion: 24-Month results of the brighter study. *Ophthalmology* 2017;124:1778–87.
- Campochiaro PA, Heier JS, Feiner L, Gray S, Saroj N, Rundle AC, et al. Bravo investigators. Ranibizumab for macular edema following branch retinal vein occlusion: Six-month primary end point results of a phase III study. *Ophthalmology* 2010;117:1102–12.
- Heier JS, Campochiaro PA, Yau L, Li Z, Saroj N, Rubio RG, et al. Ranibizumab for macular edema due to retinal vein occlusions: Long term follow-up in the HORIZON trial. *Ophthalmology* 2012;119:802–9.
- Ozkaya A, Alkin Z, Yesilkaya C, Erdogan G, Perente I, Taskapili M. Ranibizumab in macular edema secondary to retinal vein occlusion in a real life practice: A retrospective case series. *Be-yoglu Eye J* 2016;1:5–9.
- Yuksel B, Karti O, Celik O, Kerici SG, Kusbeci T. Low frequency ranibizumab versus dexamethasone implant for macular oedema secondary to branch retinal vein occlusion. *Clin Exp Optom* 2018;101:116–22.
- Chatziralli I, Theodossiadis G, Chatzirallis A, Parikakis E, Mitropoulos P, Theodossiadis P. Ranibizumab for retinal vein occlusion: Predictive factors and Long-term outcomes in Real-life data. *Retina* 2018;38:559–68.
- Lip PL, Cikatrixis P, Sarmad A, Damato EM, Chavan R, Mitra A, et al. Efficacy and timing of adjunctive therapy in the anti-VEGF treatment regimen for macular oedema in retinal vein occlusion: 12-month Real-world result. *Eye (Lond)* 2018;32:537–45.
- Gallego-Pinazo R, Diaz-Llopis M, Frances E, Lopez-Lizcano R, Gomez-Maestra M, Udaondo P. Macular thickness might be a recurrence probability predictor in macular edema due to retinal vein occlusions treated with repeated intravitreal injections of antiangiogenics. *Arch Soc Esp Ophthalmol* 2009;84:177–8.
- Yamada R, Nishida A, Shimozone M, Kameda T, Miyamoto N, Mandai M, et al. Predictive factors for recurrence of macular edema after successful intravitreal bevacizumab therapy in branch retinal vein occlusion. *Jpn J Ophthalmol* 2015;59:389–93.
- Moon BG, Cho AR, Kim YN, Kim JG. Predictors of refractory macular edema after branch retinal vein occlusion following intravitreal bevacizumab. *Retina* 2018;38:1166–74.
- Noma H, Funatsu H, Mimura T, Tatsugawa M, Shimada K, Eguchi S. Vitreous inflammatory factors and serous macular detachment in branch retinal vein occlusion. *Retina* 2012;32:86–91.
- Yoo JH, Ahn J, Oh J, Cha J, Kim SW. Risk factors of recurrence of macular oedema associated with branch retinal vein occlusion after intravitreal bevacizumab injection. *Br J Ophthalmol* 2017;101:1334–9.
- Goel S, Kumar A, Ravani RD, Chandra P, Chandra M, Kumar V. Comparison of ranibizumab alone versus ranibizumab with targeted retinal laser for branch retinal vein occlusion with macular edema. *Indian J Ophthalmol* 2019;67:1105–8.
- Zhou JQ, Xu L, Wang S, Wang YX, You QS, Tu Y, et al. The 10-year incidence and risk factors of retinal vein occlusion: The Beijing eye study. *Ophthalmology* 2013;12:803–8.
- Tomita R, Iwase T, Uneo Y, Goto K, Yamamoto K, Ra E, et al. Differences in blood flow between superior and inferior retinal hemispheres. *Invest Ophthalmol Vis Sci* 2020;61:27.
- Nagatomo A, Nao-i N, Maruiwa F, Arai M, Sawada A. Multifocal electroretinograms in normal subjects. *Jpn J Ophthalmol* 1998;42:129–35.
- Miyake Y, Shiroyama N, Horiguchi M, Ota I. Asymmetry of focal ERG in human macular region. *Invest Ophthalmol Vis Sci* 1989;30:1743–9.
- Curcio CA, Allen KA. Topography of ganglion cells in human retina. *J Comp Neurol* 1990;300:5–25.
- Curcio CA, Sloan KR, Kalina RE, Hendrickson AE. Human photoreceptor topography. *J Comp Neurol* 1990;29:497–523.
- Cunha-Vaz J. Mechanisms of retinal fluid accumulation and blood-retinal barrier breakdown. *Dev Ophthalmol* 2017;58:11–20.