

Author affiliations: Royal Perth Hospital, Perth, Western Australia, Australia (L.S. Pozzi, J.O. Robinson, J.C. Pearson, K.J. Christiansen, G.W. Coombs, R.J. Murray); and Curtin University of Technology, Perth (K.J. Christiansen, G.W. Coombs).

DOI: 10.3201/eid1510.081532

References

1. Udo EE, Pearman JW, Grubb WB. Genetic analysis of community isolates of methicillin-resistant *Staphylococcus aureus* in Western Australia. *J Hosp Infect.* 1993;25:97–108. DOI: 10.1016/0195-6701(93)90100-E
2. Moran GJ, Krishnadasan A, Gorwitz RJ, Fosheim GE, McDougal LK, Carey RB, et al. EMERGEncy ID Net Study Group. Methicillin-resistant *S. aureus* infections among patients in the emergency department. *N Engl J Med.* 2006;355:666–74. DOI: 10.1056/NEJMoa055356
3. Gillet Y, Issartel B, Vanhems P, Fournet JC, Lina G, Bes M, et al. Association between *Staphylococcus aureus* strains carrying gene for Panton-Valentine leukocidin and highly lethal necrotising pneumonia in young immunocompetent patients. *Lancet.* 2002;359:753–9. DOI: 10.1016/S0140-6736(02)07877-7
4. Miller LG, Perdreau-Remington F, Rieg G, Mehdi S, Perlroth J, Bayer AS, et al. Necrotizing fasciitis caused by community-associated methicillin-resistant *Staphylococcus aureus* in Los Angeles. *N Engl J Med.* 2005;352:1445–53. DOI: 10.1056/NEJMoa042683
5. L'Heriteau F, Lucet JC, Scanvic A, Bouvet E. Community-acquired methicillin-resistant *Staphylococcus aureus* and familial transmission. *JAMA.* 1999;282:1038–9. DOI: 10.1001/jama.282.11.1038
6. Urth T, Juul G, Skov R, Schonheyder HC. Spread of a methicillin-resistant *Staphylococcus aureus* ST80-IV clone in a Danish community. *Infect Control Hosp Epidemiol.* 2005;26:144–9. DOI: 10.1086/502518
7. Huijsdens XW, van Santen-Verheuevel MG, Spalburg E, Heck ME, Pluister GN, Eijkelkamp BA, et al. Multiple cases of familial transmission of community-acquired methicillin-resistant *Staphylococcus aureus*. *J Clin Microbiol.* 2006;44:2994–6. DOI: 10.1128/JCM.00846-06
8. O'Brien FG, Udo EE, Grubb WB. Contour-clamped homogeneous electric field electrophoresis of *Staphylococcus aureus*. *Nat Protocols.* 2006;1:3028–33. DOI: 10.1038/nprot.2006.382

9. Coombs GW, Pearson JC, O'Brien FG, Murray RJ, Grubb WB, Christiansen KJ. Methicillin-resistant *Staphylococcus aureus* clones, Western Australia. *Emerg Infect Dis.* 2006;12:241–7.
10. Pearman JW, Christiansen KJ, Annear DI, Goodwin CS, Metcalf C, Donovan FP, et al. Control of methicillin-resistant *Staphylococcus aureus* (MRSA) in an Australian metropolitan teaching hospital complex. *Med J Aust.* 1985;142:103–8.

Address for correspondence: James O. Robinson, Department of Microbiology and Infectious Diseases, PathWest Laboratory Medicine, Royal Perth Hospital, Wellington Street, Perth 6000, Western Australia, Australia; email: owen.robinson@health.wa.gov.au

Rhombencephalitis and Coxsackievirus A16

To the Editor: Hand, foot, and mouth disease (HFMD) is a common illness in children and is mainly caused by coxsackievirus A16 (CA16) and enterovirus 71 (EV71). Although its clinical course is usually uneventful and most patients experience a full recovery, serious neurologic complications, including encephalitis, can occur secondarily to HFMD caused by EV71. Such neurological complications occurred during an epidemic in Taiwan in 1998 (1). Encephalitis caused by EV71 is characterized by rhombencephalitis, which is a combination of brainstem encephalitis and cerebellitis. Signs and symptoms of rhombencephalitis are irritability, myoclonus, ataxia, and cranial nerve involvement (1). In contrast to EV71, HFMD caused by CA16 is associated with few neurologic complications with the exception of infrequent aseptic meningitis (2). We report a case of rhombencephalitis that developed in an infant as a complication of HFMD caused by CA16.

HFMD was diagnosed in a 23-month-old girl on the basis of high fever (>40°C, 3 d duration), stomatitis, and multiple papules on her palms, soles, and buttocks. Her illness occurred in the summer of 2007, when sentinel surveillance in the region indicated an epidemic of HFMD caused by both CA16 and EV71. She was admitted to our hospital in Fukoka, Japan, on day 4 of illness because of abnormal eye movement, irritability, and inability to stand. She had intermittent to-and-fro, horizontal oscillations of the eyes (ocular flutter). She also had truncal and limb ataxia and myoclonus in her head and limbs. Brain magnetic resonance imaging (MRI) showed T1-low and T2-high bulbopontine and cerebellar lesions around the fourth ventricle (Figure). Peripheral blood showed a mild leukocytosis ($13.13 \times 10^9/L$) and a C-reactive protein level within reference range (0.9 mg/L). Blood chemistry results were unremarkable. Cerebrospinal fluid (CSF) examination showed mononuclear pleocytosis ($74/\mu L$) with normal protein and glucose levels. CA16 was isolated from her stool specimen on day 4 of illness. Based on reverse transcription-PCR, CSF was negative for enterovirus RNA.

Without specific treatment, our patient's fever resolved on day 5 of illness. The myoclonus, ocular flutter, and irritability subsided by day 16, when MRI findings returned to normal. Ataxia disappeared gradually ≈ 1 month after onset, and no neurologic sequelae occurred. Neutralizing antibody titers against CA16 and EV71 on day 21 of illness were 32 and <8, respectively. Based on the sequence analysis of the partial VP1 region (876 bp), we classified the patient's CA16 strain phylogenetically as genetic lineage C (3). This lineage was identical to lineage 2 (4), which became the dominant circulating strain in Asia, including Japan, after the late 1990s (98.2% identical to the 1018T/VNM/05 strain isolated in Vietnam

in 2005 [GenBank accession no. AM292441]) (4,5).

The patient's symptoms of irritability, ataxia, myoclonus, and ocular flutter 3 days after the onset of typical HFMD manifestations, along with CSF mononuclear pleocytosis and the lesions around the fourth ventricle shown on MRI, led to the diagnosis of rhombencephalitis associated with HFMD. Virologic examination, including virus isolation and antibody assay, suggested that HFMD was caused by CA16 but not by EV71, although the possibility that CA16 infection was coincidental to the rhombencephalitis could not be excluded.

Although rhombencephalitis can be related to various infectious agents (6), HFMD complicated by this condition has been exclusively caused by EV71 (1,7,8). In Japan, CA16 and EV71 are consistently the 2 major causative agents of HFMD (9). EV71 infection is much more frequently associated with serious neurologic complications and fatalities than is CA16 (2). Since 1997, several HFMD out-

breaks with multiple cases of severe neurologic pathologies have occurred in the Asia-Pacific region including Malaysia, Taiwan, and Western Australia (1,7,8). These complications were associated exclusively with EV71.

Why rhombencephalitis developed in our patient with CA16-related HFMD is unclear. One possibility is that the CA16 strain might have acquired neurovirulence by genetic recombination with EV71; phylogenetic evidence supports the possible occurrence of intertypic recombination involving EV71 and CA16 (10). Through phylogenetic analysis of the VP1 sequences, we classified the CA16 strain isolated from the patient's stool phylogenetically as genetic lineage C (3), a lineage which was identical to lineage 2 (4). Genetic recombinations among enteroviruses occur mainly in noncapsid regions (10). We did not conduct phylogenetic analysis of the noncapsid regions of the patient's CA16 strain because sequence data on the regions were very limited.

Besides the viral factors, host factors, such as immune status and environmental factors, could confer susceptibility to neurologic complications of enteroviral infections.

Rhombencephalitis associated with HFMD developed in this patient and was caused by CA16. Therefore, neurologic complications, including rhombencephalitis, should be considered even when CA16 is the prevalent virus causing HFMD.

This work was supported in part by Grants-in-Aid for Scientific Research from the Ministry of Education, Culture, Sports, Science and Technology of Japan (no. 21790995 and no. 21591389) and a Grant-in-Aid for Research on Emerging and Reemerging Infectious Diseases from the Ministry of Health, Labour and Welfare, Japan.

**Kazuna Goto,
Masafumi Sanefuji,
Koichi Kusuhara,¹
Yorihiko Nishimura,
Hiroyuki Shimizu, Ryutarō Kira,
Hiroyuki Torisu,
and Toshiro Hara**

Author affiliations: Kyushu University, Fukuoka, Japan (K. Goto, M. Sanefuji, K. Kusuhara, R. Kira, H. Torisu, T. Hara); and National Institute of Infectious Diseases, Tokyo, Japan (Y. Nishimura, H. Shimizu)

DOI: 10.3201/eid1510.090594

References

- Huang CC, Liu CC, Chang YC, Chen CY, Wang ST, Yeh TF. Neurologic complications in children with enterovirus 71 infection. *N Engl J Med*. 1999;341:936–42. DOI: 10.1056/NEJM199909233411302
- Chang LY, Lin TY, Huang YC, Tsao KC, Shih SR, Kuo ML, et al. Comparison of enterovirus 71 and coxsackie-virus A16 clinical illnesses during the Taiwan enterovirus epidemic, 1998. *Pediatr Infect Dis J*. 1999;18:1092–6. DOI: 10.1097/00006454-199912000-00013

¹Current affiliation: University of Occupational and Environmental Health School of Medicine, Kitakyushu, Japan.

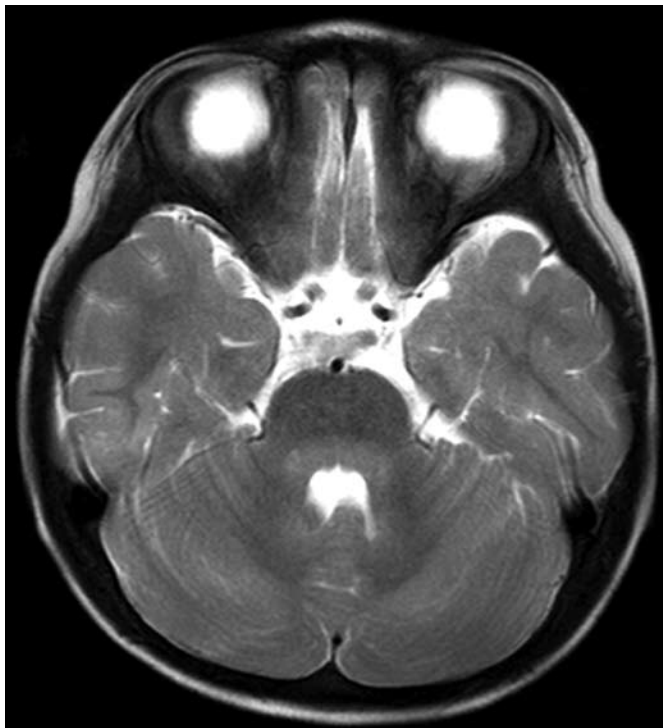


Figure. Axial T2-weighted slice of brain by magnetic resonance imaging, showing hyperintensity lesions in the pons and cerebellum around the fourth ventricle.

3. Li L, He Y, Yang H, Zhu J, Xu X, Dong J, et al. Genetic characteristics of human enterovirus 71 and coxsackievirus A16 circulating from 1999 to 2004 in Shenzhen, People's Republic of China. *J Clin Microbiol.* 2005;43:3835-9. DOI: 10.1128/JCM.43.8.3835-3839.2005
4. Perera D, Yusof MA, Podin Y, Ooi MH, Thao NT, Wong KK, et al. Molecular phylogeny of modern coxsackievirus A16. *Arch Virol.* 2007;152:1201-8. DOI: 10.1007/s00705-006-0934-5
5. Hosoya M, Kawasaki Y, Sato M, Honzumi K, Hayashi A, Hiroshima T, et al. Genetic diversity of coxsackievirus A16 associated with hand, foot, and mouth disease epidemics in Japan from 1983 to 2003. *J Clin Microbiol.* 2007;45:112-20. DOI: 10.1128/JCM.00718-06
6. Hall WA. Infectious lesions of the brain stem. *Neurosurg Clin N Am.* 1993;4:543-51.
7. Chan LG, Parashar UD, Lye MS, Ong FG, Zaki SR, Alexander JP, et al. Deaths of children during an outbreak of hand, foot, and mouth disease in Sarawak, Malaysia: clinical and pathological characteristics of the disease. *Clin Infect Dis.* 2000;31:678-83. DOI: 10.1086/314032
8. McMinn P, Stratov I, Nagarajan L, Davis S. Neurological manifestations of enterovirus 71 infection in children during an outbreak of hand, foot, and mouth disease in Western Australia. *Clin Infect Dis.* 2001;32:236-42. DOI: 10.1086/318454
9. Infectious Disease Surveillance Center. Infectious agents surveillance report [cited 2009 Apr 17]. Available from <https://hasseidoko.mhlw.go.jp/Byogentai/Pdf/data37e.pdf>
10. Yoke-Fun C, AbuBakar S. Phylogenetic evidence for inter-typic recombination in the emergence of human enterovirus 71 subgenotypes. *BMC Microbiol.* 2006;6:74. DOI: 10.1186/1471-2180-6-74

Address for correspondence: Masafumi Sanefuji, Department of Pediatrics, Graduate School of Medical Sciences, Kyushu University, 3-1-1 Maidashi, Higashi-ku, Fukuoka 812-8582, Japan; email: sane26@pediatr.med.kyushu-u.ac.jp

Japanese Encephalitis in Hill and Mountain Districts, Nepal

To the Editor: Nepal, a landlocked country in Southeast Asia with an estimated population of 27 million, is divided administratively into 5 regions; 75 districts comprise 3 ecological zones that run from east to west. Altitude increases from south to north: the 20-district Terai plains in the south, the hill region in the center with 39 districts, and the 16-district mountain regions in the north. Japanese encephalitis (JE) is seasonally endemic to the Terai region, which borders the northern India states of Uttar Pradesh and Bihar. The first outbreak of JE in Nepal was reported in 1978 from the Terai district of Rupendehi (1). Since then, JE infection has been reported in animal reservoirs and in humans throughout the Terai region (1-5). Although few publications describe the presence of JE outside the Terai, an outbreak of JE in Kathmandu valley in the hill region was confirmed in 1997 (6), and a 2006 study reported JE endemicity in Kathmandu Valley (7). In recent years, the Ministry of Health and Population in Nepal has introduced public health interventions, including mass immunization campaigns, for JE prevention in these known JE-endemic areas.

JE cases are captured through acute encephalitis syndrome (AES) surveillance conducted by the government of Nepal, with support from the World Health Organization (WHO), through a national sentinel surveillance network. From 2004 through 2006, a total of 108 laboratory-confirmed JE cases were reported from hill or mountain districts (excluding Kathmandu Valley). However, travel histories for case-patients were not available for these years to determine the origin of JE infection. We conducted a study to provide evidence of JE endemicity in

hill and mountain districts of Nepal (excluding Kathmandu Valley).

Laboratory-confirmed JE case-patients identified in 2007 who reported residence in 1 of the 52 hill or mountain districts, excluding the 3 hill districts of the Kathmandu Valley, were followed up by surveillance medical officers. All patients (or next of kin if the patient was deceased or unavailable) were visited at home or contacted by telephone to confirm their residence and travel history during the 30 days before the onset of symptoms. Data and sample collection procedures and laboratory methods used for JE diagnosis were as previously reported by Partridge et al. (7). Patients were identified by the AES surveillance system if patients' symptoms met the case definition for AES adopted from WHO guidelines (www.who.int/vaccines-documents/DocsPDF06/843.pdf), i.e., acute onset of fever and a change in mental status (e.g., confusion, disorientation, coma, or inability to talk); or if the patient experienced a new onset of seizures (excluding simple febrile seizures) or was identified as having AES, JE, or viral encephalitis. The study population included any person of any age who reported being a resident of 1 of the 52 hill or mountain districts (excluding Kathmandu Valley), who had been seen at any AES reporting site from January 1 through December 31, 2007, and who had been confirmed to have JE antibody by immunoglobulin M capture ELISA on a serum or cerebrospinal fluid (CSF) specimen.

In 2007, a total of 360 AES cases were reported from 40 hill or mountain districts. Of the 344 reported AES cases for which diagnostic samples were obtained, 90 (26%) were laboratory confirmed as JE from 21 hill and 3 mountain districts. Among laboratory confirmed JE cases, CSF samples were collected from 13 (14%) patients and serum samples from 77 (86%) patients (Table). The largest number of AES and laboratory-confirmed JE cas-

EID
online
www.cdc.gov/eid