

Curcuma purpurascens Bl. rhizome accelerates rat excisional wound healing: involvement of Hsp70/Bax proteins, antioxidant defense, and angiogenesis activity

Elham Rouhollahi¹
Soheil Zorofchian
Moghadamtousi²
Fatemeh Hajiaghaalipour³
Maryam Zahedifard²
Faezeh Tayebzadeh²
Khalijah Awang⁴
Mahmood Ameen Abdulla³
Zahurin Mohamed¹

¹Pharmacogenomics Laboratory, Department of Pharmacology, Faculty of Medicine, ²Institute of Biological Sciences, Faculty of Science, ³Department of Biomedical Science, Faculty of Medicine, ⁴Department of Chemistry, Faculty of Science, University of Malaya, Kuala Lumpur, Malaysia

Correspondence: Elham Rouhollahi
Pharmacogenomics Laboratory,
Department of Pharmacology, Faculty of
Medicine, University of Malaya, 50603
Kuala Lumpur, Malaysia
Tel +60 3 7967 5725
Fax +60 3 7967 4791
Email elhamrouhollahi@gmail.com

Purpose: *Curcuma purpurascens* Bl. is a member of Zingiberaceae family. The purpose of this study is to investigate the wound healing properties of hexane extract of *C. purpurascens* rhizome (HECP) against excisional wound healing in rats.

Materials and methods: Twenty four rats were randomly divided into 4 groups: A) negative control (blank placebo, acacia gum), B) low dose of HECP, C) high dose of HECP, and D) positive control, with 6 rats in each group. Full-thickness incisions (approximately 2.00 cm) were made on the neck area of each rat. Groups 1–4 were treated two-times a day for 20 days with blank placebo, HECP (100 mg/kg), HECP (200 mg/kg), and intrasite gel as a positive control, respectively. After 20 days, hematoxylin and eosin and Masson's trichrome stainings were employed to investigate the histopathological alterations. Protein expressions of Bax and Hsp70 were examined in the wound tissues using immunohistochemistry analysis. In addition, levels of enzymatic antioxidants and malondialdehyde representing lipid peroxidation were measured in wound tissue homogenates.

Results: Macroscopic evaluation of wounds showed conspicuous elevation in wound contraction after topical administration of HECP at both doses. Moreover, histopathological analysis revealed noteworthy reduction in the scar width correlated with the enhanced collagen content and fibroblast cells, accompanied by a reduction of inflammatory cells in the granulation tissues. At the molecular level, HECP facilitates wound-healing process by downregulating Bax and upregulating Hsp70 protein at the wound site. The formation of new blood vessel was observed in Masson's trichrome staining of wounds treated with HECP (100 and 200 mg/kg). In addition, HECP administration caused a significant surge in enzymatic antioxidant activities and a decline in lipid peroxidation.

Conclusion: These findings suggested that HECP accelerated wound-healing process in rats via antioxidant activity, angiogenesis effect and anti-inflammatory responses involving Hsp70/Bax.

Keywords: Zingiberaceae, wound closure, immunohistochemistry, antioxidant enzyme activity, inflammatory cells

Introduction

Wounds, especially chronic wounds, are debilitating ailments that afflict a patient's recovery procedure and severely attenuate the quality of life of the patient.¹ A previous investigation on the Western pharmacopeia revealed that only 1%–3% of the listed drugs are suitable for the skin-related ailments, including wounds. However, one-third of herbal remedies can be effectively used for such a purpose.^{1,2} Therefore, the approach of developing new drugs from natural products that are capable of treating wounds has

been in progress in order to elevate the therapeutic effects and accelerate the wound-healing procedure.^{3,4}

Skin wound healing represents a chain of dynamic and well-orchestrated biological process, which results in the regeneration and growth of wounded tissue.⁵ In cutaneous tissue injury, disruption of vascular vessels, and extravasation instantly commence the inflammation stage. A temporary fibrin clot and vasoconstriction favoring homeostasis provide a fleeting substrate for platelets that leads to the release of inflammatory mediators, including cytokines, extracellular matrices, and secrete growth factors.⁶ In addition, the incision space is filled by the proliferation of granulation tissue.⁷ The recruitment of macrophages and neutrophils by the inflammatory mediators initiates the tissue reepithelialization through secretion of various specific factors. The stage of tissue reepithelialization mediates the regeneration of new epithelium via migration and proliferation of keratinocytes in the wound periphery.⁸ Maturation or tissue remodeling stage strengthens the tissue tensile by the synthesis of collagen fibers and fibroblast proliferation. The full mending of disrupted surface by collagen fibers completes the healing process.⁷

Plants with an immemorial history of ethnomedicinal uses have been proven to possess substantial capability of treatment of various ailments and diseases.^{9,10} However, there are numerous plant species that need to be covered with detailed scientific inspection regarding their traditional uses. One such plant with ethnomedicinal uses is *Curcuma purpurascens* BI. from the Zingiberaceae family. *C. purpurascens* is commonly known as “Temu tis” and “Koneng tinggang” in Indonesia.¹¹ The rhizome of this plant has been reported to have extensive traditional uses in rural communities against different skin ailments and dermatological disorders, especially wounds and burns.^{11,12} Despite its traditional application, no scientific evidence has been corroborated on the potential wound-healing effect of this plant. Thus, in the present study, the efficacy of hexane extract of *C. purpurascens* rhizome (HECP) was investigated against excisional wound healing in rats.

Material and methods

Materials and drugs

The *C. purpurascens* rhizome was procured from Yogyakarta, Indonesia, in August 2013. The plant material was authenticated and deposited in the herbarium of the Chemistry Department, University of Malaya with voucher specimen number KL 5793. The botanical identification was made by Mr Teo Leong Eng, Faculty of Science, University of Malaya. Intrasisite gel, a trademark for Smith

and Nephew Healthcare Limited, Hull, UK, is a colorless transparent aqueous gel applied as the standard wound-dressing drug and acacia gum used as blank placebo.

Preparation of the extract

The air-dried rhizomes of *C. purpurascens* were ground into small pieces using a hammer mill. The rhizomes (1.0 kg) were extracted by being macerated in hexane (4 L) at 25°C for 3 days. The extract was filtered using Whatman No 1 filter paper. The filtrate was concentrated to dryness at 40°C using the Buchi R110 Rotavapor (Büchi Labortechnik AG, Flawil, Switzerland) and stored at -20°C until use. Two concentrations of HECP (100 and 200 mg/kg) were provided by homogeneously mixing the extract with the blank placebo.

Animals

Male Sprague Dawley rats (150–180 g, 6–8 weeks old), obtained from the animal house of the Animal Experimental Unit (University of Malaya), were individually housed in polypropylene cages under standard experimental conditions. The rats were controlled at temperature of 25°C±0.50°C, with 12 hour light–dark cycles, and fed on normal pellet diet and water ad libitum. All animal procedures were approved by the Faculty of Medicine Institutional Animal Care and Use Committee, University of Malaya (FOM IACUC, ethics approval number 2014-03-05/PHAR/R/ER).

Excision wound model

The excision wound model was used to study the wound-healing effect of HECP in rats. The rats were generally anesthetized using intramuscular injection of ketamine and xylazine prior to the wound creation. The necks of the rats were thoroughly shaved with sterile razor blade and disinfected with alcohol (70%). After marking an oval wound on the shaved necks of the rats, a full thickness of the excision wound (approximately 2.00 cm) with 2 mm depth was created without any damage to the muscle layer using a sterile surgical blade and disinfected scissors (Figure 1). The neck area was chosen for this experiment to preclude the rats from biting and stretching the wound area.

Grouping, ointment administration and wound closure percentage

Four groups (n=6/group) of rats were used for the experiment. Group A: wounds treated with blank placebo (negative control), group B: wounds treated with HECP (100 mg/kg, low dose), group C: wounds treated with HECP (200 mg/kg, high dose), and group D: wounds

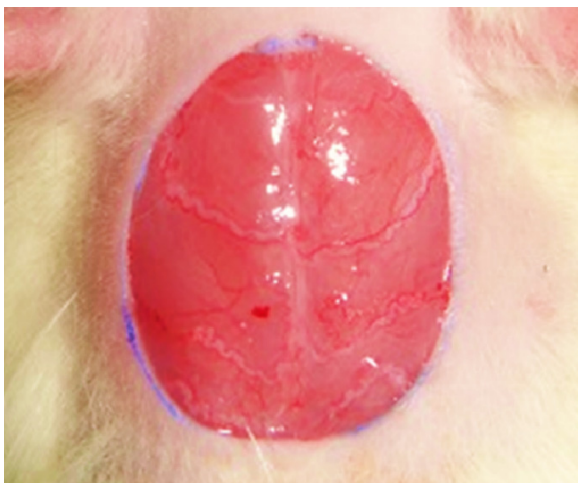


Figure 1 The excision wound model on day 0, before starting the treatments.

treated with intrasite gel (500 mg/kg). Starting from the day of wounding (day 0), treatment samples (0.2 mL) were topically dressed over the entire wound twice daily for 20 days. Wound contraction (mm^2) was measured by tracing margins of the wound using transparent graph papers on days 5, 10, 15, and 20. The evaluated surface area was then employed to determine the wound-healing percentage of each rat through calculation of the wound reduction from the initial size.¹³

Histological evaluation

On day 20 after surgery, the cross-sectional full-thickness specimens of skins were excised from healed wounds and surrounding tissues. Samples were fixed and processed using a paraffin tissue-processing machine (Leica Microsystems, Wetzlar, Germany), and then 5 μm sections were stained with hematoxylin and eosin, and Masson's trichrome stain to examine the histopathological alterations.

Immunohistochemistry analysis

The Bax and Hsp70 protein expressions were evaluated in each formalin-fixed paraffin-embedded wounded tissue section, as previously described in detail.¹⁴ Immunostaining was performed using the EGFR pharmDx™ kit (DakoCytomation, Carpinteria, CA, USA), according to the manufacturer's protocol. In brief, endogenous peroxidase activity was quenched using a peroxidase block. Tissue sections were then incubated with Bax (1:200, Cat: ab7977; Abcam, Cambridge, MA, USA) and Hsp70 (1:500, Cat: ab2787, Abcam) biotinylated primary antibody for 15 minutes followed by another 15 minutes of incubation with streptavidin–horseradish peroxidase. The sections were

incubated with diaminobenzidine tetrahydrochloride for 5 minutes, and then counterstained with hematoxylin and 0.5% ammonia in water. The brown illustrations of samples under a light microscope demonstrated the positive findings.

Enzymatic activities

On day 20 after surgery, the granulation tissues (200 mg) were homogenized in Tris buffer. The tissue homogenates were centrifuged at 6,000 rpm for 20 minutes at 4°C and the supernatant was employed for further assessment of the enzymatic activities. Commercial kits (Cayman, Ann Arbor, MI, USA) were applied to measure the activity of catalase (CAT) (Item No 707002; Cayman), glutathione peroxidase (GPx) (Item No 703102; Cayman), and superoxide dismutase (SOD) (Item No 706002; Cayman) in tissue homogenates, according to the vendor's protocol.

Lipid peroxidation

Lipid peroxidation in wound tissue homogenates was determined by measuring the malondialdehyde (MDA) content (Item No 10009055; Cayman), a direct product formed as a result of peroxidation of lipids, using Wills' method described in a previous study.¹⁵ MDA level was assayed in the form of thiobarbituric acid reactive substances and represented in nanomoles of MDA formed per milligram protein.

Statistical analysis

All data were expressed as mean \pm SEM of n animals per group. Statistical significance of difference groups was evaluated by analysis of variance followed by Tukey's test. Values of $P < 0.05$ were considered significant.

Results and discussion

Topical application of HECP-augmented excision wound healing in rats

In ethno medicine of Indonesia, *C. purpurascens* rhizome has been employed for its wound-healing effect with topical use on the skin.¹² In a previous study, the same author identified that the chemical constituted the HECP. The presence of c-elemene, benzofuran, 6-ethenyl-4,5,6,7-tetrahydro-3,6-dimethyl-5-isopropenyl, turmerone, germacrone, ar-turmerone, curlone, and 3,7-cyclodecadien-1-one, 3,7-dimethyl-10-(1-methylethylidene), has been shown by gas chromatography–time of flight mass spectrometry analysis.¹¹

This study showed the presence of turmerone, germacrone, and ar-turmerone as the major compounds. However, turmerone, and ar-turmerone have been reported as active compounds in anticancer activity.¹⁶ It has been reported that the essential

oil obtained from *C. purpurascens* rhizome possesses efficient antiproliferative activity against human carcinoma cell lines such as MCF7, Ca Ski, A549, HT29, and HCT116.^{16,17}

These sesquiterpenoids are well established as effective biological molecules with antioxidant property.^{18,19} Despite the fact that the chemical constituents of *C. purpurascens* rhizome strongly support its application as the wound-healing agent,^{20,21} a scientific examination is still required to substantiate its use in folk medicine. Therefore, in the current study, we evaluated the effect of the topical administration of HECP on excision wound model in rats.

The mean percentage of wound contraction was determined after 5, 10, 15, and 20 days of treatment in all four groups. The curative effect of HECP at both doses (100 and 200 mg/kg) after 20 days is distinctly obvious in the gross

appearance of excision wound, compared to the negative control group (Figure 2). During the initial 5 days, the healing rate was significantly higher than the negative control only in rats treated with intrasite gel (39.16%, positive control). However, after 10 days, topical treatment with HECP at both doses showed significant wound-healing activity (low dose: 56.21%; high dose: 63.8%; and positive control, 69.31%). Similarly after 15 days, the percentage of wound closure was significantly higher in rats treated with HECP (100 and 200 mg/kg) and intrasite gel (Figure 3). No significant difference between wound-healing effect of HECP (100 and 200 mg/kg) groups and positive control group after 20 days demonstrated their comparable effectiveness. These results showed the potential effect of HECP in accelerating the process of excisional wound healing in rats.

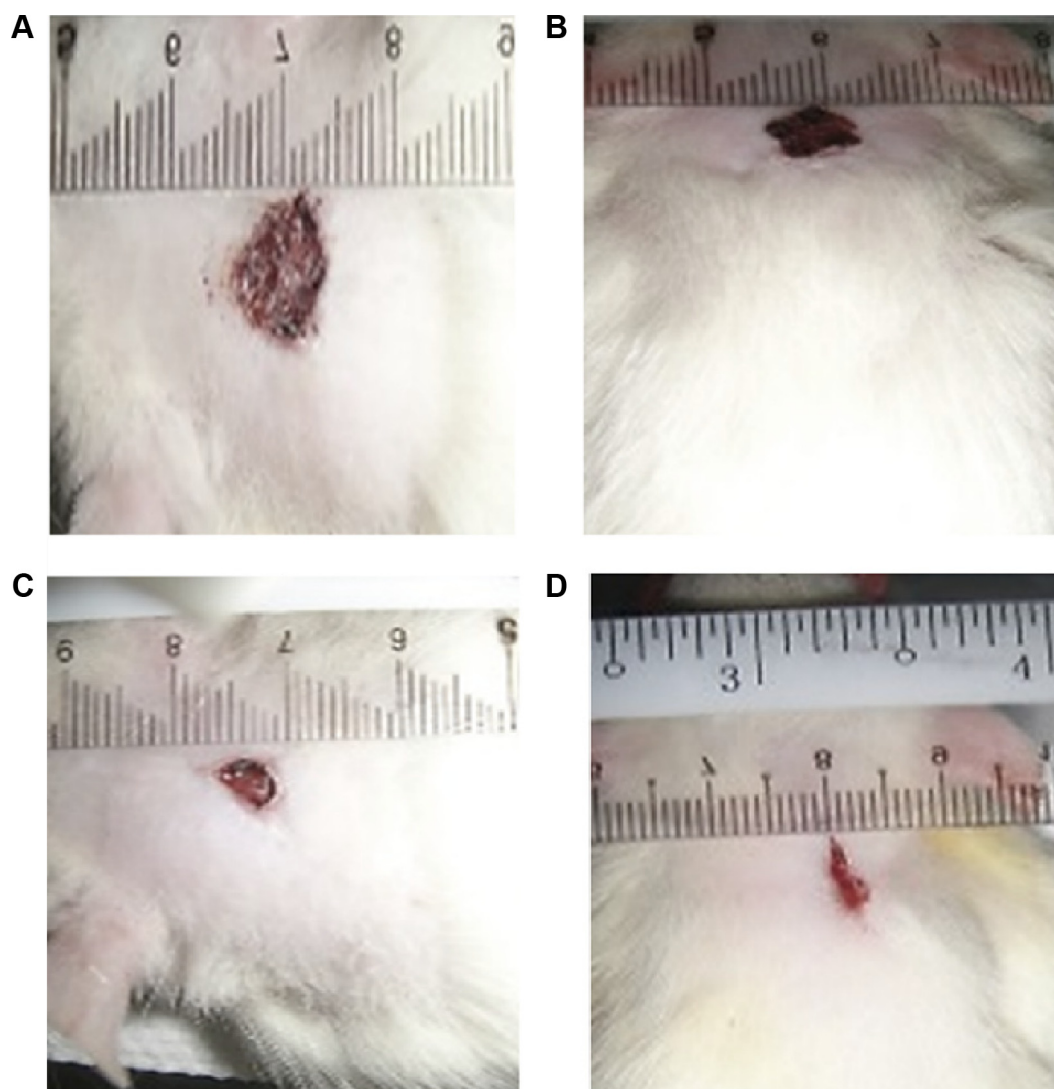


Figure 2 Gross appearance of the excision wound in rats after 20 days of treatment (0.2 mL) with (A) blank placebo, (B) HECP (100 mg/kg), (C) HECP (200 mg/kg), and (D) intrasite gel on excision wound contraction.

Abbreviation: HECP, hexane extract of *Curcuma purpurascens* rhizome.

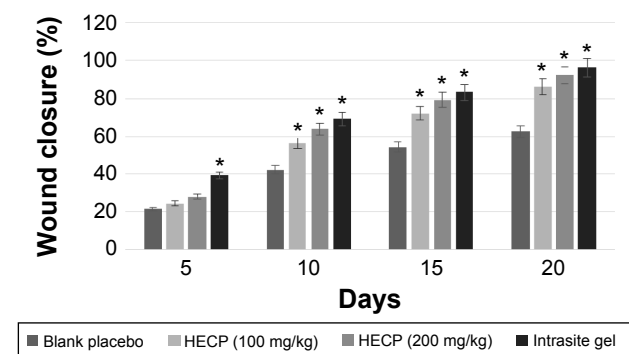


Figure 3 Effect of topical treatment (0.2 mL) with blank placebo, HECP (100 mg/kg), HECP (200 mg/kg), and intrasisite gel on excision wound contraction percentage after 5, 10, 15, and 20 days.

Notes: Values are expressed as mean \pm SEM, $n=6$ animals in each group. * $P<0.05$ vs negative control rats.

Abbreviation: HECP, hexane extract of *Curcuma purpurascens* rhizome.

Histological evaluations validated the accelerated wound healing effect of HECP

Histological analysis of the wound tissues was carried out on day 20 after operation using hematoxylin and eosin, and Masson's trichrome stains. As shown in Figures 4 and 5, both stains illustrated that the scar width was considerably reduced after topical administration of HECP for 20 days, when compared with negative control group. The granulation tissues from rats treated with blank placebo contained high number of inflammatory cells (mononuclear cells), which were comparatively reduced after topical treatment

with HECP (both concentrations) or intrasisite gel (Figures 4 and 5). Instead, the collagen fiber and fibroblast formations were conspicuously stimulated and enhanced in these three groups. In addition, as illustrated in Figure 5, new blood vessels were actively formed in rats treated with HECP at both concentrations, comparable with the intrasisite gel group.

Histological evaluations revealed a significant elevation in wound repair after topical administration of HECP. Mechanisms underlying this effect could be due to an increase in angiogenesis and deposition of collagen fibers. Collagen, a principal component of connective tissue, is a critical contributing factor for the tensile strength of healing wounds.²² Our results showed that apart from a decline in the number of inflammatory cells, collagen fiber synthesis was augmented in the wound site. Impairment of blood flow to the wound site causes severe deficiencies in the wound-healing process, including decreased anabolic activity, impaired local immune and cell defenses, oxidative stress, protein malnutrition and shortage of growth factors. All these factors amplify the collapse in collagen and fibroblast synthesis.^{23,24} As a major determinant in the wound-healing process, angiogenesis enables oxygen and nutrient deliveries to the wound area that result in the suppression of ROS stress and the facilitation of the local collagen synthesis and reepithelialization.²⁵

Topical application of HECP induced downregulation of Bax

The energy-dependent mechanism of apoptosis has a pivotal role in the progression of wound-healing process.^{26,27}

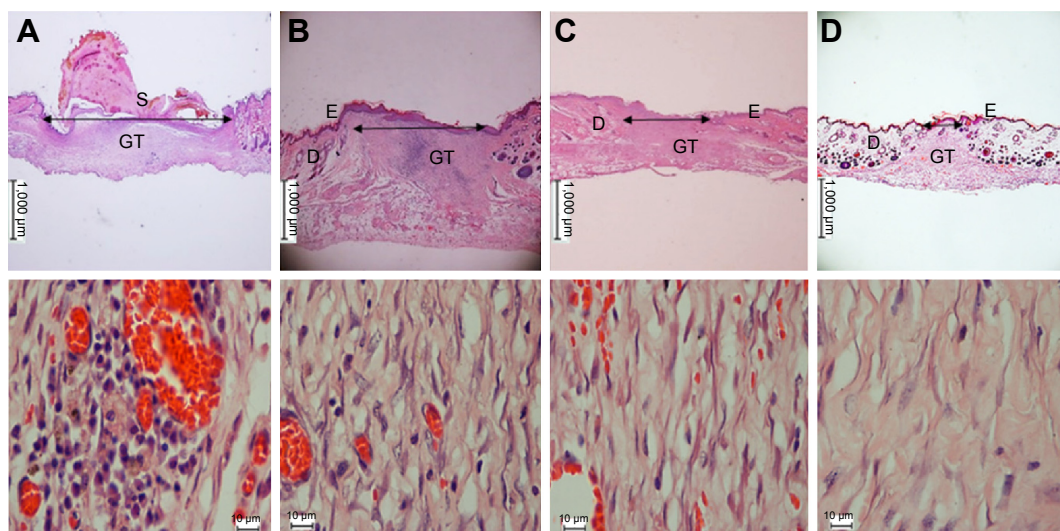


Figure 4 Histopathological view of excision wound healing after H&E staining at two magnifications.

Notes: On the 20th day of treatment, wound tissues were processed from rats treated with (A) blank placebo, (B) HECP (100 mg/kg), (C) HECP (200 mg/kg), and (D) intrasisite gel. Skin sections illustrate dermis, epidermis, granulation tissue, and scar width. Scale bar: 1,000 μ m (low magnification) and 10 μ m (high magnification).

Abbreviations: D, dermis; E, epidermis; GT, granulation tissue; H&E, hematoxylin and eosin; HECP, hexane extract of *Curcuma purpurascens* rhizome; S, scar width.

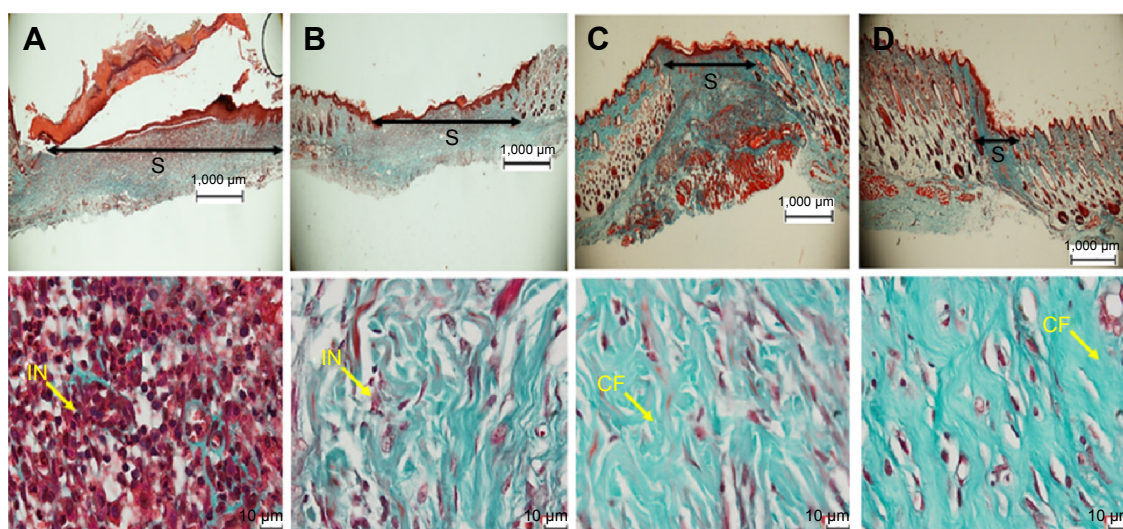


Figure 5 Photomicrographs of healed wounds stained with Masson's trichrome at two magnifications.

Notes: On the 20th day, wound tissues were taken from rats treated with (A) blank placebo, (B) HECP (100 mg/kg), (C) HECP (200 mg/kg), and (D) intrasite gel. Scale bar: 1,000 µm (low magnification) and 10 µm (high magnification).

Abbreviations: CF, collagen fiber; HECP, hexane extract of *Curcuma purpurascens* rhizome; IN, inflammatory cell; S, scar width.

Neutrophils are the first cells that arrive at the wound site to eliminate microorganisms and initiate the inflammatory process.²⁸ Neutrophils and other recruited inflammatory cells could generate ROS in the wound area.²⁶ Excessive production of reactive species oxygen at the wound site results in the induction of apoptosis of surrounding cells, including keratinocytes,²⁹ through activation of pro-apoptotic protein such as Bax and further mitochondrial-initiated events.³⁰ A previous study has suggested a direct relationship between the expression of Bax protein and the corresponding relationship with the apoptotic frequency in the process of wound healing.³¹ Immunohistochemistry staining of the wound sections demonstrated marked Bax protein expression in rats treated with blank placebo, indicating that the wound-healing process is still at the inflammatory phase. However, the other three groups treated with HECP (both doses) and intrasite gel showed a remarkable decrease in Bax protein expression, demonstrating that the wound-healing process was at a later stage. This level of Bax protein expression and induction of apoptosis in these groups is possibly to remove the scar and as a part of normal homeostasis of the tissue cells.

Topical application of HECP induced upregulation of Hsp70

Heat-shock proteins (HSPs) are highly conserved family of proteins and among the most copious intracellular proteins.³² It has been proposed that Hsp70 accelerates wound healing by upregulating macrophage-mediated phagocytosis.^{33,34} A study showed that the level of HSP expression is elevated after the exposure of cells to a wide variety of stress,

including wound injury.³⁴ HSPs have a pivotal role in the wound-healing process through attenuation of the inflammatory responses. Moreover, HSPs defend tissues against injuries by preserving synthesis and conformation of proteins, repairing damaged proteins and accelerating the healing process.³⁵ It was previously established that Hsp70 is the most abundant inducible HSP in the wound bed, therefore its protein expression was determined in this study using immunohistochemistry analysis.³⁶ As illustrated in Figure 6, topically treated rats with blank placebo elicited the basal level of Hsp70; however, the inflammatory cells (mononuclear cells) clearly accumulated in the wound section. The brown staining representing the Hsp70 protein expression was elevated after the administration of HECP at 100 and 200 mg/kg concentrations. The induction of Hsp70 protein expression by HECP was comparable with the effect of intrasite gel. These results strongly suggest that HECP induced the protein expression of Hsp70 in the wound tissue which subsequently accelerated the wound-healing process.

HECP enhanced the activity of antioxidants enzymes

Free radicals or reactive oxygen species (ROS) play a pivotal role in wound-healing process. Skin ischemia in the tissue site causes ROS production by activated leukocytes that can be amplified by positive feedback between the release of free radicals and accumulation of leukocytes.³⁷ Moreover, in the inflammation phase, phagocytosis and digestion of wound debris by neutrophils and macrophages led to the excessive ROS formation in the wound site.³⁸ The human

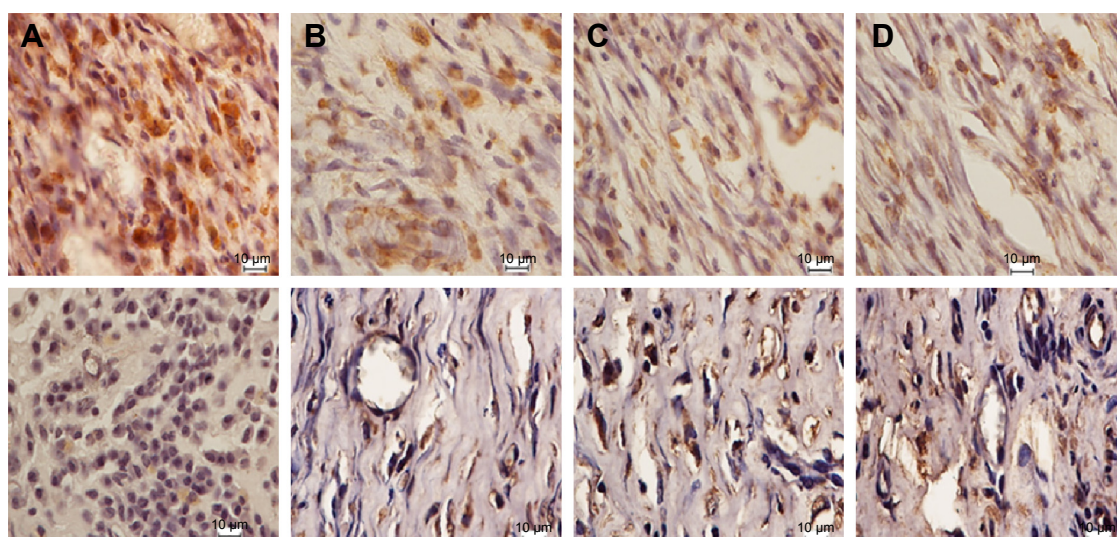


Figure 6 Immunohistochemistry of wound tissue sections for Bax (top row) and Hsp70 (bottom row) proteins from four groups of rats treated with (A) blank placebo, (B) HECP (100 mg/kg), (C) HECP (200 mg/kg), and (D) intrasite gel.

Notes: The tissue sections were taken after 20 days of treatment. Immunopositivity shown as brown staining demonstrated downregulation of Bax and upregulation of Hsp70 in groups (B–D). Scale bar: 10 μ m.

Abbreviation: HECP, hexane extract of *Curcuma purpurascens* rhizome.

body regulates ROS homeostasis through enzymatic systems. The main class of cellular enzymatic antioxidants consists of CAT, GPx, and SOD that play an important role in the vascular system by attenuation of oxidative stress.³⁹ Nonetheless, excessive accumulation of highly reactive radicals could induce different structural changes, including damages to mitochondrial DNA, lipids, and proteins, which result in further reversible or irreversible cell injuries.⁴⁰

As shown in Table 1, after topical administration of HECP (100 and 200 mg/kg), CAT, GPx, and SOD activities were significantly augmented in wound tissue homogenates compared with those treated with blank placebo. The increased enzymatic antioxidants of HECP in wound tissues, especially at 200 mg/kg, were comparable to the positive control. These results were in agreement with previous studies exploring the antioxidant effects of compounds and extracts from *Curcuma* species. An earlier study on four species of *Curcuma* showed the major role of sesquiterpenoids in the antioxidant potential of *Curcuma* species.⁴¹ Investigation on the antioxidant capacity of curcumin-free turmeric oil with

major compounds of ar-turmerone, turmerone, and curlone introduced this oil as an alternative natural antioxidant.⁴² Another in vivo study on antioxidant and antihyperlipidemic effects of turmeric oil with turmerone as the most abundant compound revealed the preventive effect of turmeric oil against oxidative stress generation in hyperlipidemic rats.⁴³ These findings showed that the marked enzymatic antioxidant effect of HECP may be a contributing factor in the wound-healing potential of HECP.

HECP attenuated the MDA level

In biological systems, lipid peroxidation is generally defined as the free-radical oxidation of polyunsaturated fatty acids.⁴⁴ The excessive production of ROS, including hydroxyl radicals in wound tissues, induces lipid peroxidation and causes damage to the cells.⁴⁵ Impairment in the functions of collagen and fibroblast metabolism, endothelial cells, and keratinocyte capillary permeability is one of the destructive effects of lipid peroxidation. Moreover, as a detrimental factor in the expression of vascular-endothelial growth factor, lipid peroxidation

Table 1 Effect of ointment administration on antioxidants enzymes, namely CAT, GPx, and SOD, from four groups of rats

Group	CAT (nmol/mg protein)	GPx (nmol/mg protein)	SOD (U/mg protein)
A: blank placebo (negative control)	35.25 \pm 2.25	0.81 \pm 0.04	13.67 \pm 1.71
B: HECP (100 mg/kg)	65.70 \pm 2.80*	1.75 \pm 0.39*	24.33 \pm 2.03*
C: HECP (200 mg/kg)	79.55 \pm 1.98*	2.46 \pm 0.40*	31.63 \pm 1.23*
D: positive control	84.56 \pm 4.03*	3.08 \pm 0.12*	34.18 \pm 1.90*

Notes: Values are expressed as mean \pm SEM, n=6 animals in each group. * P <0.05 vs negative control rats (Group A).

Abbreviations: CAT, catalase; GPx, glutathione peroxidase; SOD, superoxide dismutase; HECP, hexane extract of *Curcuma purpurascens* rhizome.

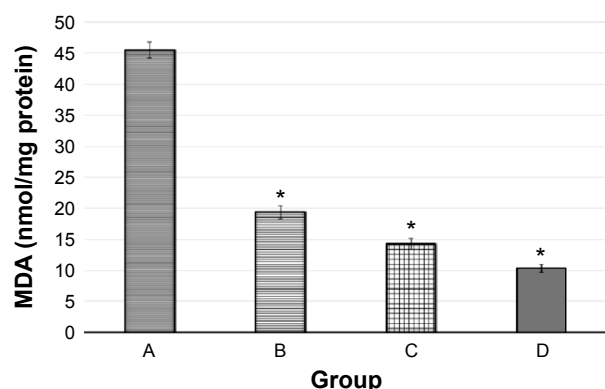


Figure 7 The MDA level in wound tissues homogenates from four groups of rats. **Notes:** Group A: blank placebo, Group B: HECP (100 mg/kg), Group C: HECP (200 mg/kg), and Group D: positive control. Results showed significant attenuation in rats treated topically with HECP (100 mg/kg and 200 mg/kg) and intrasite gel. Values are expressed as mean \pm SEM, n=6 animals in each group. * $p < 0.05$ vs negative control rats (Group A). **Abbreviations:** HECP, hexane extract of *Curcuma purpurascens* rhizome; MDA, malondialdehyde.

can negatively impact the progress of wound-healing process.⁴⁶ As one of the most copious carbonyl products of this process, MDA is an easy index of lipid peroxidation.⁴⁷ As shown in Figure 7, topical administration of HECP (both doses) and intrasite gel significantly declined the MDA level in the wound tissues of rats, compared to the negative control group. However, there was no significant difference between MDA level in the HECP-treated rats and intrasite gel-treated rats representing that HECP at both doses attenuated lipid peroxidation with comparable results with the positive control.

Conclusion

Overall, we provided evidence that the root hexane extract of *C. purpurascens* has positive effects on wound healing. The data substantiated the traditional use of *C. purpurascens* upon wound injury for the first time. The observed pharmacological effect of the *C. purpurascens* rhizome may be due to the presence of sesquiterpenoids such as turmerone, germacrone, and ar-turmerone. The accelerated wound healing in rats after HECP topical administration is facilitated via antioxidant effects, angiogenesis, and deposition of collagen fibers. Moreover, we show that exposure to HECP leads to downexpression of Bax and overexpression of Hsp70 protein at the wound site, indicating a possible mechanistic action at the molecular level.

Acknowledgments

This work was supported by the University Malaya Research Grant (UMRG: RG539-13HTM) and High Impact Research (HIR) MOHE Grant (UM HIR MOHE E000049-20001). The generosity of Prof Sri Nurestri Abd Malek and Prof

Khalijah Awang in providing the plant material is also greatly appreciated.

Author contributions

Acquisition of data: Elham Rouhollahi, Faezeh Tayeb, and Maryam Zahedifard; analysis and interpretation of data: Elham Rouhollahi, Soheil Zorofchian Moghadamtousi, and Fatemeh Hajiaghaalipour; drafting of manuscript: Elham Rouhollahi, Soheil Zorofchian Moghadamtousi, Fatemeh Hajiaghaalipour, and Faezeh Tayeb; critical revision: Elham Rouhollahi, Mahmood Ameen Abdulla, and Zahurin Mohamed. All authors contributed toward data analysis, drafting and critically revising the paper, and agree to be accountable for all aspects of the work.

Disclosure

The authors report no conflicts of interest in this work.

References

- Hayouni E, Miled K, Boubaker S, et al. Hydroalcoholic extract based ointment from *Punica granatum* L. peels with enhanced *in vivo* healing potential on dermal wounds. *Phytomedicine*. 2011;18(11):976–984.
- Balick MJ, Cox PA. *Plants, People, and Culture: the Science of Ethnobotany*. New York: Scientific American Library; 1996.
- Kumar B, Vijayakumar M, Govindarajan R, Pushpangadan P. Ethnopharmacological approaches to wound healing – exploring medicinal plants of India. *J Ethnopharmacol*. 2007;114(2):103–113.
- Zorofchian Moghadamtousi S, Abdul Kadir H, Hassandarvish P, Tajik H, Abubakar S, Zandi K. A review on antibacterial, antiviral, and antifungal activity of curcumin. *Biomed Res Int*. 2014;2014:186864. doi:10.1155/2014/186864.
- Heng MC. Wound healing in adult skin: aiming for perfect regeneration. *Int J Dermatol*. 2011;50(9):1058–1066.
- Rappolee DA, Patel Y, Jacobson K. Expression of fibroblast growth factor receptors in peri-implantation mouse embryos. *Mol Reprod Dev*. 1998;51(3):254–264.
- Diegelmann RF, Evans MC. Wound healing: an overview of acute, fibrotic and delayed healing. *Front Biosci*. 2004;9(1):283–289.
- Santoro MM, Gaudino G. Cellular and molecular facets of keratinocyte reepithelization during wound healing. *Exp Cell Res*. 2005;304(1):274–286.
- Moghadamtousi SZ, Kamarudin MNA, Chan CK, Goh BH, Kadir HA. Phytochemistry and biology of *Loranthus parasiticus* Merr, a commonly used herbal medicine. *Am J Chin Med*. 2014;42(01):23–35.
- Hajiaghaalipour F, Kanthimathi M, Abdulla MA, Sanusi J. The effect of *Camellia sinensis* on wound healing potential in an animal model. *Evid Based Complement Alternat Med*. 2013;2013:386734.
- Rouhollahi E, Zorofchian Moghadamtousi S, Hamdi OAA, et al. Evaluation of acute toxicity and gastroprotective activity of curcuma purpurascens BL rhizome against ethanol-induced gastric mucosal injury in rats. *BMC Complement Altern Med*. 2014;14:378.
- Koller E. *Javanese Medical Plants used in Rural Communities* [Master thesis]: Wien: Pharmacognosy Department, University of Vienna; 2009.
- Tamri P, Hemmati A, Boroujerdnia MG. Wound healing properties of quince seed mucilage: *In vivo* evaluation in rabbit full-thickness wound model. *Int J Surg*. 2014;12(8):843–847.
- Hajrezaie M, Hassandarvish P, Moghadamtousi SZ, et al. Chemo-preventive evaluation of a Schiff base derived copper (II) complex against azoxymethane-induced colorectal cancer in rats. *PLoS One*. 2014;9(3):e91246.

15. Wills E. Mechanisms of lipid peroxide formation in animal tissues. *Biochem J.* 1966;99:667–676.
16. Hong S-L, Lee G-S, Syed Abdul Rahman SN, et al. Essential oil content of the rhizome of *Curcuma purpurascens* Bl. (Temu Tis) and its anti-proliferative effect on selected human carcinoma cell lines. *Scientific World Journal.* 2014;2014:397430.
17. Rouhollahi E, Moghadamtousi SZ, Paydar M, et al. Inhibitory effect of *Curcuma purpurascens* Bl. rhizome on HT-29 colon cancer cells through mitochondrial-dependent apoptosis pathway. *BMC Complement Altern Med.* 2015;15(1):15.
18. Jayaprakasha G, Jagan Mohan Rao L, Sakariah K. Chemistry and biological activities of *C. longa*. *Trends Food Sci Technol.* 2005;16(12):533–548.
19. Bakkali F, Averbeck S, Averbeck D, Idaomar M. Biological effects of essential oils—a review. *Food Chem Toxicol.* 2008;46(2):446–475.
20. Thakare V, Chaudhari R, Patil V. Wound healing evaluation of some herbal formulations containing curcuma longa and cynodon dactalon extract. *Int J Phytomed.* 2011;3(3):325–332.
21. Farahpour MR, Emami P, Ghayour SJ. In vitro antioxidant properties and wound healing activity of hydroethanolic turmeric rhizome extract (zingiberaceae). *Int J Pharm Pharm Sci.* 2014;6(8):474–478.
22. Al-Bayaty F, Abdulla MA. A comparison of wound healing rate following treatment with aftamed and chlorine dioxide gels in streptozotocin-induced diabetic rats. *Evid Based Complement Altern Med.* 2012;2012:468764.
23. Longo UG, Lamberti A, Maffulli N, Denaro V. Tissue engineered biological augmentation for tendon healing: a systematic review. *Br Med Bull.* 2011;98(1):31–59.
24. Davidson JM, Klagsbrun M, Hill KE, et al. Accelerated wound repair, cell proliferation, and collagen accumulation are produced by a cartilage-derived growth factor. *J Cell Biol.* 1985;100(4):1219–1227.
25. Buemi M, Galeano M, Sturiale A, et al. Recombinant human erythropoietin stimulates angiogenesis and healing of ischemic skin wounds. *Shock.* 2004;22(2):169–173.
26. Rai NK, Tripathi K, Sharma D, Shukla VK. Apoptosis: a basic physiologic process in wound healing. *Int J Low Extrem Wounds.* 2005;4(3):138–144.
27. Moghadamtousi SZ, Rouhollahi E, Hajrezaie M, Karimian H, Abdulla MA, Kadir HA. *Annona muricata* leaves accelerate wound healing in rats via involvement of Hsp70 and antioxidant defence. *Int J Surg.* 2015;18:110–117.
28. Ohta H, Yatomi Y, Sweeney EA, Hakomori S-I, Igarashi Y. A possible role of sphingosine in induction of apoptosis by tumor necrosis factor- α , in human neutrophils. *FEBS Lett.* 1994;355(3):267–270.
29. Roberts AB, Sporn MB. Physiological actions and clinical applications of transforming growth factor- β (TGF- β). *Growth Factors.* 1993;8(1):1–9.
30. Ocker M, Höpfner M. Apoptosis-modulating drugs for improved cancer therapy. *Eur Surg Res.* 2012;48(3):111–120.
31. Cui YF, Xia GW, Fu XB, et al. Relationship between expression of Bax and Bcl-2 proteins and apoptosis in radiation compound wound healing of rats. *Chin J Traumatol.* 2003;6(3):135–138.
32. Benjamin IJ, McMillan DR. Stress (heat shock) proteins molecular chaperones in cardiovascular biology and disease. *Circ Res.* 1998;83(2):117–132.
33. Kovalchin JT, Wang R, Wagh MS, Azoulay J, Sanders M, Chandawarkar RY. In vivo delivery of heat shock protein 70 accelerates wound healing by up-regulating macrophage-mediated phagocytosis. *Wound Repair Regen.* 2006;14(2):129–137.
34. Atalay M, Oksala N, Lappalainen J, Laaksonen DE, Sen CK, Roy S. Heat shock proteins in diabetes and wound healing. *Curr Protein Pept Sci.* 2009;10(1):85–95.
35. Lamore SD, Cabello CM, Wondrak GT. The topical antimicrobial zinc pyrithione is a heat shock response inducer that causes DNA damage and PARP-dependent energy crisis in human skin cells. *Cell Stress Chaperones.* 2010;15(3):309–322.
36. Wagstaff M, Shah M, McGrouther D, Latchman D. The heat shock proteins and plastic surgery. *J Plast Reconstr Aesthet Surg.* 2007;60(9):974–982.
37. Bickers DR, Athar M. Oxidative stress in the pathogenesis of skin disease. *J Invest Dermatol.* 2006;126(12):2565–2575.
38. Clark L, Moon R. Hyperbaric oxygen in the treatment of life-threatening soft-tissue infections. *Respir Care Clin N Am.* 1999;5(2):203–219.
39. Singh M, Sandhir R, Kiran R. Effects on antioxidant status of liver following atrazine exposure and its attenuation by vitamin E. *Exp Toxicol Pathol.* 2011;63(3):269–276.
40. Valko M, Leibfritz D, Moncol J, Cronin MT, Mazur M, Telser J. Free radicals and antioxidants in normal physiological functions and human disease. *Int J Biochem Cell Biol.* 2007;39(1):44–84.
41. Zhao J, Zhang J-S, Yang B, Lv G-P, Li S-P. Free radical scavenging activity and characterization of sesquiterpenoids in four species of *Curcuma* using a TLC bioautography assay and GC-MS analysis. *Molecules.* 2010;15(11):7547–7557.
42. Yu Y, Chen F, Wang X, et al. Evaluation of antioxidant activity of curcumin-free turmeric (*Curcuma longa* L.) oil and identification of its antioxidant constituents. *ACS Symposium Series.* 2008;993:152–164.
43. Ling J, Wei B, Lv G, Ji H, Li S. Anti-hyperlipidaemic and antioxidant effects of turmeric oil in hyperlipidaemic rats. *Food Chem.* 2012;130(2):229–235.
44. Gutteridge J. Lipid peroxidation and antioxidants as biomarkers of tissue damage. *Clin Chem.* 1995;41(12):1819–1828.
45. Muralikrishna Adibhatla R, Hatcher J. Phospholipase A₂, reactive oxygen species, and lipid peroxidation in cerebral ischemia. *Free Radic Biol Med.* 2006;40(3):376–387.
46. Altavilla D, Squadrito F, Polito F, et al. Activation of adenosine A_{2A} receptors restores the altered cell-cycle machinery during impaired wound healing in genetically diabetic mice. *Surgery.* 2011;149(2):253–261.
47. Marnett LJ. Oxy radicals, lipid peroxidation and DNA damage. *Toxicology.* 2002;181:219–222.

Drug Design, Development and Therapy

Publish your work in this journal

Drug Design, Development and Therapy is an international, peer-reviewed open-access journal that spans the spectrum of drug design and development through to clinical applications. Clinical outcomes, patient safety, and programs for the development and effective, safe, and sustained use of medicines are a feature of the journal, which

Submit your manuscript here: <http://www.dovepress.com/drug-design-development-and-therapy-journal>

Dovepress

has also been accepted for indexing on PubMed Central. The manuscript management system is completely online and includes a very quick and fair peer-review system, which is all easy to use. Visit <http://www.dovepress.com/testimonials.php> to read real quotes from published authors.