

Face-neck lifting and ancillary procedures

A series of 203 cases

Recep Anlatıcı, MD^a, Gökhan Özerdem, MD^b, Sarp Demiralay^c, Ömer Refik Özerdem, MD^{d,*}

Abstract

Various methods and ancillary procedures have been defined in the era of face-lifting surgery.

The purpose of this study was to evaluate the esthetic outcomes of our face-neck cases and the importance of adding ancillary procedures based on individual assessment.

We conducted a retrospective review of 203 face-neck cases, basically following the endoscopic and open principles of Vasconez. The ancillary procedures added in selected cases included genioplasty, augmentation with autologous facial superficial fascial tissue or fat injections, upper lip shortening, perioral dermabrasion, ear lobe reduction, buccal fat reduction, mentum lifting, and upper orbital rim shaving. Complications, postoperative follow-up, esthetic outcomes, and contribution of the ancillary procedures were recorded.

Our esthetic face complication rates were comparable to those of previous studies and included chemosis, hematoma, cyst on the eyelid suture line, skin sloughing, scar abnormalities (hypertrophic scar and widespread scar), pseudoparalysis of the marginal mandibular branch, temporary hypoesthesia of the forehead, irregularity of the glabella after endoscopy, and asymmetry. We did not observe any comorbidity owing to genioplasty and augmentation with autologous tissue except for a case with infection after fat injection.

More improvement can be obtained with careful planning of ancillary procedures in face-neck lifting surgery.

Abbreviation: SMAS = superficial muscular aponeurotic system.

Keywords: ancillary procedures, face lift, neck lift

1. Introduction

Various techniques have been used in the history of face and neck rejuvenation.^[1–29] An optimal surgical result is based on profound knowledge of technical, historical, and anatomic features, experience, planning of each operation with respect to individual facial properties, and benefitting from ancillary interventions, where indicated. In this manuscript, we present our experience of 203 face and neck lifting cases with some ancillary procedures and our original and useful modifications.

2. Materials-methods

As this was a retrospective clinical series research, no ethical committee approval was needed.

Editor: Yan Li.

The authors report no conflicts of interest.

^a Assistant Professor, Sanko University Dep. of Plastic and Reconstructive Surgery, G.Antep, ^b Consultant Plastic Surgeon, A-PlastEstetik, Antalya, ^c Bahcesehir University, School of Medicine, Istanbul, ^d Professor of Plastic Surgery, A-Plast Estetik, Istanbul, Turkey.

* Correspondence: Ömer Refik Özerdem, Akasya AVM, A1 Kule, D:117Acibadem-Istanbul-Turkey, Professor of Plastic Surgery, A-Plast Estetik, Istanbul 34660, Turkey (e-mail: omerozerdem@yahoo.com).

Copyright © 2018 the Author(s). Published by Wolters Kluwer Health, Inc. This is an open access article distributed under the terms of the Creative Commons Attribution-Non Commercial-No Derivatives License 4.0 (CCBY-NC-ND), where it is permissible to download and share the work provided it is properly cited. The work cannot be changed in any way or used commercially without permission from the journal.

Medicine (2018) 97:39(e12333)

Received: 10 April 2018 / Accepted: 21 August 2018

<http://dx.doi.org/10.1097/MD.000000000012333>

2.1. Face-neck lifting

We used the Superficial Muscular Aponeurotic System (SMAS) and malar fat pad suspension technique as described by Vasconez.^[1–6] Briefly, skin dissection was carried out above the superficial fascial and malar fat pad layers to the level of a line drawn vertically from the outer eyebrow. The pre- and infra-auricular excess SMAS was resected. No further SMAS dissection was carried out. The excision was started inferior to the zygomatic arch and continued downward and backward, to avoid the temporal and marginal mandibular facial nerve branches. Then, the superficial structures (SMAS, posterior platysma, malar fat pad, and orbicularis oculi) were suspended to the superficial temporal or mastoid fascia with polydioxanone sutures. Finally, the excess skin was excised without any tension that might impair the healing process.

In the neck, liposuction and suspension of the platysma to the mastoid and sternocleidomastoid fascia were carried out in all cases requiring mild to moderate neck correction. In more severe cases, open submental intervention was also carried out. The submental incision was followed by subcutaneous liposuction with tiny cannulas, enabling removal of the excess fat as well as much easier dissection and elevation of the skin with immediate exposure of the platysma most of the time. Liposuction was carried out carefully with blunt tip cannulas and a 2- to 3-mm-thick subcutaneous fat pad was preserved when elevating the skin flap to avoid irregularity of the skin and hollowness of the neck.^[9] Plication of the platysma in the midline and transverse partial transection were then completed. We did not perform any procedures on the submandibular glands or digastric muscles.

Dissection of the neck after submental incision was limited to the mandibular areas laterally. Additionally, mandibular area

anterior to the masseter muscle was not dissected during midface lifting, as stated above. Thus, facial and submental dissection planes were not in contact with each other to reduce the likelihood of complications such as accidental injury to the marginal mandibular branch.

No drain was inserted, but meticulous hemostasis was performed. The dressing was removed the following day, and the patient was asked to shower. Artificial tear drops and analgesics were prescribed routinely.

2.2. Eyebrow-forehead lifting

We performed endoscopic or combined open-endoscopic methods for eyebrow-forehead lifting as described by Vasconez et al.^[5,6] Briefly, with pure endoscopic technique, 3 small triangles of skin were removed at the frontal hairline followed by subperiosteal dissection to the supraorbital and frontotemporal levels. The endoscope was introduced, the supraorbital periosteum was detached, and finally the depressors between the midline and supraorbital nerve were removed bilaterally with a punch. We modified the technique in cases with more severely ptotic eyebrows by performing two longer, rather than 3 small incisions. These hairline incisions were approximately 3 cm in length, with midpoints at the level of a line between the lateral limbus and lateral canthus. The skin was elevated off the galea inferiorly for a few centimeters and then the subperiosteogaleal plane was approached through a vertical slit incision. After supraorbital periosteal detachment and removal of the depressors by means of an endoscope (as described above), the periosteogaleal complex was folded, and the excess skin was removed, enabling more effective elevation of the eyebrows.

In severe cases, combined open and endoscopic technique was used.^[5,6] A frontal hairline incision was followed by subcutaneous dissection for a few centimeters inferiorly. Then, the subperiosteogaleal approach was achieved through three superior vertical slit incisions. The endoscope was introduced through these incisions and the depressors were removed. The periosteogaleal complex was folded superiorly with polydioxanone sutures, the excess skin was removed, and finally the wound was closed without any tension.

2.3. Upper and lower blepharoplasty

After removal of the excess upper eyelid skin, a strip of the orbicularis oculi muscle was removed to expose the septum and also to create an eyelid fold. The herniated fat was removed conservatively to avoid hollowness. The remaining fat was contracted with bipolar heat (cautiously, to avoid thermal injury to the surrounding soft tissues). In those with blepharoptosis, the levator muscle was plicated with 6/0 polypropylene sutures.^[7] Partial excision of the orbicularis oculi muscle is often carried out laterally to improve deep crow's feet.^[7,8–13]

For the lower eyelids, lateral orbicularis muscle plasty through a temporal facelift incision^[7] was performed for mild and moderate cases. Open lower blepharoplasty with a subciliary incision was added in more severe cases, especially in those with evident festoons. For lower eyelid blepharoplasty, protective measures were applied to avoid possible complications such as ectropion and lower lid retraction, as follows; some marginal skin and orbicularis muscle were preserved during the lower eyelid incision; very conservative skin excision was performed, mostly laterally; 2 silk sutures were placed medially and laterally on the suture line for the purpose of frontal traction, to be removed the

following day; the orbicularis was suspended to the orbital rim periosteum; canthopexy was added, especially if the eyelids were lax. The herniated fat was treated by thermal contraction with or without conservative partial excision, or was released and radiated downward to fill the infraorbital depression and tear trough area. Bipolar thermal contraction was performed very carefully to avoid damage to the local tissues, especially the extraocular muscles.

2.4. Tissue augmentation

Rather than discarding the valuable autologous tissues, we preferred to use them to treat volume deficiencies.^[12,25–27] Excised platysma, orbicularis or SMAS from the face and neck were used to fill perioral, infraorbital, and nasolabial depressions, as well as to improve the vertical and transverse creases of the frontal area. These tissues were also used for augmentation of the lips. Superficial temporal fascial grafts and fat injections were also used for the same purposes, when needed. In endoscopic-open combined forehead lifting, a piece of SMAS was placed and/or the underlying SMAS was folded under the level of the deep frontal crease. If the crease was lower than the level of the skin dissection or in purely endoscopic cases, the SMAS graft was inserted through a subcutaneous tunnel using two or three small incisions.

2.5. Genioplasty

Advancement genioplasty was combined with midface lifting in 12 cases. Submental dissection for platysmaplasty was not added in any of these cases. Genioplasty operations were performed as previously described.^[29–31] Briefly, an intraoral incision was followed by subperiosteal dissection and transverse mandibular symphyseal osteotomy. Fixation was achieved with three wires after advancement. All procedures were carried out with extreme caution to avoid injuring the mental nerve; three precautions were taken: some soft tissue around the nerve was preserved, osteotomy was performed a minimum 6 mm below the mental foramen to avoid downward curve of the mental nerve inside the bone, and finally, the aspirator was used very carefully, since Wolfe^[32] stated that nerve injury generally occurs as a result of vigorous use of the aspirator tip by the assistant.

We assessed the adequacy of bone advancement by taking three points of Riedel plane (upper lip, lower lip, and soft tissue pogonion) as the reference points on the profile. No cephalometric examination was needed.^[31]

2.6. Other procedures

Other procedures were upper lip shortening, perioral dermabrasion, ear lobe reduction, intraoral buccal fat reduction, mentum lifting, upper orbital rim shaving, and treatment of masseteric muscle hypertrophy (with partial excision of the masseteric muscle and reduction of the lateral surface of the mandibular angle), where indicated.

3. Results

We used combined techniques and some of our modifications in esthetic facial cases during the last decade (Figs. 1–18). A retrospective chart review of 203 facial cases that were followed up for at least 6 months was conducted. Age ranged from 45 to 67 years with an average of 52 years. There were 195 women (96.06%) and 8 (3.94%) men. The neck area was managed with



Figure 1. Preoperative views of a 50-year-old-male. Face-neck lifting, upper blepharoplasty, and open-endoscopic combined forehead lifting were performed. Excised SMAS and platysmal tissues were used as autografts to fill the deep transverse and vertical creases of the forehead.

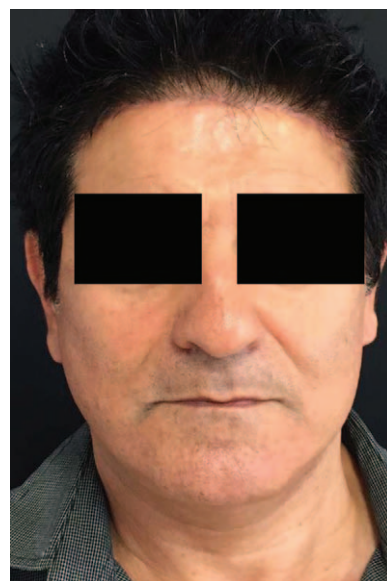

Figure 3. Postoperative views of the same case after 2 years.

posterior lifting of the platysma and liposuction in all cases, as described above. In 93 cases (45.81%), submental incision was added for midline plication of the platysma. In 12 (5.91%) cases, a face lift was combined with advancement genioplasty, with fat injections in 20 (9.85%) and autologous tissue augmentation in 25 (12.32%). Upper blepharoplasty was added in 195 cases (96.06%) and lower blepharoplasty in 33 (16.26%). Symmetric or asymmetric blepharoptosis was detected in 25 cases (12.32% of upper eyelid operations) and satisfactorily managed with

levator plication. Two (0.99%) iatrogenic lower eyelid retraction cases that were referred from other clinics were treated with lateral canthopexy. Eyebrow-forehead lifting procedures were done in 120 (59.11%) cases. Most of our patients were satisfied with the results; only 12 of them (5.91%) were dissatisfied with the results overall.

Complications included 4 hematoma cases (1.97%). One underwent immediate operation for evacuation and hemostasis; the others were managed during follow-up visits with repetitive drainage. We observed no seroma.

Although 1 case had prolonged drainage from multiple points after fat injection (4% of fat injection cases), we observed no infection or drainage in cases with SMAS-platysma-fascia grafting. Interestingly, 2 lip augmentation cases (one with SMAS

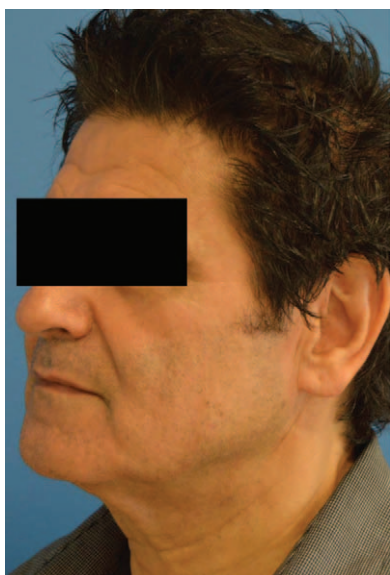

Figure 2. Preoperative views of a 50-year-old-male. Face-neck lifting, upper blepharoplasty, and open-endoscopic combined forehead lifting were performed. Excised SMAS and platysmal tissues were used as autografts to fill the deep transverse and vertical creases of the forehead.

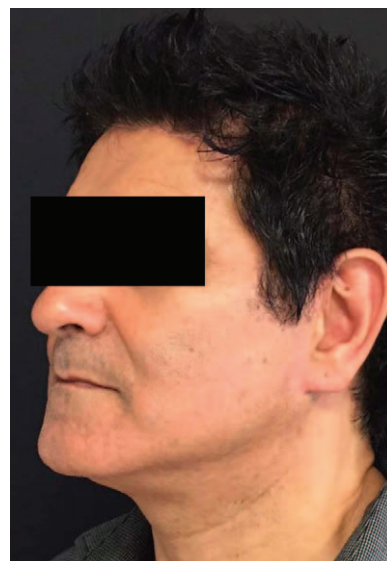

Figure 4. Postoperative views of the same case after 2 years.

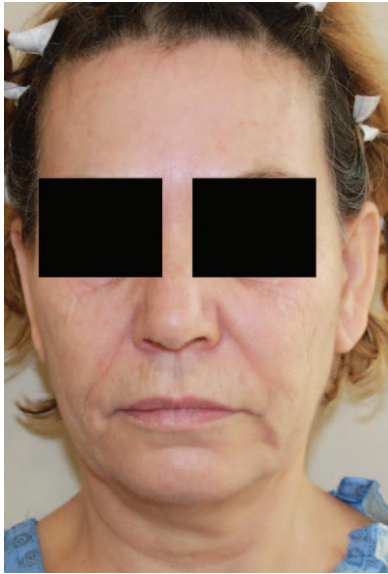

Figure 5. Preoperative view of a 55-year-old-female. Face-neck lifting and upper blepharoplasty were carried out. SMAS grafts are used to treat the glabellar and infraorbital depressions and tear trough deformity. The nasolabial folds were treated with fat injections. Upper lip shortening and dermabrasion as well as lip augmentation with SMAS grafts were also performed.

and the other with temporalis fascia) demanded removal of the grafts within the first month after surgery. Both showed symptoms of depression and were managed with assurance. After the first month, they both changed their minds, with relief of depression symptoms.

Upper eyelid cyst formation on the scar line was observed in 1 case (0.52% of upper blepharoplasty cases). The cyst was

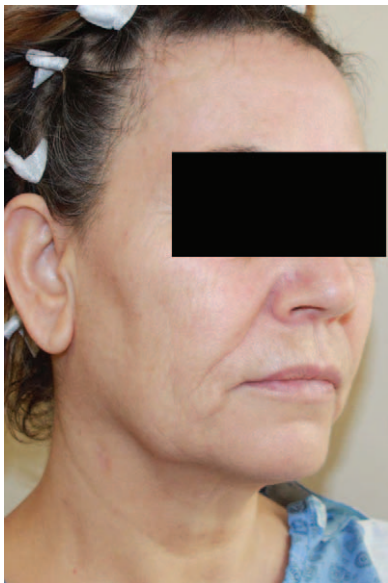

Figure 6. Preoperative view of a 55-year-old-female. Face-neck lifting and upper blepharoplasty were carried out. SMAS grafts are used to treat the glabellar and infraorbital depressions and tear trough deformity. The nasolabial folds were treated with fat injections. Upper lip shortening and dermabrasion as well as lip augmentation with SMAS grafts were also performed.

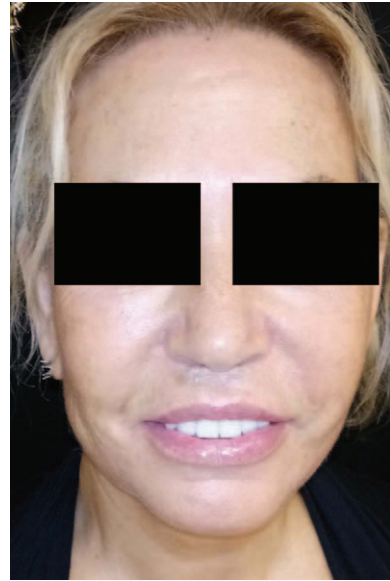

Figure 7. Postoperative views of the same case after a year.

removed under local anesthesia. Revision upper blepharoplasty was demanded by 10 cases (5.13%). Most of these cases complained of residual excess skin and asymmetric scar location between the 2 sides. There was no chemosis in cases with upper eyelid surgery alone. However, this complication arose in some cases with both upper and lower blepharoplasty (6 of 33, 18.18%). All were treated with artificial tears and antibiotic-cortisone eye drops. In 3 cases of lower blepharoplasty (9.09%), revision surgery was demanded for a scar or asymmetry.

Skin sloughing was seen in 5 cases (2.46% of all cases). All were managed with wound care. Four cases underwent revision under local anesthesia after 6 months, and 1 did not demand revision. Other abnormalities included hypertrophic scars in 2 (0.99%) cases as well as recurrent widespread scarring despite

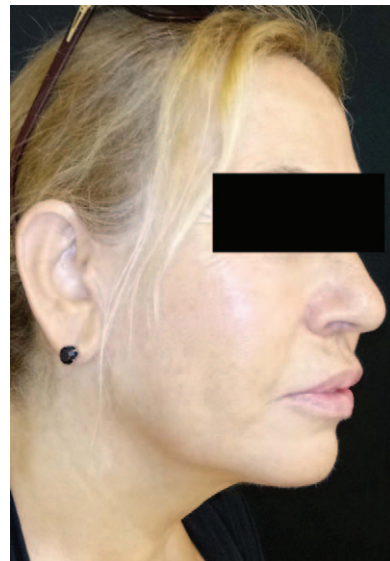

Figure 8. Postoperative views of the same case after a year.

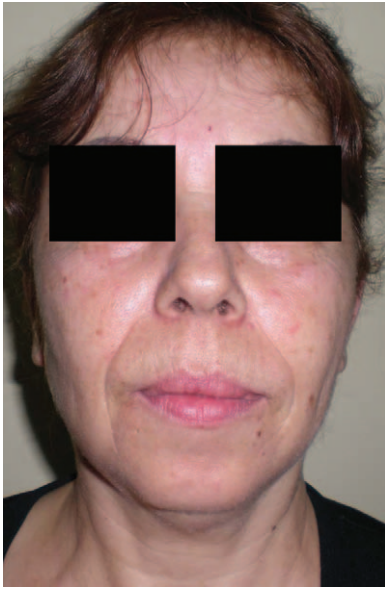


Figure 9. Preoperative view of a 57-year-old-female. Face lifting, neck liposuction, endoscopic eyebrow lifting, lower and upper blepharoplasty with levator plication, and sliding genioplasty were carried out. Deep nasolabial and marionette lines were improved with fat injections.

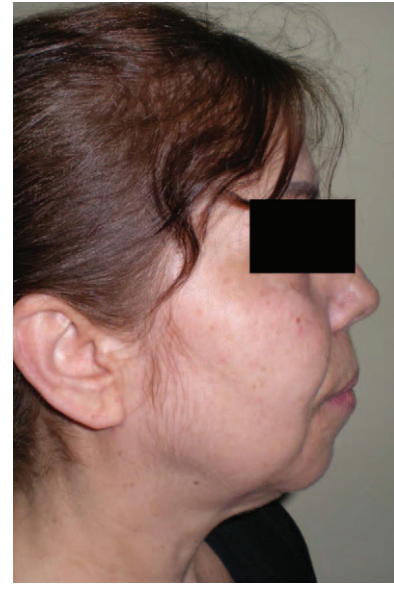

Figure 11. Preoperative view of a 57-year-old-female. Face lifting, neck liposuction, endoscopic eyebrow lifting, lower and upper blepharoplasty with levator plication, and sliding genioplasty were carried out. Deep nasolabial and marionette lines were improved with fat injections.

revision attempts in 1 case (0.49%). One case (0.83%) with glabellar irregularity after endoscopic intervention was managed successfully with fat injection.

No motor nerve injury was detected except in 1 case (0.49%) with pseudoparalysis of the marginal mandibular nerve owing to cervical branch injury. No restriction of lower lip eversion was observed in this case. The problem subsided gradually within a few months. Temporary forehead hypoesthesia was the complaint in 10 of 120 (4.92%) forehead cases. No complications such as dysesthesias, extrusion, chronic pain, and neuropraxia were observed because of suspension sutures.

Advancement genioplasty with osteotomy and wire fixation were carried out in 12 face lift cases. There were no complications, and neck contour and patient satisfaction were significantly improved (Figs. 9–18). Wire fixation was adequate to obtain osteotomy line stability in all cases, as stated above. However, patients were informed preoperatively that screw-plate systems might be necessary, should wires be insufficient for osteosynthesis. Platysmaplasty through submental incision was not performed in these cases.

We observed that an additional chin operation did not prolong the recovery period significantly, which was a main concern in some cases. Tapes were applied around the chin postoperatively

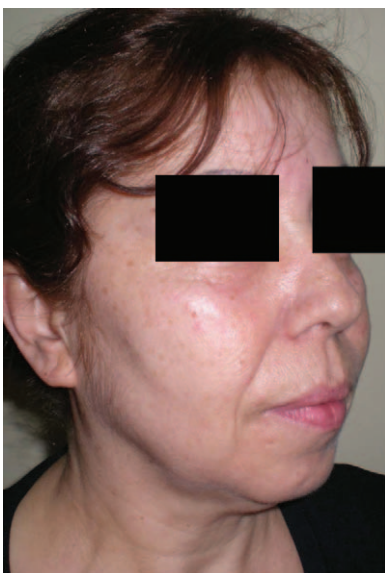

Figure 10. Preoperative view of a 57-year-old-female. Face lifting, neck liposuction, endoscopic eyebrow lifting, lower and upper blepharoplasty with levator plication, and sliding genioplasty were carried out. Deep nasolabial and marionette lines were improved with fat injections.

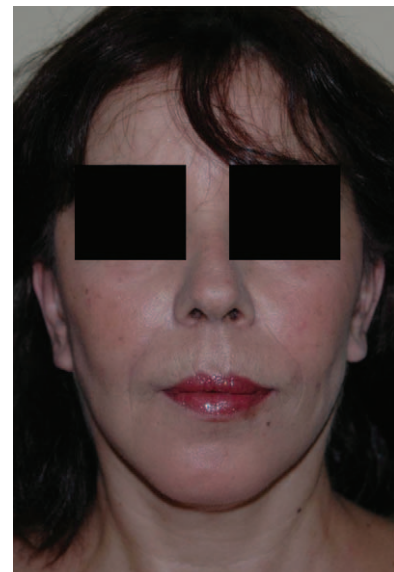

Figure 12. Postoperative views of the same case after 6 months.

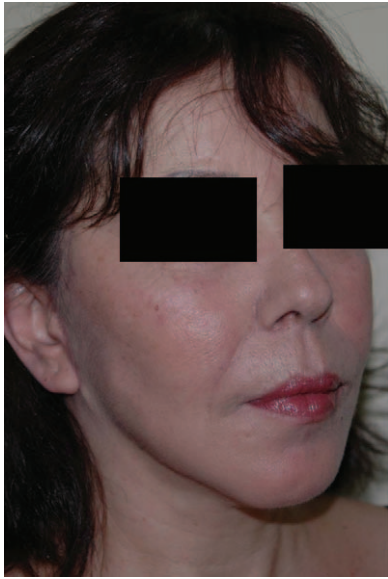

Figure 13. Postoperative views of the same case after 6 months.

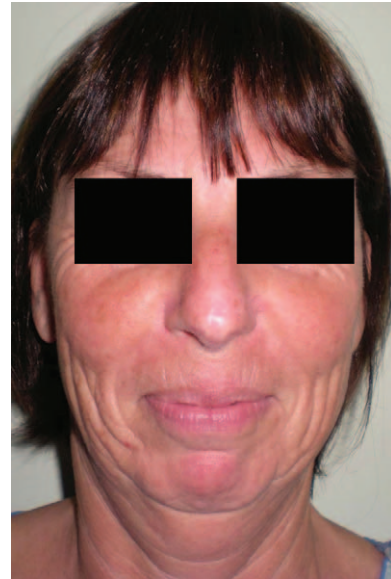

Figure 15. Preoperative view of a 54-year-old-female. Face lifting,neck liposuction, endoscopic eyebrow lifting, lower and upper blepharoplasty, and sliding genioplasty were carried out.

and daily mouthwash was recommended to relieve edema and to ensure uncomplicated wound healing.

4. Discussion

Three main issues must be taken into account in face rejuvenation: sagging tissues, volume deficiency, and skin degeneration. All these should be addressed in the same session or in additional sessions to obtain optimal results. For instance, while treating sagging tissues with face-neck lifting, volume problems could be solved with autologous grafts, and so-called smoking lines with dermabrasion. Likewise, the upper lips become longer and thinner with aging. Addressing these changes in a face lift would further improve the results very significantly.

We believe in retrospect that individually tailored combined procedures offer greater patient and surgeon satisfaction. Our esthetic face complication rates were comparable to those of previous studies,^[1,3–8,33] and included chemosis, hematoma, cyst on the eyelid suture line, skin sloughing, scar abnormalities (hypertrophic and widespread scar), pseudoparalysis of the marginal mandibular branch, temporary hypoesthesia, irregularity of the glabella after endoscopy, and asymmetry. We did not observe any comorbidity owing to the ancillary procedures except for a case with infection because of fat injection.

The main limitation of our study was the difficulty of the assessment of the satisfaction rate. As our operations were as combined interventions, some patients were very satisfied with

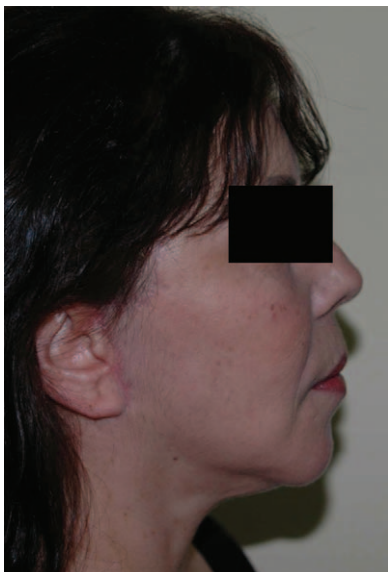

Figure 14. Postoperative views of the same case after 6 months.

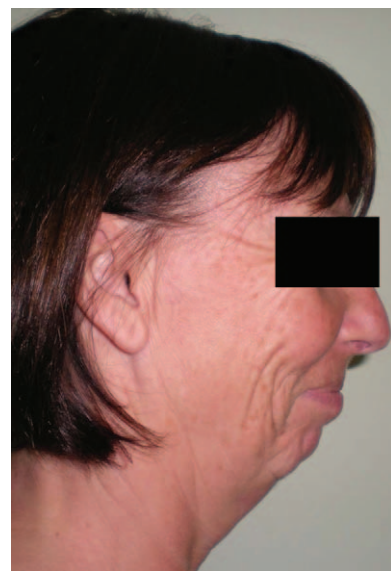

Figure 16. Preoperative view of a 54-year-old-female. Face lifting,neck liposuction, endoscopic eyebrow lifting, lower and upper blepharoplasty, and sliding genioplasty were carried out.

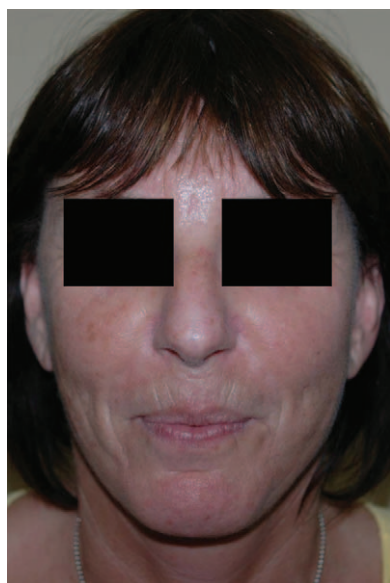

Figure 17. Postoperative views of the same case after 2 months. Note that almost 180 degrees of neck angle became 90 degrees without submental open intervention. Upper dermabrasion was not requested before the operation but would have been very beneficial.

one part of the operation, but not with another part. All of the genioplasty patients were satisfied with the improved chin-neck contours; however, some blepharoplasty patients demanded revisions, as stated before. However, only 12 patients (5.91%) were dissatisfied with the overall results.

Kaye^[19] preferred to perform ancillary procedures during a separate session owing to the increased operating time required. We often completed the face lift and ancillary procedures in the same sitting and completed most of the procedures in our study

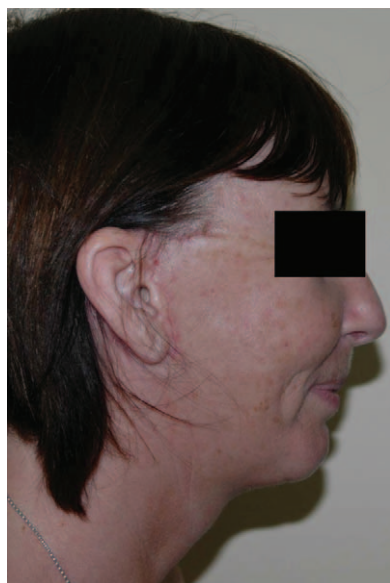

Figure 18. Postoperative views of the same case after 2 months. Note that almost 180 degrees of neck angle became 90 degrees without submental open intervention. Upper dermabrasion was not requested before the operation but would have been very beneficial.

population within 3.5 hours. In 1 case, we combined the face lift with post-bariatric procedures (mammoplasty and abdominoplasty) that lasted for 5.5 hours. Our main strategy is to perform the combined operations using 2 surgeons to shorten the duration, as we believe that the shorter the operative time, the less the morbidity. As a result, the majority of our cases were discharged from the hospital the following day without any major problem. The main problem seemed to be slightly prolonged postoperative edema because of additional procedures. We observed that edema and bruising subsided significantly within 2 weeks. However, in cases in which forehead lifting was combined with both upper and lower blepharoplasty or in which infraorbital fat injections were added, edema persisted for up to 3 or 4 weeks. Only 1 patient, a fitness trainer, complained of prolonged swelling and difficulty in returning to work, even after 2 months, probably because of straining during exercise.

Cabbabe et al^[8] analyzed 76 periorbital rejuvenation patients and concluded that suspension of the orbicularis decreases the complication rate and avoids lower eyelid incision as well as more extensive dissection in some cases. We performed lateral orbicularis oculi muscle rejuvenation in all of our cases without any major comorbidity. Lower eyelid incision was only added in more severe cases.

We believe that plastic surgeons, who are familiar with craniofacial interventions, have many more options in the management of esthetic facial cases. Anatomic knowledge and subperiosteal dissection enable them to fix the stretched soft tissues to the bone and to change the skeleton of the face using osteotomies without the necessity of a foreign material. Genioplasty is a good example. Wolfe^[32] stated that genioplasty is an ideal operation for plastic surgeons who only recently started performing craniofacial surgery. Kawamoto^[31] suggested that all plastic surgeons should be able to perform this operation. It is very beneficial in some cervicoplasty cases. Moreover, Rohrich et al^[9] said: "The chin should be considered whenever facial rejuvenation is considered. Inadequate chin projection may detract from the aesthetic result of an otherwise superb facial rejuvenation procedure."

Guyuron et al^[34] compared osteoplastic and alloplastic genioplasty in 76 cases and concluded that both methods were effective and satisfactory. However, they noted that the soft tissue response was more predictable for osteoplastic genioplasty and that the cervicomenal angle improved more with osteoplastic genioplasty. Jones and Vesely^[35] also reported the versatility and long-term stability of osteoplastic genioplasty compared to alloplastic methods, after analyzing 54 patients retrospectively.

We have not used implants to advance the chin for a long time. We believe that advancement genioplasty is more effective than the use of chin prosthesis for tightening of the local muscles, as they are directly attached to the advanced bone. Additionally, risks associated with use of foreign material are avoided.^[36]

We carried out neck liposuction and posterior platysma suspension in all of our cases, as stated above. In more severe neck sagging, fat removal and muscle plication through a submental incision was necessary. Rather than performing a wide dissection of the face and neck as a unified plane, we did not dissect mandibular area anterior to the masseter edge. Thus, we avoided the marginal mandibular branch. We also feel that neck deformities caused by wide dissection were prevented. However, we also accept that connected dissection of the facial and cervical areas might be needed in cases with severe neck sagging.

We feel that simultaneous genioplasty decreases the necessity of submental open platysmaplasty in many cases. We thought SMAS-platysmal fixation to the mastoid and sternocleidomastoid fascia as well as stretching of the neck muscles by means of advancement of attached bone was sufficient to treat the neck problems in our cases. However, we also admit that in more severe neck sagging, combination of fat excision and platysmaplasty through a submental incision might be necessary.

Leaf and Firouz^[25] performed lip augmentation with SMAS tissue in 103 cases and obtained very natural results. Calderon et al^[26] reported the results of 70 cases for which they used SMAS to treat deep nasolabial folds. We prefer using all removed muscle tissues (even excised blepharoplasty tissues^[37]), SMAS, and fascia to augment deep creases or folds. We believe that these are more predictable as compared to fat injections. A tunnel created through 2 or 3 small incisions is all that is needed to insert these tissues. However, fat injections and superficial temporal fascial grafts are also very useful when more soft tissue is needed.

We observed that endoscopic methods are very effective in brow lifting. Endoscopy could be used in combination with open hairline incision in more severe cases. However, in cases that reject a long hairline scar (especially younger cases) or those with short hairline-eyebrow distances, two 3-cm incisions on both sides could be an option. These longer incisions allow entrance of the endoscope and plication of the periosteal-galeal complex, hence providing effective elevation of the eyebrows.

5. Conclusion

Profound knowledge of anatomy and history, and planning of each operation with respect to patient's physical findings are of paramount importance in face-neck lifting. Ancillary procedures and modifications during face-neck lifting operations would further support the results without any significant increase in comorbidity, and increase the satisfaction rate for both surgeons and patients.

Author contributions

Investigation: Sarp Demiralay.

Project administration: Recep Anlatıcı, Gokhan Ozerdem, Ömer Refik Özerdem.

References

- [1] Gamboa GM, de la Torre J, Vasconez LO. Surgical anatomy of the midface as applied to facial rejuvenation. *Ann Plastic Surg* 2004;52:240–5.
- [2] Gamboa-Bobadilla M, Ozerdem OR, Vasconez LO, Grotting J. Adjunctive surgical procedures to improve the facelift results. *Reoperative Aesthetic and Plastic Surgery Quality Medical Pub*, St. Louis, MI:2006;347–76.
- [3] De Cordier BC, de la Torre JI, Al-Hakeem MS, et al. Rejuvenation of the midface by elevating the malar fat pad: review of technique, cases, and complications. *Plast and Reconstr Surg* 2002;110:1526–36.
- [4] Ozerdem OR, Andrades P, Vasconez LO, Shiffman MA, Mirrafati S, Samuel M, et al. Anatomy and surgical approaches to the midface lift. *Simplified Facial Rejuvenation Springer*, Berlin:2008;505–21.
- [5] Ozerdem OR, Andrades P, Vasconez LO, Shiffman MA, Mirrafati S, Samuel M, et al. Endoscopic forehead lifting. *Simplified Facial Rejuvenation*. Springer, Berlin:2008;437–41.
- [6] Ozerdem OR, Vasconez LO, de la Torre J. Upper face lifting. *Facial Plast Surg Clin North Am* 2006;14:159–65.
- [7] de la Torre JI, Martin SA, De Cordier BC, et al. Aesthetic eyelid ptosis correction: a review of technique and cases. *Plast and Reconstr Surg* 2003;112:655–60.
- [8] Cabbabe SW, Andrades P, Vasconez LO. Lateral orbicularis oculi muscle plasty in conjunction with face lifting for periorbital rejuvenation. *Plast and Reconstr Surg* 2009;124:1285–93.
- [9] Rohrich RJ, Rios JL, Smith PD, et al. Neck rejuvenation revisited. *Plast Reconstr Surg* 2006;118:1251–63.
- [10] Viterbo F. New treatment for crow's feet wrinkles by vertical myectomy of the lateral orbicularis oculi. *Plast Reconstr Surg* 2003;112:275–9.
- [11] Connell BF, Marten TJ. Surgical correction of the crow's feet deformity. *Clin Plast Surg* 1993;20:295–302.
- [12] Aston SJ. Orbicularis oculi muscle flaps: a follow-up of the technique to reduce crow's feet and lateral canthal skin folds. *Clin Plast Surg* 1981;8:679–86.
- [13] Camirand A. Treatment of dynamic crow's feet while performing a blepharoplasty. *Aesthetic Plast Surg* 1993;17:17–21.
- [14] Ramirez O. Endoscopic Full face lifting. *Aesth Plast Surg* 1994;18:363–71.
- [15] Teimourian B, Delia S, Wahrman A. The multiplane face lift. *Plast and Reconstr Surg* 1994;93:78–85.
- [16] Owsley JQ. SMAS-platysma facelift. A bidirectional cervicofacial rhytidectomy. *Clin Plast Surg* 1983;10:429–40.
- [17] Connell BF, Marten TJ. The trifurcated SMAS flap: three-part segmentation of the conventional flap for improved results in the midface, cheek, and neck. *Aesth Plast Surg* 1995;19:415–20.
- [18] Baker D. Lateral SMASectomy, plication and short scar facelifts: indications and techniques. *Clin Plast Surg* 2008;35:533–50.
- [19] Kaye B. The Extended facelift with ancillary procedures. *Ann Plast Surg* 1981;6:335–46.
- [20] Wolfe SA, Baird WL. The subcutaneous forehead lift. *Plast Reconstr Surg* 1989;83:251–6.
- [21] Wolfe SA, Fusi S. Treatment of the particularly fatty neck and the short-interval secondary facelift. *Aesth Plast Surg* 1991;15:195–201.
- [22] Oscar R. The subperiosteal rhytidectomy: the third-generation face-lift. *Ann Plast Surg* 1992;28:218–34.
- [23] Larson DL. An historical glimpse of the evolution of rhytidectomy. *Clin Plast Surg* 1995;22:207–12.
- [24] Hester TR, Codner MA, McCord CD, Nahai F, Giannopoulos A. Evolution of technique of the direct transblepharoplasty approach for the correction of lower lid and midfacial aging: maximizing results and minimizing complications in a 5-year experience. *Plast Reconstr Surg* 2000;105:393–406.
- [25] Leaf N, Firouz J. Lip augmentation with superficial musculoaponeurotic system grafts: report of 103 cases. *Plast Reconstr Surg* 2002;109:319–26.
- [26] Calderon W, Andrades P, Guillermo I, et al. SMAS graft of the nasolabial area during deep plane rhytidectomy. *Plast Reconstr Surg* 2004;114:559–64.
- [27] Little JW. Applications of the classic dermal fat graft in primary and secondary facial rejuvenation. *Plast Reconstr Surg* 2002;109:788–804.
- [28] Zins JE, Fardo D. The “anterior-only” approach to neck rejuvenation: an alternative to face lift surgery. *Plast Reconstr Surg* 2005;115:1761–8.
- [29] Wider TM, Spiro SA, Wolfe SA. Simultaneous osseous genioplasty and meloplasty. *Plast Reconstr Surg* 1997;99:1273–81.
- [30] Wolfe SA. Chin advancement as an aid in correction of deformities of the mental and submental regions. *Plast Reconstr Surg* 1981;67:624–9.
- [31] Kawamoto H. Osseous genioplasty. *Aesth Surg J* 2000;20:509–16.
- [32] Wolfe SA. Personal communication (corresponding author) as his craniofacial fellow. 2002–2003.
- [33] Rees TD, Barone CM, Valauri FA, et al. Hematomas requiring surgical evacuation following face lift surgery. *Plast Reconstr Surg* 1994;93:1185–90.
- [34] Guyuron B, Richard LR. A critical comparison of osteoplastic and alloplastic augmentation genioplasty. *Aesth Plast Surg* 1990;14:199–206.
- [35] Jones BM, Vesely MJJ. Osseous genioplasty in facial aesthetic surgery—a personal perspective reviewing 54 patients. *J Plast Reconstr Aesth Surg* 2006;59:1177–87.
- [36] Terino EO, Peck G. Complications of chin and malar augmentation. *Complications and Problems in Aesthetic Plastic Surgery*. Gower Medical, New York:1991;62–3.
- [37] Yen MT, Anderson RL, Small RG. Orbicularis oculi muscle graft augmentation after protractor myectomy in blepharospasm. *Ophthalmic Plast Reconstr Surg* 2003;19:287–96.