

Pityriasis rubra pilaris potentially triggered by messenger RNA–1273 COVID vaccine



Etsubdenk M. Ajebo, MD, John D. Howard, BS, Dipti Anand, MD, and Loretta S. Davis, MD
Augusta, Georgia

Key words: intraepidermal acantholysis; Moderna vaccine; pityriasis rubra pilaris; vaccine.

INTRODUCTION

Multiple common cutaneous reactions, including delayed large local reactions, urticaria, and morbilliform eruptions, have been attributed to vaccinations, including the messenger RNA–1273 COVID-19 vaccine (Moderna).¹ Although less frequent, vaccines have also been implicated in triggering papulosquamous eruptions, including psoriasis, lichen planus, and, rarely, pityriasis rubra pilaris (PRP). A case of PRP following Moderna vaccination is presented.

CASE

A 75-year-old, otherwise healthy man presented to his dermatologist with scalp redness and flaking that had begun several days after his first Moderna vaccination. Seborrheic dermatitis was diagnosed, and ketoconazole 2% shampoo was prescribed. He received his second Moderna vaccination 4 weeks after the first. Eight days later, he returned to his dermatologist with erythematous patches and plaques on his neck. He denied previous skin issues and any new or chronic medications. He had no family history of PRP.

Based on the timing relative to the skin complaints, the eruption was attributed to the Moderna vaccine. Topical corticosteroids were prescribed. Over the following weeks, the rash progressed in a cephalocaudal pattern, involving the neck, trunk, and proximal extremities. Initial skin biopsies were interpreted as favoring a drug-induced or vaccine-induced reaction. A prednisone taper was prescribed but was discontinued by the patient after 5 days due to minimal improvement and worsening of the rash. Wet wraps over triamcinolone 0.1% ointment offered mild symptomatic improvement. He was referred to our clinic for further evaluation and management.

Abbreviations used:

PRP: pityriasis rubra pilaris

On presentation, he reported chills without fever and mild itching. He denied joint pain and muscle weakness. Examination showed thin, salmon-colored papules and plaques, with minimal desquamation, on the proximal upper extremities and trunk, confluent over the upper trunk and neck. Well-demarcated areas of unaffected skin (islands of sparing) were appreciated on the torso (Fig 1, A). The bilateral palms had a slightly shiny appearance (Fig 1, B). His muscle strength was normal. His creatine phosphokinase and aldolase levels were normal. HIV testing was negative.

A review of the outside histopathology demonstrated hyperkeratosis, follicular plugging, intraepidermal acantholysis, and patchy lichenoid and superficial perivascular lymphocytic infiltrate with scattered eosinophils (Fig 2). A repeat biopsy, performed weeks later, demonstrated alternating orthokeratosis and parakeratosis and acanthosis with broad rete ridges, as described in PRP (Fig 3).

Based on the clinical presentation, supportive histopathology, and onset following vaccination, a diagnosis of PRP, potentially induced by the Moderna vaccine, was made. The initial treatment regimen was based on the patient's preference to avoid any risk of immunosuppression. Acitretin 25 mg twice daily was initiated, and the triamcinolone wet wraps were continued. In addition, based on several case reports of its successful treatment of PRP, apremilast was initiated and slowly titrated to 30 mg twice daily. Over the following weeks, the

From the Department of Dermatology, Medical College of Georgia, Augusta University, Augusta.

Funding sources: None.

IRB approval status: Not applicable.

Correspondence to: Etsubdenk M. Ajebo, MD, Department of Dermatology, Medical College of Georgia, Augusta University, 1004 Chafee Avenue, Augusta, GA 30904. E-mail: eajebo@augusta.edu.

JAAD Case Reports 2022;23:114-6.
2352-5126

© 2022 by the American Academy of Dermatology, Inc. Published by Elsevier, Inc. This is an open access article under the CC BY-NC-ND license (<http://creativecommons.org/licenses/by-nc-nd/4.0/>).

<https://doi.org/10.1016/j.jidcr.2022.03.013>

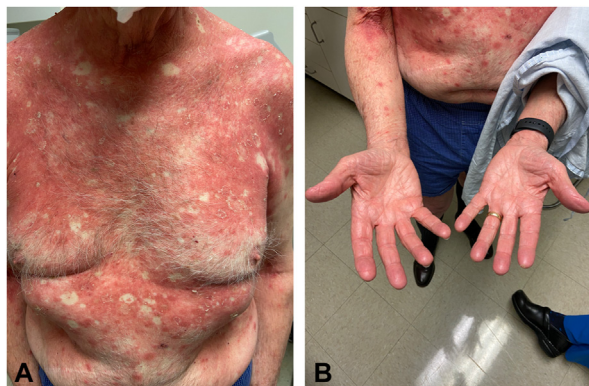


Fig 1. Cutaneous lesions on initial presentation. **A**, Erythematous, scaly plaques with islands of sparing involving the neck, trunk, and proximal upper extremities. **B**, Slightly shiny erythema covering the bilateral palms and fingers.

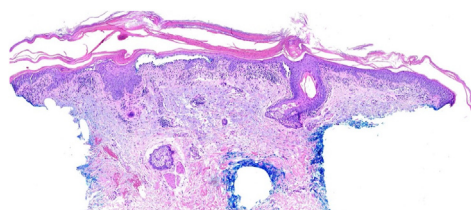


Fig 2. Initial histopathology demonstrating hyperkeratosis, follicular plugging, foci of intraepidermal acantholysis, and superficial perivascular and focal band-like lymphocytic infiltrate. (Hematoxylin-eosin stain; original magnification: 40 \times .)

patient's condition progressed, with the generalized involvement of the trunk and extremities and the evolution of waxy keratoderma. At the 1-month follow-up, the upper body erythema and desquamation had improved, but the palms and soles were tender and fissured; the acitretin was decreased to 25 mg daily. Over the ensuing month, his condition flared (Fig 4, A and B). Despite increasing the acitretin back to 25 mg twice daily, the generalized erythroderma persisted; mild ectropion also ensued. Due to the concern for medication-related depression and persistent disease, the apremilast was discontinued. Ustekinumab 90 mg was initiated, with subsequent dosing at 4 weeks and then every 8 weeks; aggressive dosing was utilized to hasten improvement. At the 12-week follow-up, the generalized scaling and the lower trunk had improved; at the 26-week follow-up, marked but incomplete improvement was noted.

DISCUSSION

PRP is a rare papulosquamous inflammatory dermatosis of unclear etiology. Clinical findings of

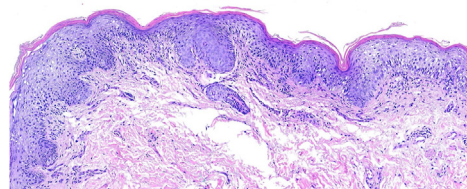


Fig 3. Repeat histopathology demonstrating alternating orthokeratosis and parakeratosis, acanthosis with broad rete ridges, mild spongiosis, and a minimal inflammatory response. (Hematoxylin-eosin stain; original magnification: 100 \times .)

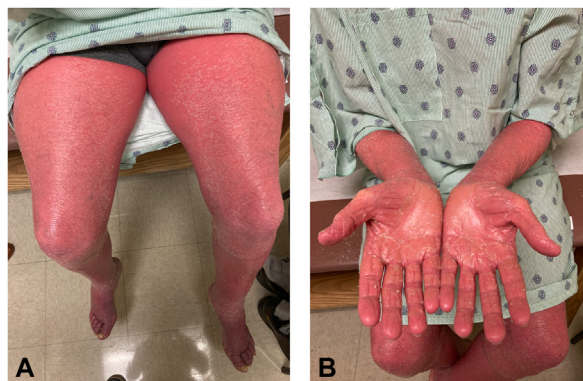

Fig 4. Lesions 14 weeks after initial presentation. **A**, Erythroderma and scaling progressed to involve the entire lower extremities. **B**, Painful fissures developed over a diffuse waxy keratoderma.

the classic variant include follicular papules with an erythematous base, the coalescence of orange-red plaques, islands of sparing, and, in many cases, subsequent erythroderma.² As seen in our patient, cephalocaudal spread, waxy palmoplantar keratoderma, and ectropion are additional characteristic features.²

The histologic findings of PRP include irregular epidermal acanthosis, alternating vertical and horizontal orthokeratosis and parakeratosis, follicular plugging with adjacent parakeratosis, and sparse, superficial, perivascular, lymphohistiocytic dermal infiltrate.³ While not routinely listed as a classic finding, acantholysis, as seen in this case, is well described.^{3,4} Ko et al⁴ reported 8 of 24 cases of PRP demonstrating acantholysis; the authors concluded that in the context of a papulosquamous clinical presentation, acantholysis should raise concern for PRP. Likewise, while the inflammatory infiltrate of PRP is often nonspecific, lichenoid infiltrates, as seen in this case, should not exclude the diagnosis.⁴

PRP often presents sporadically but can follow an acute illness or be medication induced.⁵ Rare case reports implicate vaccines as a trigger. Two reported

cases involved adult women, ages 32 and 47, who developed PRP 10 days after receiving the diphtheria, tetanus, and pertussis vaccination and 18 days after the anti-influenza vaccination, respectively. Two other cases involved infants, ages 19 months and 17 months, who developed PRP 2 weeks after diphtheria, tetanus, and pertussis and poliovirus vaccinations and 2 weeks after the measles, mumps, and rubella vaccination, respectively.⁵ Relevant to the current case, 2 cases have been reported following vaccination for COVID-19 with ChAdOx1 nCoV-19 vaccines. Specifically, a 72-year-old man developed PRP 3 weeks after the initial Covishield vaccination, and a 63-year-old woman developed PRP 9 days after the initial Vaxzevria vaccination. Manufactured by different companies, Covishield and Vaxzevria are identical recombinant vaccines that utilize an adenoviral vector that expresses the SARS-CoV-2 spike proteins.^{6,7} Compared to our case, the 72-year-old man with PRP responded to high-potency topical corticosteroids, and the PRP did not recur following the second Covishield vaccination.⁶ The 63-year-old woman was treated with acitretin, without the mention of a second vaccine dose or response to therapy.⁷ Notably, our patient's skin eruption arose days after receiving his first Moderna vaccine, worsened dramatically after his second dose, and persists, albeit improved with therapy, 1 year later.

In summary, many cutaneous reactions to COVID-19 vaccination have been reported. The temporal relationship between vaccination and the onset of classic PRP in the current case implicates the Moderna vaccine as the potential etiologic trigger. This case and the recently reported cases of PRP following Covishield and Vaxzevria vaccinations

reinforce the observation that vaccinations, including COVID-19 vaccinations, are potential triggers of PRP. An accurate vaccination history in a patient presenting with findings of PRP should be obtained, and the potential risk for flaring or recurrent skin disease should be discussed prior to subsequent vaccinations.

Conflicts of interest

None disclosed.

REFERENCES

1. McMahon DE, Amerson E, Rosenbach M, et al. Cutaneous reactions reported after Moderna and Pfizer COVID-19 vaccination: a registry-based study of 414 cases. *J Am Acad Dermatol*. 2021;85(1):46-55. <https://doi.org/10.1016/j.jaad.2021.03.092>
2. Roenneberg S, Biedermann T. Pityriasis rubra pilaris: algorithms for diagnosis and treatment. *J Eur Acad Dermatol Venereol*. 2018;32(6):889-898. <https://doi.org/10.1111/jdv.14761>
3. Wang D, Chong VCL, Chong SWS, Oon HH. A review on Pityriasis rubra pilaris. *Am J Clin Dermatol*. 2018;19(3):377-390. <https://doi.org/10.1007/s40257-017-0338-1>
4. Ko CJ, Milstone LM, Choi J, McNiff JM. Pityriasis rubra pilaris: the clinical context of acantholysis and other histologic features. *Int J Dermatol*. 2011;50(12):1480-1485. <https://doi.org/10.1111/j.1365-4632.2011.04990.x>
5. Mohamed M, Belhadjali H, Hammedi F, Meriem CB, Zili J. Pityriasis rubra pilaris occurring after vaccination with diphtheria-pertussis-tetanus and oral poliovirus vaccines. *Ind J Dermatol Venereol Leprol*. 2015;81(6):618-620. <https://doi.org/10.4103/0378-6323.168326>
6. Sahni MK, Roy K, Asati DP, Khurana U. An old entity, a new trigger: post COVID-19 vaccine Pityriasis rubra pilaris. *Int J Risk Saf Med*. 2021;32(4):261-264. <https://doi.org/10.3233/JRS-210048>
7. Lladó I, Butrón B, Sampedro-Ruiz R, Fraga J, de Argila D. Pityriasis rubra pilaris after Vaxzevria® COVID-19 vaccine. *J Eur Acad Dermatol Venereol*. 2021;35(12):e833-e835. <https://doi.org/10.1111/jdv.17542>