

Per-oral cholangioscopy in patients with primary sclerosing cholangitis: a 12-month follow-up study



Authors

Rachid Mohamed¹, Sooraj Tejaswi², Lars Aabakken³, Cyriel Y Ponsioen⁴, Christopher L Bowlus², Douglas G Adler⁵, Nauzer Forbes¹, Vemund Paulsen³, Rogier P. Voermans⁴, Shiro Urayama², Joyce Peetermans⁶, Matthew J Rousseau⁶, Bertus Eksteen⁷

Institutions

- 1 Gastroenterology and Hepatology, University of Calgary, Calgary, Canada
- 2 Division of Gastroenterology & Hepatology, University of California Davis School of Medicine, Sacramento, United States
- 3 Dept of Transplantation Medicine, Oslo University Hospital, University of Oslo, Oslo, Norway
- 4 Gastroenterology and Hepatology, Amsterdam University Medical Centres, Amsterdam, Netherlands
- 5 Center for Advanced Therapeutic Endoscopy, Adventist Porter Hospital, Denver, United States
- 6 Gastroenterology and Hepatology, University of Calgary, Calgary, Canada
- 7 Clinical Endoscopy, Boston Scientific Corporation, Marlborough, United States
- 8 Gastroenterology, Aspen Woods Clinic, Calgary, Canada

Key words

Cholangioscopy, Pancreatobiliary (ERCP/PTCD), Diagnostic ERC, Endoscopy Upper GI Tract, Malignant strictures

received 6.9.2023

accepted after revision 22.12.2023

accepted manuscript online 02.01.2024

Bibliography

Endosc Int Open 2024; 12: E237–E244

DOI 10.1055/a-2236-7557

ISSN 2364-3722

© 2024. The Author(s).

This is an open access article published by Thieme under the terms of the Creative Commons Attribution-NonDerivative-NonCommercial License, permitting copying and reproduction so long as the original work is given appropriate credit. Contents may not be used for commercial purposes, or adapted, remixed, transformed or built upon. (<https://creativecommons.org/licenses/by-nc-nd/4.0/>)

Georg Thieme Verlag KG, Rüdigerstraße 14,
70469 Stuttgart, Germany

Corresponding author

Dr. Rachid Mohamed, University of Calgary,
Gastroenterology and Hepatology, 3500 26 Avenue NE,
T1Y 6J4 Calgary, Canada
rmmohame@ucalgary.ca

Supplementary Material is available at
<https://doi.org/10.1055/a-2236-7557>

ABSTRACT

Background and study aims Patients with primary sclerosing cholangitis (PSC) have a 9% to 20% lifetime incidence of cholangiocarcinoma (CCA). Per-oral cholangioscopy (POCS) added to endoscopic retrograde cholangiography (ERC) could potentially improve detection of CCA occurrence. We prospectively assessed POCS identification of 12-month CCA incidence in PSC patients undergoing ERC.

Patients and methods Consecutive patients with PSC, an indication for ERC, and no prior liver transplantation were enrolled. During the index procedure, POCS preceded planned therapeutic maneuvers. The primary endpoint was ability for POCS visualization with POCS-guided biopsy to identify CCA during 12-month follow-up. Secondary endpoints included ability of ERC/cytology to identify CCA, repeat ERC, liver transplantation, and serious adverse events (SAEs).

Results Of 42 patients enrolled, 36 with successful cholangioscope advancement were analyzed. Patients had a mean age 43.5±15.6 years and 61% were male. Three patients diagnosed with CCA had POCS visualization impressions of benign/suspicious/suspicious, and respective POCS-guided biopsy findings of suspicious/positive/suspicious for malignancy at the index procedure. The three CCA cases had ERC visualization impressions of benign/benign/suspicious, and respective cytology findings of atypical/atypical/suspicious for malignancy. No additional patients were diagnosed with CCA during median 11.5-month follow-up. Twenty-three repeat ERCs (5 including POCS) were performed in 14 patients. Five patients had liver transplantation, one after CCA diagnosis and four after benign cytology at the index procedure. Three patients (7.1%) had post-ERC pancreatitis. No SAEs were POCS-related.

Conclusions In PSC patients, POCS visualization/biopsy and ERC/cytology each identified three cases of CCA. Some patients had a repeat procedure and none experienced POCS-related SAEs.

Introduction

Primary sclerosing cholangitis (PSC) is a chronic cholestatic liver disease characterized by intrahepatic and/or extrahepatic inflammation, fibrosis, and bile duct injury [1]. Patients with PSC have a lifetime incidence of cholangiocarcinoma (CCA) as high as 9% to 20% [2]. Because 20% to 50% incident CCA is observed within 1 year of PSC diagnosis [3], the American Gastroenterological Association recommends consideration of surveillance for CCA and gallbladder cancer in all adult patients with PSC regardless of disease stage, especially in the first year following initial diagnosis [4, 5].

The majority of CCAs resemble a dominant stricture cholangiographically. One should be aware that in about 5% of possible dominant strictures, high-grade dysplasia or cholangiocarcinoma is present [6, 7]. When a symptomatic possible dominant stricture is encountered, the recommended next step is endoscopic retrograde cholangiography (ERC) to dilate (stent as needed) and obtain cytology brushings to evaluate for CCA [7]. ERC with brush cytology or biopsy is the most commonly used technique to differentiate benign from malignant strictures, but this method is hindered by low diagnostic yield in patients with PSC [1, 8]. Fluorescence in situ hybridization (FISH) might be considered to confirm malignancy in PSC patients with clinical or laboratory suspicion of CCA (e.g. weight loss, abdominal pain, dominant stricture, high CA 19–9), but because of its low sensitivity, FISH is not appropriate as a screening test in unselected patients [9, 10, 11].

The addition of per-oral cholangioscopy (POCS) to ERC could potentially improve diagnostic yield and prognostication of progression to CCA via direct visualization of the bile duct lumen and targeted tissue acquisition, but POCS indications and effectiveness in patients with PSC are not well established [12, 13]. Extra information obtained during cholangioscopy may not necessarily improve the diagnostic yield of ERC alone. For example, a study of 30 PSC patients found that the addition of high-resolution per-oral video cholangioscopy with narrow-band imaging led to an increased sampling rate but did not increase detection of dysplasia compared with ERC alone [14]. The current study aimed to assess the ability of POCS and POCS-guided biopsy to detect 12-month CCA incidence in patients with PSC and an indication for ERC.

Patients and methods

Study design

We conducted a prospective, international, multicenter consecutive case series at seven sites in four countries (Canada, Netherlands, Norway, United States) evaluating the added clinical benefit of POCS in adult patients with PSC scheduled for ERC (ClinicalTrials.gov number, NCT03766035). Study enrollment began in December 2018 and ended in December 2021. Devices used in the study were SpyGlass DS Direct Visualization System including: SpyScope DS or SpyScope DS II and SpyGlass Digital Controller, SpyBite or SpyBite Max Biopsy Forceps (Boston Scientific, Marlborough, Massachusetts, United States).

Patient population

Inclusion criteria were: 1) age 18 years or older; 2) confirmed diagnosis of PSC; 3) clinical indication for ERC; and 4) diameter of bile ducts deemed sufficient to accommodate cholangioscopy system based on preprocedural imaging. Exclusion criteria were: 1) contraindication to ERC or POCS; 2) history of liver transplantation; 3) mass/metastasis extrinsic to the bile duct identifiable on diagnostic imaging; 4) history of iatrogenic bile duct trauma; 5) international normalized ratio > 1.5 or platelets count < 50,000; and 6) pregnant or trying to become pregnant. Subjects with biliary/pancreatic stents within 3 months of the index procedure could be included. All centers obtained approval from their respective local ethics committees or institutional review boards, and all patients provided signed informed consent before the procedure.

Index procedure and follow-up

POCS visualization and POCS-guided biopsy

Before ERC-guided sampling was performed, patients underwent POCS for visualization of any stricture of interest and POCS-guided biopsy per investigator discretion. POCS results were recorded prior to manipulation of the stricture such as dilation, cytology, and biopsy. POCS visual impression was classified as 1) **normal** (including fibrotic, inflammatory or other changes) or 2) **suspicious for malignancy or malignant** based on macroscopic features of strictures, including but not limited to presence of dysplasia, asymmetric fibrotic lesion(s), pathologic vessels indicating neovascularization, and mucosal irregularities. Visual impression categories were determined by each investigator for his/her own cases; there was no central adjudication of these decisions.

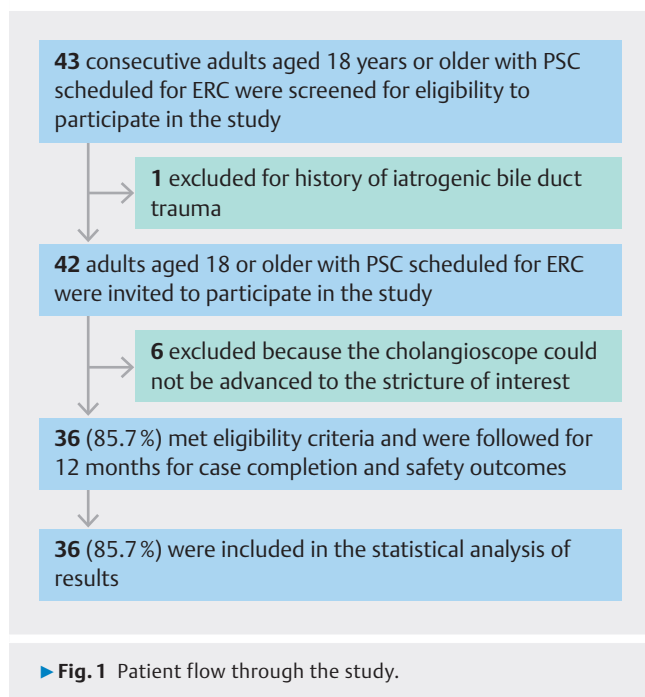
ERC and fluoroscopy-guided brushing samples

Fluoroscopy-guided brushing samples during ERC were performed with a guidewire-guided brush. Cells from the brush tip and the fluid flushed from the catheter with ethanol/saline were added to a 50% ethanol container for cytological processing. A small cell sample (20–100 cells) could be analyzed for aneuploidy characteristic of CCA using FISH if performed per standard of practice. Radiologic assessment was performed as needed based on ERC and brush cytology.

Participants had telephone follow-up at 24 hours and 30 days after the index procedure, 6-month follow-up by phone or in clinic, and a 12-month in-person clinic visit including assessment of symptoms or disease progression or referral to oncology treatment, serum laboratory tests or imaging if clinically indicated, assessment of adverse events (AEs), and documentation of all related diagnostic and therapeutic procedures since the most recent follow-up visit.

Primary endpoint

The primary endpoint was ability of POCS visualization with POCS-guided biopsy to identify CCA during the study period. POCS visual impression was classified as normal, or suspicious for malignancy or malignant (combined category). For CCA,



biopsy findings were classified as: 1) **benign** (including normal, reactive, atypical findings) or 2) **malignant** (including suspicious for malignancy, dysplasia or positive for malignancy).

Secondary endpoints

Secondary endpoints included: 1) ability of ERC visualization and brush cytology to identify CCA; 2) technical success, defined as the ability to visualize the stricture using POCS at the index procedure. Image quality was also rated subjectively as “excellent,” “good,” “fair,” or “poor”; 3) repeat ERC with or without POCS; 4) liver transplantation; and 5) serious AEs (SAEs), with seriousness and relatedness to the POCS or ERC procedure judged by the treating physician.

Statistical analysis

A priori sample size calculations based on a meta-analysis of 17 prior studies [15, 16, 17, 18, 19, 20, 21, 22, 23, 24, 25, 26, 27, 28, 29, 30, 31] of endoscopic retrograde cholangiopancreatography (ERCP) to detect cholangiocarcinoma estimated that 105 patients (assuming 10% attrition) would be required for 80% power with a one-sided alpha of 0.05 to detect diagnostic accuracy $\geq 90\%$ for POCS added to ERCP.

Baseline characteristics, medical history, outcome measures, and AEs were summarized using mean, median, standard deviation (SD), and range for continuous variables (e.g. age, procedure times), and proportions for categorical variables. All analyses were performed in SAS version 9.4.

Results

Patient and procedure characteristics

Of 43 consecutive patients screened for study eligibility, one was excluded for a history of iatrogenic bile duct trauma

► **Table 1** Baseline characteristics of patients in whom cholangioscope could be advanced (N = 36 patients).

| | Mean \pm SD (range) or % (n/N) |
|--|----------------------------------|
| Age (yr) | 43.5 \pm 15.6 (20.0,78.0) |
| Male | 61.1% (22/36) |
| BMI | 26.2 \pm 5.3 (18.7,44.9) |
| Medical conditions or comorbidities | |
| ▪ Ulcerative colitis | 44.4% (16/36) |
| ▪ Crohn's disease | 33.3% (12/36) |
| ▪ Cholecystectomy | 27.8% (10/36) |
| ▪ Proctocolectomy | 11.1% (4/36) |
| ▪ Anemia | 8.3% (3/36) |
| ▪ Autoimmune hepatitis | 5.6% (2/36) |
| ▪ Cardiovascular disease | 5.6% (2/36) |
| ▪ DVT or blood clotting disease | 5.6% (2/36) |
| ▪ Rheumatoid arthritis | 5.6% (2/36) |
| ▪ Cancer | 2.8% (1/36) |
| ▪ Diabetes - insulin dependent | 2.8% (1/36) |
| ▪ Diabetes - non-insulin dependent | 2.8% (1/36) |
| ▪ Severe allergies | 2.8% (1/36) |
| ▪ Respiratory disease | 2.8% (1/36) |
| ▪ Variceal bleeding | 2.8% (1/36) |
| ▪ Medical condition - other | 55.6% (20/36) |
| ▪ Biliary stent placed in last 3 months | 16.7% (6/36) |
| Indication for ERC | |
| ▪ Worsening symptoms | 55.6% (20/36) |
| ▪ Elevated serum liver enzymes | 47.2% (17/36) |
| ▪ Suspected new stricture based on imaging | 41.7% (15/36) |
| ▪ Suspicion for malignancy | 41.7% (15/36) |
| ▪ Indication for ERC - other | 30.6% (11/36) |

ERC, endoscopic retrograde cholangiography.

(► **Fig. 1**). Among 42 patients enrolled in the study, the cholangioscope could not be advanced to the stricture in six patients; those six patients were included in the analysis of technical success and safety endpoints. The 36 patients in whom the cholangioscope could be advanced into the bile duct were included in the analysis of clinical effectiveness outcomes. Baseline characteristics of the patients are summarized in ► **Table 1**. Because the study was inadequately powered, hypothesis testing of a performance goal was not conducted.

► **Table 2** Index POCS procedure characteristics of patients in whom cholangioscope could be advanced (N = 36 patients).

| POCS procedure characteristic | Mean ± SD (range) or % (n/N) |
|---|------------------------------|
| Quality of POCS image | |
| ▪ Excellent | 77.8% (28/36) |
| ▪ Good | 19.4% (7/36) |
| ▪ Fair | 2.8% (1/36) |
| Antibiotics administered | |
| ▪ Days administered | 6.34 ± 5.32 (1.00, 30.00) |
| Ability to visualize the stricture with cholangioscopy | |
| Location of stricture of interest | |
| ▪ Common hepatic duct | 44.4% (16/36) |
| ▪ Common bile duct | 36.1% (13/36) |
| ▪ Left main hepatic duct | 27.8% (10/36) |
| ▪ Right main hepatic duct | 13.9% (5/36) |
| ▪ No stricture of interest | 8.3% (3/36) |
| Cholangioscopy findings | |
| ▪ Concentric fibrosis | 47.2% (17/36) |
| ▪ Inflammation | 47.2% (17/36) |
| ▪ Mucosal changes-friability | 41.7% (15/36) |
| ▪ Dominant stricture | 36.1% (13/36) |
| ▪ Epithelial sloughing | 36.1% (13/36) |
| ▪ Mucosal irregularities | 36.1% (13/36) |
| ▪ Asymmetric fibrosis areas | 19.4% (7/36) |
| ▪ Suspicion of neovascularization | 11.1% (4/36) |
| ▪ Bleeding | 8.3% (3/36) |
| ▪ Papillary lesion | 8.3% (3/36) |
| ▪ Polypoid lesion | 8.3% (3/36) |
| ▪ Ulceration | 8.3% (3/36) |
| ▪ Erythematous papule | 5.6% (2/36) |
| ▪ Hemorrhagic/Necrotic tissue | 2.8% (1/36) |
| ▪ Other | 11.1% (4/36) |
| ▪ None | 5.6% (2/36) |
| Endoscopist impression based on cholangioscopy | |
| ▪ Normal or fibrotic/inflammatory changes or benign | 86.1% (31/36) |
| ▪ Suspicious for malignancy or malignant | 13.9% (5/36) |
| Maneuvers performed during POCS procedure | |
| ▪ Selective guidewire placement | 66.7% (24/36) |

► **Table 2** (Continuation)

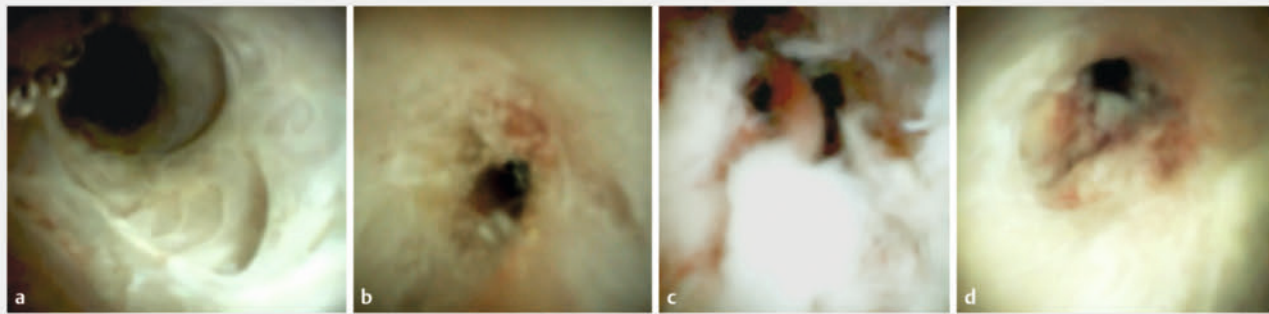
| POCS procedure characteristic | Mean ± SD (range) or % (n/N) |
|--------------------------------|------------------------------|
| ▪ Sphincterotomy | 25.0% (9/36) |
| ▪ Dilation | 13.9% (5/36) |
| ▪ Biliary stent placed | 11.1% (4/36) |
| ▪ Removal of cast/debris/stone | 11.1% (4/36) |
| ▪ Pre-cut sphincterotomy | 5.6% (2/36) |
| ▪ Sphincteroplasty | 2.8% (1/36) |
| ▪ None | 19.4% (7/36) |
| POCS per-oral cholangioscopy | |

POCS-guided biopsy results

Tissue was obtained using SpyBite in 33 of 36 patients. A mean of 3.0 biopsy samples (range 1.0 to 10.0) were taken per patient, most commonly from the common hepatic duct (37.1%, 26/70), common bile duct (25.7%, 18/70) and left (15.7%, 11/70) and right (11.4%, 8/70) main hepatic duct. Thirty samples (43.5% of 69) were at the level of the stricture, while 39 samples (56.5% of 69) were not at the stricture but were taken from a ductal location of sufficient concern to warrant biopsy. Among the 30 patients with adequate POCS-guided biopsy results, one or more of the following histological findings were reported: inflammation or reactive changes (19), fibrous change (7), nuclear atypia (5), ulceration (3), nuclear polymorphism (3), granulation tissue (2), nuclear crowding (1), atypical nucleoli (1), intestinal metaplasia (1), many neutrophils, lymphocytes and histiocytes (1).

Primary endpoint: POCS visualization and ability to identify CCA

POCS visual findings were judged to be normal, fibrotic/inflammatory or benign changes in 31 patients (86.1% of 36), or suspicious for malignancy or malignant in five (13.9%) patients (► **Table 2**, ► **Fig. 2**). Among the five reported visual findings of “suspicious for malignancy or malignant” at the index procedure, three patients were diagnosed with CCA. Among the three CCA cases, one patient had a benign POCS visualization impression (POCS findings: concentric fibrosis, inflammation, dominant stricture, papillary lesion) with a suspicious POCS-guided biopsy diagnosis; the second had a suspicious POCS visualization impression (POCS findings: dominant stricture, papillary lesion, ulceration) with a CCA-positive POCS-guided biopsy diagnosis; and the third had a suspicious POCS visualization impression (POCS findings: concentric fibrosis, inflammation, mucosal irregularities, papillary lesion) with a suspicious POCS-guided biopsy diagnosis (► **Table 3**). No additional patients were diagnosed with CCA within a median follow-up of 11.5 months (range 4.1–13.7).



► **Fig. 2** a, b Biliary strictures identified as benign and c, d suspicious for malignancy or malignant using per-oral cholangioscopy (POCS) in patients with PSC.

► **Table 3** POCS with biopsy versus ERC with brush cytology for three cases of cholangiocarcinoma identified at the index procedure.

| Cholangiocarcinoma case identified at index procedure | POCS visual impression | POCS biopsy result | ERC visual impression | Brush cytology result |
|---|---|---------------------------|---|---------------------------|
| CCA 1 | Normal or fibrotic/inflammatory changes or benign | Suspicious for malignancy | Normal or fibrotic/inflammatory changes or benign | Atypical |
| CCA 2 | Suspicious for malignancy or malignant | Positive for malignancy | Normal or fibrotic/inflammatory changes or benign | Atypical |
| CCA 3 | Suspicious for malignancy or malignant | Suspicious for malignancy | Suspicious for malignancy or malignant | Suspicious for malignancy |

POCS per-oral cholangioscopy; ERC endoscopic retrograde cholangiography; CCA, cholangiocarcinoma.

Ability of ERC visualization and brush cytology to identify CCA

ERC visualization findings were judged to be normal, fibrotic/inflammatory or benign changes in 35 patients (97.2% of 36), or suspicious for malignancy or malignant in one patient (2.8%) (**Appendix**). Brush cytology showed six patients with atypical findings (2 of whom were diagnosed with CCA), and one patient with findings suspicious for malignancy (diagnosed with CCA).

Technical success

Technical success (ability to visualize the stricture of interest with POCS) was achieved in 35 patients (83.3% of 42). Thirty-three of those patients had a POCS-guided biopsy, of whom 30 had specimens adequate for histology. The three patients without a POCS-guided biopsy adequate for histology had cytology results negative for CCA.

Among the seven patients without technical success, the cholangioscope could not be advanced into the stricture in six patients because the duct was of a narrow caliber and fibrotic nature that did not permit the safe and complete advancement of the cholangioscope. These strictures were located in the right intrahepatic duct, mid-to-distal common bile duct, distal common bile duct, common bile duct, common hepatic duct, or left main hepatic duct based on imaging. In one other pa-

tient, the stricture of interest could not be visualized with POCS.

Repeat ERC with or without POCS

After the index procedure, 14 patients had 23 repeat ERCs, five of which included POCS procedures. The maneuvers (one or more per patient) performed during the repeat ERCs included selective guidewire placement (15), dilation (13), removal of cast/debris/stone (6), biliary stent placement (4), stent removal (3, one of which was followed by balloon dilation), sphincterotomy (1), and sphincteroplasty (1). POCS-guided biopsy samples were taken during four of the five repeat POCS procedures; all of these samples were negative for CCA.

Liver transplantation

Five patients (13.9%) underwent liver transplantation, one 131 days after CCA diagnosis at the index procedure, and four at 103, 299, 317, and 338 days after benign POCS cytology findings at the index procedure. The four patients with benign POCS cytology underwent liver transplantation associated with progressive or end-stage liver disease (3) or PSC disease progression and cholangitis (1).

Adverse events

No SAEs were reported to be associated with POCS. Overall, there were 11 SAEs experienced by nine patients who had cholangioscopy. Three patients (7.11% of 42) had post-ERC pancreatitis (► **Table 4**). All other SAEs occurred 14 days or more after the index procedure, including three cases of cholangitis on days 49, 102, and 289 after the index procedure. Five patients underwent liver transplantation during the study period. Three had progressive liver disease, one had progression of PSC, and one had progression of CCA. No SAEs were reported in the patients in whom the cholangioscope could not be advanced. No patients died during the study.

Discussion

POCS visualization plus POCS-guided biopsy identified three CCA cases in PSC patients undergoing ERC. No incident cases of CCA were identified during 12-month follow-up.

The most common indication for endoscopic intervention in patients with PSC is dominant strictures, estimated to be prevalent in 36% to 57% of patients [12, 32] and associated with increased risk of CCA and reduced survival [33]. POCS may theoretically have a useful role in the diagnosis of CCA in a dominant stricture, or in ruling out CCA because the majority of dominant strictures do not harbor malignancy [7]. In addition, POCS could potentially improve PSC treatment by clarifying the status of biliary inflammation and stenosis [34]. We acknowledge that POCS visualization missed one of three cases of CCA in our study, while all three CCA cases were diagnosed on both POCS-guided biopsy and cytology. Thus, in this study, the addition of POCS did not improve detection of CCA compared with ERC and fluoroscopy-guided brushings alone, and our preliminary findings do not support routine use of the combined techniques. However, because POCS was safe and has potential for im-

proved diagnosis in larger studies, further research is warranted.

We acknowledge strengths and limitations of this study. The prospective study design with a sample size of 42 and 1-year follow-up was notable among the mostly small retrospective or cross-sectional studies of POCS in PSC patients currently published. Regarding limitations, due to low recruitment, the study was inadequately powered for estimating diagnostic accuracy as originally planned. Six of the 42 patients had to be excluded from the analysis due to impassable strictures, and POCS-guided data biopsies were taken at the endoscopist's discretion; therefore, we could not estimate the diagnostic accuracy of POCS for the entire study population in an unbiased manner. Because the intervention was performed by expert endoscopists at high-volume medical centers, results may not be generalizable to all centers where patients with PSC receive care. For example, the study might have included patients diagnosed with dysplasia or CCA on a recent ERCP, but we do not have baseline data on this factor. Because of its diameter, cholangioscopic observations are likely to be challenging for lesions in the deeper intrahepatic ducts.

Conclusions

In conclusion, POCS-guided biopsy identified three of three CCA cases, and POCS visualization identified two of three CCA cases in patients with PSC, with some patients receiving a repeat procedure. No POCS-related SAEs occurred. Future larger longitudinal studies of the benefits and risks of POCS in this patient population should be considered.

Acknowledgement

The authors acknowledge Boston Scientific employee Margaret Gourlay, MD, MPH for assistance in preparation of the manuscript.

Conflict of Interest

Rachid Mounir Mohamed: none. Sooraj Tejaswi: none. Lars Aabakken: Olympus – training, once-a-year advisory, clinical trial participation; Ambu – advisory board; Boston Scientific – clinical trial participation. Cyriel Ponsioen: research grants from Gilead and Perspectum, speaker's fee from Tillotts, and advisory board fees from Shire. Christopher L. Bowlus: grants or contracts and consulting fees from Cymabay, GSK, Eli Lilly; grants or contracts from Gilead, BMS, Intercept, Hanmi, TARGET, Pliant, Genfit, Novartis, Takeda, Arena Pharmaceuticals, Calliditas; consulting fees from BiomX, Trevi Therapeutics, Shire, Mirum. Douglas Adler: research funding from Boston Scientific. Nauzer Forbes: Boston Scientific – consultant and speaker's bureau; Pentax Medical – research funding, consultant and speaker's bureau; Astra-Zeneca – consultant. Vemund Paulsen: lecture fee from Boston Scientific. Rogier Voermans: research grants from Boston Scientific and Prion Medical, speaker's fees from Viatrix, Zambon and Boston Scientific. Shiro Urayama: consultant for Olympus. Joyce A. Peetermans: full-time employee of Boston Scientific. Matthew J. Rousseau: full-time employee of Boston Scientific. Bertus Eksteen: Pliant – scientific board; consulting for Jansen, Pfizer, Abbvie.

► **Table 4** Serious adverse events.

| | Number of SAEs | Percent of patients (n/N) |
|---------------------------------|----------------|---------------------------|
| Any serious adverse event | 11 | 21.4% (9/42) |
| Cholangitis* | 3 | 7.1% (3/42) |
| Post-ERC pancreatitis | 3 | 7.1% (3/42) |
| Cholangiocarcinoma progression* | 1 | 2.4% (1/42) |
| Urinary tract infection† | 1 | 2.4% (1/42) |
| Hemobilia† | 1 | 2.4% (1/42) |
| End-stage liver disease* | 1 | 2.4% (1/42) |
| Progressive liver failure* | 1 | 2.4% (1/42) |

*In each of these categories, one patient had a liver transplant by the end of study follow-up. The patient with cholangiocarcinoma progression was diagnosed with cholangiocarcinoma on POCS-guided biopsy and cytology during the study.

†The patient with cholangitis who had a liver transplant also had a urinary tract infection and hemobilia.

SAE, serious adverse event; ERC, endoscopic retrograde cholangiography.

Funding Information

Boston Scientific Corporation <http://dx.doi.org/10.13039/100008497>

Clinical trial

ClinicalTrials.gov (<http://www.clinicaltrials.gov/>)
Registration number (trial ID): NCT03766035
Type of Study: Prospective, multicenter cohort study

References

- [1] Dyson JK, Beuers U, Jones DEJ et al. Primary sclerosing cholangitis. *Lancet* 2018; 391: 2547–2559 doi:10.1016/S0140-6736(18)30300-3
- [2] Song J, Li Y, Bowlus CL et al. Cholangiocarcinoma in patients with primary sclerosing cholangitis (PSC): a comprehensive review. *Clin Rev Allergy Immunol* 2020; 58: 134–149
- [3] Barkin JA, Levy C, Souto EO. Endoscopic management of primary sclerosing cholangitis. *Ann Hepatol* 2017; 16: 842–850 doi:10.5604/01.3001.0010.5274
- [4] Bowlus CL, Lim JK, Lindor KD. AGA Clinical Practice Update on Surveillance for Hepatobiliary Cancers in Patients With Primary Sclerosing Cholangitis: Expert Review. *Clin Gastroenterol Hepatol* 2019; 17: 2416–2422 doi:10.1016/j.cgh.2019.07.011
- [5] Bowlus CL, Arrive L, Bergquist A et al. AASLD practice guidance on primary sclerosing cholangitis and cholangiocarcinoma. *Hepatology* 2023; 77: 659–702 doi:10.1002/hep.32771
- [6] Ponsioen CY, Assis DN, Boberg KM et al. Defining primary sclerosing cholangitis: results from an international primary sclerosing cholangitis study group consensus process. *Gastroenterology* 2021; 161: 1764–1775
- [7] Aabakken L, Karlsen TH, Albert J et al. Role of endoscopy in primary sclerosing cholangitis: European Society of Gastrointestinal Endoscopy (ESGE) and European Association for the Study of the Liver (EASL) Clinical Guideline. *Endoscopy* 2017; 49: 588–608 doi:10.1055/s-0043-107029
- [8] Tejaswi S, Olson KA, Loehfelme TW. Cholangioscopy in primary sclerosing cholangitis: a case series of dominant strictures and cholangiocarcinoma. *VideoGIE* 2021; 6: 277–281 doi:10.1016/j.vgie.2021.01.009
- [9] Bangarulingam SY, Bjornsson E, Enders F et al. Long-term outcomes of positive fluorescence in situ hybridization tests in primary sclerosing cholangitis. *Hepatology* 2010; 51: 174–180 doi:10.1002/hep.23277
- [10] Navaneethan U, Njei B, Venkatesh PG et al. Fluorescence in situ hybridization for diagnosis of cholangiocarcinoma in primary sclerosing cholangitis: a systematic review and meta-analysis. *Gastrointest Endosc* 2014; 79: 943–950 doi:10.1016/j.gie.2013.11.001
- [11] Kaura K, Sawas T, Bazerbach F et al. Cholangioscopy biopsies improve detection of cholangiocarcinoma when combined with cytology and FISH, but not in patients with PSC. *Dig Dis Sci* 2020; 65: 1471–1478
- [12] Fung BM, Fejleh MP, Tejaswi S et al. Cholangioscopy and its Role in Primary Sclerosing Cholangitis. *Eur Med J Hepatol* 2020; 8: 42–53
- [13] Liu R, Cox Rn K, Siddiqui A et al. Peroral cholangioscopy facilitates targeted tissue acquisition in patients with suspected cholangiocarcinoma. *Minerva Gastroenterol Dietol* 2014; 60: 127–133
- [14] Azeem N, Gostout CJ, Knipschild M et al. Cholangioscopy with narrow-band imaging in patients with primary sclerosing cholangitis undergoing ERCP. *Gastrointest Endosc* 2014; 79: 773–779
- [15] Charatcharoenwithaya P, Enders FB, Halling KC et al. Utility of serum tumor markers, imaging, and biliary cytology for detecting cholangiocarcinoma in primary sclerosing cholangitis. *Hepatology* 2008; 48: 1106–1117 doi:10.1002/hep.22441
- [16] Forbes N, Mohamed R, Heitman S et al. Tu1534 Detection of cholangiocarcinoma in patients with primary sclerosing cholangitis using single-operator cholangioscopy: a prospective evaluation and cost analysis. *Gastrointestinal Endoscopy* 2016; 83: AB598–AB599
- [17] Nanda A, Brown JM, Berger SH et al. Triple modality testing by endoscopic retrograde cholangiopancreatography for the diagnosis of cholangiocarcinoma. *Therap Adv Gastroenterol* 2015; 8: 56–65 doi:10.1177/1756283X14564674
- [18] Levy MJ, Baron TH, Clayton AC et al. Prospective evaluation of advanced molecular markers and imaging techniques in patients with indeterminate bile duct strictures. *Am J Gastroenterol* 2008; 103: 1263–1273
- [19] Ponsioen CY, Vrouenraets SM, Prawirodirdjo W et al. Natural history of primary sclerosing cholangitis and prognostic value of cholangiography in a Dutch population. *Gut* 2002; 51: 562–566 doi:10.1136/gut.51.4.562
- [20] Boyd S, Mustonen H, Tenca A et al. Surveillance of primary sclerosing cholangitis with ERC and brush cytology: risk factors for cholangiocarcinoma. *Scand J Gastroenterol* 2017; 52: 242–249
- [21] Tischendorf JJ, Kruger M, Trautwein C et al. Cholangioscopic characterization of dominant bile duct stenoses in patients with primary sclerosing cholangitis. *Endoscopy* 2006; 38: 665–669
- [22] Ponsioen CY, Vrouenraets SM, van Milligen de Wit AW et al. Value of brush cytology for dominant strictures in primary sclerosing cholangitis. *Endoscopy* 1999; 31: 305–309
- [23] Siqueira E, Schoen RE, Silverman W et al. Detecting cholangiocarcinoma in patients with primary sclerosing cholangitis. *Gastrointest Endosc* 2002; 56: 40–47
- [24] Lindberg B, Arnelo U, Bergquist A et al. Diagnosis of biliary strictures in conjunction with endoscopic retrograde cholangiopancreatography, with special reference to patients with primary sclerosing cholangitis. *Endoscopy* 2002; 34: 909–916
- [25] Lal A, Okonkwo A, Schindler S et al. Role of biliary brush cytology in primary sclerosing cholangitis. *Acta Cytol* 2004; 48: 9–12 doi:10.1159/000326276
- [26] Furmanczyk PS, Grieco VS, Agoff SN. Biliary brush cytology and the detection of cholangiocarcinoma in primary sclerosing cholangitis: evaluation of specific cytomorphologic features and CA19–9 levels. *Am J Clin Pathol* 2005; 124: 355–360 doi:10.1309/J030-JYPW-KQTH-CLNJ
- [27] Boberg KM, Jebesen P, Clausen OP et al. Diagnostic benefit of biliary brush cytology in cholangiocarcinoma in primary sclerosing cholangitis. *J Hepatol* 2006; 45: 568–574 doi:10.1016/j.jhep.2006.05.010
- [28] Moff SL, Clark DP, Maitra A et al. Utility of bile duct brushings for the early detection of cholangiocarcinoma in patients with primary sclerosing cholangitis. *J Clin Gastroenterol* 2006; 40: 336–341
- [29] Moreno Luna LE, Kipp B, Halling KC et al. Advanced cytologic techniques for the detection of malignant pancreatobiliary strictures. *Gastroenterology* 2006; 131: 1064–1072
- [30] Halme L, Arola J, Numminen K et al. Biliary dysplasia in patients with primary sclerosing cholangitis: additional value of DNA ploidy. *Liver Int* 2012; 32: 783–789
- [31] Heif M, Yen RD, Shah RJ. ERCP with probe-based confocal laser endomicroscopy for the evaluation of dominant biliary stenoses in primary sclerosing cholangitis patients. *Dig Dis Sci* 2013; 58: 2068–2074 doi:10.1007/s10620-013-2608-y

- [32] Dhaliwal AS, Naga Y, Ramai D et al. A comparison of balloon- versus stent-based approach for dominant strictures in primary sclerosing cholangitis: a meta-analysis. *Ann Gastroenterol* 2022; 35: 307–316 doi:10.20524/aog.2022.0701
- [33] Chapman RW, Williamson KD. Are dominant strictures in primary sclerosing cholangitis a risk factor for cholangiocarcinoma? *Curr Hepatol Rep* 2017; 16: 124–129 doi:10.1007/s11901-017-0341-2
- [34] Fujisawa T, Ushio M, Takahashi S et al. Role of peroral cholangioscopy in the diagnosis of primary sclerosing cholangitis. *Diagnostics (Basel)* 2020; 10: 268 doi:10.3390/diagnostics10050268