

Increased Predisposition of SJS TEN in COVID-19 Patients, Presenting as Post COVID Complication: Report of Two Cases

Abstract

We report two consecutive cases of toxic epidermal necrolysis presented to our emergency department in the past 5 months. Both patients had history of fever prior to the onset of skin manifestations and showed radiological findings suggestive of COVID-19 pneumonia and elevated D dimers. ALDEN score was used to assess the drug causality, which showed probable and possible associations, respectively. In this report, along with brief review of literature, we highlight the possible role of viral etiology, that is SARS-CoV2, in triggering toxic epidermal necrolysis.

Keywords: *Allopurinol, diclofenac, SARS-CoV2, SJS TEN*

**Shayna Aulakh,
Raina Arora,
Rishu Sarangal,
Dimple Chopra**

*Department of Dermatology,
Government Medical College,
Patiala, Punjab, India*

Introduction

Steven Johnson syndrome (SJS) and toxic epidermal necrolysis (TEN) is a life-threatening cutaneous adverse reaction presenting as extensive epidermal detachment of skin and mucous membranes. The etiological factors include drugs, mycoplasma, viruses and immunization.^[1] COVID-19 is caused by severe acute respiratory syndrome coronavirus-2 (SARS-COV2) with many reports of dermatological manifestations including SJS-TEN occurring either during illness or during recovery phase.

Case Report

Case 1

A 48-year-old woman presented in March 2021, with dusky brown macules on trunk along with erythematous atypical targetoid lesions on bilateral limbs. These lesions coalesced and got detached to reveal oozy raw erosions measuring 10*15 cm. She also had hemorrhagic crusting over lips and erosions in buccal and genital mucosae. Eye examination revealed bilateral ankyloblepharon formation which on separation showed conjunctival erythema and purulent discharge [Figure 1]. On enquiring, patient gave history of fever with generalized body aches 10 days prior to onset of skin

lesions for which she took paracetamol and allopurinol for 2 days. She had labored breathing (RR = 24/min) and cough, with extensive mucopurulent exudation from respiratory route. Her SCORTEN was 3 and her ALDEN score was -1 and +4, for paracetamol and allopurinol, respectively. Laboratory data showed leukopenia (TLC = 3000 cells/mm³), hypoproteinemia (TSP=5.2 g/dl), elevated D-Dimer (3.37 g/dl), elevated transaminases (SGOT = 96 IU/L, SGPT = 73 IU/L). Her RTPCR was negative, but chest X-ray revealed haziness in lower zone of bilateral lung fields, causing partial obscuration in bilateral costophrenic angles, suggesting COVID-19.

Case 2

A 60-year-old woman presented in July 2021, with history of fever and sore throat 10 days back for which she took paracetamol and diclofenac for 3 days. Ten days later, she presented with rash and oral erosions. On examination, she had erythematous dusky macules with few erosions, hemorrhagic crusting of lips, erosions in vulval and conjunctival mucosae, along with purulent ophthalmic and ear discharge [Figure 2]. Her systemic examination was normal on day of admission but she developed respiratory distress following 2 days along with livedoid vasculopathy

This is an open access journal, and articles are distributed under the terms of the Creative Commons Attribution-NonCommercial-ShareAlike 4.0 License, which allows others to remix, tweak, and build upon the work non-commercially, as long as appropriate credit is given and the new creations are licensed under the identical terms.

For reprints contact: WKHLRPMedknow_reprints@wolterskluwer.com

How to cite this article: Aulakh S, Arora R, Sarangal R, Chopra D. Increased predisposition of sjs ten in COVID-19 patients, presenting as post COVID complication: Report of two cases. Indian Dermatol Online J 2022;13:237-9.

Received: 09-Aug-2021. **Revised:** 18-Sep-2021.
Accepted: 19-Sep-2021. **Published:** 03-Mar-2022.

Address for correspondence:

*Dr. Rishu Sarangal,
176, Ground Floor, Block A,
Sector 85, Mohali - 140 308,
Punjab, India.
E-mail: sarangalr@gmail.com*

Access this article online

Website: www.idoj.in

DOI: 10.4103/idoj.idoj_510_21

Quick Response Code:



and purpuric lesions on legs, flanks and bilateral breasts [Figure 3]. Her SCORTEN was 3 and ALDEN score was -2 and +1, for paracetamol and diclofenac, respectively. On investigating, she had leucocytosis (TLC = 21000 cells/mm³), hypoproteinemia (TSP = 4.9 g/dl), elevated serum creatinine (3.5 mg/dL), elevated blood urea nitrogen (73.36 mg/dL) and highly

elevated D-dimers (>9990 g/dl). Her RTPCR was negative on admission, but her imaging studies revealed bilateral moderate pleural effusion with consolidation of underlying lung parenchyma, fibrotic changes and tiny ground-glass opacities in bilateral upper lobes, suggestive of COVID pneumonia. [Figure 4].

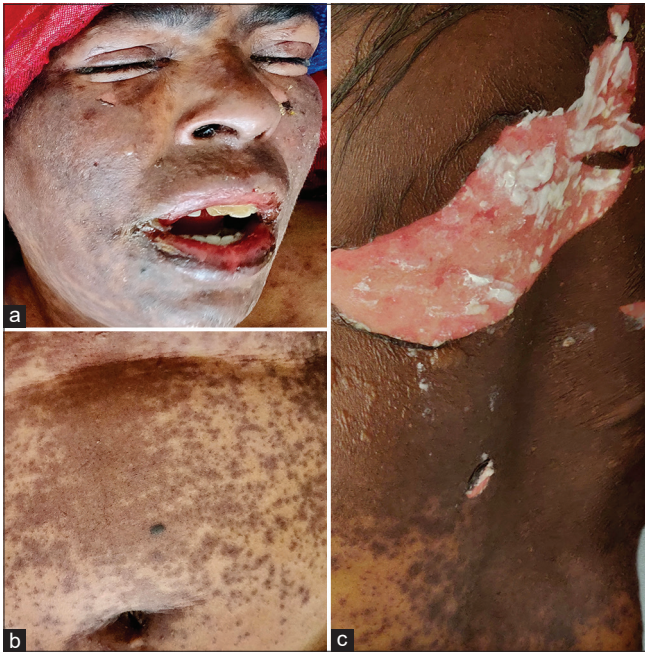

Figure 1: Case 1 clinically presented with (a) Hemorrhagic crusting of lips and bilateral ankyloblepharon, (b) Erythematous targetoid macules, coalescing together on anterior trunk, and (c) sheets of epidermal detachment, revealing raw oozy erosions on posterior trunk

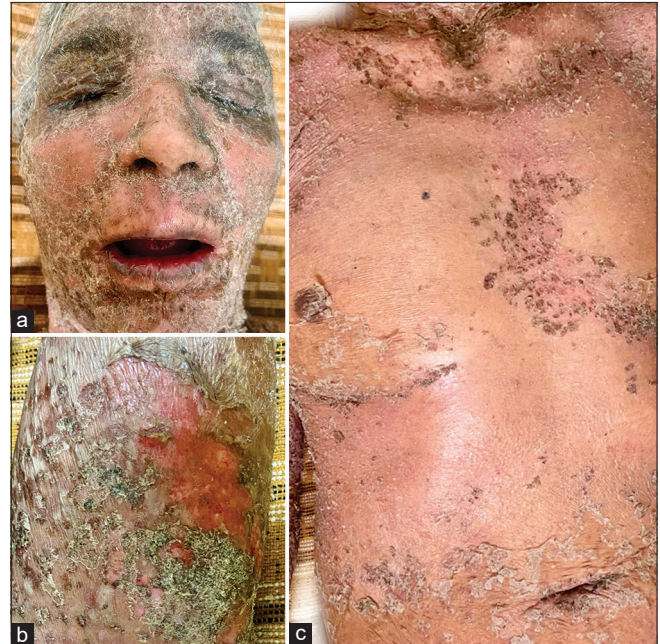

Figure 2: Case 2 on day of admission presented with (a) Oral, conjunctival and nasal erosions, (b) Area of epidermal detachment revealing raw erosion, and (c) Generalized erythema on trunk with superficial scaling

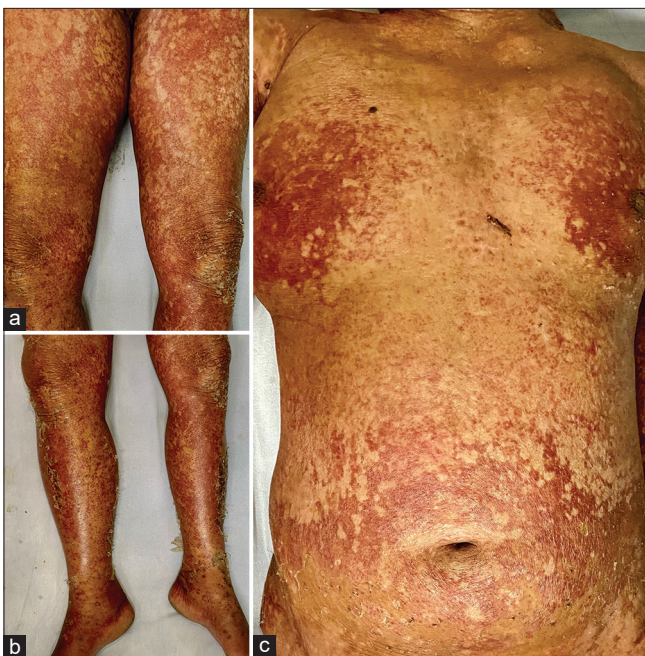


Figure 3: Case 2, two days following admission developed (a) (c) Livedoid rash on bilateral thighs, abdomen and breasts (b) Purpuric rash on bilateral lower limbs

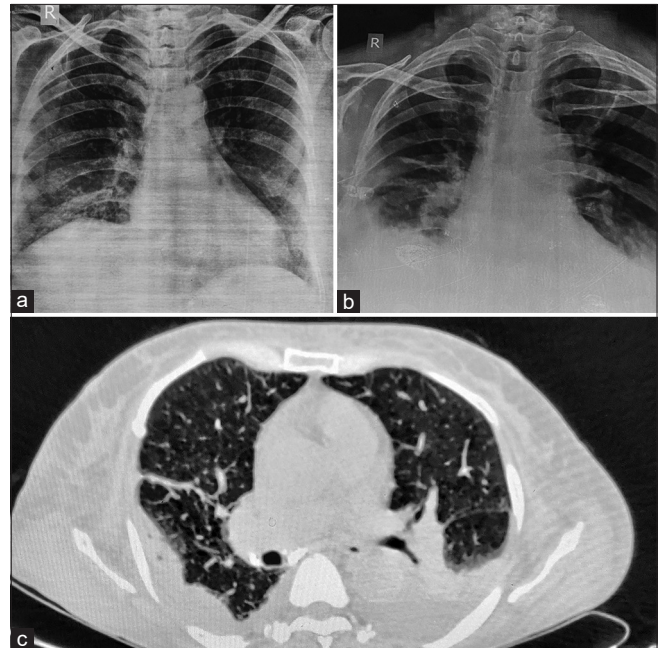


Figure 4: Radiological findings (a) Chest X-ray (Case 1) shows haziness in lower zone of bilateral lung fields and partial obscuration of bilateral costophrenic angles, (b) Chest X-ray (Case 2) shows bilateral opacities in lower zones and pleural effusion, (c) CT Chest* (Case 2) shows bilateral pleural effusion, fibrotic changes and tiny ground glass opacities

Discussion

SJS TEN is severe cutaneous adverse reaction due to delayed hypersensitivity to drugs.^[2] However, drugs are not sole culprits, but concurrent infections have also been implicated.^[3] In one such short case series, an observation linking viral etiology to SJS TEN was proposed in 6 cases.^[4]

The major organ affected in SARS CoV2 is the respiratory system, but it can also affect other organs of body, including skin. Cutaneous manifestations can range from urticarial/maculopapular/morbilliform rash, papulovesicular exanthem, chilblain like acral lesions, livedo-reticularis or racemosa like lesions.^[5] However, there are only few reports linking COVID-19 to SJS TEN.^[6-9]

The first report by Rossi *et al.*^[6] suggested that hydroxychloroquine given in patient suffering from concomitant COVID-19 infection developed SJS TEN due to increased immune reactivation by virus. Pudukadan *et al.*^[7] also reported similar association in a 57-year-old woman who developed TEN, but had not received any drugs prior to the onset of TEN, but was COVID-19 positive.

Also, with the advent of vaccination, TEN is also being reported post-vaccination. Elboraey *et al.*^[8] reported a middle-aged woman developing SJS TEN after 5 days of the second dose of COVID-19 vaccine. A similar report was published by Dash *et al.* of 60-year-old man who developed SJS like lesions post COVID vaccination.^[9]

Similarly, in both our patients, radiological and laboratory findings suggested recent SARS-CoV2 infection. Though the highest ALDEN score of +4 and +1 in each patient suggested probable and possible drug etiology, respectively, but the same was not confirmatory to implicate drugs as the sole culprits for causation of TEN.^[10] Thus, we propose that the possible trigger of TEN is exuberant immune reactivation and plethora of intense cytokine storm, occurring during COVID-19 infection, leading to presentation with TEN in post COVID phase.

Conclusion

SARS-CoV2 is a novel virus with many systemic and cutaneous manifestations being reported. However, it is yet to unfold the mechanism by which such associations are possible and have been implicated in pathogenesis of known diseases such as SJS TEN. Our report adds on to

existing literature that even post-recovery from SARS CoV2, the ongoing immune reactivation can increase the susceptibility of such cutaneous adverse reactions. Though drugs are implicated agents in our cases, a possible viral etiology cannot be entirely overruled.

Declaration of patient consent

Authors confirm that appropriate consent from patients or their guardians was taken.

Financial support and sponsorship

Nil.

Conflicts of interest

There are no conflicts of interest.

References

1. Fournier S, Bastuji-Garin S, Mentec H, Revuz J, Roujeau JC. Toxic epidermal necrolysis associated with Mycoplasma pneumoniae infection. *Eur J Clin Microbiol Infect Dis* 1995;14:558-9.
2. Lerch M, Mainetti C, Terzicoli Beretta-Piccoli B, Harr T. Current perspectives on Stevens-Johnson syndrome and toxic epidermal necrolysis. *Clin Rev Allergy Immunol* 2018;54:147-76.
3. Okamoto-Uchida Y, Nakamura R, Sai K, Imatoh T, Matsunaga K, Aihara M, *et al.* Effect of infectious diseases on the pathogenesis of Stevens-Johnson syndrome and toxic epidermal necrolysis. *Biol Pharm Bull* 2017;40:1576-80.
4. Ban GY, Ahn SJ, Yoo HS, Park HS, Ye YM. Stevens-Johnson syndrome and toxic epidermal necrolysis associated with acetaminophen use during viral infections. *Immune Netw* 2016;16:256-60.
5. Wang CJ, Worswick S. Cutaneous manifestations of COVID-19. *Dermatol Online J* 2021;27:13030/qt2m54r7nv.
6. Rossi CM, Beretta FN, Traverso G, Mancarella S, Zenoni D. A case report of Toxic epidermal necrolysis (TEN) in a patient with COVID-19 treated with hydroxychloroquine: Are these two partners in crime? *Clin Mol Allergy* 2020;18:19.
7. Pudukadan D, John B. Toxic epidermal necrolysis and coronavirus disease 2019: A rare association. *J Skin Sex Transm Dis* doi: 10.25259/JSSTD_37_2021.
8. Elboraey MO, Essa EE. Stevens-Johnson syndrome post second dose of Pfizer COVID-19 vaccine: A case report. *Oral Surg Oral Med Oral Pathol Oral Radiol* 2021;132:e139-42.
9. Dash S, Sirka CS, Mishra S, Viswan P. COVID-19 vaccine-induced Stevens-Johnson syndrome. *Clin Exp Dermatol* 2021;10.1111/ced.14784. doi: 10.1111/ced.14784. Online ahead of print.
10. Sassolas B, Haddad C, Mockenhaupt M, Dunant A, Liss Y, Bork K, *et al.* ALDEN, an algorithm for assessment of drug causality in Stevens-Johnson syndrome and toxic epidermal necrolysis: Comparison with case-control analysis. *Clin Pharmacol Ther* 2010;88:60-8.