

REVIEW

A review of thoracic aortic aneurysm disease

Paul F Clift MD¹ and Elena Cervi MD PhD²

¹Department of Cardiology, University Hospital Birmingham, Birmingham, UK

²Department of Cardiology, Great Ormond St Hospital, London, UK

Correspondence should be addressed to E Cervi: elena.cervi@nhs.net

Abstract

Aortic diseases may be diagnosed after a long period of subclinical development or they may have an acute presentation. Acute aortic syndrome is often the first sign of the disease, which needs rapid diagnosis and decision making to reduce the extremely poor prognosis. Aortic dilatation is a well-recognised risk factor for acute events and can occur as a result of trauma, infection, or, most commonly, from an intrinsic abnormality in the elastin and collagen components of the aortic wall. Over the years it has become clear that a few monogenic syndromes are strongly associated with aneurysms and often dictate a severe presentation in younger patients while the vast majority have a multifactorial pathogenesis. Conventional cardiovascular risk factors and ageing play an important role. Management strategy is based on prevention consisting of regular follow-up with cross-sectional imaging, chemoprophylaxis of further dilatation with drugs proved to slow down the disease progression and preventative surgery when dimension exceeds internationally recognised cut-off values for aortic diameters and the risk of rupture/dissection is therefore deemed very high.

Key Words

- ▶ aortic dilatation
- ▶ aortic aneurysm
- ▶ aortic dissection
- ▶ bicuspid aortic valve
- ▶ inherited aortic disease

Introduction

The finding of a mildly dilated aorta is not uncommon on routine imaging of the heart. Examination of the aortic root, ascending aorta and aortic arch is part of the standard reporting for echocardiographers. This paper reviews aortic disease with specific focus on diagnosis, management and further investigations. It will review the genetic basis of hereditary aortic disease and summarise the presentation and management of acute aortic presentations.

There is no accepted definition for aortic diseases, or aortopathies, and the term is broadly applicable to both inherited and acquired conditions. They include thoracic and abdominal aneurysms and their risk of rupture or dissection. They account for significant cardiovascular morbidity and mortality worldwide. Recent European studies reflect this with incidence of aortic dissection in developed countries of 6 per 100,000 (1).

Aortic aneurysms can develop at any location but the majority happen in the abdominal aorta and more specifically between the renal arteries and the common iliac bifurcation. While the physiopathology has common features with abdominal aneurysm, cardiologists are far more involved in the management of thoracic aortic aneurysms. Therefore, the definition of aortopathy for the purpose of this paper relates to any condition where there is enlargement of the thoracic aorta, which will be the focus of this review.

In the past decades, more consistent surveillance and advances in understanding the genetic background and clinical presentation have been made so that there are now a number of new entities in which the main concern is around vascular dilatation and/or ruptures. It is also known that many congenital heart defects are associated with aortic dilatation, especially cono-truncal

abnormalities, where it is felt a significant hemodynamic role with stretch to the proximal aorta is played by a longstanding right-to-left shunt in utero (i.e. tetralogy of Fallot).

Presentation of aortopathy

Patients with aortopathy present in a number of ways: 1) as an incidental finding as part of a routine examination such as transthoracic echocardiography (TTE), computerised tomography (CT) of the chest, cardiac magnetic resonance imaging (CMR) or on a routine chest radiograph (CXR), 2) as an acute presentation with thoracic aortic dissection 3) as part of cascade screening for a relative of an individual presenting with aortic disease and 4) as part of a recognised congenital cardiac condition.

Echocardiography descriptors used for the aorta will usually include the dimensions of the aorta at the aortic valve annulus, the aortic root, the sino-tubular junction, the ascending aorta, the mid arch and the proximal descending aorta, with aortic valve morphology and function being described and the velocity in the proximal descending aorta given (Table 1).

A comment on flow reversal in the aortic arch will be made for patients with aortic incompetence. The presence of diastolic tailing on continuous wave Doppler (CW) is made if coarctation of the aorta is suspected. TTE will give all of these measurements but the ability to define accurate dimensions and to produce three-dimensional reconstructions of the aorta is best achieved using CT scanning or MRI.

Table 1 Echocardiographic assessment of the aorta (data from 2010 EAE guidelines (37)).

View	Part of the aorta
Transthoracic aorta	
Parasternal long + short axis	Ascending + descending thoracic
Apical four-chamber	Descending thoracic
Apical two-chamber and/or long axis	Descending thoracic
Suprasternal	Arch, descending + ascending thoracic
Subcostal	Abdominal (+ascending thoracic)
Transoesophageal echo	
Upper oesophageal – long/short axis	Ascending aorta
Aortic – long/short axis	Descending thoracic and arch

Common categories of aortopathy disease

Degenerative aortic disease

The aorta normally possesses a high degree of elasticity, which aids in the propulsion of blood downstream and this is due to the wall structure, especially components of the tunica media. It is the smooth muscle cells, elastin and collagen, which impart the elastic properties and strength of the aorta. It is alteration of the quantity and/or architecture of these fibers that leads to the mechanical and functional changes associated with aortic disease (2).

Physiological changes to the aortic anatomy occur throughout life but are generally asymptomatic until middle age. Age-related changes occur, with the tunica media, gradually stiffening due to fracturing of elastin fibers and loss of smooth muscle cells, which are responsible for synthesizing elastin within the aorta. Following this decline in elasticity, the aorta will dilate and the mechanical forces of expansion will be transferred to collagen within the aortic wall. This process leads to progressive remodelling, resulting in a stiffer and less compliant vessel (3). This results in diminished aortic resilience and tensile strength, culminating in aortic wall thinning, dilation and increased wall stress, all of which may result in dissection and/or rupture.

Thoracic aortic dilatation is therefore a common finding with increasing age and is often seen in patients with known atherosclerotic disease, in particular in those patients with systemic hypertension. The distribution of aortic dilatation varies from being confined to the aortic root and ascending aorta to gross dilatation of root, ascending, arch and descending aorta, the so-called mega aortic syndrome.

Patients will frequently present as an incidental finding and routine monitoring, blood pressure control and secondary prevention of atherosclerosis is the management strategy.

Whilst the first diagnosis may be with TTE 2D imaging, initial sizing and subsequent surveillance of the aorta is best carried out using CT or MRI and will determine the management strategy.

Bicuspid aortic valve disease

This is a common congenital abnormality with a prevalence estimated at 1% of the general population. It is also a common associated feature of a number of congenital abnormalities including aortic coarctation, Shones syndrome and Turner syndrome.

Transthoracic echo is ideally suited to define the morphology of the valve and to measure annular and sinus dimensions. It is worth noting that the aortic valve annulus may be small and the aortic root and ascending aorta may also be smaller than normal – this is important to recognise as surgery in such conditions may require enlargement of the annulus and root to prevent patient prosthesis mismatch.

When assessing the aortic valve, subtypes relating to the valve morphology are described with true bileaflet valves and combinations of fusion patterns of the right, left and non-coronary cusps, with the commonest form being fusion of right and left coronary cusps around 80%.

It is described that certain valve types are more likely to develop ascending aortic dilatation. Recent 4D MRI studies of aortic flow in BAV demonstrate marked differences in wall stress associated with differing valve morphology. The R-L fusion pattern shows a highly eccentric flow, which is associated with aortic dilatation (4).

Proteomic analysis of explanted aortic tissue following surgery has demonstrated a key difference between bicuspid and non-bicuspid aortic valve aortas. Proteins involved in the inflammatory response are upregulated in the non-bicuspid aortopathy, where proteins involved in repair mechanisms are seen to be induced in the bicuspid aortopathy tissue (5), suggesting that the pathophysiology of BAV-associated aortopathy differs from other forms of the disease where intrinsic aortic disease may exist.

Hereditary aortopathy

It has long been recognised that there are families in which multiple members have suffered a thoracic aortic dissection, often with dissection occurring at young ages. There are many recognised hereditary aortopathies, which broadly fall into the syndromic and non-syndromic categories (Fig. 1).

Marfan syndrome (MFS), which has been considered the prototype of monogenic syndromic disease, is known to increase the risk of TAAD. Since the early 1990s, it has been demonstrated that the majority of cases of MFS are due to mutations in the Fibrillin 1 gene (FBN1) (6). Since then, though, improvements in the process of mutation detection has allowed a number of mutations to be identified as the cause of TAAD in hereditary aortopathy conditions other than MFS. The most common display an autosomal dominant pattern of inheritance with highly variable penetrance. Extensive clinical and imaging studies found that involvement of the arterial vasculature is far more extensive than just the thoracic aorta in some

**BGN COL1A2 COL3A1 COL5A1 COL5A2
EFEMP2
ELN EMILIN1 FBN1 FBN2 MFAP5 LOX**

Extra-cellular Matrix genes

**FLNA FOXE3 PRKG1
MAT2A
MYH11 MYLK ACTA2**

Smooth muscle genes

**SK1 SLC2A10 SMAD2 SMAD3 SMAD4 TGFBR1
TGFBR2 TTGF2 TGF3**

Transforming growth factor Beta pathway

Figure 1

Known genes with mutations associated with hereditary aortopathy.

of these conditions. Also, genetic mutations that were originally described with syndromic presentation have been found to be present in families with familial thoracic aortic aneurysms and dissection (FTAAD) where the only manifestation is vascular with no other systems involved.

Familial aortopathy with known genotypes typically relate to mutations in the proteins forming the lamellar unit of the aortic wall and currently these known genotypes fall into three areas: mutations in genes coding for the extracellular matrix, those coding for smooth muscle protein and those that code for transforming growth factor beta (TGF beta) signalling (Fig. 2).

These known genetic variants account for around 40% of familial aortopathies and far less in those presenting with thoracic aortic dissection for the first time in their family. There is ongoing collaborative work looking for novel variants and to define what polygenic interactions may account for this otherwise unexplained aortic dilatation.

Marfan syndrome

First described clinically in 1896, Marfan syndrome is the most common of the inheritable condition with significant aortic disease. It is a highly penetrant

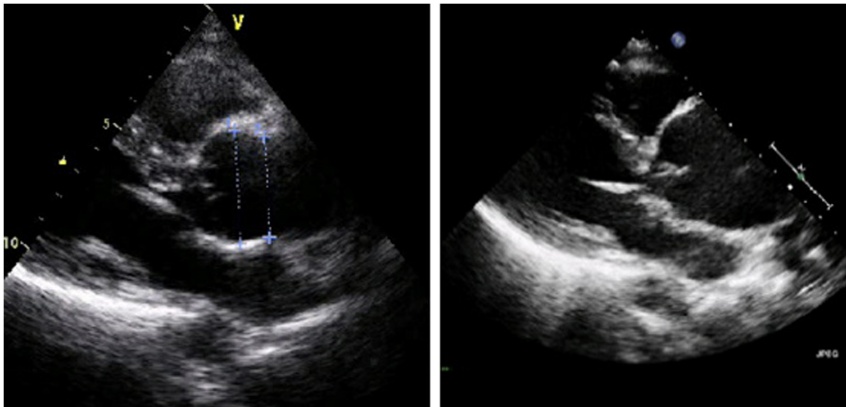


Figure 2
(A) long-axis view of aortic root measuring a maximum of 3.8 cm; (B) seven years later long-axis view of aortic root measuring a maximum of 6.2 cm which required urgent aortic surgery.

autosomal dominant disease with variable expressivity involving a number of systems mainly cardiovascular, ocular and skeletal. Prevalence is as much as 17 cases per 100,000 population and ~25–30% mutations are de novo.

Marfan syndrome is caused by mutations in the FBN1 gene on chromosome 15q21 encoding fibrillin-1, a glycoprotein in the extracellular matrix. A deficiency of fibrillin leads to weakening of the extracellular matrix and upregulation of transforming growth factor beta signalling (TGFB) and altered transcription of target genes. More than 1800 mutations have been identified, almost all unique to an affected family (7).

Significant morbidity and mortality are typically related to the cardiovascular manifestations and complications and in particular dilatation of the aortic root at the sinus of Valsalva, which is present in many patients. Other manifestations include mitral valve prolapse and rarely dilated cardiomyopathy irrespective of vascular disease. Mean survival of untreated patients is 40 years but advances in understanding of the disease have brought a lower threshold for preventative surgery and systematic medical therapy, so that life expectancy is currently not dissimilar to the general population when appropriate management is in place.

The diagnosis of Marfan syndrome is established using the revised Ghent criteria in suspected cases (8). Briefly, the diagnosis is made in an individual who has an FBN1 pathogenic variant known to be associated with Marfan syndrome and aortic root enlargement (Z-score ≥ 2.0) or ectopia lentis. In the absence of genetic testing a clinical diagnosis can be made with demonstration of aortic root enlargement (Z-score ≥ 2.0) and ectopia lentis or a defined combination of features throughout the body, yielding a systemic score ≥ 7 according to the revised Ghent criteria (Table 2).

Lifelong follow-up is mandated and for aortic root measurements, transthoracic echocardiography is easy

and reproducible. We recommend an echocardiogram every 2 years in stable aorta and more frequent imaging when progression is documented and in the paediatric group. Should there be any serial growth CT or MRA is warranted to facilitate discussion with the aortic surgical team. Below are two TTE of the aortic root of an FBN1 mutation positive Marfan patient who failed to attend follow-up for many years with significant interval change.

Loeys Dietz syndrome

Loeys-Dietz syndrome was first described in 2006 and has a significant clinical overlap with Marfan (9). It can be distinguished by the presence of cleft palate/bifid uvula,

Table 2 Systemic score for Marfan syndrome.

Skeletal features	
Wrist AND thumb sign	score +3
Wrist OR thumb sign	score +1
Pectus carinatum deformity	score +2
Pectus excavatum or chest asymmetry	score +1
Hindfoot deformity	score +2
Plain pes planus	score +1
Reduced US/LS AND increased arm/height AND no severe scoliosis	score +1
Scoliosis or thoracolumbar kyphosis	score +1
Reduced elbow extension	score +1
Imaging features	
Dural ectasia	score +2
Protrusio acetabuli	score +2
Cardiac features	
Mitral valve prolapse	score +1
Other features	
Pneumothorax	score +2
Skin striae	score +1
Myopia > 3 diopters	score +1
Facial features (3/5)	score +1

Dolichocephaly, enophthalmos, downslanting palpebral fissures, malar hypoplasia, retrognathia. Maximum total: 20 points; score ≥ 7 indicates systemic involvement.

hypertelorism and widespread aortic and arterial tortuosity and aneurysms. Clinical features are frequently present involving vascular, skeletal, craniofacial and cutaneous systems. Incidence is currently unknown and cardiovascular manifestations are more severe and include congenital heart disease and early onset aortic and middle-size artery aneurysm with tendency to rupture at smaller diameter.

Diagnosis is based on the presence of suggestive vascular findings associated with a genetic mutation in one of the six described genes encoding for components of the TGFB pathway. Mutations in cytokines (TGFB2/3), receptors (TGBR1/2) or downstream effectors (SMAD2/3) are also associated with similar clinical presentations, and have led to the classification of Loews-Dietz type 1 to 6 (10). Median survival was reported at 26 years of age in the early description of the disease and it is heavily dependent on a prompt diagnosis. Catastrophic vascular events have been described as early as 3 months of age and preventative surgery is the only effective management. Routine use of angiotensin II receptor antagonists is recommended based on the known interaction between the two pathways. Such events are also commonly seen in the peri-partum period of pregnancy and many families report death following childbirth.

Aortic dissection can occur even with normal aortic dimensions, as illustrated by the CT scans (Fig. 3). Therefore, education of the affected individual and their family is important, so that they ensure urgent review if they suffer any chest pain. Annual MRA scanning of the aorta is mandated and if there is evidence of serial growth then discussion with the patient and aortic surgical team is reasonable. Replacement of the aortic root will prevent

a type A dissection but the long-term risk to the rest of the vasculature remains.

Histologic examination of aortic tissue in LDS reveals fragmentation of elastic fibers, loss of elastin content, and accumulation of amorphous matrix components in the aortic media. Structural analysis shows loss of the intimate spatial association between elastin deposits and vascular smooth muscle cells and a marked excess of aortic wall collagen. These characteristics are observed in young children and in the absence of inflammation, suggesting a severe defect in elastogenesis rather than secondary elastic fibre destruction (11).

Vascular EDS

Vascular Ehlers Danlos syndrome is associated with vascular rupture of middle-size arteries and the aorta at normal diameters and hollow organs (12). Clinically, important clues are a history of an arterial/intestinal/uterine rupture and minor features including easy bruising and a typical facial appearance. Guidelines recommend surgical intervention only in the setting of life-threatening complications due to the increased surgical and interventional risk (13, 14) so management of aneurysms requires a multidisciplinary approach and expert team. Lifespan is estimated at a median age of 51 with a wide range and phenotype-genotype correlations are emerging and might allow for a better stratification of risk of events.

Turner syndrome

Turner syndrome, one of the most common sex chromosome aneuploidy syndromes, is present

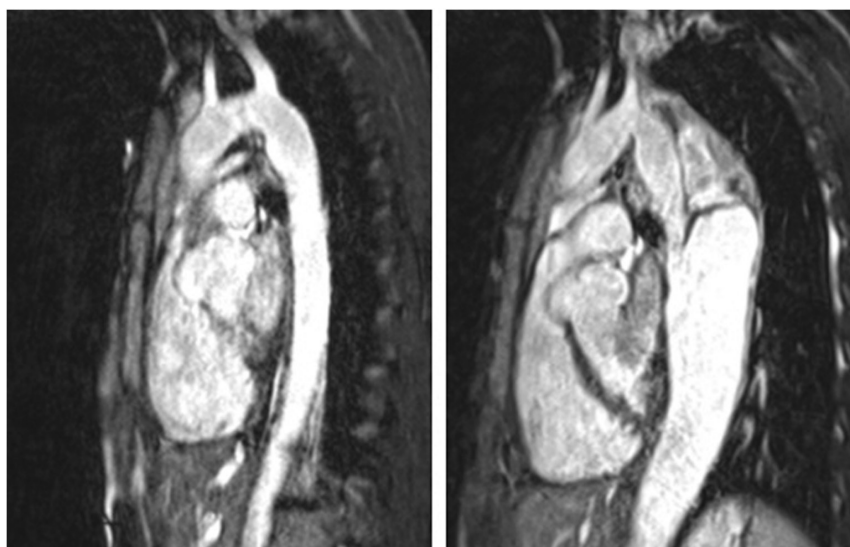


Figure 3
(A) MRA of aorta in patient with TGFB1 mutation;
(B) MRA demonstrating type B dissection and rapid expansion of descending aorta six months later.

in 25–50 per 100,000 females. Diagnosis is made in phenotypic females with a karyotype containing one X chromosome and complete or partial absence of the second sex chromosome, monosomy (45X0) is present in 40–50%. The most important phenotypic features are short stature, gonadal dysgenesis, neck webbing, and an increased incidence of renal and cardiovascular abnormalities. The latter include a wide range of left-sided lesion, more frequently consisting of bicuspid aortic valve (BAV) documented in 14–34%, coarctation of the aorta in 7–14% and thoracic aortic aneurysms reported in 3–42%. Aortic dissection has been estimated to be seven-fold more frequent than in the general population at 40 events in 100,000 patient years with the majority happening in young women in their third or fourth decade. Presence of congenital heart disease, 45X0 genotype, hypertension and pregnancy are considered risk factors. As aortic events do happen at small diameters and considering the short stature related to the syndrome, disease-specific z-scores and surgical thresholds have been suggested (15). Surveillance, even in the absence of overt cardiac disease, is recommended, as acquired cardiac diseases including aortic and coronary disease is prevalent.

Other inherited conditions with aortic dilatation

A more in-depth understanding of the molecular background and biological pathways involved in aneurysms formation has allowed to recognize new inherited entities with aortic disease where genes coding for components of the extracellular matrix, TGF β pathway and smooth muscle cells. Syndromic and non-syndromic presentation overlaps in some genotypes and they include subtypes of Ehlers-Danlos syndrome. A mild and stable degree of aortic dilatation with a benign course is described in up to 25% of patients with the most common forms, classical and hypermobile,

while vascular accidents have been described with higher frequency in rarer subtypes (16, 17, 18). Some genotypes have been demonstrated to be responsible for a syndromic presentation, or an isolated vascular phenotype often referred to as familial thoracic aneurysms and dissection (FTAAD). A complete description is beyond the scope of the review but it is summarized in the paper from Loeys and colleagues (19).

Additional features suggestive of hereditary aortopathy

Arterial tortuosity

Arterial tortuosity of the aortic branch vessels and specifically the head and neck vessels (Fig. 4) is a common finding in a number of hereditary aortopathies and therefore should be screened for with appropriate imaging modality (typically MRA of the whole aorta and head and neck vessels). Whilst tortuosity in itself rarely causes a clinical concern, many conditions also demonstrate small and medium vessel aneurysm formation associated with a significant lifetime risk of morbidity (20). Also the presence of tortuosity has been suggested as a marker for increased risk of aortic events.

Early onset osteoarthritis

Early onset osteoarthritis is particularly associated with mutations in SMAD3 and is characterised by early onset of widespread osteoarthritis and osteochondritis dissecans, and by widespread vascular abnormalities including aneurysms and marked tortuosity. It is a highly penetrant autosomal dominant pattern of inheritance. Often the osteoarthritis is the presenting feature and this should be considered in patients with a family history of early cardiovascular death and early onset osteoarthritis (21).

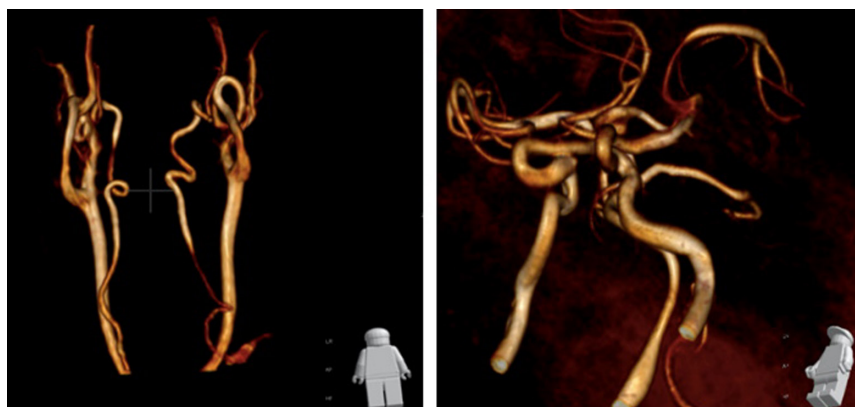

Figure 4
(A) Mild tortuosity and looping of the head and neck vessels in a young patient with confirmed TGFBR1 mutation and (B) marked cerebral vessel tortuosity in a young man with genotype negative gross aortic root dilatation.

Aortic embryology

The specific location of dilatation which occurs first in the aortic root is thought to be secondary to the high pressures generated by the left ventricle but has been recently felt to be also a consequence of a different embryological origin of the vascular smooth muscle cells in the aortic root (22). In early embryogenesis, vascular smooth muscle cells (VSMC) derive from a number of areas and these appear to be consistent, with aortic root VSMC deriving from the lateral plate mesoderm, the ascending aorta and arch from neural crest origin and the descending aorta from the paraxial mesoderm (23) (Fig. 3). It is of note that the point at which aortic dissection occurs is at the junction of these parts of the aorta (Fig. 5). This is the subject of further investigation but may explain the specific nature of thoracic aortic dissection.

Acute aortic syndromes

Sudden severe chest pain typically radiating through to the back is the classical presentation of patients with a thoracic aortic dissection. The pathological characteristic is separation of the intima from the media of the aorta, creating a new channel, the false lumen. This is termed a thoracic aortic dissection and is typically defined by the point at which the intimal flap occurs and whilst there are a number of classifications used, the simplest is the Stanford classification of type A or type B (Fig. 4). Whenever a thoracic aortic dissection is suspected, urgent CT scanning is mandated to demonstrate the integrity or otherwise of the aortic wall. Recent guidelines suggest that TOE is an alternative to this, but where available CT should be used as it is diagnostic and will demonstrate the full extent of the dissection, allowing the surgeon to plan the surgical intervention (13). Early intervention in this condition is essential to reduce mortality and immediate discussion with the surgical team once the diagnosis is made is crucial.

In the type A dissection (Fig. 4A) the intimal flap originates in the ascending aorta and in the type B it originates in the descending aorta (Fig. 4B). The false lumen typically extends distal to the point of dissection and can extend as far as the iliac vessels in both types. The distinction is important as Type A dissection is associated with significant early mortality, and is managed with emergency open surgical intervention to replace the segment of aorta where the intimal flap has been raised. Without surgery, proximal extension can lead to a cardiac tamponade and/or acute coronary ischaemia when the coronary origins are compromised, or rapid expansion

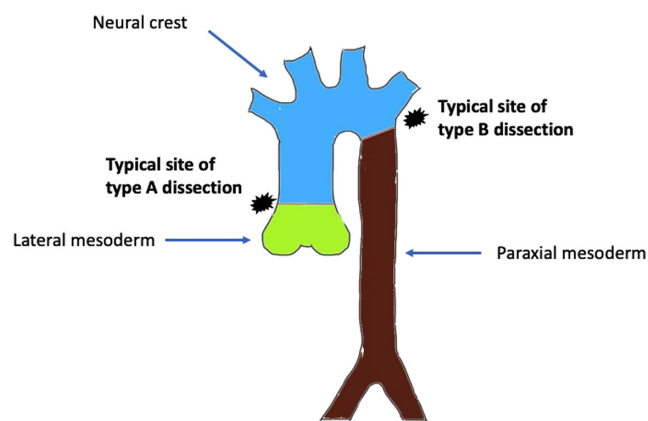


Figure 5

Embryological origins of the vascular smooth muscle cells of the thoracic aorta. (A) Stanford type A thoracic aortic dissection and (B) Stanford type B thoracic aortic dissection.

of the aorta leading to rupture. In such cases, death can occur rapidly, with the diagnosis of aortic dissection being made post mortem.

The management of a type B dissection is typically conservative with control of systemic hypertension, with i.v. beta-adrenergic blockade being the mainstay of therapy. In recent times, the developing technology of self-expanding stents has allowed for percutaneous placement of a large covered thoracic aortic stent. Thoracic endovascular aortic replacement (TEVAR) is routinely used in many countries for the acute management of type B dissection but this remains controversial and is not supported by randomised trial data (24). Medical management is associated with excellent outcomes for most patients with type B dissection and remains the standard treatment for all, with additional TEVAR therapy in selected cases.

In selected cases, TEVAR should be considered. In patients post Type B dissection with a rapidly expanding descending aorta, distal perfusion issues, uncontrolled hypertension, ongoing symptoms. These features are more common in patients with a dissection entry point >10 mm, a partially thrombosed false lumen, a descending aortic dimension >35 mm or false lumen diameter >20 mm (25). What is clear, is that if an early intervention (<14 days from presentation) is required in these patients then the outcome is poor regardless of intervention (25).

Routine medical treatment

Systemic hypertension can play a key role in the formation of aortic aneurysm or as a contributing factor

in patients with congenital cardiac defects or inherited conditions. Aggressive medical treatment is important and a number of drug classes can be used as monotherapy or in combination to achieve optimal blood pressure values (26). Young patients with inherited aortic diseases are very rarely hypertensive but medications that reduce hemodynamic stress on the aortic wall, such as beta blockers (β -blockers) or angiotensin receptor blockers (ARBs), have been tested in Marfan syndrome. Though literature is limited to small studies with some controversial results (27) there is evidence medicines are beneficial and reduce the rate of aortic growth and β -blockade is currently recommended and generally initiated at diagnosis or upon documentation of significant and/or progressive aortic dilatation (28, 29). Beside the haemodynamic stress to the arterial wall, which is an obvious target for treatment, interest in the past decade has moved to possibly modifying the dysregulation of the TGF β pathway as ARBs have proven effective in mice models (30) and results of the AIMS study are at least partially supporting findings in humans (31). There is evidence in the trials these should be up titrated to the highest tolerated dose and to haemodynamic effect on exercise. No evidence is available in many other rare conditions including scarce data in bicuspid aortic valve aortopathy and medical management is largely extrapolated from Marfan data. A single small randomized trial in vEDS patients showed a reduced rate of vascular events in the group treated with the β -blocker Celiprolol but more data is needed (32). Many centres are now routinely using ARBs in the management of younger patients with aortopathy based on these studies, where beta-blockers remain mainstay therapy in other institution and ARBs are used in conjunction.

Moderate aerobic exercise is safe and should be encouraged in all patients, but certain activities are not recommended. Patients with a dilated aorta do not compete in impact sports or in activities where sudden deceleration is a risk, they should not lift where straining is required as this may induce a Valsalva manoeuvre associated with a rapid transient increase in systemic blood pressure on release. Extreme sports should be avoided including extreme endurance sports. All recreational drugs should be avoided and smoking cigarettes is discouraged.

Having adequate travel insurance is recommended for all travel, and patients currently should declare they have a dilated aorta and should declare any family history but do not need to declare genetic results. This may change in the future when widespread genotyping may become available and this should be discussed with their clinical genetics team.

Pregnancy is a risk for young women with a dilated aorta. The normal vascular changes that occur in pregnancy predispose to further aortic dilatation and thoracic aortic dissection is not uncommon. Our practice is for all women to undergo pre-pregnancy counselling regarding the risks. Any woman with a dilated aorta will undergo a mid-trimester MRA of the thoracic aorta (33) and if further dilatation has occurred we would discuss a planned caesarian section, prior to the expected date of delivery. Surgery during pregnancy may be indicated in certain cases (34). If the aorta is greater than 4.5 cm prior to pregnancy then the risk of dissection during pregnancy is considered greater than the risk of surgery and patients may discuss prophylactic surgery with their clinical teams. Progesterone-only contraception is recommended and is safe in all women with a cardiovascular condition.

Elective surgical management

Indication for elective surgical treatment is commonly discussed to replace the dilated portion of the aorta and address any significant valvular disease or other anatomic findings amenable to surgical repair. While it was once felt the absolute diameter was the only factor influencing the decision making (35) it is clear that many other factors need to be taken into account when assessing these patients' risk and when trying to prevent acute aortic events. Some of them are incorporated in the most recent guidelines from the American and European societies of cardiology (13, 14), but the most recent genotype-phenotype correlations are not reflected by these documents. Therefore, in rare diseases decision making is extrapolated from data available in similar conditions and thorough assessment of the perceived individual risk and dictate a patient-tailored approach (36).

In Marfan syndrome surgical repair of the aorta is indicated once the maximal measurement approaches 5.0 cm, or the rate of increase of the aortic root diameter approaches 1.0 cm per year or there is progressive and severe aortic regurgitation (13, 14). More aggressive therapy may be indicated in individuals with a family history of early aortic dissection and we would typically offer surgery in such instances once the aorta exceeds 4.5 cm in Marfan syndrome and greater than 4 cm in Loeys Dietz syndrome. Many individuals can receive a valve-sparing procedure that precludes the need for chronic anticoagulation.

While there is no agreed-upon absolute size threshold for aortic root surgery in childhood, many centres use

the adult guideline of 5.0 cm given the extreme rarity of aortic dissection in young children or 4.5 cm in the presence of a perceived increased risk. Every effort is made to allow the aortic annulus to reach a size of at least 2.0 cm, allowing placement of an aortic graft of sufficient size to accommodate body growth (18).

Surgery usually consists in replacing the dilated portion of the aorta aiming for a valve-sparing operation when possible in order to avoid the long-term anticoagulation required with mechanical valves (i.e. David/Yacoub operation versus Bentall operation). Novel techniques such as surgical aortic valve repair/plasty and external aortic root support are gaining research interest and results are awaited to assess if they can represent a viable option on a vast scale.

Conclusion

Thoracic aortopathy is a rare condition in which the thoracic aorta dilates, placing the individual at risk of thoracic aortic dissection and rupture. It is a rare cause of sudden death in the younger adult and very occasionally in children, when it is likely to have a genetic cause. However, the majority of such cases remain unexplained and considerable efforts are being made to understand the genetic disorders that underlie aortic dilatation. Imaging is key to diagnosis and long-term surveillance both prior to and following intervention or dissection. In time we may understand the mechanisms underlying the dilatation of the aorta and better therapeutic interventions may be developed.

Declaration of interest

The authors declare that there is no conflict of interest that could be perceived as prejudicing the impartiality of this review.

Funding

This review did not receive any specific grant from any funding agency in the public, commercial or not-for-profit sector.

References

- Howard DP, Banerjee A, Fairhead JF, Perkins J, Silver LE, Rothwell PM & Oxford Vascular Study. Population-based study of incidence and outcome of acute aortic dissection and premorbid risk factor control: 10-year results from the Oxford Vascular Study. *Circulation* 2013 **127** 2031–2037. (<https://doi.org/10.1161/CIRCULATIONAHA.112.000483>)
- Tsamis A, Krawiec JT & Vorp DA. Elastin and collagen fibre microstructure of the human aorta in ageing and disease: a review. *Journal of the Royal Society, Interface* 2013 **10** 20121004. (<https://doi.org/10.1098/rsif.2012.1004>)
- Collins JA, Munoz J-V, Patel TR, Loukas M & Tubbs RS. The anatomy of the aging aorta. *Clinical Anatomy* 2014 **27** 463–466. (<https://doi.org/10.1002/ca.22384>)
- Mahadevia R, Barker AJ, Schnell S, Entezari P, Kansal P, Fedak PW, Malaisrie SC, McCarthy P, Collins J, Carr J, et al. Bicuspid aortic cusp fusion morphology alters aortic three-dimensional outflow patterns, wall shear stress, and expression of aortopathy. *Circulation* 2014 **129** 673–682. (<https://doi.org/10.1161/CIRCULATIONAHA.113.003026>)
- Kjellqvist S, Maleki S, Olsson T, Chwastyniak M, Branca RM, Lehtio J, Pinet F, Franco-Cereceda A & Eriksson P. A combined proteomic and transcriptomic approach shows diverging molecular mechanisms in thoracic aortic aneurysm development in patients with tricuspid- and bicuspid aortic valve. *Molecular and Cellular Proteomics* 2013 **12** 407–425. (<https://doi.org/10.1074/mcp.M112.021873>)
- Blanton SH, Sarfarazi M, Eiberg H, de Groote J, Farndon PA, Kilpatrick MW, Child AH, Pope FM, Peltonen L & Francomano CA. An exclusion map of Marfan syndrome. *Journal of Medical Genetics* 1990 **27** 73–77. (<https://doi.org/10.1136/jmg.27.2.73>)
- Judge DP & Dietz HC. Marfan's syndrome. *Lancet* 2005 **366** 1965–1976. ([https://doi.org/10.1016/S0140-6736\(05\)67789-6](https://doi.org/10.1016/S0140-6736(05)67789-6))
- Loeys BL, Dietz HC, Braverman AC, Callewaert BL, De Backer J, Devreux RB, Hilhorst-Hofstee Y, Jondeau G, Faivre L, Milewicz DM, et al. The revised Ghent nosology for the Marfan syndrome. *Journal of Medical Genetics* 2010 **47** 476–485. (<https://doi.org/10.1136/jmg.2009.072785>)
- Loeys BL, Schwarze U, Holm T, Callewaert BL, Thomas GH, Pannu H, De Backer JF, Oswald GL, Symoens S, Manouvrier S, et al. Aneurysm syndromes caused by mutations in the TGF-beta receptor. *New England Journal of Medicine* 2006 **355** 788–798. (<https://doi.org/10.1056/NEJMoa055695>)
- MacCarrick G, Black 3rd JH, Bowdin S, El-Hamamsy I, Frischmeyer-Guerrero PA, Guerrero AL, Sponseller PD, Loeys B & Dietz 3rd HC. Loeys-Dietz syndrome: a primer for diagnosis and management. *Genetics in Medicine* 2014 **16** 576–587. (<https://doi.org/10.1038/gim.2014.11>)
- Loeys BL & Dietz HC. Loeys-Dietz syndrome. In *Gene Reviews*. Eds MA Adam, HH Ardinger & RA Pagon. Seattle, WA, USA: University of Washington, 2018. (available at: <https://www.ncbi.nlm.nih.gov/books/NBK1133/>)
- Byers PH, Belmont J, Black J, De Backer J, Frank M, Jeunemaitre X, Johnson D, Pepin M, Robert L, Sanders L, et al. Diagnosis, natural history, and management in vascular Ehlers–Danlos syndrome. *American Journal of Medical Genetics: Part C, Seminars in Medical Genetics* 2017 **175** 40–47. (<https://doi.org/10.1002/ajmg.c.31553>)
- Erbel R, Aboyans V, Boileau C, Bossone E, Bartolomeo RD, Eggebrecht H, Evangelista A, Falk V, Frank H, Gaemperli O, et al. 2014 ESC Guidelines on the diagnosis and treatment of aortic diseases: document covering acute and chronic aortic diseases of the thoracic and abdominal aorta of the adult. The Task Force for the Diagnosis and Treatment of Aortic Diseases of the European Society of Cardiology (ESC). *European Heart Journal* 2014 **35** 2873–2926. (<https://doi.org/10.1093/eurheartj/ehu281>)
- Hiratzka LF, Bakris GL, Beckman JA, Bersin RM, Carr VF, Casey Jr DE, Eagle KA, Hermann LK, Isselbacher EM, Kazerooni EA, et al. 2010 ACCF/AHA/AATS/ACR/ASA/SCA/SCAI/SIR/STS/SVM guidelines for the diagnosis and management of patients with thoracic aortic disease: executive summary. A report of the American College of Cardiology Foundation/American Heart Association Task Force on Practice Guidelines, American Association for Thoracic Surgery, American College of Radiology, American Stroke Association, Society of Cardiovascular Anesthesiologists, Society for Cardiovascular Angiography and Interventions, Society of Interventional Radiology,

- Society of Thoracic Surgeons, and Society for Vascular Medicine. *Catheterization and Cardiovascular Interventions* 2010 **76** E43–E86. (<https://doi.org/10.1002/ccd.22537>)
- 15 Gravholt CH, Andersen NH, Conway GS, Dekkers OM, Geffner ME, Klein KO, Lin AE, Mauras N, Quigley CA, Rubin K, *et al.* Clinical practice guidelines for the care of girls and women with Turner syndrome: proceedings from the 2016 Cincinnati International Turner Syndrome Meeting. *European Journal of Endocrinology* 2017 **177** G1–G70. (<https://doi.org/10.1530/EJE-17-0430>)
 - 16 Brady AF, Demirdas S, Fournel-Gigleux S, Ghali N, Giunta C, Kapferer-Seebacher I, Kosho T, Mendoza-Londono R, Pope MF, Rohrbach M, *et al.* The Ehlers-Danlos syndromes, rare types. *American Journal of Medical Genetics: Part C, Seminars in Medical Genetics* 2017 **175** 70–115. (<https://doi.org/10.1002/ajmg.c.31550>)
 - 17 Meester JAN, Verstraeten A, Schepers D, Alaerts M, Van Laer L & Loeys BL. Differences in manifestations of Marfan syndrome, Ehlers-Danlos syndrome, and Loeys-Dietz syndrome. *Annals of Cardiothoracic Surgery* 2017 **6** 582–594. (<https://doi.org/10.21037/acs.2017.11.03>)
 - 18 Dietz H. Marfan syndrome. In *GeneReviews*. Eds MA Adam, HH Ardinger & RA Pagon. Seattle, WA, USA: University of Washington, 2017. (available at: <https://www.ncbi.nlm.nih.gov/books/NBK1335/>)
 - 19 Verstraeten A, Luyckx I & Loeys B. Aetiology and management of hereditary aortopathy. *Nature Reviews: Cardiology* 2017 **14** 197–208. (<https://doi.org/10.1038/nrcardio.2016.211>)
 - 20 Emmanuel Y, Gordon-Smith J, McKillop G, Duddy M & Clift P. Late peripheral thoracic aneurysms following aortic root surgery in patients with Loeys-Dietz syndrome. *Journal of Vascular and Interventional Radiology* 2015 **26** 1539–1543. (<https://doi.org/10.1016/j.jvir.2015.04.014>)
 - 21 van de Laar IM, van der Linde D, Oei EH, Bos PK, Bessems JH, Bierma-Zeinstra SM, van Meer BL, Pals G, Oldenburg RA, Bekkers JA, *et al.* Phenotypic spectrum of the SMAD3-related aneurysms-osteoarthritis syndrome. *Journal of Medical Genetics* 2012 **49** 47–57. (<https://doi.org/10.1136/jmedgenet-2011-100382>)
 - 22 Sherif HM. Heterogeneity in the segmental development of the aortic tree: impact on management of genetically triggered aortic aneurysms. *Aorta* 2014 **2** 186–195. (<https://doi.org/10.12945/j.aorta.2014.14-032>)
 - 23 Sinha S, Iyer D & Granata A. Embryonic origins of human vascular smooth muscle cells: implications for in vitro modeling and clinical application. *Cellular and Molecular Life Sciences* 2014 **71** 2271–2288. (<https://doi.org/10.1007/s00018-013-1554-3>)
 - 24 Nienaber CA, Kische S, Rousseau H, Eggebrecht H, Rehders TC, Kundt G, Glass A, Scheinert D, Czerny M, Kleinfeldt T, *et al.* Endovascular repair of type B aortic dissection: long-term results of the randomized investigation of stent grafts in aortic dissection trial. *Circulation: Cardiovascular Interventions* 2013 **6** 407–416. (<https://doi.org/10.1161/CIRCINTERVENTIONS.113.000463>)
 - 25 Nienaber CA. The art of stratifying patients with Type B aortic dissection. *Journal of the American College of Cardiology* 2016 **67** 2843–2845. (<https://doi.org/10.1016/j.jacc.2016.04.016>)
 - 26 Mancía G, Fagard R, Narkiewicz K, Redon J, Zanchetti A, Böhm M, Christiaens T, Cifkova R, De Backer G, Dominiczak A, *et al.* 2013 ESH/ESC practice guidelines for the management of arterial hypertension. *Blood Pressure* 2014 **23** 3–16. (<https://doi.org/10.3109/08037051.2014.868629>)
 - 27 Singh MN & Lacro RV. Recent clinical drug trials evidence in Marfan syndrome and clinical implications. *Canadian Journal of Cardiology* 2016 **32** 66–77. (<https://doi.org/10.1016/j.cjca.2015.11.003>)
 - 28 Lacro RV, Dietz HC & Mahony L. Atenolol versus losartan in Marfan's syndrome. *New England Journal of Medicine* 2015 **372** 980–981. (<https://doi.org/10.1056/NEJMc1500128>)
 - 29 Shores J, Berger KR, Murphy EA & Peyeritz RE. Progression of aortic dilatation and the benefit of long-term beta-adrenergic blockade in Marfan's syndrome. *New England Journal of Medicine* 1994 **330** 1335–1341. (<https://doi.org/10.1056/NEJM199405123301902>)
 - 30 Habashi JP, Judge DP, Holm TM, Cohn RD, Loeys BL, Cooper TK, Myers L, Klein EC, Liu G, Calvi C, *et al.* Losartan, an AT1 antagonist, prevents aortic aneurysm in a mouse model of Marfan syndrome. *Science* 2006 **312** 117–121. (<https://doi.org/10.1126/science.1124287>)
 - 31 Mullen MJ, Flather MD, Jin XY, Newman WG, Erdem G, Gaze D, Valencia O, Banya W, Foley CE & Child A. A prospective, randomized, placebo-controlled, double-blind, multicenter study of the effects of irbesartan on aortic dilatation in Marfan syndrome (AIMS trial): study protocol. *Trials* 2013 **14** 408. (<https://doi.org/10.1186/1745-6215-14-408>)
 - 32 Ong KT, Perdu J, De Backer J, Bozec E, Collignon P, Emmerich J, Fauret AL, Fiessinger JN, Germain DP, Georgesco G, *et al.* Effect of celiprolol on prevention of cardiovascular events in vascular Ehlers-Danlos syndrome: a prospective randomised, open, blinded-endpoints trial. *Lancet* 2010 **376** 1476–1484. ([https://doi.org/10.1016/S0140-6736\(10\)60960-9](https://doi.org/10.1016/S0140-6736(10)60960-9))
 - 33 Moody WE, Pickup L, Plunkett E, Fryearson J, Clift PF, Katie Morris R, Thompson PJ, Thorne S & Hudsmith LE. Feasibility of performing non-contrast magnetic resonance angiography in pregnant subjects with familial aortopathies. *International Journal of Cardiology* 2017 **244** 354–357. (<https://doi.org/10.1016/j.ijcard.2017.05.125>)
 - 34 van Hagen IM & Roos-Hesselink JW. Aorta pathology and pregnancy. *Best Practice and Research: Clinical Obstetrics and Gynaecology* 2014 **28** 537–550. (<https://doi.org/10.1016/j.bpobgyn.2014.03.007>)
 - 35 Coady MA, Rizzo JA, Hammond GL, Kopf GS & Elefteriades JA. Surgical intervention criteria for thoracic aortic aneurysms: a study of growth rates and complications. *Annals of Thoracic Surgery* 1999 **67** 1922–1926; discussion 1953–1928. ([https://doi.org/10.1016/s0003-4975\(99\)00431-2](https://doi.org/10.1016/s0003-4975(99)00431-2))
 - 36 Jondeau G, Ropers J, Regalado E, Braverman A, Evangelista A, Teixedo G, De Backer J, Muino-Mosquera L, Naudion S, Zordan C, *et al.* International registry of patients carrying TGFBR1 or TGFBR2 mutations: results of the MAC (Montalcino Aortic Consortium). *Circulation: Cardiovascular Genetics* 2016 **9** 548–558. (<https://doi.org/10.1161/CIRCGENETICS.116.001485>)
 - 37 Evangelista A, Flachskampf FA, Erbel R, Antonini-Canterin F, Vlachopoulos C, Rocchi G, Sicari R, Nihoyannopoulos P, Zamorano J, European Association of Echocardiography, *et al.* Echocardiography in aortic diseases: EAE recommendations for clinical practice. *European Journal of Echocardiography* 2010 **11** 645–658. (<https://doi.org/10.1093/ejechocard/jeq056>)

Received in final form 22 November 2019

Accepted 5 December 2019

Accepted Manuscript published online 5 December 2019