

# Contrast blush on CT is a poor predictor of active bleeding on pelvic angiography

Andrew S. Do, BS, Benjamin R. Childs, BS, Sarah Gael, MD, Heather A. Vallier, MD\*

## Abstract

**Objective:** Determine if contrast extravasation (CE) on computed tomography (CT), also called CT blush, is a reliable predictor of clinically relevant arterial bleeding from pelvic ring injury.

**Design:** Retrospective cohort.

**Setting:** Single level I trauma center.

**Patients/participants:** A total of 189 patients who underwent pelvic angiography between 1999 and 2015.

**Intervention:** Demographic and injury data, including Young–Burgess fracture classification, Injury Severity Score (ISS), Glasgow Coma Scale (GCS), and clinical data including hypotension and heart rate upon presentation were recorded. Charts, radiographs, and interventional radiology reports and studies were reviewed.

**Main outcome measurements:** CE on CT scan was noted from reports. Angiography studies were reviewed for active arterial bleeding.

**Results:** Mean age was 49 years, with 64% male. CE was noted in 111 patients (66%), with increasing frequency over the study period. Patients under age 55 were less likely to have CE ( $P < .001$ ). GCS was higher and ISS lower in patients with CE (both  $P < .05$ ). For CE as predictor of active bleeding, sensitivity was 67%, specificity 34%, and positive predictive value (PPV) was 58% ( $P = .95$ ). For CE as predictor of overall mortality, the sensitivity, specificity, and PPV were 67%, 33%, and 16%, respectively ( $P = 1.0$ ). However, hypotension had sensitivity of 83% for active bleeding and 97% for mortality, both  $P < .001$ .

**Conclusions:** While CT blush was neither a sensitive nor specific predictor of active bleeding on pelvic angiography, hypotension was a sensitive indicator of both bleeding and mortality. These findings suggest that CE is not an independently sufficient indication for pelvic angiography.

Level of Evidence: Level III

**Abbreviations:** APC = anterior posterior compression, CE = contrast extravasation, CMI = combined mechanism of injury, CT = computed tomography, GCS = Glasgow Coma Scale, GSW = gunshot wound, ISS = Injury Severity Score, LC = lateral compression, LOS = length of stay, MCC = motorcycle crash, MVC = motor vehicle collision, NPV = negative predictive value, PED = pedestrian struck, PPV = positive predictive value, SBP = systolic blood pressure, SD = standard deviation, VS = vertical shear

**Keywords:** angiography, contrast extravasation, CT blush, hypotension, pelvic ring injury, pelvis fracture, predictive

## Introduction

Arterial bleeding from pelvic ring fracture is associated with high rates of morbidity and mortality.<sup>[1–4]</sup> Due to concomitant injuries, multidisciplinary treatment, and time constraints, hemorrhage control from pelvic fracture can be particularly

challenging. While angiographic embolization is a widely utilized treatment approach for hemorrhage in pelvic fracture patients with suspected arterial bleeding, there is still ongoing discussion regarding which patients are the best candidates for interventional radiology.<sup>[5]</sup>

In a review of 25 studies by Karadimas et al,<sup>[6]</sup> there was great variation in the therapeutic rates of embolization for angiography, ranging from 10% to 100% and averaging 71%. Previous studies have investigated different possible predictors and indications for patients that would most benefit from angiographic embolization, including hypotension upon admission, fracture pattern, hematoma, and CE.<sup>[4,7,8]</sup> CE on contrast-enhanced CT, also referred to as contrast blush, is commonly used to diagnose arterial bleeding related to pelvic fracture and is considered an important indication for pelvic angiography. The 2011 Eastern Association for Surgery of Trauma (EAST) guidelines recommend pelvic angiography for patients with CE on pelvic CT, regardless of hemodynamic status.<sup>[5,9–11]</sup> Accurately identifying sites of active bleeding via non-invasive imaging studies may guide interventionalists to the anatomic location requiring hemostasis.<sup>[12]</sup> However, some studies have found CT contrast blush to have low positive predictive value. These

The authors have no funding and no conflicts of interest to disclose.

Department of Orthopaedic Surgery, affiliated with Case Western Reserve University, MetroHealth Medical Center, Cleveland, OH

\* Corresponding author. Address: MetroHealth Medical Center, Department of Orthopaedic Surgery, 2500 MetroHealth Drive, Cleveland, OH 44109. Tel: +216 778 7361; fax: +216 778 4069. E-mail address: hvallier@metrohealth.org (Heather A. Vallier).

Copyright © 2018 The Authors. Published by Wolters Kluwer Health, Inc. on behalf of the Orthopaedic Trauma Association.

This is an open-access article distributed under the Creative Commons Attribution-NoDerivatives License 4.0, which allows for redistribution, commercial and non-commercial, as long as it is passed along unchanged and in whole, with credit to the author.

OTA (2018) e009

Received: 12 February 2018 / Accepted: 17 July 2018

<http://dx.doi.org/10.1097/OI9.000000000000009>

authors suggest that not all patients with blush require intervention and caution against using it as the sole indication for invasive intervention.<sup>[13–17]</sup> Furthermore, less than half of patients with contrast blush required angiographic embolization in several studies.<sup>[1,13–17]</sup> Clearly, there is much discrepancy between various institutions and practices, making it difficult to draw conclusions. With conflicting observations, the question remains: in trauma patients with pelvic fracture, does CE on CT indicate an active arterial hemorrhage that warrants angiographic evaluation for embolization?

The purpose of this study is to investigate if CE on CT is a clinically useful predictor for arterial hemorrhage requiring therapeutic angiographic embolization. In addition, we explored demographic, injury, and admission characteristics that may be associated with active bleeding or in-hospital mortality. We hypothesized that contrast blush on CT in isolation is not a reliable predictor of clinically significant arterial bleeding.

## Methods

A retrospective review of a single level I trauma center included 189 skeletally mature patients between 1999 and 2015 who underwent angiography following pelvic trauma. This accounted for 10.3% of all patients with pelvic ring fractures treated during that time. Patient data including age, sex, mechanism of injury, ISS, and GCS were abstracted from medical records. Plain radiographic images and CT scans of the pelvis were reviewed to classify fractures as described by Young and Burgess.<sup>[18,19]</sup> It is standard practice at this institution to perform pelvic CT scans for pelvic ring injuries after major blunt trauma. CE was reported within the pelvis CT scan. In some cases, it was not necessarily at a location of fracture or fracture displacement. This study did not attempt to link the location of CE with the proximity of active bleeding on angiography.

Indications for pelvic angiography included clinical signs and radiographic findings suggestive of active bleeding. The decision for pelvic angiography was at discretion of the attending trauma surgeon after initial circumferential pelvic reduction and administration of an intravenous fluid bolus. Possible clinical signs of ongoing bleeding included persistent hypotension, anteroposterior compression (APC) pattern, and/or pelvic hematoma, and CE on CT. Hypotension was defined as systolic blood pressure <90 mm Hg. Blood pressure was measured upon presentation to the emergency department and at a minimum of 15 minute intervals thereafter. Patients who demonstrated hypotension were all identified within the first 90 minutes after presentation. Sixteen (8.7%) of all angiography patients underwent emergent laparotomy followed by angiography, without a prior CT scan and were, therefore, excluded from the study.

Findings and interventions of angiography were acquired from interventional radiology procedure reports and review of studies. Findings were categorized as either “no bleeding seen” for negative angiography or “active bleeding” for positive angiography findings, which was determined by the presence or absence of bleeding on angiography. Other angiographic findings and morphologic descriptions, such as pseudoaneurysms or small intimal tears, were categorized as “no bleeding seen.” Specific arterial embolization was accomplished using microcoils while nonspecific embolization employed Gelfoam pledgets (Pfizer, Kalamazoo, MI).

Statistical analysis was performed with IBM SPSS Statistics 24 software, using student *t*-test for continuous variables and

chi-square or one-way ANOVA for categorical variables where appropriate. Microsoft Excel 2016 was used to calculate sensitivity, specificity, and positive predictive value (PPV). Graphs and charts were also generated using SPSS or Excel. The *P*-value level for significance was set at  $P < .05$ .

## Results

Mean age was 49 years, and 121 patients (64%) were male. The 3 most common mechanisms of injury were motor vehicle collision (MVC) 32%, motorcycle crash (MCC) 18%, and pedestrian struck by motor vehicle 16%. Mean ISS was 29 (range, 9–50) and mean GCS was 12 (range, 3–15). Fracture patterns included APC ( $n = 57$ ), lateral compression (LC,  $n = 55$ ), vertical shear (VS,  $n = 16$ ), and combined mechanism of injury (CMI,  $n = 5$ ). Thirty-five patients had an acetabulum fracture without pelvic ring injury; all had patterns with fracture of the sciatic buttress and medialization of the affected hemipelvis, consistent with potential injury to adjacent vascular structures.

Over the course of the entire study period, 111 (66%) angiography patients demonstrated CE on CT scan, with an upward trend in CE observed over the years. Prior to 2003, there were more CT scans that were negative for CE than scans that were positive. However, after 2003 we observed more CT scans that were positive for CE than negative (Figs. 1–3).

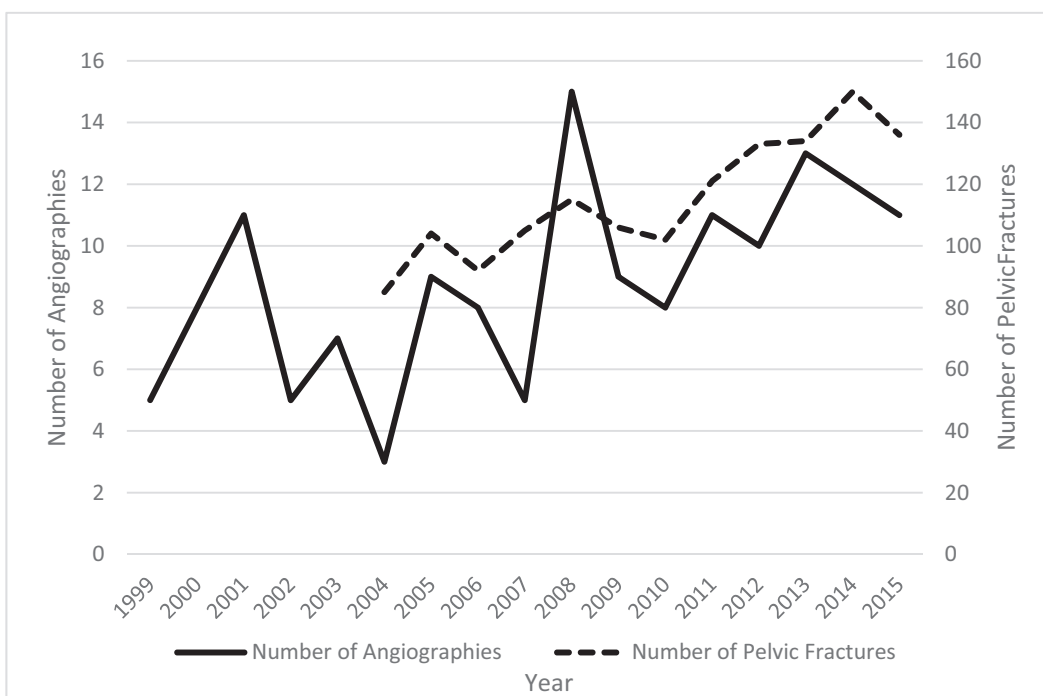
Overall in-hospital mortality was 16%. Mean hospital length of stay (LOS) was 15 days.

Around 72% of all patients presented with hypotension not responsive to resuscitation. Persistent hypotension and in-hospital mortality were both related to finding active bleeding on pelvic angiography ( $P = .001$  and  $0.006$ , respectively) (see Table 1). The mean age of patients with active bleeding on angiography was significantly higher than those with no bleeding seen (55 vs 46 years,  $P = .035$ ). Patients with active bleeding on angiography had higher mean ISS (31 vs 14,  $P = .045$ ) but no differences in GCS, sex, or LOS. No complications or adverse events, directly related to the angiography procedure were identified.

CE on CT was reported in 111 patients (66%), with increasing frequency over the study period. When comparing the patients with and without CE on CT, patients with CE had greater mean age (53 vs 43 years,  $P = .003$ ), lower ISS (28 vs 33,  $P = .049$ ), and a higher GCS (13 vs 11,  $P = .015$ ). Pelvic fracture patients age  $\geq 55$  years were more likely to have CE (84%,  $P < .001$ ).

Age, sex, ISS, GCS, and LOS had no significant relationships with active bleeding in patients without CE. Patients with both CE and active bleeding had a higher mean age at 57 years old ( $P = .048$ ). Interestingly, men were more likely than women to have an angiogram negative for active bleeding despite showing CE on CT scan ( $P = .039$ ). 71% of patients with APC fracture patterns had active bleeding on angiography without having CE on CT ( $P = .004$ ). Hypotension and mortality were both more likely in patients showing both CT blush and active bleeding on angiography ( $P = .016$  and  $P = .003$ , respectively), see Table 2. The presence of CE on CT had no effect on the type of vessel embolized during angiography, or if an intervention was performed at all ( $P = .83$ , Table 3).

Of the patients with CE on CT, the most common mechanisms were MVC, fall from height, and MCC. The 3 most common fracture patterns were APC, LC, and VS. However, we did not observe a correlation between CE and mechanism or fracture pattern (both  $P = .60$ , Table 4).

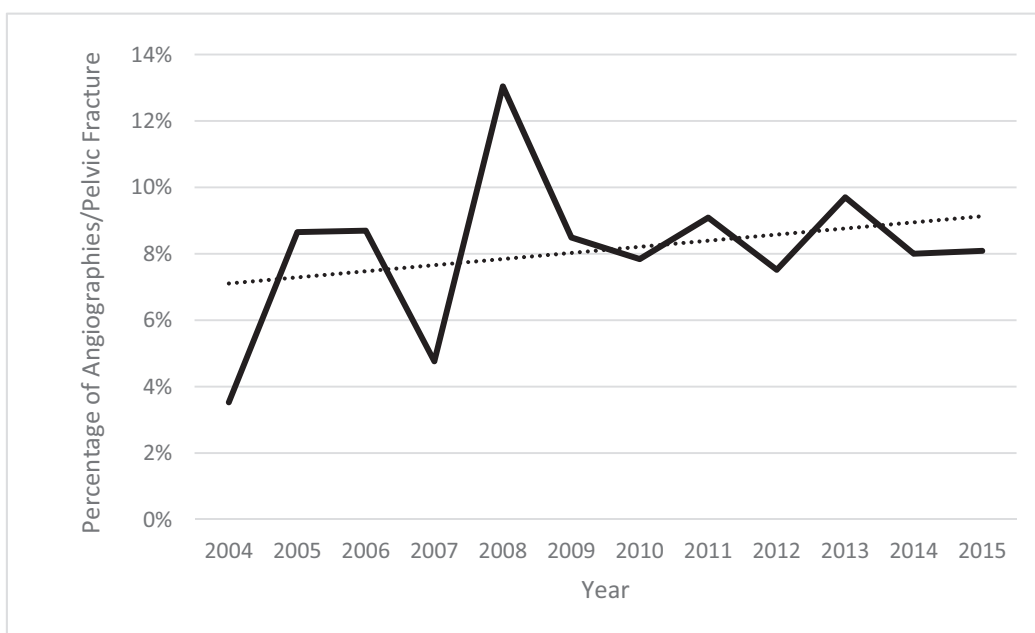


**Figure 1.** Number of patients with pelvis ring injury each year, and number who underwent pelvic angiography. On the left y-axis, the number of pelvic angiographies performed per year in the setting of pelvic trauma were plotted. The right y-axis contains the number of pelvic fractures recorded per year.

CE was analyzed as a predictor of hypotension, active bleeding, or overall mortality. No significant correlations were identified. Sensitivity, specificity, and PPV for CE on CT scan as indicator of active bleeding were 67%, 34%, and 58%, respectively. Hypotension’s sensitivity, specificity, and PPV for predicting an active bleed were all better: 83%, 40%, and 62%, respectively (all  $P < .001$ ). Hypotension also predicted mortality at 97%, 33%, and 25%, respectively (all  $P < .001$ , Table 5).

**Discussion**

CE on CT has been considered an important independent indication for angiography in blunt trauma pelvic fracture patients. At our institution, it is standard practice to obtain a CT scan of pelvis in the setting of pelvic ring injury. In accordance with EAST guidelines, pelvic angiographies may have been performed for CE in pelvic fracture patients, regardless of



**Figure 2.** Ratio of number of pelvis angiographies per pelvic fractures by year.  $R^2$  of line of best fit (dotted line) is 0.0789.

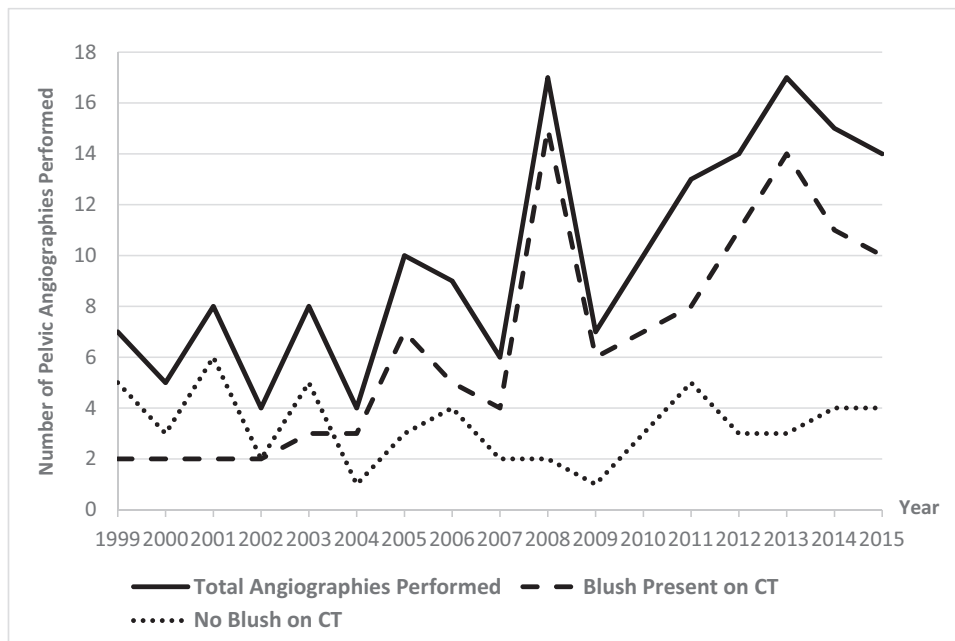


Figure 3. The presence of CE versus number of pelvic angiographies per year.

hemodynamic status.<sup>[5]</sup> However, some studies have suggested CE to have poor sensitivity or PPV for active bleeding during angiography.<sup>[10,15,17]</sup> We sought to investigate the efficacy of CE, or CT blush, in predicting active bleeding on angiography.

CE was noted in 111 (66%) patients, and 118 (73%) presented with hypotension. The patients who had angiography after CE on CT were on average older than age 55 years and less injured, with a lower ISS and higher GCS, than patients without CE. Many of the older patients who underwent angiography for CE were noted to have fractures after low energy fall, frequently with LC-1 pattern, and were unlikely to have active bleeding on angiography.

Not surprisingly, patients with active bleeding on angiography were also on average older, and were *more severely injured*, and more hypotensive than those with no bleeding seen.<sup>[4,9]</sup> This may be due to older patients having weaker, fragile vasculature with

less physiologic reserve. Previous literature suggests differing variables as predictors of active bleeding on angiography. A study by Salim et al,<sup>[8]</sup> found independent predictors of hemorrhage to be duration of hypotension, sacroiliac joint disruption, and female gender. While finding significant correlations, other studies did not identify a single variable that was strong predictor of pelvic fracture-related arterial bleeding, and noted that demographics, mechanism of injury, and fracture pattern had poor predictive value, which is consistent with our findings.<sup>[4,20]</sup> Our study did not find mechanism of injury or fracture pattern alone to be associated with the presence of CT blush. However, there was a discrepancy between CE on CT and angiography, and we noted a significant association between fracture pattern and active bleeding in patients without CE on CT, with 71% of patients with no CT blush yet positive angiography having APC fracture pattern. The majority of APC injuries with active

**Table 1**  
Characteristics of angiography patients.

	All patients (n=189)	CE on CT scan (n=168)		P	Angiography findings (n=187)		P	
		No (n=56)	Yes (n=112)		No bleed (n=84)	Bleed (n=103)		
Mean age, years	49	43	53	.003	46	52	.04	
Age group	Age <55	118 (62%)	45 (80%)	56 (50%)	<.001	57 (68%)	60 (58%)	.18
	Age ≥55	71	11	56		27	43	
Sex	Male	121 (64%)	38 (68%)	73 (65%)	.73	54 (64%)	67 (65%)	.91
	Female	68	18	39		30	36	
Mean ISS	29	33	28	<.05	27	31	<.05	
Mean GCS	12	11	13	.015	12	12	.36	
LOS	15	15	16	.72	15	16	.65	
Hypotension	No	45 (27%)	9 (20%)	29 (29%)	.25	30 (40%)	15 (17%)	.001
	Yes	118	37	73		45	73	
In-hospital mortality	31 (16%)	9 (16%)	18 (16%)	.008	7 (8.3%)	24 (23%)	.006	

Percentages represent the percent of patients in that column with that feature. Patients are described regarding presence or absence of CE on pelvis CT scan, and by presence of active bleeding on pelvic angiography.

**Table 2**  
Demographics versus CE on CT and angiography findings.

	No CE (n=56)			CE on CT (n=112)		
	No bleeding (n=24)	Active bleeding (n=32)	P	No bleeding (n=47)	Active bleeding (n=64)	P
Mean age, years	42	44	.46	48	57	.048
Age group	Age <55	20 (83%)	.63	27 (57%)	29 (45%)	.400
	Age ≥55	4		20	35	
Sex	Male	14 (17%)	.19	36 (77%)	37 (58%)	.039
	Female	10		11	27	
ISS	29	35	.36	26	29	.18
GCS	11	11	.68	13	13	.65
LOS	15	15	.59	15	16	.48
Young–Burgess	APC	3 (16%)	.004	13 (37%)	24 (44%)	.82
	LC	11 (58%)		5 (21%)	23 (43%)	
	VS	4 (21%)		2 (8%)	5 (9%)	
	CMI	1 (5%)		0 (0%)	2 (4%)	
Hypotension	No	6 (29%)	.16	18 (41%)	11 (19%)	.016
	Yes	15		26	47	
Mortality	4 (17%)	5 (16%)		2 (4.3%)	16 (25%)	.003

Percentages represent the percent of patients in that column with that feature. Patients are first described regarding presence or absence of CE on pelvis CT scan, and then categorized further by presence of active bleeding on pelvic angiography.

**Table 3**  
CT blush versus angiographic intervention performed.

Arterial embolization	CT blush		P value
	No N (%)	Yes N (%)	
No bleeding seen	24 (43%)	46 (41%)	.83
Nonspecific embolization and unnamed vessels	11 (20%)	26 (23%)	
Embolization of named artery	20 (36%)	35 (32%)	
Death*	1 (2%)	4 (4%)	
Total	56 (34%)	111 (66%)	

\* Patients expired during pelvic angiography procedure.

**Table 4**  
Presence of CT blush by mechanism of injury and fracture pattern as classified by Young and Burgess.

	All Patients N	CT Blush				P value
		No		Yes		
		N	%	N	%	
Mechanism						
MVC	52	20	39%	32	62%	.58
MCC	27	8	30%	19	70%	
Pedestrian MVC	29	12	41%	17	59%	
High-energy fall	26	6	23%	20	77%	
Low-energy fall	18	4	22%	14	78%	
Industrial injury	8	2	25%	6	75%	
GSW	3	1	33%	2	67%	
Other	5	3	60%	2	40%	
Fracture pattern						
APC	57	20	35%	37	65%	.55
LC	55	16	29%	39	71%	
VS	16	6	38%	10	63%	
CMI	5	1	20%	4	80%	
No pelvis fracture	35	13	37%	22	63%	

**Table 5**  
**Accuracy of admission characteristics as predictive factors.**

	Sensitivity	Specificity	PPV	P value
Contrast blush at predicting:				
Active bleeding	67%	34%	58%	.95
Mortality	67%	33%	16%	1.0
Hypotension	76%	34%	28%	.25
Hypotension at predicting:				
Active bleeding	83%	40%	62%	.001
Mortality	97%	33%	25%	.001
Contrast blush	72%	20%	66%	.25
Age > 55 at predicting:				
Active bleeding	42%	68%	61%	.18
Mortality	39%	63%	17%	.89
Contrast blush	50%	80%	84%	<.0001
Hypotension	43%	69%	79%	.16

bleeding on angiography were APC-3, suggesting posterior pelvic ring displacement is more likely associated with arterial injury, which is consistent with prior reports.<sup>[3,4,8]</sup>

The presence or absence of CT blush had no association with the angiographic findings or intervention, in terms of embolization of named or unnamed vessels. We next investigated if CE was a predictor of positive angiography in our patient cohort. In our study, the sensitivity was 67%, specificity was 34%, and PPV was 58%. Several studies have reported variable but somewhat promising sensitivity, specificity, PPV, and negative predictive value (NPV) for CT blush.<sup>[5,12,21]</sup> In addition, a recent study that proposes a predictive score of massive hemorrhage in pelvic ring fractures utilizes pelvic CE on CT as the most weighted risk factor.<sup>[22]</sup>

Other studies question the efficacy of CT blush with lower PPV but emphasize a high specificity and NPV.<sup>[10,15]</sup> Juern and colleagues<sup>[15]</sup> showed the sensitivity, specificity, positive predictive value, and negative predictive value of CE on CT were 100%, 88%, 23%, and 100%, respectively. While some other studies show both higher and lower therapeutic rates, a recent paper by Tesoriero et al,<sup>[23]</sup> with a similar number of patients, showed only 8% undergoing angiography, with 56% having therapeutic embolization.<sup>[1,7,12,13,23]</sup> Similarly, our study's overall therapeutic embolization rate over the study period in patients who underwent CT before angiography was 59%. Alternatively, hypotension had a higher sensitivity and PPV, at 83% and 62%, respectively, than CE. This information, along with the CE and angiography discrepancies, suggest that CE is not as useful of an independent predictor of arterial hemorrhage in pelvic fracture patients as previously contended, and may not be sufficient as the sole indication for pelvic angiography.

Over the course of the study period, there was an increase in number of angiographies performed per year, as well as a higher proportion of CE detected on CT scans after 2004, contrary to another study.<sup>[15]</sup> The possible explanations include utilization of a more sensitive CT scanner with better resolution, detecting more CE. Our hospital had the same brand and model of CT scanners during the 1999 to 2011 time period, although another CT scanner with reportedly better resolution was added in 2011. Scanning thicknesses for pelvic protocols were the same throughout the study period, and both old and new CT units were used. We were not able to identify which scans were performed on which scanner, which is a weakness of this study. Alternatively, with increasing attention to the CE phenomenon, radiologists may have become more attentive to possible

extravasation. Newer radiologists employed during that time frame may have a different threshold as to what they describe as extravasation. We are unable to provide an objective measurement of the volume of hemorrhage denoted by CE on CT scan.

More recently, physicians may also be ordering more CT scans rather than plain films to evaluate elderly patients with low-energy fractures. With a higher percentage of patients getting CTs we could be noticing a higher number of CT scans with CE, and therefore more resultant angiographies. Because of the retrospective design of this study, it is subject to other inherent limitations and biases. Another limitation of our study is that we were unable to accurately calculate the NPV, as we were unable to identify all patients with negative CT blush who did not undergo angiography. Nor were we able to determine the total number of patients who had some hypotension in association with pelvic ring injury. The primary focus of this study was to determine if the presence of CT blush would be a good indicator of active bleeding on angiography, therefore emphasizing sensitivity and PPV. Furthermore, there was no set treatment protocol for these pelvic fracture patients, as the decision for angiography was at the attending trauma surgeon's discretion.

## Conclusion

Over the study period, there was an increasing trend in number of CT CE reported. CE (or CT blush) was neither a sensitive nor specific predictor of active bleeding on pelvic angiography in the setting of pelvic trauma. Alternatively, hypotension was a better indicator for pelvic angiography, with a sensitivity of 83% for active bleeding compared to 67% for CE. Our findings suggest that CE is not independently a sufficient indication for pelvic angiography. CE may present more often in older patients with less clinically alarming sources of arterial bleeding. Avoiding pelvic angiography when CT blush is the only indication would prevent unnecessary interventions, reduce costs, and ease patient burden.

## Acknowledgments

The authors would like to thank Mary Breslin for editorial assistance.

## References

1. Costantini TW, Coimbra R, Holcomb JB, et al. Current management of hemorrhage from severe pelvic fractures: results of an American Association for the Surgery of Trauma multi-institutional trial. *J Trauma Acute Care Surg.* 2016;80:717-723.
2. Black SR, Sathy AK, Jo C, et al. Improved survival after pelvic fracture: 13-year experience at a single trauma center using a multidisciplinary institutional protocol. *J Orthop Trauma.* 2016;30:22-28.
3. Gabbe BJ, de Steiger R, Esser M, et al. Predictors of mortality following severe pelvic ring fracture: results of a population-based study. *Injury.* 2011;42:985-991.
4. Toth L, King KL, McGrath B, et al. Factors associated with pelvic fracture-related arterial bleeding during trauma resuscitation: a prospective clinical study. *J Orthop Trauma.* 2014;28:489-495.
5. Cullinane DC, Schiller HJ, Zielinski MD, et al. Eastern Association for the Surgery of Trauma practice management guidelines for hemorrhage in pelvic fracture—update and systematic review. *J Trauma.* 2011;71:1850-1868.
6. Karadimas EJ, Nicolson T, Kakagia DD, et al. Angiographic embolisation of pelvic ring injuries. Treatment algorithm and review of the literature. *Int Orthop.* 2011;35:1381-1390.
7. Brown CV, Kasotakis G, Wilcox A, et al. Does pelvic hematoma on admission computed tomography predict active bleeding at angiography for pelvic fracture? *Am Surg.* 2005;71:759-762.

8. Salim A, Teixeira PG, DuBose J, et al. Predictors of positive angiography in pelvic fractures: a prospective study. *J Am Coll Surg.* 2008;207:656–662.
9. Bozeman MC, Cannon RM, Trombold JM, et al. Use of computed tomography findings and contrast extravasation in predicting the need for embolization with pelvic fractures. *Am Surg.* 2012;78:825–830.
10. Miller PR, Moore PS, Mansell E, et al. External fixation or arteriogram in bleeding pelvic fracture: initial therapy guided by markers of arterial hemorrhage. *J Trauma.* 2003;54:437–443.
11. Yoon W, Kim JK, Jeong YY, et al. Pelvic arterial hemorrhage in patients with pelvic fractures: detection with contrast-enhanced CT. *Radiographics.* 2004;24:1591–1605.
12. Cerva DSJr, Mirvis SE, Shanmuganathan K, et al. Detection of bleeding in patients with major pelvic fractures: value of contrast-enhanced CT. *AJR Am J Roentgenol.* 1996;166:131–135.
13. Brasel KJ, Pham K, Yang H, et al. Significance of contrast extravasation in patients with pelvic fracture. *J Trauma.* 2007;62:1149–1152.
14. Diamond IR, Hamilton PA, Garber AB, et al. Extravasation of intravenous computed tomography scan contrast in blunt abdominal and pelvic trauma. *J Trauma.* 2009;66:1102–1107.
15. Juern JS, Milia D, Codner P, et al. Clinical significance of computed tomography contrast extravasation in blunt trauma patients with a pelvic fracture. *J Trauma Acute Care Surg.* 2017;82:138–140.
16. Michailidou M, Velmahos GC, van der Wilden GM, et al. Blush” on trauma computed tomography: not as bad as we think!. *J Trauma Acute Care Surg.* 2012;73:580–584.
17. Verbeek DO, Zijlstra IA, van der Leij C, et al. Management of pelvic ring fracture patients with a pelvic “blush” on early computed tomography. *J Trauma Acute Care Surg.* 2014;76:374–379.
18. Young JW, Burgess AR, Brumback RJ, et al. Pelvic fractures: value of plain radiography in early assessment and management. *Radiology.* 1986;160:445–451.
19. Marsh JL, Slongo TF, Agel J, et al. Fracture and dislocation classification compendium -2007: Orthopaedic Trauma Association classification, database and outcomes committee. *J Orthop Trauma.* 2007;21:S1–133.
20. Sarin EL, Moore JB, Moore EE, et al. Pelvic fracture pattern does not always predict the need for urgent embolization. *J Trauma.* 2005;58:973–977.
21. Anandakumar V, Hussein FK, Varuun B, et al. Predictive parameters for angiography and embolization in the bleeding pelvic fracture. *J Clin Orthop Trauma.* 2013;4:70–74.
22. Ohmori T, Matsumoto T, Kitamura T, et al. Scoring system to predict hemorrhage in pelvic ring fracture. *Orthop Traumatol Surg Res.* 2016;102:1023–1028.
23. Tesoriero RB, Bruns BR, Narayan M, et al. Angiographic embolization for hemorrhage following pelvic fracture: is it “time” for a paradigm shift? *J Trauma Acute Care Surg.* 2017;82:18–26.