

CASE REPORT

# An unusual presentation of filariasis in a nonendemic country

Parampil Thulasidharan Shibu Kandalam<sup>1</sup>, Arif Nellyyulla Parampath<sup>2</sup>, Hanan Ibrahim Farghaly<sup>3</sup>, Salem Abo Salah<sup>1</sup>, Muhammed Kunhi Kayakkool<sup>1</sup>, Joe Varghese Mathew<sup>1</sup>, Pradeep Radhakrishnan<sup>1</sup>, Ibrahim Al Badawi<sup>1</sup>, Saleena Farook<sup>4</sup>

Address for Correspondence:

**Parampil Thulasidharan Shibu Kandalam**

<sup>1</sup>Emergency Department Short Stay Unit, Hamad General Hospital, Hamad Medical Corporation, Doha, Qatar

<sup>2</sup>Department of Radiology, Emergency Radiology Section, Hamad General Hospital, Hamad Medical Corporation, Doha, Qatar

<sup>3</sup>Department of Laboratory Medicine, Pathology Section, Hamad General Hospital, Doha, Qatar

<sup>4</sup>Department of Medicine, Hamad General Hospital, Hamad Medical Corporation, Doha, Qatar

Email: shibudoc@yahoo.co.in; pkandalam@hamad.qa

<http://dx.doi.org/10.5339/qmj.2015.17>

Submitted: 1 June 2015

Accepted: 23 December 2015

© 2015 Shibu Kandalam, Parampath, Farghaly, Salah, Kayakkool, Mathew, Radhakrishnan, Al Badawi, Farook, licensee Bloomsbury Qatar Foundation Journals. This is an open access article distributed under the terms of the Creative Commons Attribution license CC BY 4.0, which permits unrestricted use, distribution and reproduction in any medium, provided the original work is properly cited

Cite this article as: Shibu Kandalam PT, Parampath AN, Farghaly HI, Salah SA, Kayakkool MK, Mathew JV, Radhakrishnan P, Al Badawi I, Farook S. An unusual presentation of filariasis in a nonendemic country, Qatar Medical Journal 2015;17 <http://dx.doi.org/10.5339/qmj.2015.17>

## ABSTRACT

**Introduction:** Filariasis is an endemic disease with worldwide distribution in tropical and subtropical regions. It is uncommon in Qatar. The conventional diagnostic procedure is the demonstration of microfilaria in blood smears. Even with its high incidence, it is unusual to detect microfilaria in fine needle aspiration cytology (FNAC) smears. Although the 'filarial dance sign' is rarely documented, it remains a classical ultrasonographic sign in lymphatic filariasis. **Case presentation:** We present a case of a 38-year-old male patient with fever, chills, shortness of breath and a tender warm swelling on his right thigh. Ultrasound of the thigh lesion showed the classical filarial dance sign. Subsequently FNAC from the lesion documented microfilaria in spite of absent peripheral blood eosinophilia and microfilaria. The patient underwent an incision and drainage of the thigh lesion and was treated with ivermectin and diethylcarbamazine. He was subsequently admitted to the medical ward and discharged home after two weeks in a stable condition.

**Conclusion:** This case report illustrates the importance of diagnostic tools like ultrasound and FNAC along with a high index of clinical suspicion while evaluating patients presenting with unusual signs and symptoms. We would like to highlight the rarity of filarial presentation in a nonendemic country like Qatar. This case is unique since microfilaria was demonstrated in the pus aspirated from the thigh abscess and showed the filarial dance sign by ultrasound along with involvement of the pleura and pericardium.

**Keywords:** microfilariae, filarial dance sign, Wuchereria bancrofti, FNAC, Diff-Quick stain

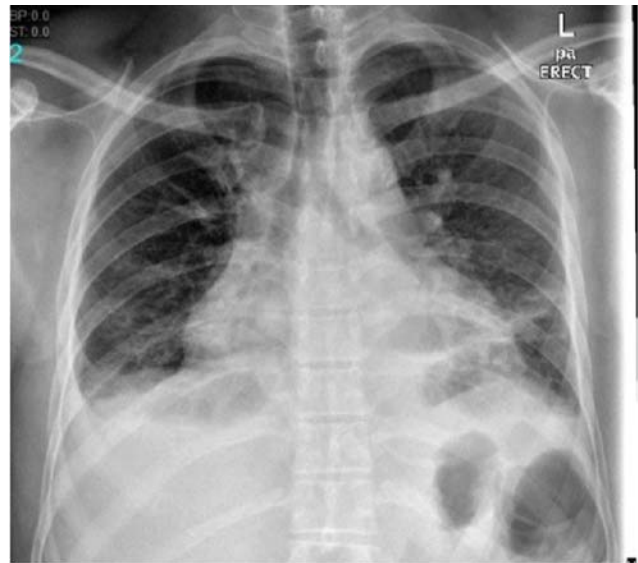
## INTRODUCTION

Filariasis is an endemic disease in tropical and subtropical regions affecting nearly 120 million people worldwide.<sup>1,2,3,4</sup> In developing countries, filariasis is still a major public health problem. It is uncommon in Qatar.<sup>2</sup> The conventional diagnostic procedure is for the demonstration of microfilaria in peripheral blood smears.<sup>5</sup> Even though incidence is high, it is unusual to detect microfilaria in fine needle aspiration cytology (FNAC) smears. Incidental demonstration of microfilariae in fine needle aspirates of different types of lesions have been reported earlier and most of the cases were clinically unsuspected with no microfilariae detected in the peripheral blood.<sup>2,3,4,5</sup> Although the "filarial dance sign"<sup>7,8</sup> is rarely documented, it remains as a classical ultrasonographic sign in lymphatic filariasis. To detect and demonstrate live adult worms of *Wuchereria bancrofti* in the lymphatics, we can use ultrasound scan (B mode or M mode) with or without pulse wave Doppler or colour Doppler.<sup>7,8</sup> Clinical presentations vary a lot and in the majority of cases the disease is usually seen as an incidental finding. Symptomatic patients may present with lymphoedema of different areas of the body or repeated attacks of acute lymphangio-adenitis or dermatolymphangio-adenitis. Lymph vessels are the habitat of the adult worms and the first change in lymphatic filariasis is usually dilation of these vessels which in turn leads to lymphatic dysfunction. The manifestations of these changes leads to lower limb lymphoedema, chyluria, hydrocoele, lymphadenovariex and rarely as soft tissue lesions.<sup>4,5,10,11</sup>

The reason for reporting this case is the rarity of filariasis presentation as an isolated soft tissue inflammatory swelling with absence of microfilariae and eosinophilia in peripheral blood smear. The first clue to diagnosis was the presence of the filarial dance sign. This case strongly recommends the importance of routine fine needle aspiration cytology in the diagnosis of clinically unsuspected cases of bancroftian filariasis especially with unexplained lymphangitis and lymphadenitis.

## CASE REPORT

A 38-year-old male Indian patient working in Qatar for the last two years presented to Hamad General Hospital Emergency Department (ED) in September 2014 with history of fever, a painful swelling on the right thigh and cough with shortness of breath for five



**Figure 1. Chest X-ray shows minimal bilateral pleural effusion, lower zone pulmonary infiltrates and cardiomegaly.**

days. He was unable to lie flat on the bed. Six days prior to his present visit, he attended the ED for a small abscess on his right arm below the elbow joint for which he underwent an incision and drainage and was discharged with amoxicillin and clavulanic acid which he continued till the present visit.

On examination he was of normal build, febrile 38.2°C, dyspneic with a respiratory rate of 24 per minute and a blood pressure of 116/82 mm Hg. He was orthopneic and hypoxemic with room air oxygen saturation of 92%. Chest examination showed bilateral infrascapular (basal) crepitations. His right thigh had a swelling of 5 × 3 cm which was indurated, tender and warm. Chest X-ray revealed bilateral minimal pleural effusion, lower zone pulmonary infiltrates and cardiomegaly (Figure 1). An ultrasound was ordered and showed an ill-defined hypoechoic area involving the muscular as well as the subcutaneous plane of the proximal thigh approximately measuring 4 × 2.3 cm.

### Ultrasound findings

Serpiginous echogenic structures showing peculiar movements were noted in the inflamed area, which was recognized as the 'filarial dance sign'<sup>7,8</sup> (Figures 2 & 3).

The patient was then admitted to the Emergency Department Short Stay Unit which is an acute medical unit. A peripheral blood smear did not show the presence of eosinophilia (0.5% only). Nocturnal

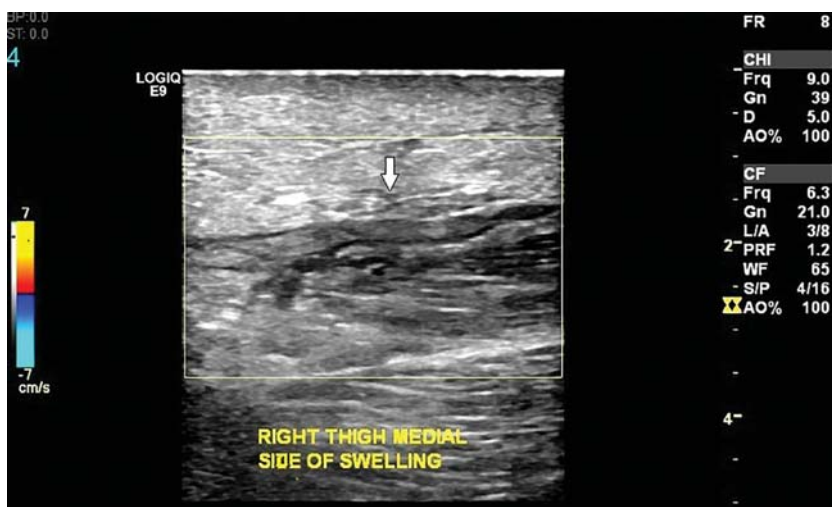

Figure 2. Ultrasound scan of the right thigh swelling showing hypoechoic area of inflammation with serpiginous echogenic structures (arrow).

peripheral blood smears did not show any microfilaria. He was treated as having inflammation of the thigh soft tissue possibly due to filaria with involvement of the lung and pleura. A single stat dose of ivermectin 6 mg was given on day one. Echo done showed mild global hypokinesia with 45% ejection fraction and mild to moderate pericardial effusion. He also received intravenous furosemide every eight hours. A fine needle aspiration (FNA) was taken under ultrasound guidance from the right thigh inflammatory area and it revealed microfilaria.<sup>9</sup> He underwent an incision and drainage of the thigh lesion the next day. His total immunoglobulin E (IgE) was found to be 625 Ku/l (normal range 0-114 Ku/l). His pleural fluid was tapped and showed transudate and was negative for

microfilaria and tubercular PCR. He received diethyl-carbamazine (DEC) 6 mg/kg twice daily for two weeks. He was later admitted to the medical unit and was subsequently discharged on the seventeenth day. He had undergone computerized tomography of the chest and abdomen during his stay in the medical ward, which showed pleural and pericardial effusions. His fever subsided after five days of admission. His pleural effusion resolved and pulmonary infiltrates improved as was evident in the chest X-ray before discharge (Figure 4). His respiratory rate improved to 18 per minute with no dyspnea or orthopnea at the time of discharge. Doxycycline 100 mg tablet twice orally per day for four weeks was prescribed on discharge.

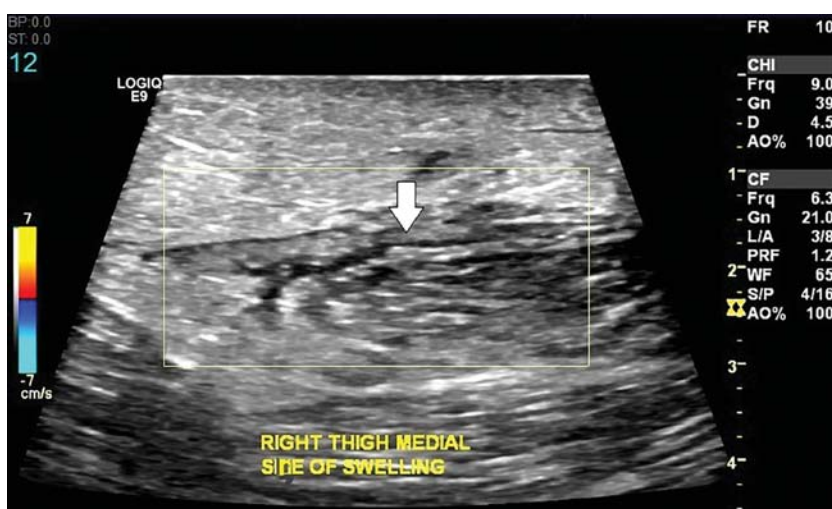


Figure 3. Ultrasound scan of the right thigh swelling showing hypoechoic area of inflammation with serpiginous echogenic structures (arrow).

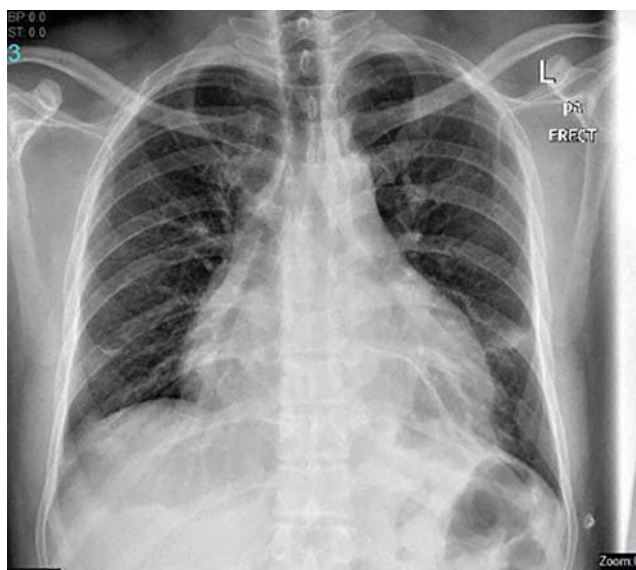

Figure 4. Chest X-ray before discharge shows good resolution of the bilateral pleural effusion and pulmonary infiltrates.

### Fine needle aspiration cytology<sup>9</sup>

Cyst content was aspirated by the clinical team and air-dried smears were prepared. The needle rinse was collected in a container. The smears were stained by Diff-Quick stain and the rinse was processed for cell block.

### RESULTS

Microscopic examination of cytology smears revealed microfilaria of *Wuchereria bancrofti* in a background of acute inflammatory cells aggregates. The microfilaria

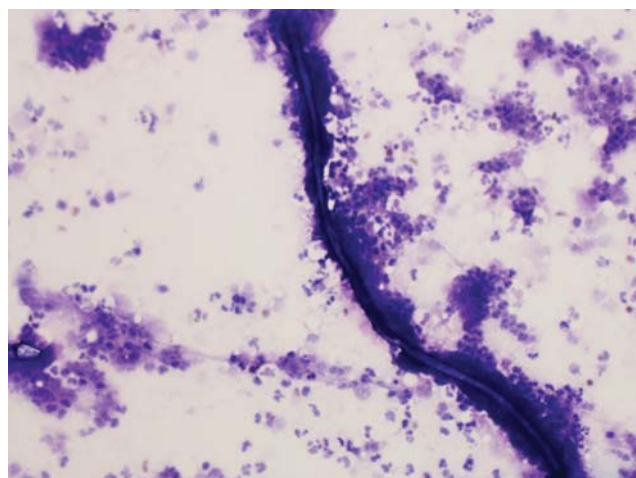


Figure 5. Diff-Quick cytology smear shows microfilaria of *Wuchereria bancrofti* in a background of acute inflammatory cells (20X).

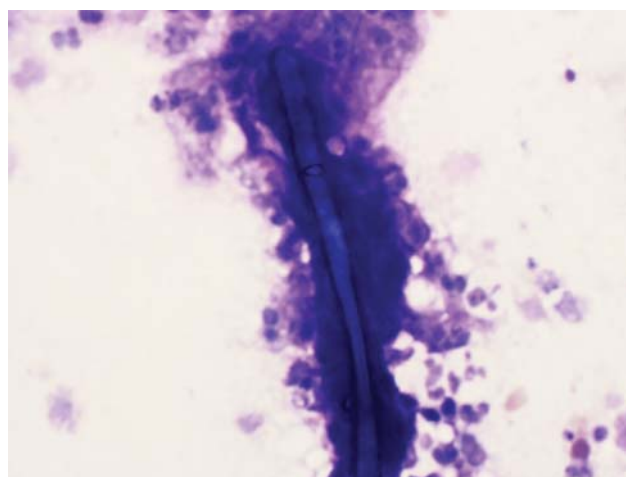


Figure 6. Diff-Quick cytology smear shows microfilaria of *Wuchereria bancrofti* with one end of the round body is blunt, while the other is pointed (60X).

morphology is sheathed, and measures approximately 250  $\mu\text{m}$ . One end of the round body is blunt, while the other is pointed. The diagnosis of microfilaria of *Wuchereria bancrofti* was made (Figures 5 & 6).

### DISCUSSION

Filariasis is seen in tropical and subtropical countries and is a vector-borne disease due to infection by filarial worms which infects and spread through the human lymphatic system.<sup>1,2,3,4</sup> *Wuchereria bancrofti* is the most common cause (90%) of lymphatic filariasis. The confirmation of existence of adult worms is by demonstrating microfilariae or by an antigen test in the patient's blood.<sup>6</sup> To detect and demonstrate live adult worms of *W. bancrofti* in the lymphatics, ultrasound scan (B mode or M mode) with or without pulse wave Doppler or colour Doppler (Filarial dance sign)<sup>7,8</sup> can be used. Microscopic examination of fine needle aspirates can be used to demonstrate and detect microfilariae.<sup>9</sup> Aspirates from lymph nodes, scrotal lymphatics, hydrocoele fluid, breast masses, thyroid, soft tissue swellings, pleural, pericardial, ascitic and joint fluids have demonstrated microfilariae.<sup>1,2,3,4,5,9</sup> The diagnosis of filariasis can be easily missed if physicians are unaware of its possible presence, especially in cases where presentation is atypical and unusual with absent tissue or blood eosinophilia. In this case we illustrated the value of ultrasonography and FNAC along with a high index of clinical suspicion in evaluating a patient who presented with a soft tissue swelling on his thigh along with features of pulmonary involvement as well as



pleuropericardial effusions. The rarity of filarial presentation in a nonendemic country like Qatar and its diagnosis with the help of invasive and noninvasive diagnostic interventions are thus highlighted in this case report.<sup>2</sup> This case demonstrated the presence of microfilaria in pus aspirated from the thigh abscess in the absence of live adult worms. The filarial dance sign was demonstrated by ultrasound in the soft tissue inflammatory thigh swelling and polyserositis involving pleura and pericardium were also confirmed by computerized tomography and echocardiography. This is a rare case report of filarial infection as only one case has previously been reported from Qatar.<sup>2</sup>

## CONCLUSION

Due to increasing travel and migration of people from endemic countries to nonendemic areas, physicians

should be aware of such unusual presentations of filariasis. This case report illustrated the importance of diagnostic tools such as ultrasound and FNAC along with a high index of clinical suspicion while evaluating patients presenting with dilated lymphatics, subcutaneous nodules or similar soft tissue lesions

## ACKNOWLEDGEMENTS

We are greatly thankful to Hamad Medical Corporation Medical Research Center for the approval of this report. We are also grateful to the laboratory staff of Hamad General Hospital Pathology and Microbiology Department for their great cooperation. We are also thankful to the Section of Infectious Disease in Hamad General Hospital for their guidance in pharmacological management.

## REFERENCES

1. Belokar WK, De Sa OO, Amonkar DP, Dharwadkar AM, Priolkar RP. Uncommon manifestations of filariasis. *JPGM*. 1983;29:170–174B.
2. Al Bozom I, Koshy SM, Mahdi H, Abdullah MF, Bedair EM. Retroperitoneal filariasis diagnosed by fine needle aspiration: A case report. *Acta Cytol*. 2010;54(3):325–327.
3. Haleem A, Al Juboury M, Al Hussein H. Filariasis: A report of three cases. *Ann Saudi Medicine*. 2002;22(1-2):77–79.
4. Eswari V, Sekhar G, Ansari IA, Rajeswari K, Prakash G, Srivatsa P. Axillary mass – An unusual presentation of filariasis. *Bombay Hosp J*. 2010;52(4):470–472. <http://www.bhj.org.in/journal/2010-5204-oct/download/pg470-472.pdf>
5. Basu A, Sistla SC, Verma SK, Jagdish S. Lymphadenovariex in the axilla – an unusual presentation of filariasis. *Filaria J*. 2006;30:5:9. <http://www.filariajournal.com/content/5/1/9>
6. Chandrashekar R. Recent advances in diagnosis of filarial infections. *Indian J Exp Biol*. 1997;35(1):18–26.
7. Chaubal NG, Pradhan GM, Chaubal JN, Ramani SK. Dance of live adult filarial worms is a reliable sign of scrotal filarial infection. *J Ultrasound Med*. 2003;22:765–769.
8. Chew LL, Teh HS. The filarial dance sign in scrotal filarial infection: A case report. *J Clin Ultrasound*. 2013;41(6):377–379.
9. Sivakumar S. Role of fine needle aspiration cytology in detection of microfilariae: Report of 2 cases. *Acta Cytol*. 2007;51:803–806.
10. Dreyer G, Addiss D, Roberts J, Noroes J. Progression of lymphatic vessel dilatation in the presence of living adult *Wuchereria bancrofti*. *Trans R Soc Trop Med Hyg*. 2002;96:157–161.
11. Sen SB, Chatterjee H, Ramaprasad S. Chylous manifestations of filariasis: A clinical and lymphographic study. Part II. Lymphadenovariex, chylocele and chylous scrotum. *Ind Jour Med Res*. 1969;57:1738–1744.