

## Kidney angiomyolipoma in pregnancy

Krzysztof Tupikowski<sup>1</sup>, Aleksander Biały<sup>2</sup>, Janusz Dembowski<sup>1</sup>, Monika Złotkiewicz<sup>2</sup>, Maciej Guziński<sup>3</sup>, Anna Karina Kołodziej<sup>1</sup>, Romuald Zdrojowy<sup>1</sup>

<sup>1</sup>Department of Urology and Oncological Urology, Wrocław Medical University, Wrocław, Poland

<sup>2</sup>Department of Urology and Oncological Urology, University Clinical Hospital in Wrocław, Wrocław, Poland

<sup>3</sup>Department of General Radiology, Interventional Radiology and Neuroradiology, Wrocław Medical University, Wrocław, Poland

### Article history

Submitted: June 23, 2013

Accepted: Nov. 6, 2013

### Correspondence

Krzysztof Tupikowski

Department of Urology and

Oncological Urology

213, Borowska Street

50–556 Wrocław, Poland

phone: +48 71 733 10 10

krzysztof.tupikowski@umed.wroc.pl

Neoplasms are rare in pregnant women, however they are always a challenging diagnostic and curative problem. We present a case of a benign kidney tumor (angiomyolipoma) imitating nephroblastoma on magnetic resonance diagnosed in pregnancy. Cesarean section was performed in 29. gestotic week followed immediately by right radical nephrectomy.

**Key Words:** kidney tumor ◊ pregnancy ◊ angiomyolipoma ◊ nephrectomy

## INTRODUCTION

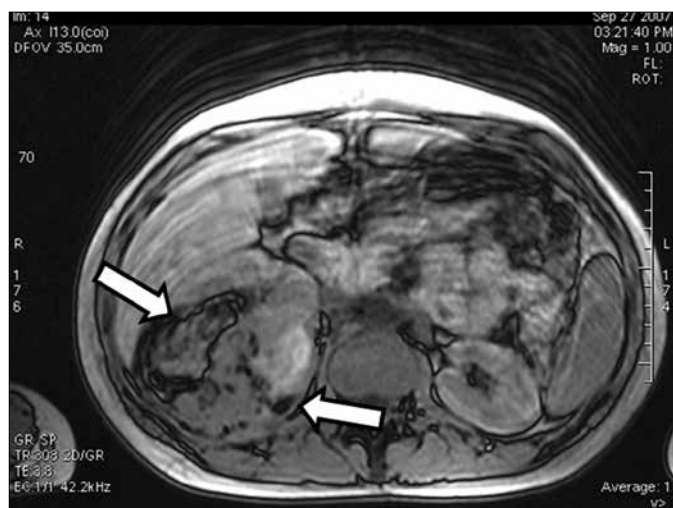
Neoplasms are rare findings in pregnant women. Only several cases of kidney tumors in pregnancy were described in Polish medical literature [1–4] and approximately 200 in the world. Here we present this rare entity – kidney tumor found in a pregnant woman.

## CASE REPORT

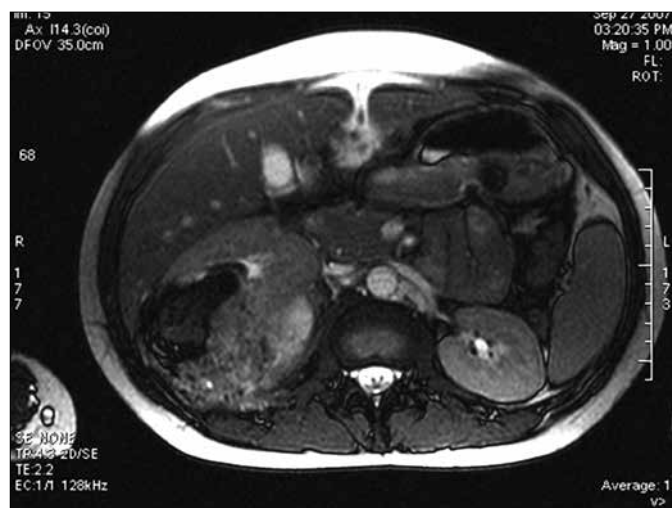A 25-year-old 16-week gravida (second pregnancy, second birth) was admitted to the gynecological ward because of acute right lumbar pain. Physical examination on admission revealed tenderness in the right lower abdominal quadrant without evident peritoneal signs and positive right Goldflamm sign. Serum C-reactive protein was elevated up to 229.1 mg/l with accompanying leucocytosis of 19.69 G/l, low hemoglobin concentration – 9.6 g/l and elevated urinary ketonic bodies. On ultrasound (US), a heterogenous right renal mass 72 x 33 mm was discovered. No signs of invasion of adjacent tissues was visible. The fetal US did not display any pathological

findings. After 3 weeks and cessation of symptoms, she was transferred to the obstetrics and neonatology ward. Initially conservative management was advised, because of young fetal age and high surgical risk.

An MRI in the 25th week showed rapid growth of the tumor with measurements 90 x 77 mm. A polycystic tumor with multiple thick-walled cysts with inhomogeneous contents and signs of fresh intracystic bleedings in some cysts was closely adherent to the liver and right lumbar muscle but was without signs of local invasion (Figure 1 and Figure 2). An India ink artifact was visible, which pointed to angiomyolipoma (AML), but rapid growth and the patients young age led to the conclusion that a polycystic nephroblastoma can not be excluded. The patient declined percutaneous biopsy and opted for primary surgery. Premature termination of pregnancy was advised because of the suspected life threatening renal tumor. Under general anesthesia in the 29th gestotic week a premature girl was born through cesarean section. Her body weight was 1290 g, with Apgar score of – 7. Right radical nephrectomy through subcostal incision followed immediately afterwards.



**Figure 1.** MRI of abdomen, axial opposed-phase T1-weighted MR image (TR/TE, 308/3.3) shows 9 cm mass in upper pole of right kidney. India ink artifact (arrows) is present at interface of renal mass with kidney. Most AMLs contain macroscopic fat, the India ink artifact appears at all interfaces of the tumor with the kidney or at the interfaces of the fatty and nonfatty portions of the mass. Other renal masses do not contain macroscopic fat; for that reason, the India ink artifact appears at the interface of the renal mass with perinephric fat when the mass is exophytic. Thus, the diagnosis of AML is indicated when the India ink artifact is present at a renal mass–kidney interface or within a renal mass.



**Figure 2.** MRI of abdomen, axial T2-weighted MR image (TR/TE, 4,3/2.2) shows 9 cm mass in upper pole of right kidney. The different signal of tumor and signs of bleeding product and smooth muscle/fat.

The whole tumor has been excised within macroscopic healthy borders. The mother's postoperative course was uneventful. Histopathology revealed angiomyolipoma.

Two days after birth sepsis was diagnosed in the baby. Blood cultures were positive for methicillin resistant and coagulase negative *Staphylococcus epidermidis*. Ultrasound of the brain demonstrated intraventricular bleeding and brain echostructure shading. Targeted treatment with teicoplanine was efficient and the newborn has left the incubator 4 weeks after birth. 30 months after birth mother is well and without local recurrence nor new lesions in contralateral kidney. The baby has been diagnosed with mild cerebral palsy and is being rehabilitated.

## DISCUSSION

Neoplasms are rare findings in pregnant women. Only several cases of kidney tumors in pregnancy have been described in Polish medical literature [1–4] and approximately 200 in the world. Pregnant women with tumors are rare patients but the incidence of tumors in pregnancy is probably rising. Several facts can facilitate that speculation: firstly, the mean age of pregnant women is rising. Secondly, the

general incidence of malignancies is rising, thirdly, advanced diagnostic means especially prenatal ultrasound discover asymptomatic tumors. These would otherwise be discovered later in the course of life of the expecting mother, or would never be discovered at all if they remained symptomless. No exact data exists to support or discard this theory.

Many tumors in pregnancy manifest in our patients as pain on either flank, with abdominal or colic-like character. Many patients also present with haematuria or other symptoms like arterial hypertension. Only rarely can a classical kidney tumor triad (flank pain, haematuria, palpable mass) be observed [5]. It is feasible that nowadays many tumors can be discovered at an early stage or before first clinical symptoms present themselves, as in several described patients [4, 6, 7, 8]. It is possible that the tumor in our patient might have been discovered before symptoms occurred and endangered the pregnancy, as she has had the US in first trimester. The baby was born with cerebral palsy and one of potential risk factors is the maternal inflammatory process which was present in this case [9]. It is possible that early diagnosis of this tumor might have led to a better outcome for the child if the mother was operated on earlier in her pregnancy or even before becoming pregnant. This fact underlines in our opinion the necessity and usefulness of abdominal and pelvic ultrasound especially in early pregnancy. This examination is cheap, easy to perform, safe for the fetus and not uncomfortable for the pregnant woman. The ideal time points and number of examinations remains to be established.

The Polish Society of Gynecology recommends 3 ultrasound examinations during pregnancy: the first examination should be performed between week 11 and week 13 +6, the second in between week 18 and 22 and the third between 28 and 32 week of gestation. They should include fetal and maternal assessment. The latter is limited to the evaluation of minor pelvis only [10]. The examinations are performed with convex ultrasound probes that can also be used to assess intraperitoneal solid organs (like the liver or spleen) and the retroperitoneal space (i.e. kidneys are located). This could be an opportunity to perform abdominal screening and retroperitoneal ultrasound examination. In our opinion, the first trimester examination is the best time point to perform such procedure, as many diagnostic and surgical options are still open and second trimester is probably the safest time for surgical intervention. Screening examination can be performed by an obstetrician that had basic training in abdominal ultrasound. In case of any mothers abnormality seen on screening US, a directed examination by radiologist or urologist should follow and magnetic resonance

(MRI) should be performed as soon as possible as it is safe for both the fetus and the gravida. MRI can yield clinical information as to the local spread of the tumor, nodal and/or venous involvement critical for decision-making and choosing the right type of treatment. MRI can be safely performed using Gadolinium contrast agents when no sign of fetal or maternal renal impairment is present. It gives more accurate and objective information compared to US, is not observer interchangeable and is less prone to patients characteristics that make US technically difficult [11].

## CONCLUSIONS

It might be reasonable that pregnant women undergo screening abdominal ultrasound examination during first trimester of pregnancy by a trained obstetrician. This procedure should be mandatory at any time point if any complications or abnormal laboratory values are seen. If any pathologies are noted MRI should follow.

## References

1. Czerkwiński J, Marianowski L, Szymanowski J, Ułanowska D. Przypadek samoistnego pęknięcia prostego naczyniaka nerki w przebiegu ciąży. *Wiad Lek.* 1988; 41: 1318–1321.
2. Swierż J, Stawarz B. Guz Wilmsa u 22-letniej kobiety w ciąży. *Pol Tyg Lek.* 1994; 49: 198–199.
3. Tupikowski K, Dembowski J, Zdrojowy R, Lorenz J. Renal-cell carcinoma in pregnancy. *Centr Eur J Urol.* 2009; 62: 108–109.
4. Cegłowska A, Michalski A. Renal cell carcinoma during pregnancy. *Gin Pol.* 2004; 75: 145–149.
5. Walker JL, Knight EL. Renal cell carcinoma in pregnancy. *Cancer.* 1986; 58: 2343–2347.
6. Lee D, Abraham N. Laparoscopic radical nephrectomy during pregnancy: case report and review of the literature. *J Endourol.* 2008; 22: 517–518.
7. Pomara G, Salinitri G, Nesi G, Maio E, Minervini A, Gammazza AM, Francesca F, Cappello F, Selli C. p53 and Ki-67 expression in renal cell carcinomas of pregnant women and their correlation with prognosis: a pilot study. *Int J Gynecol Cancer.* 2008; 18: 132–135.
8. Radopoulos D, Dimitriadis G, Gologinas P, Tahmatzopoulos A, Kotakidou R. Solitary multilocular cystic renal cell carcinoma in adults: diagnostic problems, pathological features and treatment. *Scand J Urol Nephrol.* 2009; 43: 84–87.
9. Keogh JM, Badawi N. The origins of cerebral palsy. *Curr Opin Neurol.* 2006; 19: 129–134.
10. Polish Gynecological Society – Ultrasound Section Guidelines on ultrasound screening in uncomplicated pregnancy (2 December 2011). *Ginekol Pol.* 2012; 83: 309–315.
11. Putra LGJ, Minor TX, Bolton DM, Appu S, Dowling CR, Neerhut GJ. Improved assessment of renal lesions in pregnancy with magnetic resonance imaging. *Urology.* 2009; 74: 535–539. ■