

# A CARE-compliant article: Extranasal glial heterotopia in a female infant

## A case report

Weigang Gan, MD<sup>a,b</sup>, Yu Xiang, MB<sup>c</sup>, Yiping Tang, MM<sup>d</sup>, Xinrong He, MM<sup>e</sup>, Juanjuan Hu, MD<sup>a</sup>, Fengjuan Yang, MM<sup>a</sup>, Shixi Liu, MD<sup>a</sup>, Junming Xian, MD<sup>a,\*</sup>, Juan Meng, MD<sup>a,\*</sup>

### Abstract

**Rationale:** Nasal glial heterotopia is a rare type of neoplasm consisting of meningotheial and/or neuroglial elements.

**Patient concerns:** A 17-month-old female infant was evaluated for treatment for a congenital mass present since birth on the right side of the nasal dorsum.

**Diagnoses:** The patient was preoperatively diagnosed with a congenital extranasal neoplasm.

**Interventions:** Surgery was performed under general anesthesia, and the mass was completely resected. The tissue was sent for histological examination, and the diagnosis was of extranasal glial heterotopia.

**Outcomes:** The surgical outcome was good, and no surgical site infection was recorded. After 6 months of follow-up, the girl was asymptomatic with no recurrence.

**Lessons:** Surgical excision, a curative method used to address extranasal glial heterotopia, resulted in no recurrence during the clinical follow-up period. The potential for an intracranial connection must always be kept in mind when considering how to surgically treat a congenital midline mass to prevent the risk of cerebrospinal fluid leakage.

**Abbreviations:** CSF = cerebrospinal fluid, CT = computed tomography, GFAP = glial fibrillary acidic protein, MRI = magnetic resonance imaging, NGH = nasal glial heterotopia.

**Keywords:** glial, heterotopia, hypodermic, lesion

## 1. Introduction

Nasal glial heterotopia (NGH), a rare type of neoplasm consisting of meningotheial and/or neuroglial elements, was first described by Reid in 1852.<sup>[1]</sup> The incidence of congenital nasal masses has been reported at 1 in 20,000 to 40,000 live births,<sup>[2]</sup> and NGH accounts for 5% of all congenital nasal masses.<sup>[3]</sup> Here, we present a case of an extranasal glial

heterotopia that occurred in a 17-month-old girl who suffered from lookism because of her malformation; however, the patient experienced no dysfunction.

## 2. Case report

A 17-month-old female infant presented to the ENT Department of our hospital for evaluation and treatment of a congenital mass on the right side of the nasal dorsum (Fig. 1). The lesion had remained unchanged since birth. There was no history of nasal blockage. Physical and neurological developments were normal. A physical examination revealed a 1.5 × 1.5 cm moderately firm, rubbery mass with a distinct boundary and good mobility. The mass exhibited no pulsation and expansion during crying or straining. The patient's nasal passages were patent. Magnetic resonance imaging (MRI) and computed tomography (CT) scanning revealed a subcutaneous mass with a clear border on the right side of the nose with no bony defect located on the basal skull and no intracranial connecting structure (Fig. 2). The preoperative diagnosis was of an extranasal mass. To avoid complications and because of the lack of cooperation from the young patient, preoperative biopsy was not performed. Surgery was performed, and the mass was completely resected under general anesthesia (Fig. 3), and the perioperative course was uneventful. The tissue was sent for histological examination and showed prominent astrocytes and oligodendrocytes with occasional neurons intermixed with a fibrous connective tissue stroma (Fig. 4). Moreover, immunohistochemistry showed that glial fibrillary acidic protein (GFAP) was strongly positive (Fig. 5). The diagnosis was of an extranasal glial heterotopia. After 6 months

Editor: N/A.

Weigang Gan and Yu Xiang have contributed equally to this work.

The authors have no conflicts of interest to disclose.

<sup>a</sup> Department of Otorhinolaryngology, Head and Neck Surgery, West China Hospital, West China School of Medicine, Sichuan University, Chengdu,

<sup>b</sup> Department of Otorhinolaryngology, Head and Neck Surgery, Affiliated Hospital of North Sichuan Medical College, <sup>c</sup> Morphometric Research Laboratory, North Sichuan Medical College, <sup>d</sup> Department of Otorhinolaryngology, Head and Neck Surgery, Nanchong Central Hospital, <sup>e</sup> Department of Pathology, Affiliated Hospital of North Sichuan Medical College, Nanchong, Sichuan, China.

\* Correspondence: Juan Meng, Junming Xian Department of Otorhinolaryngology, Head and Neck Surgery, West China Hospital, West China School of Medicine, Sichuan University, Chengdu, Sichuan, China (e-mail: mjmelinda@163.com, junmingxian@163.com).

Copyright © 2018 the Author(s). Published by Wolters Kluwer Health, Inc. This is an open access article distributed under the terms of the Creative Commons Attribution-Non Commercial-No Derivatives License 4.0 (CCBY-NC-ND), where it is permissible to download and share the work provided it is properly cited. The work cannot be changed in any way or used commercially without permission from the journal.

Medicine (2018) 97:38(e12000)

Received: 10 April 2018 / Accepted: 20 July 2018

<http://dx.doi.org/10.1097/MD.00000000000012000>



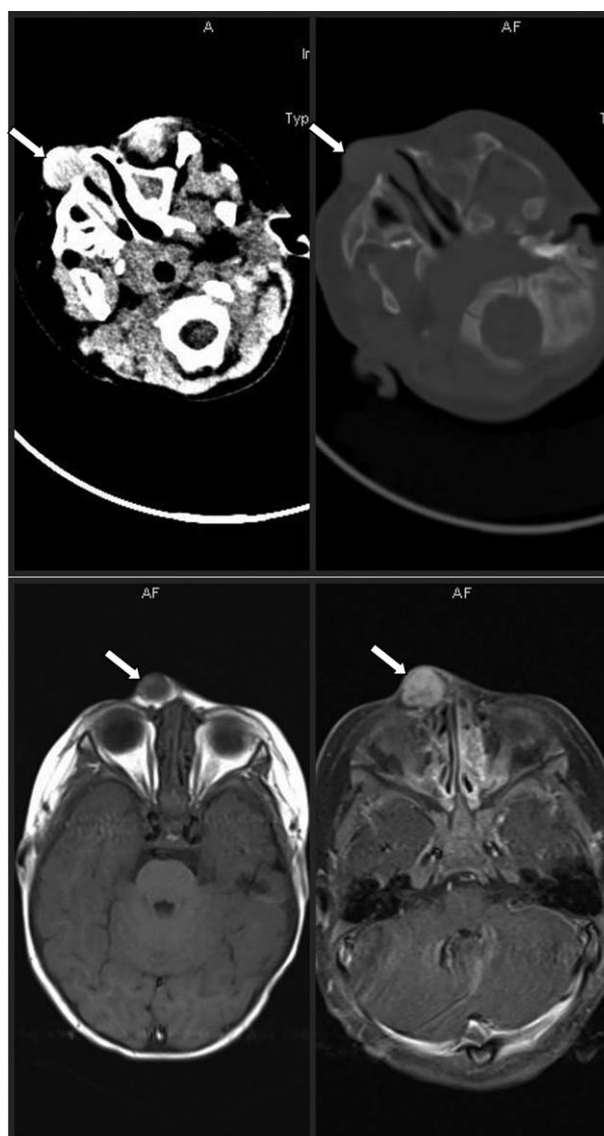
**Figure 1.** A rubbery, movable, and well-demarcated nodule was observed on the right side of the nose.

of follow-up, the girl was asymptomatic with no recurrence. The postoperative cosmetic result was satisfactory. The patient's father agreed to the publication of this report and has provided written informed consent.

### 3. Discussion

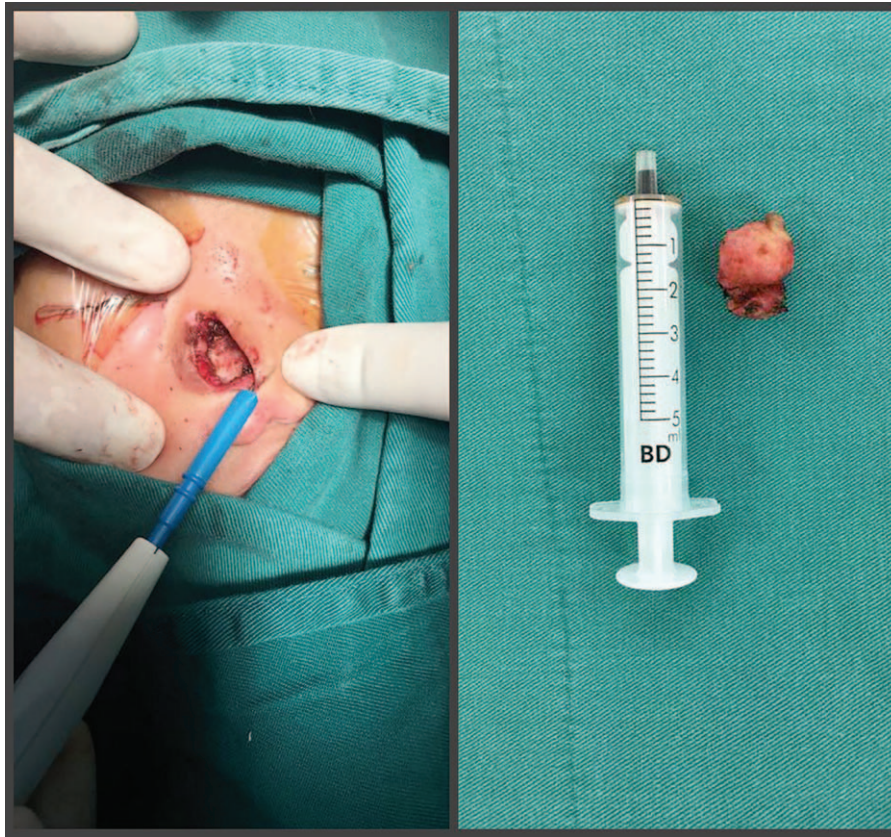
NGH is also known as heterotopic central nervous system tissue or nasal glioma. It is thought to develop either from the entrapment of neuroectodermal tissue during the closure of the tissue that covers the brain or from a nasal encephalocele that becomes covered by the dura, pia, and arachnoid meninges and is sequestered from the intracranial cavity during subsequent embryonic development.<sup>[4]</sup> NGHs can be thought of as cephaloceles that have lost their intracranial connection. NGH is generally present at birth or diagnosed in early childhood; however, rare cases of NGH developing in adulthood have also been reported.<sup>[5]</sup> For the current case, the lesion had been identified since birth. NGHs are predominantly located inside or near the nasal cavity, with 60% of cases located extranasally, 30% intranasally, and 10% both extranasally and intranasally.<sup>[6,7]</sup> Extranasal glial heterotopias are firm, noncompressible, smooth masses that can be located anywhere from the nasal tip to the nasal glabella and do not pulsate or expand during crying, coughing, or straining. Intranasal glioma often presents as a pale mass that obstructs the nasal cavity and can lead to nasal congestion.<sup>[2]</sup> In our case, the mass belonged to the extranasal type. Overall, in 15% of patients, NGHs are connected to the dura via a fibrous stalk,<sup>[8]</sup> but no fluid fills the space connecting the lesion to the subarachnoid space. Dural attachments are more commonly associated with the intranasal type (35%) than with the extranasal type (9%). Rare locations, such as the scalp, orbit, paranasal sinuses, nasopharynx, tongue, lips, oropharynx, and mastoid process, have also been reported.<sup>[9]</sup>

NGHs should be differentiated from nasal dermoids and encephaloceles due to their similar embryological origins and the



**Figure 2.** Computed tomography scan showing a nasal mass (arrows) arising from subcutaneous tissue connected with the nasal bone. An magnetic resonance imaging of the nasal mass (arrows) with low T1 and T2 signals showing that the mass had no connection with the brain.

fact that they can all manifest as extranasal masses. Encephaloceles are extracranial hernias of the meninges and/or brain caused by congenital defects in the skull, and they maintain a subarachnoid connection. This connection with the central nervous system and the possibility that they might contain brain tissue make it important to rule out encephaloceles. It has been reported that the rate of associated developmental anomalies varies from 0% to 40% in patients with encephaloceles.<sup>[1]</sup> The most common location for encephaloceles is occipital (75%) followed by frontal (25%). Frontal encephaloceles are further divided into sincipital (60%) and basal (40%) lesions. Sincipital encephaloceles present as external nasal masses.<sup>[10]</sup> Because they have an intracranial connection, pulsation and expansion of the mass occur with crying, straining, or compression of the jugular vein (Furstenberg test). In our patient, the mass exhibited no pulsation and expansion during crying or straining, making the diagnosis of encephaloceles unlikely.



**Figure 3.** The nasal bone was exposed after lump resection, and its gross pathology showed a soft mass measuring 1.5 cm across the largest dimension.

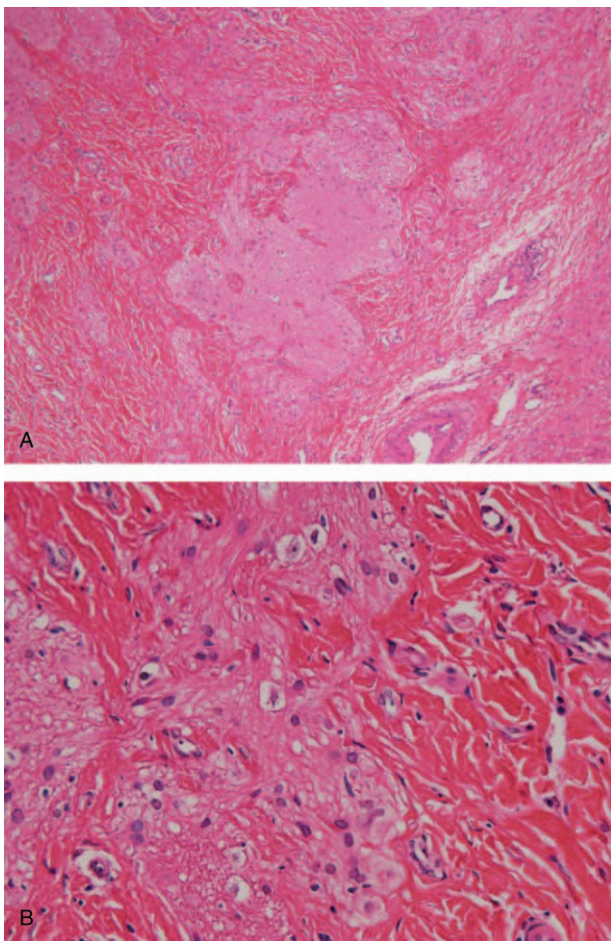
Nasal dermoids account for 1% to 3% of all dermoid cysts and typically present as midline masses that are most commonly found along the dorsum. Nasal dermoids are firm, noncompressible, nonpulsatile masses, and do not transilluminate. A sinus may be present on the surface of the skin, and sometimes, there is hair at this opening. The lumens of dermoid cysts are lined by keratinized stratified squamous epithelium, containing skin tissues or dermal appendages (e.g., hair follicles, sebaceous glands, sweat glands) and may secrete sebaceous fluid or pus. They may have an intracranial extension. The most widely accepted theory for the formation of nasal dermoids is the prenasal space theory. According to this theory, when the dura mater recedes from the prenasal space during embryological development, it can pull the nasal ectoderm upward and inward, and the resulting epithelial lining may then form a sinus or cyst.<sup>[11]</sup>

NGHs can have a telangiectatic surface. Therefore, they can be initially misdiagnosed as capillary hemangiomas. Other frontonasal masses in newborns, infants, and young children include hairy or teratoid polyps, fibromas, lipomas, lipoblastomas, and rare malignancies, such as fibrosarcoma, rhabdomyosarcoma, primitive neuroectodermal tumors, and hematopoietic tumors, such as granulocytic sarcoma.<sup>[4]</sup>

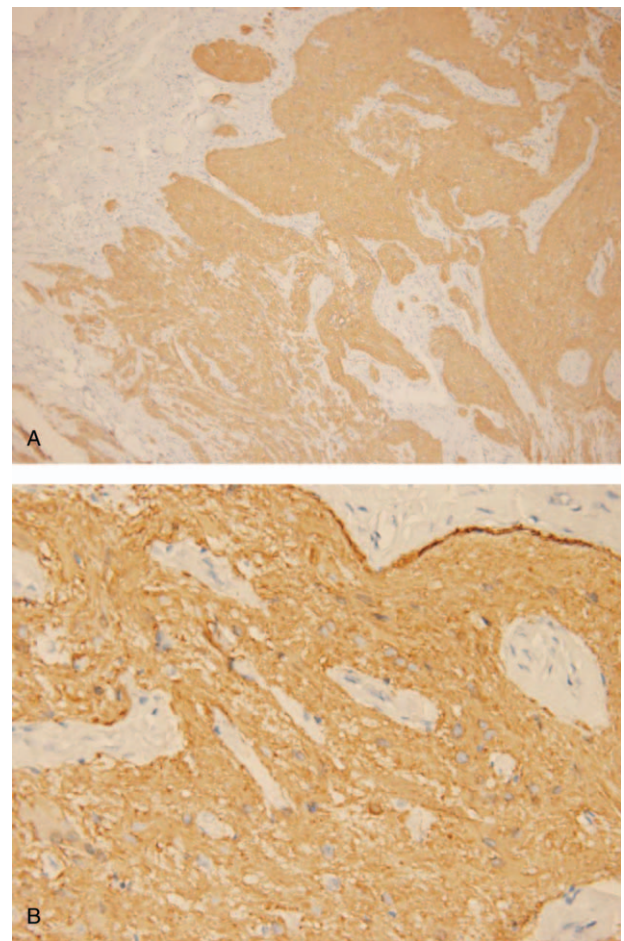
Imaging methods, such as CT scanning and MRI, are very important for the diagnosis of NGH. These methods make it possible to differentiate NGHs from encephaloceles if an adjacent communicating cerebrospinal fluid (CSF)-filled space suggesting an encephalocele is present. CT scans are better for delineating

bony structures. An enlarged foramen cecum or bifidity of the crista galli on CT scan is consistent with intracranial involvement; however, these observations are not diagnostic. Bony defects may be seen in association with NGH in patients with developmental abnormalities but may not have any communications with intracranial tissue.<sup>[4]</sup> Denoyelle reviewed 36 children with nasal dermoids, 2 of whom showed false-positive CT scan evidence of intracranial connections that were not found in surgery.<sup>[12]</sup> Therefore, Pensler et al suggested that in CT scans, these findings are conclusive only if they are absent, indicating no intracranial connection. When these findings are present on CT, they may be false positive.<sup>[13]</sup> MRI is better than CT at providing details regarding soft tissues and is valuable for identifying intracranial connections. In most clinical practices, MRI has supplanted CT as the first choice and is typically the only preoperative imaging study required to evaluate newborns and infants with congenital frontonasal masses.<sup>[4]</sup> In our patients, both MRI and CT scanning were performed to rule out intracranial extension.

Histologically, an NGH is composed of large and small islands of glial cells within connective fibrous tissue. Buckner has confirmed that an NGH is strongly positive for GFAP and S-100 proteins,<sup>[14]</sup> consistent with our observation. It is often not possible to distinguish NGHs from encephaloceles on histological examination, as both lesions show varying proportions of neuronal and glial elements. Although ependymal tissue is not always identified in encephaloceles, when present, a diagnosis of encephaloceles is more likely.<sup>[10]</sup>



**Figure 4.** Neuroglial heterotopia composed of glial cells and neuroglial fibers. Hematoxylin and eosin: (A)  $\times 100$ , (B)  $\times 400$ .



**Figure 5.** Immunohistochemistry: The neuroglial tissue was positively stained for glial fibrillary acidic protein. (C)  $\times 100$ , (D)  $\times 400$ .

NGHs tend to have slow growth rates and are benign. They show no potential for malignant degeneration. Even though these lesions are benign, early surgical intervention is recommended to avoid further significant local damage or cosmetic deformity caused by the compression and destruction of the nasal cartilage and orbital wall. Before surgery is scheduled, NGHs must be carefully differentiated from encephaloceles and other midline nasal masses. Preoperative biopsy and excision without preoperative imaging are contraindicated due to the possibility of complications, such as CSF leakage, meningitis, or the removal of brain tissue in cases of encephaloceles.<sup>[3]</sup> That is why we did not perform biopsy before surgery for our patient. The surgical approach should be based on the location and size of the mass. External rhinoplasty is recommended for extranasal gliomas because it allows adequate exposure for complete excision and achieves an excellent cosmetic outcome. When a fibrous stalk is present, a nasal osteotomy is recommended to improve exposure. A transnasal endoscopic approach is recommended for intranasal gliomas. Proper exposure and complete excision can currently be achieved in an intranasal glioma as a result of advancements in endoscopic equipment and techniques.<sup>[10]</sup> Potential complications include meningitis and CSF leakage. Additionally, inadequate primary excision results in a recurrence rate of 4% to 10%.<sup>[15]</sup> For our patient, no recurrence was found during 6 months of follow-up after surgery.

#### 4. Conclusion

We report a rare case of extranasal glial heterotopia identified at birth. Extranasal glial heterotopia is a type of congenital lesion that is rarely reported in the literature. The potential for this type of NGH to have an intracranial connection must always be considered when planning surgery for a congenital midline mass to prevent the risk of CSF leakage. Surgical excision is a curative method used to address extranasal glial heterotopia without the risk of recurrence during clinical follow-up.

#### Author contributions

**Investigation:** Xinrong He, Juanjuan Hu.

**Resources:** Yiping Tang, Fengjuan Yang, Junming Xian.

**Supervision:** Shixi Liu.

**Writing – original draft:** Weigang Gan.

**Writing – review and editing:** Yu Xiang, Juan Meng.

#### References

- [1] Rouev P, Dimov P, Shomov G. A case of nasal glioma in a new-born infant. *Int J Pediatr Otorhinolaryngol* 2001;58:91–4.
- [2] Hughes GB, Sharpino G, Hunt W, et al. Management of the congenital midline nasal mass: a review. *Head Neck Surg* 1980;2:222–33.
- [3] Bradley PJ, Singh SD. Congenital nasal masses: diagnosis and management. *Clin Otolaryngol Allied Sci* 1982;7:87–97.

- [4] Hedlund G. Congenital frontonasal masses: developmental anatomy, malformations, and MR imaging. *Pediatr Radiol* 2006;36:647–62.
- [5] Altissimi G, Ascani S, Falcetti S, et al. Central nervous system tissue heterotopia of the nose: case report and review of the literature. *Acta Otorhinolaryngol Ital* 2009;29:218–21.
- [6] Jaffe BF. Classification and management of anomalies of the nose. *Otolaryngol Clin North Am* 1981;14:989–1004.
- [7] Pensler JM, Ivescu AS, Ciletti SJ, et al. Craniofacial gliomas. *Plast Reconstr Surg* 1996;98:27–30.
- [8] Barkovich AJ, Vandermarck P, Edwards MS, et al. Congenital nasal masses: CT and MR imaging features in 16 cases. *AJNR Am J Neuroradiol* 1991;12:105–16.
- [9] Mohanty S, Das K, Correa MA, et al. Extranasal glial heterotopia: case report. *Neurol India* 2003;51:248–9.
- [10] Rahbar R, Resto VA, Robson CD, et al. Nasal glioma and encephalocele: diagnosis and management. *Laryngoscope* 2003;113:2069–77.
- [11] Pratt LW. Midline cysts of the nasal dorsum: embryologic origin and treatment. *Laryngoscope* 1965;75:968–80.
- [12] Denoyelle F, Ducroz V, Roger G, et al. Nasal dermoid sinus cysts in children. *Laryngoscope* 1997;107:795–800.
- [13] Pensler JM, Bauer BS, Naidich TP. Craniofacial dermoids. *Plast Reconstr Surg* 1988;82:953–8.
- [14] Buckner JC, Brown PD, O'Neill BP, et al. Central nervous system tumors. *Mayo Clin Proc* 2007;82:1271–86.
- [15] Puppala B, Mangurten HH, McFadden J, et al. Nasal glioma. Presenting as neonatal respiratory distress. Definition of the tumor mass by MRI. *Clin Pediatr* 1990;29:49–52.