

# BMJ Open Cauterisation versus fibrin glue for conjunctival autografting in primary pterygium surgery (CAGE CUP): study protocol of a randomised controlled trial

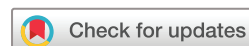Mladen Lešin,<sup>1</sup> Martina Paradžik,<sup>1</sup> Josipa Marin Lovrić,<sup>1</sup> Ivana Olujić,<sup>1</sup> Žana Ljubić,<sup>1</sup> Ana Vučinović,<sup>1</sup> Kajo Bučan,<sup>1</sup> Livia Puljak<sup>2,3</sup>

**To cite:** Lešin M, Paradžik M, Marin Lovrić J, *et al*. Cauterisation versus fibrin glue for conjunctival autografting in primary pterygium surgery (CAGE CUP): study protocol of a randomised controlled trial. *BMJ Open* 2018;**8**:e020714. doi:10.1136/bmjopen-2017-020714

► Prepublication history and additional material for this paper are available online. To view these files, please visit the journal online (<http://dx.doi.org/10.1136/bmjopen-2017-020714>).

ML and MP contributed equally.

Received 21 November 2017  
Revised 25 April 2018  
Accepted 25 April 2018



<sup>1</sup>Department of Ophthalmology, University Hospital Split, Split, Croatia

<sup>2</sup>Laboratory for Pain Research Department of Anatomy, Histology and Embryology, University of Split School of Medicine, Split, Croatia

<sup>3</sup>Department for Development, Research and Health Technology Assessment, Agency for Quality and Accreditation in Health Care and Social Welfare, Zagreb, Croatia

## Correspondence to

Dr Martina Paradžik;  
[martina.paradzik@gmail.com](mailto:martina.paradzik@gmail.com)

## ABSTRACT

**Introduction** Pterygium is a non-cancerous growth of the conjunctival tissue over the cornea that may lead to visual impairment in advanced stages, restriction of ocular motility, chronic inflammation and cosmetic concerns. Surgical removal is the treatment of choice, but recurrence of pterygium is a frequent problem. It has been previously shown that fibrin glue may result in less recurrence and may take less time than sutures for fixing the conjunctival graft in place during pterygium surgery. However, fibrin glue is a biological material and it carries the risk of transmitting infectious agents from pooled and single-donor blood donors and anaphylaxis in susceptible individuals. Cauterisation is another surgical option, and it would be advantageous to know whether cauterisation may be superior surgical option compared with fibrin glue. This protocol describes the rationale and design of the randomised controlled trial (RCT) in which we will compare cauterisation versus fibrin glue for conjunctival autografting in primary pterygium surgery.

**Methods and analyses** This will be a parallel group RCT comparing cauterisation versus fibrin glue for conjunctival autografting in primary pterygium surgery. Computer-generated randomisation will be used, and allocation concealment will be conducted using sequentially numbered opaque sealed envelopes. Surgeons will not be blinded to the procedures, but participants, other investigators and outcome assessors will be blinded. Adult participants with primary pterygium operated in a tertiary hospital in Split, Croatia, will be included. Primary outcome will be recurrence of pterygium, defined as any regrowth of tissue from the area of excision across the limbus onto the cornea after 180 days.

**Ethics and dissemination** The trial was approved by the ethics review board of the University Hospital Split (500-03/17-01/68). Results will be disseminated at conferences and through peer-reviewed publications.

**Trial registration number** NCT03321201; Pre-results.

## INTRODUCTION

Pterygium is a common progressive disease characterised by the growth of conjunctival tissue over the cornea. When it enters in the optical zone, it can interfere with vision by

## Strengths and limitations of this study

- First randomised controlled trial (RCT) that will assess cauterisation for attaching conjunctival autograft in pterygium surgery.
- Based on the planned sample size, this will be one of the largest RCTs about pterygium surgery.
- The RCT includes recurrence at 180 days as a primary outcome, as well as relevant secondary outcomes
- RCT is focused on primary pterygium; recurrent pterygia will be excluded.

masking the visual axis or inducing astigmatism.<sup>1</sup> Lesions can cause irritation and chronic inflammation due to localised drying.<sup>2</sup> Extensive pterygium may be associated with restriction of ocular motility. Deteriorated aesthetics can also be a significant problem. Pterygium occurrence is high in places with hot, dry, windy climate and those geographic areas exposed to high UV radiation.<sup>3</sup> Furthermore, pooled prevalence rate of pterygium is approximately 10% in general population, especially in low geographic latitude regions and for the elderly.<sup>4</sup>

Surgical removal of pterygium is a therapy of choice, but there is a possibility of recurrence.<sup>5 6</sup> Antimetabolites are used to lower recurrence rate, but due to their aggressive attributes, those drugs may be associated with serious complications, and therefore they are reserved for participants with recurrent pterygium and younger people.<sup>7 8</sup>

Currently, the best method of reducing the recurrence of the disease is to use a conjunctival graft after removing pterygia.<sup>5</sup> Cochrane systematic review from 2017 found that conjunctival autograft was more effective than amniotic membrane to prevent pterygium recurrence 6 months postoperative.<sup>9</sup> The most common method of connecting the graft is by

using sutures.<sup>10</sup> Despite the advancement of surgical techniques, this method is associated with increased postoperative discomfort as well as prolonged duration of surgical intervention and surgical skill needed. Different sutureless techniques of connecting graft, fibrin adhesive and cauterisation are described in the literature as methods of replacing sutures and reducing postoperative discomfort and recurrence of the disease.<sup>11–13</sup> Based on the recent Cochrane review, which compared fibrin glue and sutures as interventions for pterygium, higher complication rate was reported in the fibrin glue group compared with the suture group.<sup>6</sup>

Fibrin glue has been used for medical purposes for the last 20 years, mostly in tissue adhesion surgery, wound healing support, stomach support in vascular surgery, gastrointestinal anastomosis and neurosurgery. In ophthalmology, the fibrin adhesive is used in the management of pterygia, strabismus, reconstruction of connective tissue, amniotic membrane transplantation, corneal surgery (lamellar keratoplasty, closure of traumatic perforation and descemetokeratoma), closing the conjunctiva after trabeculoplasty, eyelash surgery and haemostasis.<sup>14 15</sup>

The fibrin adhesive is a derivative of the blood product that imitates the last cascade of blood clotting. It consists of two components: tissue adhesion proteins (fibrinogen, coagulation factor 13 and aprotinin) and thrombin (thrombin and calcium chloride); solutions that are paired before the operative procedure. Fibrinogen, as human derivative, has risk of transmitting infectious agents (parvovirus B 19, HIV and hepatitis virus).<sup>16</sup> The major disadvantage of fibrin glue is the risk of disease transmitted from pooled and single-donor blood products.<sup>17 18</sup> Although risk of contracting infectious agents with fibrin is low, with the lowest calculated margin of safety for parvovirus, manufacturers were encouraged to continue investigating processes that would increase parvovirus safety margins and investigate methods for eliminating prions.<sup>19</sup> Although this could be minimised by taking the blood from screened healthy donors, there is also a possibility to use patient's own blood to prepare fibrin glue. However, using patient's own blood is expensive, and autologous donation takes at least 24 hours of processing. Such preparation often has variable concentrations and therefore unpredictable performance. Furthermore, tensile strength of fibrin glue has not been appropriately determined, which precludes quantification, and therefore it is dependent on various external factors.<sup>14</sup> Therefore, it has been recommended that more studies are needed before fibrin glue can be recommended as a standard procedure in ophthalmology.

Another sutureless method that can be used in pterygium surgery involves cauterisation.<sup>16 20</sup> Bipolar cautery, widely used in general surgery, causes thermal welding, which results in vaporising intracellular fluid and denaturation of tissue proteins. McPearson<sup>21</sup> first mentioned usage of bipolar cautery in ophthalmic procedures in 1972. Since then, bipolar cauter has been used in oculoplastic surgery, glaucoma filtering surgery and for

closing leaking sclerotomies with conjunctiva placed over the incisions as an alternative for suture closure.<sup>22</sup>

Although fibrin glue provides a fast and efficient technique for autograft fixation in primary pterygium surgery, it carries a potential risk of transmitting infectious agents and therefore cauterisation should be explored as a potentially superior method. It has been reported already that cautery autograft fixation has reduced postoperative discomfort compared with autograft fixation with sutures, fibrin glue and autologous fibrin glue.<sup>20</sup> Studies including autografting with electrocautery pen compared with suture autografting have showed that thermal welding can be safe and fast alternative, with less postoperative discomfort.<sup>12</sup> Idea of hybrid technique for joined suturing and cauterisation has been presented for large pterygia, and further usage of bipolar cautery has been proposed. Cauterisation used for fixation of amniotic membrane transplant after pterygium excision showed no recurrence, dislocation or malposition of a transplant.<sup>16</sup> Therefore, we have hypothesised that cauterisation autografting can be at least as effective as fibrin glue autografting in terms of recurrence, complication rate, postoperative discomfort with no risk of transmitting infectious agents and causing anaphylaxis in susceptible individuals.

## METHODS AND ANALYSES

### Design

A randomised controlled trial with two active comparators will be conducted, where participants and outcome assessors will be blinded. The trial was prospectively registered on Clinicaltrials.gov (registration number: NCT03321201).

### Reporting

We reported our protocol according to the Standard Protocol Items: Recommendations for Interventional Trials statement.<sup>23</sup>

### Inclusion criteria

Participants will be adults (older than 18 years of age) of both sexes with primary nasal pterygia >4 mm, which tend to increase, including participants with reduced visual acuity, chronic inflammation, cosmetic reasons. If the participants had a bilateral pterygium, only one eye will be operated.

This study is focused on primary pterygia because characteristics of recurrent pterygium are different and therefore surgeon may opt for a different type of surgery when treating recurrent pterygium. Additionally, recurrent pterygium may be more difficult to remove because of the scarring associated with primary pterygium and its surgical removal. Furthermore, eyes that are exposed to recurrent pterygia may have biological or environmental predisposition for profuse tissue response to the causative factors of pterygium.<sup>6</sup>

### Exclusion criteria

Participants with connective tissue disease, prior eye surgery, as well as participants with chronic use of topical drugs (antiglaucoma drops) will be excluded.

### Patient and public involvement

Research question was developed after consultation with patients, and their suggestions were involved in formation of outcome measures and designing this study.

After the trial, the study participants will be informed about the results through a newsletter.

### Setting and study sample

All participants will be recruited at one location, at the Department of Ophthalmology of University Hospital Split, where they will be operated. Study will include a total of 164 participants; 82 in each of the two study groups.

### Study design

The study will be a randomised controlled trial with parallel design, including 1:1 allocation ratio. After screening for inclusion criteria, participants will be screened for study inclusion by MP. Participants fulfilling inclusion criteria will receive written information about the study and invited to participate (figure 1). After obtaining informed consent, the participants will be randomised.

Randomisation will be performed centrally by a study author (LP) who is not employed at the University Hospital Split and not involved in participant care. Randomisation will be performed using a computer-generated sequence with blocking of eight participants, since eight subjects are expected to be operated daily.

Allocation concealment will be achieved by preparing sequentially numbered opaque sealed envelopes, which will contain information about the allocation group written on paper that will be wrapped with silver aluminium foil to hide the print to prevent it from being read with a flash of light. Envelopes will then be delivered to an independent nurse, who is not involved with the study, and the nurse will open the next envelope once a study participant enters the operating theatre, immediately before the surgery.

Since the studied interventions are surgical, surgeons cannot be blinded to the type of surgery. Study participants will be blinded for the type of intervention, as well as clinical outcome assessors and author who will perform data analysis.

### Baseline assessment

A few weeks before the operation, participants will be phoned, and during the call, they will receive information about the operating procedure, a reminder about the medical documentation they need to prepare (previous ocular findings, laboratory findings including complete blood count, blood glucose and C reactive protein), date of preoperative visit and date of operative interventions.

The following baseline data will be collected *before* the surgery:

1. Age.
2. Sex.
3. Left or right eye.
4. Duration of change (when the participant first noticed the change).
5. Side of change (one sided or bilateral).
6. Best-corrected visual acuity with the values of dioptre Dsph and astigmatic values of Dcyl/Axis.<sup>1</sup>
7. Tear break-up time test.<sup>2</sup>
8. Values measured by optical biometry and corneal topography (central K1, central K2, peripheral K1, peripheral K2, axial length, intraocular lens (IOL) power calculation).<sup>24 25</sup>
9. Dimensions of pterygia: length of pterygia, maximum and minimum height, length over limbus horizontally and vertically, cornea surface covered with pterygia and corneal size horizontally and vertically.<sup>26 27</sup>
10. Digital photography (Canon EOS 5D Mark II, Canon., Tokyo, Japan) will be performed for all participants before and after surgery. Based on the photograph, an author not involved in surgery and unaware of the participant allocation will grade pterygia using Tan's classification<sup>26</sup>
11. Classification of pterygia morphology by Tan: 1: atrophic/underlying episcleral blood vessels visible, 3: fleshy/episcleral blood vessels are not visible and 2: intermediate, between 1 and 3.<sup>28</sup>
12. Pain in the eye that will be operated on the morning before surgery measured with numerical rating scale (NRS) ranging from 0 to 10, where 0=no pain and 10=pain as intense as you can imagine.<sup>29</sup>
13. Ocular Surface Disease Index (OSDI) questionnaire.<sup>30</sup>

### Intervention and comparator

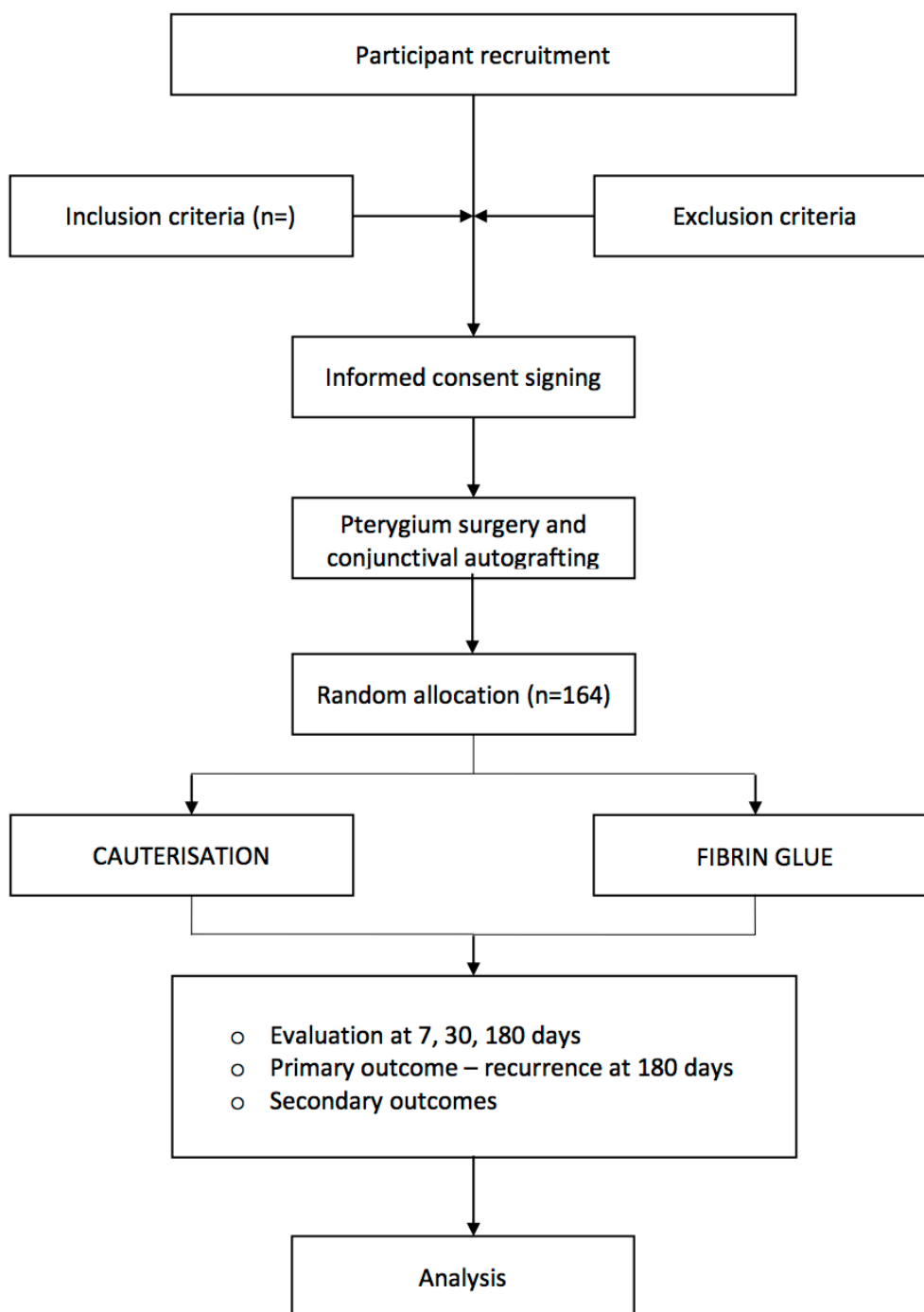
There will be two surgical techniques that do not include suturing. The intervention is autograft with cauterisation (using bipolar cautery), and the control group (active comparator) is autograft with fibrin adhesive.

### Intervention

Autografts with cauterisation: to ensure the stability of the graft before cauterisation, four sutures will be installed, which will be removed after cauterisation is completed. Autograft and conjunctiva will be approximated by hockey forceps, carefully dried by using sponge spears and will be cauterised with 9–12 spots using a bipolar cutter (ICC 50, ERBE, Tübingen, Germany) with a force 1/20 for 1 s. Hockey forceps will be released slowly to prevent elevation of the graft. The same procedure will be performed on each side of the graft (nasal, to the top and to the bottom), with 3–4 spots, until graft is well firmed. Graft adhesion will be checked up with a sponge, and additional cauterisation will be performed if needed.

### Active comparator

Fibrin adhesive (Tisseel Lyo 1 mL, Baxter, Deerfield, Illinois, USA) will be prepared according to manufacturer's instructions. Preparation time will be approximately



**Figure 1** Flow diagram. Participants flow through the study protocol.

10–15 min per kit. Once mixed, the fibrin glue is usable up to 4 hours. For the purpose of the study preparation of the fibrin glue will be performed by a nurse.

#### Operational procedure

All participants will receive premedication of diazepam 5 mg orally 2 hours before surgery. Surgery will be performed by two surgeons. Preoperative sterile preparation of the surgical field will involve the use of 10% chlorhexidine iodine on the skin of the periocular area and

5% chlorhexidine iodine on the eye surface 3–5 min prior to the procedure. In each procedure, topical anaesthesia (tetracaine) will be used together with local subconjunctival anaesthesia (lidocaine-epinephrine, 40 mg+0.025 mg injection solution, Belupo, Croatia). The head of the pterygia will be removed from the cornea without trimming, and then the pterygium will be completely cut-off with the Westcott scissors. Additional Tenon's tissue will be removed. Bleeding episcleral veins will be gently cauterised in order to prepare place for the graft. The

pterygium tissue, that would otherwise be thrown, will be stored for further analysis. The cornea will then be smoothed with a crescent blade.

### Autografts

A conjunctival autograft will be measured and excised from the superior conjunctiva including the limbal edge. The conjunctival graft will be positioned on the cornea with care taken to maintain limbal and epithelial orientation of the graft. Donor site can be left without sutures because only superficial layer of conjunctiva is excised.

### Postoperative management

On completion of the operation, polymyxin B sulfate-neomycin sulfate-dexamethasone eye-drops and ointment (Maxitrol, Alcon, Belgium) will be applied, and ocular bandage will be positioned. All participants will be instructed to take the bandage off 24 hours after surgery and to use drops polymyxin B sulfate-neomycin sulfate-dexamethasone eye-drops and ointment four times daily during the first 7 days after surgery and on the first follow-up visit and will be instructed to use same eye-drops three times daily and ointment one time daily for another 3 weeks. Also, all participants will be recommended to use artificial tears (Isopto tears, Alcon, Belgium) 4–6 times daily for a month and preferably up to 6 months postoperatively. All participants will be recommended analgesia as needed, at a dose of 500 mg paracetamol up to four times a day. In the case of complications, the postoperative therapy will be extended or adapted to the condition; this will be noted in the participant files, reported subsequently, and we will assess whether these changes may affect study outcomes.

### Follow-up visits

Participants will be followed-up on days 7, 30 and 180. At each visit, all prespecified outcomes will be recorded. After discharge from the hospital, participants will be phoned as a reminder before each scheduled follow-up visits.

### Outcomes

Primary outcome will be recurrence of pterygium, defined as any regrowth of tissue from the area of excision across the limbus onto the cornea after 180 days. We used 6-month follow-up because recurrence is the most common within the first 6 months, and the relevant Cochrane review, and the majority of relevant trials on the subject, used the same timing for the primary outcome of pterygium recurrence.<sup>6</sup>

We categorised recurrent pterygium according to the Prabhasawat *et al.*<sup>31</sup> in four grades: grade 1: normal appearance of the operative site, grade 2: presence of some fine episcleral vessels, but without any fibrous tissue in the excised area extending up to but not beyond the limbus, grade 3: presence of additional fibrous tissues in the excised area without invading the cornea and grade 4: true recurrence with a fibrovascular tissue invading the cornea.

Secondary outcomes will be:

1. Surgical time: (A) total operational time required for completion of the operation; and (B) flap time.
2. Complication rate will be analysed as the occurrence of at least one of the following major complications such as dehiscence, displacement or loss of the autograft, infection, haemorrhage, oedema, fibrosis, retraction and other indications that required special treatment. We will define dehiscence of the wound as separating the graft from the junction edge of the conjunctiva of 1 mm or more (yes or no). As a result of dehiscence, graft displacement can occur, and we will graduate it in four steps according to Mittal *et al.*: grade 0: all four sides of the graft margin are well apposed, grade 1: gaping/displacement of one side of the graft bed junction, grade 2: gaping/displacement of two sides of the graft bed junction, grade 3: gaping/displacement of three sides of the graft bed junction, grade 4: graft completely displaced from the bed.<sup>32</sup> Digital photography will be performed in order to document the space between graft and conjunctival rim and possible postoperative complications and to enable a comparison between conjunctival redness and chemosis by masked investigator.
3. Pterygium-induced astigmatism will be measured as described by Hsu *et al.*<sup>33</sup>
4. OSDI questionnaire.<sup>30</sup>
5. Postoperative discomfort, tearing, pain and foreign body sensation will be measured using modified scale from Lim-Bon-Siong *et al.*: (0) none: no pain, (1) very mild, (2) mild: pain causing some discomfort, (3) moderate: pain that partially interferes with usual activity or sleep and (4) severe: pain that completely interferes with usual activity or sleep.<sup>34 35</sup>
6. Pain in the operated eye measured with NRS ranging from 0 to 10, where 0=no pain and 10=pain as intense as you can imagine.<sup>29</sup>
7. Analysis of biological material (DNA isolation, gene and protein analysis by PCR, real-time PCR, sequencing, DNA microarray, immunohistochemistry and in situ hybridisation).<sup>3</sup>
8. Surgeon satisfaction with participants' compliance during surgery will be recorded immediately after the surgery on a numerical scale from 1 to 10, where 1=surgery not possible and 10=excellent surgical condition.<sup>36</sup>
9. Cosmetic appearance at 6 months postoperative will be defined as response to the question whether the participant is: 1: satisfied, 2: mildly satisfied and 3: dissatisfied with the postoperative cosmetic appearance (table 1).

### Statistical analysis

The sample size was calculated by power analysis based on the results of Ratnalingam 2010, in which the proportion of pterygium recurrence was 4.4% in the intervention group and 16% in the control group.<sup>37</sup> Expecting such a difference in proportions, with 80% strength and 90% confidence level, the required number of participants in each group is 82 (164 participants).

**Table 1** Schedule for enrolment, interventions and assessments

	Study period				
	Enrolment	Allocation	Follow-up		
Time point			7 days	30 days	180 days
<b>Enrolment</b>					
Eligibility screen	x				
Informed consent	x				
Allocation		x			
<b>Interventions</b>					
Cauterisation		x			
Fibrin glue		x			
<b>Assessment</b>					
Baseline evaluation	x				
<b>Primary outcome</b>					
Recurrence					x
<b>Secondary outcome</b>					
Surgical time		x			
Complication rate			x	x	x
Pterygium—induced astigmatism	x		x	x	x
OSDI	x		x	x	x
Postoperative discomfort			x	x	x
Postoperative tearing			x	x	x
Postoperative pain			x	x	
Postoperative foreign body sensation			x	x	x
Pain measured with NRS	x		x	x	x
Biological specimen		x			
Surgeon satisfaction		x			
Cosmetic appearance					x

NRS, numerical rating scale; OSDI, Ocular Surface Disease Index.

Data will be anonymised and entered into electronic datasheet for analysis. Differences between the groups will be analysed in a blinded fashion using Mann-Whitney U test. For dropouts, last observation carried forward analysis will be used. Statistical significance will be set at  $p < 0.05$ . Analyses will be conducted using GraphPad Prism software (GraphPad Prism V.6, GraphPad Prism Software, San Diego, California, USA).

After each measurement, a comparison of two methods will be made, and if one of the methods is found to be significantly worse for the participant, the study will be discontinued earlier. All authors will have access to anonymised interim results, and any final decision to terminate the trial will be made jointly by the entire author team.

### Data sharing

Individual participant data will be made available to other researchers via Figshare repository. Data collection forms will be made available to other researchers via personal communication.

### Ethics

The study will be conducted according to the principles of the Declaration of Helsinki. Informed consent will be obtained from all participants. Each participant will be assigned a numerical code, and only one author (MP) will keep information about codes assigned to individual participants. Participant data will be shared with other coauthors and authors who will conduct data analysis only in anonymised form to prevent any bias. After the trial, anonymised participant data will be securely locked together with the randomisation codes and the list of names of participants that belong to each code for archival purposes.

### Dissemination of results

The study results will be disseminated via publication in peer-reviewed international journals, as well as presentations at national and international conferences.

### Ethics approval and consent to participate

Written informed consent will be recorded from every consented patient. Informed consent form that will be

used in the study is provided as online supplementary appendix 1.

**Contributors** The protocol was written by ML, MP and LP. JML, IO, ŽL, AV and KB made significant contribution to the study design and planning. All authors read and approved the final manuscript.

**Funding** The authors have not declared a specific grant for this research from any funding agency in the public, commercial or not-for-profit sectors.

**Competing interests** None declared.

**Patient consent** Obtained.

**Ethics approval** Ethics Committee of the University Hospital Split.

**Provenance and peer review** Not commissioned; externally peer reviewed.

**Open access** This is an open access article distributed in accordance with the Creative Commons Attribution Non Commercial (CC BY-NC 4.0) license, which permits others to distribute, remix, adapt, build upon this work non-commercially, and license their derivative works on different terms, provided the original work is properly cited and the use is non-commercial. See: <http://creativecommons.org/licenses/by-nc/4.0/>

© Article author(s) (or their employer(s) unless otherwise stated in the text of the article) 2018. All rights reserved. No commercial use is permitted unless otherwise expressly granted.

## REFERENCES

- Altan-Yaycioglu R, Kucukerdonmez C, Karalezli A, et al. Astigmatic changes following pterygium removal: comparison of 5 different methods. *Indian J Ophthalmol* 2013;61:104–8.
- Ozsutcu M, Arslan B, Erdur SK, et al. Tear osmolarity and tear film parameters in patients with unilateral pterygium. *Cornea* 2014;33:1174–8.
- Cárdenas-Cantú E, Zavala J, Valenzuela J, et al. Molecular Basis of Pterygium Development. *Semin Ophthalmol* 2016;31:567–83.
- Liu L, Wu J, Geng J, et al. Geographical prevalence and risk factors for pterygium: a systematic review and meta-analysis. *BMJ Open* 2013;3:e003787.
- Clearfield E, Muthappan V, Wang X, et al. Conjunctival autograft for pterygium. *Cochrane Database Syst Rev* 2016;2:CD011349.
- Romano V, Cruciani M, Conti L, et al. Fibrin glue versus sutures for conjunctival autografting in primary pterygium surgery. *Cochrane Database Syst Rev* 2016;12:CD011308.
- Hwang S, Choi S. A Comparative Study of Topical Mitomycin C, Cyclosporine, and Bevacizumab after Primary Pterygium Surgery. *Korean J Ophthalmol* 2015;29:375–81.
- Rubinfeld RS, Pfister RR, Stein RM, et al. Serious complications of topical mitomycin-C after pterygium surgery. *Ophthalmology* 1992;99:1647–54.
- Clearfield E, Hawkins BS, Kuo IC. Conjunctival autograft versus amniotic membrane transplantation for treatment of pterygium: findings from a cochrane systematic review. *Am J Ophthalmol* 2017;182:8–17.
- Uy HS, Reyes JM, Flores JD, et al. Comparison of fibrin glue and sutures for attaching conjunctival autografts after pterygium excision. *Ophthalmology* 2005 Apr;112(4):667–71.
- Sharma A, Raj H, Gupta A, et al. Sutureless and glue-free versus sutures for limbal conjunctival autografting in primary pterygium surgery: a prospective comparative study. *J Clin Diagn Res* 2015;9:NC06–9.
- Xu F, Li M, Yan Y, et al. A novel technique of sutureless and glueless conjunctival autografting in pterygium surgery by electrocautery pen. *Cornea* 2013;32:1.
- Zloto O, Greenbaum E, Fabian ID, et al. Evicel versus Tisseel versus Sutures for Attaching Conjunctival Autograft in Pterygium Surgery: A Prospective Comparative Clinical Study. *Ophthalmology* 2017;124:61–5.
- Panda A, Kumar S, Kumar A, et al. Fibrin glue in ophthalmology. *Indian J Ophthalmol* 2009;57:371–9.
- Scalcione C, Ortiz-Vaquerizas D, Said DG, et al. Fibrin glue as agent for sealing corneal and conjunctival wound leaks. *Eye* 2018;32.
- Bradley JC. Cautery fixation for amniotic membrane transplant in pterygium surgery. *Cornea* 2011;30:194–5.
- Everts PA, Knape JT, Weibrich G, et al. Platelet-rich plasma and platelet gel: a review. *J Extra Corpor Technol* 2006 Jun;38 (2):174–87.
- Alston SM, Solen KA, Sukavaneshvar S, et al. In vivo efficacy of a new autologous fibrin sealant. *J Surg Res* 2008;146:143–8.
- Horowitz B, Busch M. Estimating the pathogen safety of manufactured human plasma products: application to fibrin sealants and to thrombin. *Transfusion* 2008;48:1739–53.
- Mejía LF, Santamaria JP, Cuevas M, et al. Comparison of 4 techniques for limbal-conjunctival autograft fixation in primary pterygium surgery. *Eur J Ophthalmol* 2017;27:466–9.
- McPherson SD. Bipolar coagulation in ophthalmic operations. *Am J Ophthalmol* 1972;73:790–1.
- Benitez-Herreros J, Lopez-Guajardo L, Vazquez-Blanco M, et al. Evaluation of mechanical closure resistance of sutureless vitrectomy sclerotomies after conjunctival cauterization with bipolar diathermy forceps. *Graefes Arch Clin Exp Ophthalmol* 2016;254:489–95.
- Chan AW, Tetzlaff JM, Gotsche PC, et al. SPIRIT 2013 explanation and elaboration: guidance for protocols of clinical trials. *BMJ* 2013;346:e7586.
- Koc M, Uzel MM, Aydemir E, et al. Pterygium size and effect on intraocular lens power calculation. *J Cataract Refract Surg* 2016;42:1620–5.
- Miyata K, Minami K, Otani A, et al. Proposal for a Novel Severity Grading System for Pterygia Based on Corneal Topographic Data. *Cornea* 2017;36:834–40.
- Han SB, Jeon HS, Kim M, et al. Risk Factors for Recurrence After Pterygium Surgery: An Image Analysis Study. *Cornea* 2016;35:1097–103.
- Safi H, Kheirkhah A, Mahbod M, et al. Correlations Between Histopathologic Changes and Clinical Features in Pterygia. *J Ophthalmic Vis Res* 2016;11:153–8.
- Tan DT, Chee SP, Dear KB, et al. Effect of pterygium morphology on pterygium recurrence in a controlled trial comparing conjunctival autografting with bare sclera excision. *Arch Ophthalmol* 1997;115:1235–40.
- Biocic M, Vidosevic D, Boric M, et al. Anesthesia and perioperative pain management during cardiac electronic device implantation. *J Pain Res* 2017;10:927–32.
- Schiffman RM, Christianson MD, Jacobsen G, et al. Reliability and validity of the Ocular Surface Disease Index. *Arch Ophthalmol* 2000;118:615–21.
- Prabhasawat P, Barton K, Burkett G, et al. Comparison of conjunctival autografts, amniotic membrane grafts, and primary closure for pterygium excision. *Ophthalmology* 1997;104:974–85.
- Mittal K, Gupta S, Khokhar S, et al. Evaluation of autograft characteristics after pterygium excision surgery: autologous blood coagulum versus fibrin glue. *Eye Contact Lens* 2017;43:68–72.
- Hsu MY, Lee HN, Liang CY, et al. Pterygium is related to a decrease in corneal endothelial cell density. *Cornea* 2014;33:712–5.
- Lim-Bon-Siong R, Valluri S, Gordon ME, et al. Efficacy and safety of the ProTek (Vifilcon A) therapeutic soft contact lens after photorefractive keratectomy. *Am J Ophthalmol* 1998;125:169–76.
- Uy HS, Reyes JM, Flores JD, et al. Comparison of fibrin glue and sutures for attaching conjunctival autografts after pterygium excision. *Ophthalmology* 2005;112:667–71.
- Batta B, Fuchs-Buder T, Tréchet F, et al. [Simplified topical anesthesia protocol for ambulatory cataract surgery: safety and patient and surgeon satisfaction]. *J Fr Ophtalmol* 2014;37:548–56.
- Ratnalingam V, Eu AL, Ng GL, Al E, Gl N, et al. Fibrin adhesive is better than sutures in pterygium surgery. *Cornea* 2010;29:485–9.