

Nonchylous bilateral pleural effusion in a newborn: A rare case

Sir,

Pleural effusions are rare in the neonatal period. Similarly, nonchylous bilateral effusions are also rare in this period with limited data.^[1,2] We report a rare case of nonchylous bilateral pleural effusion associated with pneumonia.

A full-term male infant weighing 3600 g, appropriate for gestation, was born to a 19-year-old primigravida woman at the 39th week of gestation by lower cesarean section secondary to cephalopelvic disproportion. He was discharged in a healthy and stable condition 24 h after birth with his mother after several times of successful breastfeeding.

On the 4th day of life, he was admitted to our neonatal intensive care unit because of fever and poor feeding. To rule out the possibility of sepsis, a diagnostic test was performed. Parenteral ampicillin (100 mg/kg/day) and cefotaxime (200 mg/kg/day) were initiated. Results of sepsis workup showed normal chest X-ray (CXR), cerebrospinal fluid, and arterial blood gas analysis. However, C-reactive protein level was elevated (35 mg/l) and leukocytosis (white blood cell count: 25,000/mm³ with 70% polymorphonuclear leukocytes) was noted. On the 6th day of life, he developed respiratory distress that progressively worsened. He was intubated and started on mechanical ventilation. CXR showed bilateral pleural effusion and pneumonic infiltration [Figure 1]. Ultrasound of the chest on the same day confirmed bilateral pleural effusion in the right and left hemithorax, and pericardial effusion was absent. A total of 70 cc of clear fluid was drained from both the pleural cavities. Pleural fluid evaluation revealed protein 1.1 g/l (concomitant serum protein 3.5 g/l), sugar 86 mg/dl, triglyceride 10 mg/dl, cholesterol 16 mg/dl, and lactate dehydrogenase 540 IU/l (concomitant serum lactate dehydrogenase 1300 IU/l). No microorganisms were seen on Gram staining, and the pleural fluid culture was sterile, indicating nonchylous pleural effusion.

Further tests revealed normal thyroid, liver, and kidney function. No abnormalities were detected in the echocardiography except pleural effusion. A diagnosis of parapneumonic bilateral nonchylous pleural effusion was made.

After needle aspiration, respiratory distress decreased and the ventilator setup was accordingly decreased. Repeat CXR showed good lung expansion [Figure 2]. On the 7th day of life, chest ultrasonography revealed only minimal pleural effusion in the left thorax.

Ventilator support was discontinued on the 8th day of life after gradual weaning and prompted by self-endotracheal extubation by the patient. The following periods were uneventful. Subsequent CXRs were normal and breastfeeding was tolerated well.

There was no recurrence of pleural effusion or respiratory distress. He was discharged on the 16th day of life with a weight of 4300 g. The patient is now 6 months old and has no respiratory symptoms.

Although bilateral neonatal pleural effusion remains a rare entity, the awareness of this condition is vital for timely diagnosis to identify the underlying cause or associated condition to guide management decisions.

Declaration of patient consent

The authors certify that they have obtained all appropriate patient consent forms. In the form the

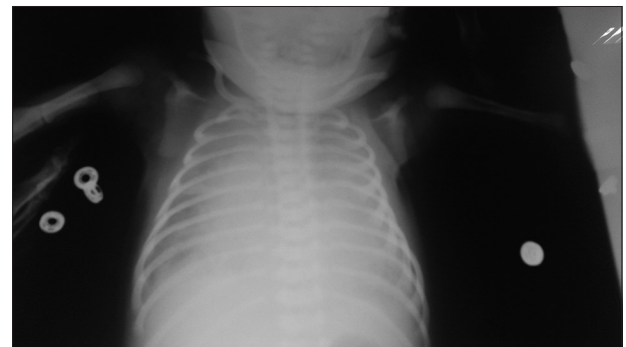

Figure 1: Chest X-ray showing bilateral pleural effusion

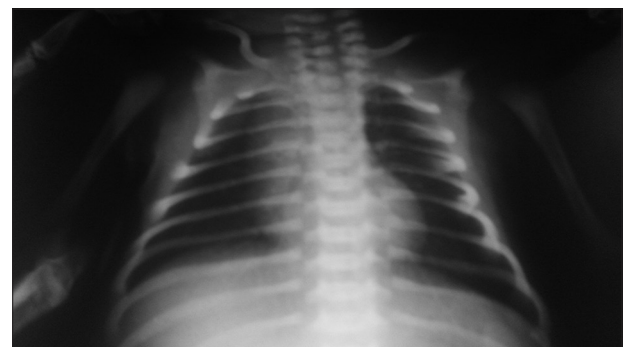


Figure 2: Follow-up chest radiograph showing the full expansion of lung fields after the pleural tap

patient(s) has/have given his/her/their consent for his/her/their images and other clinical information to be reported in the journal. The patients understand that their names and initials will not be published and due efforts will be made to conceal their identity, but anonymity cannot be guaranteed.

Acknowledgments

This study was supported by Isfahan University of Medical Sciences, Isfahan, Iran.

Financial support and sponsorship

This study was sponsored by the Isfahan University of Medical Sciences, Isfahan, Iran.

Conflicts of interest

There are no conflicts of interest.

**Parvaneh Sadeghi-Moghadam, Mohsen Pourazizi^{1,2},
Shamim Shafieyoon³**

Department of Pediatrics, Faculty of Medicine, Qom University of Medical Sciences, Qom, Iran, ¹Cancer Research Center, Semnan University of Medical Sciences, Semnan, Iran, ²Isfahan Eye Research Center, Student's Research Committee, Isfahan University of Medical Sciences, Isfahan, Iran, ³Department of pediatric, Student's Research Committee, Isfahan University of Medical Sciences, Isfahan, Iran

Address for correspondence: Dr. Shamim Shafieyoon,
Student's Research Committee, Isfahan University of Medical
Sciences, Isfahan, Iran.
E-mail: shshafieyoon@gmail.com

REFERENCES

1. Rocha G, Fernandes P, Rocha P, Quintas C, Martins T, Proença E. Pleural effusions in the neonate. *Acta Paediatr* 2006;95:791-8.
2. Wang LS, Wang HY, Zhou WH. Mid-term follow-up of neonatal pleural effusion. *Indian Pediatr* 2014;51:487-9.

This is an open access journal, and articles are distributed under the terms of the Creative Commons Attribution-NonCommercial-ShareAlike 4.0 License, which allows others to remix, tweak, and build upon the work non-commercially, as long as appropriate credit is given and the new creations are licensed under the identical terms.

Access this article online

Quick Response Code:



Website:

www.jmsjournal.net

DOI:

10.4103/jrms.JRMS_799_18

How to cite this article: Sadeghi-Moghadam P, Pourazizi M, Shafieyoon S. Nonchylous bilateral pleural effusion in a newborn: A rare case. *J Res Med Sci* 2019;24:11.