

Synchronous occurrence of appendiceal mucinous cystadenoma, with colon adenocarcinoma and tubulovillous rectal adenoma: Management and review of the literature

Nikolaos S. Salemis,
Georgios Nakos¹,
Ilias Katikaridis¹,
Andreas Zografidis

Departments of Pathology and ¹Surgery, Army General Hospital, Athens, Greece

Address for correspondence:

Dr. Nikolaos S. Salemis, Department of Surgery, Army General Hospital, 19 Taxiarchon Street, 19014 Kapandriti, Athens, Greece. E-mail: nikos_salemis@hotmail.com

Abstract

Appendiceal mucocele (AM) is a rare clinical entity comprising 8% of all appendiceal tumors, and it is seen in 0.2–0.3% of all appendectomy specimens. Apart from sporadic cases, there are not enough published data about the incidence of synchronous appendiceal tumors in patients with colorectal cancer. We describe a very rare case of synchronous occurrence of AM, colon adenocarcinoma, and tubulovillous adenoma of the rectum and review the relevant literature. We conclude that thorough preoperative and perioperative evaluations are mandatory in patients undergoing surgery for colorectal cancer to exclude a synchronous colon or an appendiceal primary tumor. Larger prospective studies are necessary to accurately determine the incidence of synchronous appendiceal tumors and colorectal cancer.

Key words: Adenoma, appendix, colon carcinoma, mucocele

INTRODUCTION

Appendiceal mucocele (AM) is defined as a gross dilatation of the vermiform appendix, caused by the accumulation of mucus material within the appendiceal lumen secondary to inflammatory or neoplastic proliferation of the appendiceal mucosa.^[1] AM is a rare clinical entity comprising 8% of all appendiceal tumors, and it is seen in 0.2–0.3% of all appendectomy specimens.^[2] Histologically, AMs have been divided into four subtypes: (1) Simple mucocele or retention cyst accounting for 20% of the cases, considered to be due to the obstruction of the appendiceal lumen, (2) focal or diffuse mucosal hyperplasia (20%), (3) mucinous cystadenoma (50%), and (4) mucinous cystadenocarcinoma (10%).^[1,2] Mucinous cystadenoma is the most common histological subtype of mucocele mostly exhibiting epithelial villous adenomatous changes with some degree of atypia.^[1-3] Although synchronous colorectal neoplasia has been reported in 3–5% of the cases,^[3] the synchronous occurrence of mucinous cystadenoma of the appendix and colorectal cancer is a rare clinical entity. We describe a case of simultaneous occurrence of mucinous

cystadenoma of the appendix, colon adenocarcinoma, and tubulovillous colon adenoma. Diagnostic evaluation and management of the patient are discussed along with a review of the relevant literature.

CASE REPORT

A 67-year-old Caucasian male presented with a 10-day history of gradually worsening abdominal pain, associated with nausea and episodes of vomiting. His medical history was significant for arterial hypertension. Physical examination revealed a distended abdomen with a palpable tender mass in the left lower quadrant. The hemogram revealed anemia with a hemoglobin level of 9.5 g/dL and a hematocrit of 30%. Biochemical investigations revealed elevated serum levels of C-reactive protein 49 mg/L (reference range < 5) and significantly elevated serum carcinoembryonic antigen levels 500 ng/mL (reference range 0–10). Colonoscopy revealed an ulcerative mass obstructing the lumen of the sigmoid colon located 25 cm from the anal verge and a mass located 9 cm from the anal verge. Biopsies taken showed

a poorly differentiated colon adenocarcinoma. Computed tomography (CT) scans showed significant thickening of the sigmoid colon along with hepatic and pulmonary nodules suggestive of secondary lesions.

At laparotomy, a large tumor was found obstructing the sigmoid lumen with infiltration of the serosal fat. The appendix was distended with a maximum diameter of approximately 2 cm. Liver metastases were also noted. A Hartman's procedure (sigmoid colectomy with end colostomy and oversewing of the rectal stump) along with appendectomy was performed. A transanal local excision of the rectal tumor was also performed. The postoperative course was uneventful. Histopathological examination showed a moderate to poorly differentiated sigmoid adenocarcinoma with extensive infiltration of the pericolic fat tissue. Four out of the twenty resected lymph nodes contained extensive metastases. Histology of the rectal tumor showed a tubulovillous rectal adenoma with high-grade dysplasia measuring 1.8 cm × 1.5 cm whereas the histopathological findings of the appendiceal tumor were suggestive of mucinous cystadenoma [Figure 1]. Although the patient received adjuvant chemotherapy, he unfortunately died of progressive disease 5 months later.

DISCUSSION

The appendix is embryologically derived from the large intestine and has a similar mucosal pattern to the colon. Therefore, any neoplastic change of the colon can affect the appendix.^[3,4]

Apart from sporadic cases,^[1,5-13] there are not enough published data about the incidence of synchronous appendiceal tumors in patients with colorectal cancer.^[4] Only four retrospective studies have reported such an incidence ranging from 0.3–11%.^[3,4,14,15] Khan and Moran^[3] reported an incidence of 4.1% of synchronous appendiceal epithelial tumors among 169 patients who underwent colorectal surgery and removal of the appendix. Mucinous cystadenoma was the most common appendiceal synchronous tumor found. The authors suggested that appendectomy should be performed in all patients undergoing surgery for colorectal cancer, given that appendectomy is unlikely to be an additional infective risk in major bowel resection and that the appendiceal mucosa is inaccessible in postoperative surveillance colonoscopy, which is mandatory in this group of patients.^[3]

In another retrospective study, Lohsiriwat *et al.*^[4] found that only one (0.3%) out of 293 patients who underwent surgery for colorectal cancer had a synchronous epithelial appendiceal tumor. The authors' explanation for the very

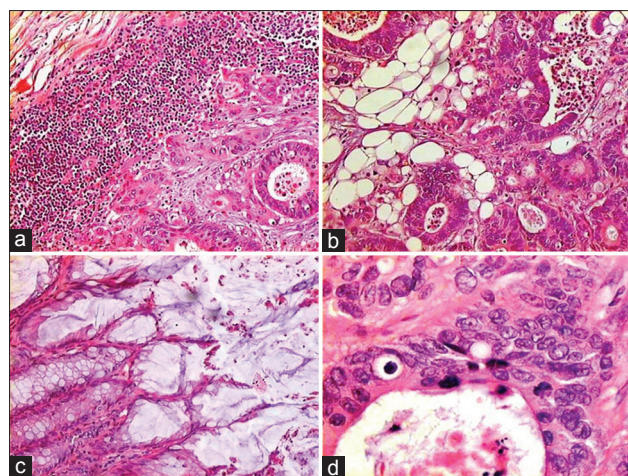


Figure 1: (a) Metastatic nodal infiltration by a colon adenocarcinoma (H and E, ×100). (b) Extensive infiltration of the pericolic fat tissue by a moderate to poorly differentiated colon adenocarcinoma (H and E, ×100). (c) Histological findings of mucinous cystadenoma of the appendix. Cylindrical epithelium and mucin production. Note the absence of atypia and mitotic figures (H and E, ×100). (d) A tubulovillous adenoma with high-grade dysplasia (H and E, ×400)

low incidence of synchronous primary appendiceal tumor in patients with colorectal cancer was that tumorigenesis of the appendix and other parts of the large bowel is not the same because the appendiceal mucosa, unlike large bowel mucosa, is not directly exposed to carcinogens in fecal material.^[4] Larger prospective studies are necessary to accurately determine the incidence of synchronous appendiceal tumors and colorectal cancer.^[4] Regarding the synchronous occurrence of AM, colon adenocarcinoma, and tubulovillous colon adenoma, we found only one case reported in the literature so far.^[16]

AMs occur most frequently in middle-aged patients with a higher incidence in women.^[2] The most common clinical presentation is a palpable mass in the right lower abdomen.^[2] There are no pathognomonic symptoms and signs, thus making preoperative diagnosis difficult.^[3] Some patients may be asymptomatic and the lesions are incidentally detected during imaging or operations performed for unrelated reasons.^[17] In some cases, however, the appendix may be macroscopically normal with even no intraoperative suggestion of an appendix tumor.^[3,4] In our case, the appendix was mildly distended with a maximum diameter of 1.3 cm on histology report. In a retrospective study including 129 patients with mucocele, Stocchi *et al.*^[14] found that the presence of symptoms such as abdominal pain and weight loss was associated more frequently with malignancy.

On ultrasonography, AM can appear as an anechoic or hypoechoic structure depending on mucus composition. On CT scan, which is the diagnostic modality of choice,^[18]

the lesion can be well circumscribed with central areas of hypoattenuation.^[2]

The main differential diagnoses of AM include periappendicular abscess, enteric duplication cysts, mesenteric cysts, and ovarian masses.^[2] The treatment of AM is surgical resection to eliminate any malignant potential,^[18] whereas the type and extend of surgery primarily depend on the dimensions and histological features.^[17,18] Thorough inspection of the peritoneal cavity is essential during surgery to detect a concomitant colon or ovarian tumor.^[1,2] Special care should be taken when mobilizing the tumor to avoid rupture of mucocele and subsequent spillage of mucin into the peritoneal cavity, resulting in the development of pseudomyxoma peritonei. Follow-up is of utmost importance after surgery not only for the appendicular disease but also due to the possibility of synchronous or metachronous tumors.^[15]

CONCLUSION

The synchronous occurrence of mucinous cystadenoma of the appendix, colon adenocarcinoma, and tubulovillous rectal adenoma is an extremely rare clinical entity. Thorough preoperative and perioperative evaluations are mandatory in patients with colorectal cancer to exclude a synchronous colon or appendiceal primary tumor. Follow-up is essential in this group of patients.

Financial support and sponsorship

Nil.

Conflicts of interest

There are no conflicts of interest.

REFERENCES

1. Fujiwara T, Hizuta A, Iwagaki H, Matsuno T, Hamada M, Tanaka N, *et al.* Appendiceal mucocele with concomitant colonic cancer. Report of two cases. *Dis Colon Rectum* 1996;39:232-6.
2. Honnif I, Moschopoulos M, Roeren T. Appendiceal mucinous cystadenoma. *Radiographics* 2008;28:1524-7.
3. Khan MN, Moran BJ. Four percent of patients undergoing colorectal cancer surgery may have synchronous appendiceal neoplasia. *Dis Colon Rectum* 2007;50:1856-9.
4. Lohsiriwat V, Vongjirad A, Lohsiriwat D. Incidence of synchronous appendiceal neoplasm in patients with colorectal cancer and its clinical significance. *World J Surg Oncol* 2009;7:51.
5. Savchenko IU, Polovinkin VV, Fedosov SR, Pryn' PS. Combination of giant mucocele of the appendix and adenocarcinoma of the rectum. *Khirurgiia (Mosk)* 2006;10:57-9.

6. Lee YT, Wu HS, Hung MC, Lin ST, Hwang YS, Huang MH. Ruptured appendiceal cystadenoma presenting as right inguinal hernia in a patient with left colon cancer: A case report and review of literature. *BMC Gastroenterol* 2006;6:32.
7. Djuranovic SP, Spuran MM, Kovacevic NV, Ugljesic MB, Kecmanovic DM, Micev MT. Mucinous cystadenoma of the appendix associated with adenocarcinoma of the sigmoid colon and hepatocellular carcinoma of the liver: Report of a case. *World J Gastroenterol* 2006;12:1975-7.
8. Vicenzi L, Moser A, Mazzola F, Rizzo S, Bonomo S, Bottura D, *et al.* Appendiceal mucocele associated with colonic neoplasm. Report of 2 cases and review of the literature. *Chir Ital* 2001;53:420-4.
9. Ohta H, Komibuchi T, Oe S, Hanafusa T, Ukikusa M, Awane H, *et al.* Incidental 67Ga uptake into an appendiceal mucocele in a patient with sigmoid colon cancer. *Ann Nucl Med* 1996;10:257-9.
10. Zullo A, Botto G, Pastormerlo M. A case of appendiceal mucocele associated with cancer of the colon. *Minerva Chir* 1995;50:1095-8.
11. Yonei Y, Kameda T, Ozawa Y, Ueno H, Tsukada N, Inagaki Y, *et al.* A case of appendiceal mucocele showing massive mucous production with concomitant colonic cancer. *Gastroenterol Jpn* 1993;28:102-9.
12. Damianov D. Mucocele of the appendix associated with carcinoma of the sigmoid in a single patient. *Khirurgiia (Sofia)* 1985;38:92-4.
13. Versaci A, Rossitto M, Giuffrè M, Leonello G, Pagano G, Terranova M. A case of appendiceal mucocele associated with adenocarcinoma of the left colon. *G Chir* 1999;20:397-401.
14. Stocchi L, Wolff BG, Larson DR, Harrington JR. Surgical treatment of appendiceal mucocele. *Arch Surg* 2003;138:585-9.
15. García Lozano A, Vázquez Tarrago A, Castro García C, Richart Aznar J, Gómez Abril S, Martínez Abad M. Mucocele of the appendix: Presentation of 31 cases. *Cir Esp* 2010;87:108-12.
16. Albayrak Y, Capoglu R, Kabalar ME, Bayraktutan U. Coexistence of appendix mucinous cystadenoma, tubulovillous adenoma of the colon and adenocarcinoma of the colon. *Minerva Chir* 2012;67:284-5.
17. Papaziogas B, Koutelidakis I, Tsiaousis P, Goula OC, Lakis S, Atmatzidis S, *et al.* Appendiceal mucocele. A retrospective analysis of 19 cases. *J Gastrointest Cancer* 2007;38:141-7.
18. Persaud T, Swan N, Torreggiani WC. Giant mucinous cystadenoma of the appendix. *Radiographics* 2007;27:553-7.

This is an open access article distributed under the terms of the Creative Commons Attribution-NonCommercial-ShareAlike 3.0 License, which allows others to remix, tweak, and build upon the work non-commercially, as long as the author is credited and the new creations are licensed under the identical terms.

For reprints contact: reprints@medknow.com

Access this article online	
Quick Response Code:	Website: www.jnsbm.org
	DOI: 10.4103/0976-9668.184705

How to cite this article: Salemis NS, Nakos G, Katikaridis I, Zografidis A. Synchronous occurrence of appendiceal mucinous cystadenoma, with colon adenocarcinoma and tubulovillous rectal adenoma: Management and review of the literature. *J Nat Sc Biol Med* 2016;7:173-5.