

Penile pyoderma gangrenosum

Mariam Philip, Joan Felicita Samson, Puthenveetil Salahudin Simi, G. Nandakumar¹, Biju Mathew²
 Department of Dermatology and Venereology, Dr. SMCSI Medical College, Karakonam, ¹Department of Pathology,
 Government Medical College, Trivandrum, ²Department of Urology, Dr. SMCSI Medical College, Karakonam, Kerala, India

Address for correspondence:

Dr. Mariam Philip, Department of Dermatology and Venereology, Dr. SMCSI Medical College, Karakonam, Kerala, India.
 E-mail: mphilipgeorge@gmail.com

Abstract

A 70-year-old man presented with indurated penile ulcers of 1-month duration. Initial biopsy was reported as chronic ulcer. A repeat biopsy done due to inadequate response to doxycycline showed features of pyoderma gangrenosum. The ulcer healed with a course of steroids and has not recurred till date.

Key words: Pyoderma gangrenosum, penile, ulcers

INTRODUCTION

Pyoderma gangrenosum (PG) is a rare, chronic, often destructive, inflammatory skin disease. It is characterized by a painful nodule or pustule which breaks down to form a progressively enlarging ulcer with a raised, tender, undermined border. It can occur by itself or with an underlying systemic disorder.^[1] PG most commonly occurs on the lower extremities and trunk of adults aged 40-60 years.^[2]

CASE REPORT

A 70-year old male, living with spouse presented with relatively asymptomatic ulcers over the penis of 1 month duration. He denied any extramarital contact. He was not a known diabetic or hypertensive.

General examination was within normal limits. Local examination showed two indurated ulcers 1.5 × 1 cm and 0.5 × 0.4 cm over the penis at the junction of foreskin and coronal sulcus. The ulcers bled on touch. There was no inguinal or femoral lymphadenopathy [Figure 1].

Squamous cell carcinoma penis, tuberculous ulcer, donovanosis, and Herpes genitalis (either because of immunocompromise or development of resistant mutation) were considered as the differential diagnosis. The following investigations: Routine blood and urine examinations, peripheral smear, ANA, rheumatoid factor, VDRL, ELISA-HIV, HBsAg, anti-HCV, Mantoux test, Chest X-ray PA view, Ultrasound abdomen, gram stain from the ulcer, and tissue smear for Donovan bodies were negative or within normal limits.

A biopsy was done, and the patient was started on doxycycline 100 mg twice daily. Biopsy revealed a chronic ulcer with no evidence of malignancy. Tissue culture for mycobacteria and fungi were negative. Despite 3 weeks of doxycycline, the ulcers were found to be increasing in size and extent. A repeat biopsy was done, and the patient was circumcised to accelerate the healing process.

The second biopsy showed an ulcer with hyperplasia of the adjacent epidermis and a dense inflammatory cell infiltrate in the dermis composed of lymphocytes, neutrophils, Langhans, and foreign body type of multinucleate giant cells. Proliferation of capillary-sized blood vessels with perivascular accumulation of inflammatory cells was noted [Figure 2].

With these histopathological findings and clinical correlation, an alternative diagnosis of PG was considered. He was started on 40 mg of prednisolone

Access this article online

Quick Response Code:



Website:

www.ijstd.org

DOI:

10.4103/0253-7184.120563

How to cite this article:

Philip M, Samson JF, Simi PS, Nandakumar G, Mathew B. Penile pyoderma gangrenosum. Indian J Sex Transm Dis 2013;34:138-40.

per day. The ulcer started healing on the third day. Prednisolone was tapered and stopped by 4 weeks. There has been no recurrence even 12 months after stopping treatment [Figure 3].

This case is reported for its extreme rarity. PG is rare, and there are only very few reports of penile PG.

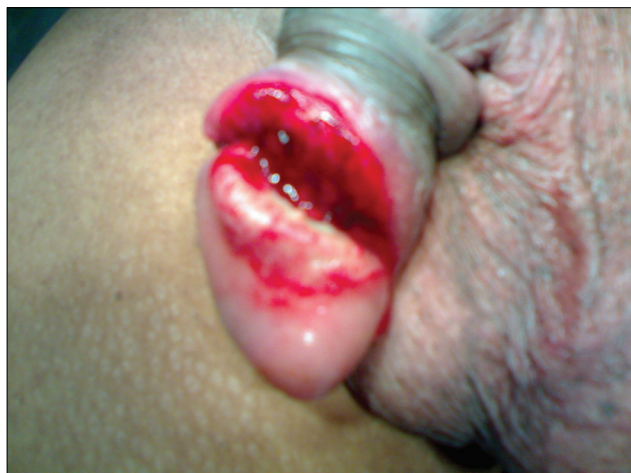

Figure 1: Shallow ulcers with irregular margins and indurated base over the penis at the junction of foreskin and coronal sulcus

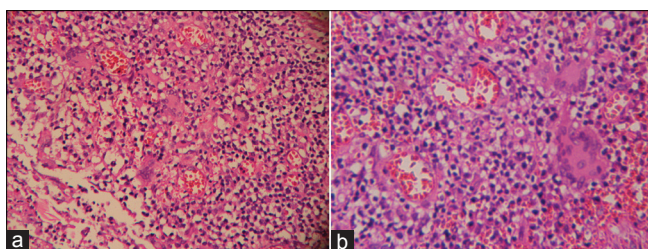


Figure 2 (a, b): A dense inflammatory cell infiltrate in the dermis composed of lymphocytes, neutrophils, Langhans, and foreign body type of multinucleate giant cells



Figure 3: 4 weeks after treatment

DISCUSSION

The initial description of PG was done by Brunsting in the year 1930.^[2] PG is a rare noninfectious neutrophilic dermatosis commonly associated with underlying systemic disease. The diagnosis is based on typical clinical features and exclusion of other cutaneous ulcerating diseases.^[3] PG can have a variety of clinical presentations such as ulcerative, pustular, bullous, and vegetative forms.^[4] The disease begins with small tender papules or pustules that evolve into painful ulcers with characteristic violaceous undermined edges. Lesions may be solitary or multiple and heal with atrophic cribriform scar. PG may be associated with constitutional symptoms.^[5]

Although the disease is idiopathic, in 25-50% of patients, an underlying immunologic abnormality may exist.^[6] The most common associations are inflammatory bowel disease (ulcerative colitis and Crohn's disease), arthritis (seronegative arthritis and rheumatoid arthritis), and hematologic diseases (myelogenous leukemia, hairy cell leukemia, myelofibrosis, and monoclonal gammopathy). Other neutrophilic dermatoses associated with PG are Behçet's disease, subcorneal pustular dermatosis, and Sweet's syndrome.^[1]

Systemic corticosteroids or cyclosporine are the first line of therapy for disseminated and localized disease. Alternatives such as mycophenolate mofetil, tacrolimus, infliximab, or plasmapheresis may also be used.^[7]

The diagnosis of PG of the genitalia is made on the exclusion of other causes of genital ulcers—infectious diseases (syphilis, chancroid, genital herpes, cutaneous tuberculosis, donovanosis, amoebiasis, and deep fungal infections), drug eruptions, traumatic ulcerations, Behçet's disease, and neoplasms. A biopsy is helpful to exclude most of these conditions, and this would make diagnosis of PG more obvious.

PG localized to the penis is rare.^[8] This case is reported to highlight the fact that rare conditions like PG should be a differential diagnosis of genital ulcers, which do not respond to usual modes of treatment. Penile PG in the elderly may masquerade as squamous cell carcinoma penis and if correctly diagnosed could avert mutilating surgery.

REFERENCES

1. Wolff K, Stingl G. Pyodermagangrenosum. In: Freedberg IM, Eisen AZ, Wolff K, et al., editors. Fitzpatrick's Dermatology in General Medicine. 5th ed. Vol. 2. New York, NY: McGraw-Hill; 1999. p. 2207-13.
2. James WD, Berger TG, Elston DR. Erythema and urticaria. In: James WD, Berger TG, Elston DR, editors. Andrews' diseases of the skin-Clinical dermatology. 10th ed. Vol. 7. Canada: Elsevier; 2006. p.

- 139-256.
3. Callen JP. Pyodermagangrenosum and related disorders. *Dermatol Clin* 1990;7:1249-59.
 4. Powell FC, Su WP, Perry HO. Pyodermagangrenosum: Classification and management. *J Am Acad Dermatol* 1996;34:395-409.
 5. Barham KL, Jorizzo JL, Grattan B, Cox NH. Vasculitis and neutrophilic vascular reactions. In: Burns T, Breathnach S, Cox N, Griffiths C, editors. *Rook's Textbook of Dermatology*. 7thed. Vol. 49. UK: Blackwell; 2004. p. 36-9.
 6. Ruocco E, Sanguiliano S, Gravina AG, Miranda A, Nicoletti G. Pyodermagangrenosum: An updated review. *J Eur Acad Dermatol Venereol* 2009;23:1008-17.
 7. Reichrath J, Bens G, Bonowitz A, Tilgen W. Treatment recommendations for pyodermagangrenosum: An evidence-based review of the literature based on more than 350 patients. *J Am Acad Dermatol* 2005;53:273-83.
 8. Gungor E, Karakayali G, Alli N, Artiiz F, Lenk N. Penile pyodermagangrenosum. *J Eur Acad Dermatol Venereol* 1999;12:59-62.

Source of Support: Nil. **Conflict of Interest:** None declared.

FEMALE GENITAL MUCOSA

The female genital tract consists of vagina, uterus (Cervix & endometrium), fallopian tubes and ovaries.

VAGINA

The vagina is a muscular tube lined by a stratified squamous mucosa containing abundant glycogen. There is no epithelial keratin layer, but the mucosa is protected by an acid environment resulting from bacterial growth on a glycogen substrate supplied by the mucosa.

APPLIED

- Vaginal mucosa is rich in lactobacilli which produces lactic acid and hydrogen peroxide, thus it is resistant to bacterial vaginosis and candidal infection.
- Vaginal mucosa is commonly infected by trichomonas vaginalis.

CERVIX

The cervix is the lower end of the uterus. The outer cervix is lined by a stratified squamous mucosa containing abundant glycogen. At the cervical os, the squamous epithelium changes to a tall columnar mucinous epithelium. squamocolumnar junction is called the **transformation zone**.

There is progressive maturation to the surface, where the flattened squamous cells have a low nuclear/cytoplasmic ratio with abundant pale-staining cytoplasm containing glycogen. The cervical surfaces receives greater wear and tear, thus there is a thick acellular layer of keratin (keratinizing squamous epithelium), as on skin.

APPLIED

- Acute gonococcal infection in woman causes endocervicitis. It is characterized by edema, erythema and erosion of cervix.
- Cervical atypia is present in CIN or cervical cancers which can be detected by PAP smear.

UTERUS

The endometrial cavity is lined by the endometrium, which is highly responsive to hormonal changes. The actual endometrial epithelial surface of columnar cells, some of which are ciliated, is not prominent. What is prominent are glands in a thick lamina propria. Thus, endometrium consists of glands and stroma. The stroma is composed of many small fibroblastic cells along with scattered lymphocytes, macrophages, and blood vessels.

FALLOPIAN TUBES

The fallopian tube is lined by a columnar epithelium, some with cilia and some with a secretory function. Some of the cilia beat upward to help sperm ascend, while other beat downward to conduct ova toward the uterus. The structure of the fallopian tube is complex in cross-section, with many fingers of epithelial-covered lamina propria creating a maze-like appearance.

APPLIED

- Sexually transmitted bacteria may ascend through uterus to tubes causing salpingitis.
- Hydrosalpinx is collection of fluid and Pyosalpinx is collection of pus in fallopian tubes.

OVARY.

The ovary is covered by a single layer of cubical cell known as germinal epithelium. The substance of gland consists of outer cortex and inner medulla.

APPLIED

- Follicular cysts are common and originate from unruptured griffin follicle.
- Luteal cysts are formed in the corpus luteum due to retention of fluid preventing corpus luteum from becoming fibrosed.
- Polycystic ovarian disease is characterized by bilateral enlarged polycystic ovaries.